

Ocular Determinants of Peripapillary Vessel Density in Healthy African Americans: The African American Eye Disease Study

Andrew J. Nelson,¹ Ryuna Chang,¹ Vivian LeTran,¹ Brian Vu,² Bruce Burkemper,³ Zhongdi Chu,⁴ Ali Fard,⁵ Amir Kashani,¹ Benjamin Xu,¹ Ruikang Wang,⁴ Rohit Varma,⁶ and Grace M. Richter¹; for the African American Eye Disease Study Group

¹USC Roski Eye Institute, Department of Ophthalmology, Keck School of Medicine of the University of Southern California, California, United States

²University of Colorado School of Medicine, Aurora, Colorado, United States

³Departments of Preventive Medicine, Keck School of Medicine of the University of Southern California, Los Angeles, California, United States

⁴Department of Bioengineering, University of Washington, Washington, United States

⁵Carl Zeiss Meditec, Dublin, California, United States

⁶Southern California Eye Institute, CHA Hollywood Presbyterian Medical Center, Los Angeles, California, United States

Correspondence: Grace M. Richter, USC Roski Eye Institute, 1450 San Pablo Street, Suite 4700, Los Angeles, CA 90033, USA; grace.richter@med.usc.edu.

See the appendix for the members of the African American Eye Disease Study Group.

Submitted: March 7, 2019

Accepted: July 3, 2019

Citation: Nelson AJ, Chang R, LeTran V, et al; for the African American Eye Disease Study Group. Ocular determinants of peripapillary vessel density in healthy African Americans: the African American Eye Disease Study. *Invest Ophthalmol Vis Sci.* 2019;60:3368-3373. <https://doi.org/10.1167/iovs.19-27035>

PURPOSE. The African American (AA) population has unique ocular anatomic characteristics and a disproportionately high incidence of glaucoma, which is associated with lower peripapillary vessel density (VD). This study aimed to identify ocular determinants of peripapillary VD in healthy AAs.

METHODS. This was a cross-sectional, population-based study of 1029 AAs, ages 40 and older. Participants underwent examination to obtain axial length (AL), IOP, central corneal thickness (CCT), mean retinal nerve fiber layer (RNFL) thickness, visual field mean deviation (MD), and 6 × 6-mm optical coherence tomography angiography scans of the optic nerve. Participants with glaucoma, vision-threatening diabetic retinopathy, or other relevant ocular disease were excluded. Prototype software was used to quantify VD. A multivariable regression model, controlling for age and signal strength, identified the ocular variables that predicted peripapillary VD. The contribution of each variable was assessed with the magnitude of standardized regression coefficients (SRC).

RESULTS. Based on univariate regressions, AL, RNFL thickness, and MD had significant associations with peripapillary VD (all $P < 0.001$). In the final multivariate model, lower mean RNFL thickness ($\beta = 0.0022$, $P < 0.001$, SRC = 0.542) and longer AL ($\beta = -0.0055$, $P < 0.001$, SRC = -0.118) were associated with lower peripapillary VD, controlling for age and signal strength, with model R^2 of 0.69.

CONCLUSIONS. Thinner RNFL and longer AL were the most influential ocular determinants of lower peripapillary perfusion in healthy AA eyes. Additional research is needed to clarify whether longer AL increases risk of glaucoma by affecting capillary perfusion.

Keywords: optical coherence tomography angiography, glaucoma, retinal blood flow, epidemiology

The prevalence of glaucoma in African Americans (AA) ranges from 4% in ages 50 to 59 to 13% in ages 80 to 89, much greater than the 2% to 3% prevalence in Americans overall.¹ In fact, glaucoma is currently the leading cause of irreversible blindness in AA in the United States.² Interestingly, Siesky et al.³ found reduced retrobulbar blood flow in AA eyes compared with those of European descent with similar IOP and glaucoma staging. AAs on the whole have been shown to have differences in other ocular anatomic characteristics, including thinner central corneal thickness (CCT),^{4,5} larger optic nerve head (ONH),⁶ increased cup-to-disc ratio (CDR),⁷ more beta zone peripapillary atrophy,⁸ and reduced pattern standard deviation on automated perimetry visual fields,⁴ as compared with Caucasian populations. The degree to which such

differences in ocular anatomic characteristics may contribute to the higher rates of glaucoma in AA deserves exploration.

Optical coherence tomography angiography (OCTA) is a noninvasive imaging technique, which provides high-resolution imaging of the retinal microvasculature with high repeatability and reproducibility.⁹ OCTA can be used to quantify vascular perfusion of the radial peripapillary capillaries (RPC) plexus that supplies the RNFL, and reduced peripapillary vessel density (VD) has been shown to be a good diagnostic marker of glaucoma.¹⁰⁻¹² Currently, little is known regarding the ocular variables that may influence peripapillary VD in healthy subjects.¹³⁻¹⁵ These data are important as clinicians and scientists seek to understand the utility of peripapillary VD measurements for glaucoma and other conditions in patients



with varying ocular anatomy. In this study, we sought to identify ocular anatomic factors associated with lower peripapillary VD in healthy AA eyes. We hypothesized that risk factors for glaucoma, such as elevated IOP, thin CCT, and myopia may be associated with lower peripapillary VD, which could then support a mechanistic link between these risk factors and subsequent glaucomatous optic neuropathy.

METHODS

This study was approved by the Health Science Institutional Review Board of the University of Southern California, is compliant with the Health Insurance Portability and Accountability Act of 1996 and is adherent to the tenets of the Declaration of Helsinki.

Study Population

In this population-based, cross-sectional study, AA aged 40 years and older living within 30 Census tracts in and around Inglewood, California, were invited to participate over a 5-year period from January 2013 through December 2017. Of the target population, approximately 8000 subjects, over 6300 AA participated in the study upon completion, resulting in a participation rate of approximately 80%. The study design and data collection methods have been previously published.¹⁶ In short, during household screening, interviewers explained the study, obtained informed consent, and conducted an in-home, computer-assisted interview. OCTA scans were introduced in the study beginning in February 2016, and subjects who received OCTA imaging were potential participants in this study.

Clinical Assessment

Study participants visited a local eye examination center for a comprehensive examination by one ophthalmologist and several technicians. Participants first completed an in-clinic questionnaire to determine medical and ocular history, potential risk factors for ocular disease, and access to health-care before proceeding to the eye examination. At the conclusion of the visit, the ophthalmologist discussed results with the participants, made appropriate diagnoses, and provided referrals for specialty care if needed. Healthy participants included normal and glaucoma suspects based on the presence of a nonglaucomatous optic disc. Glaucoma diagnosis was made by the comprehensive ophthalmologist and was based on clinical examination, including evaluation for an optic nerve rim defect characteristic of glaucoma and visual field assessment. Participants were excluded for the following reasons: diagnosis of glaucoma or vision-threatening diabetic ocular disease (including severe nonproliferative diabetic retinopathy, proliferative diabetic retinopathy, and diabetic macular edema); signal strength (SS) less than seven (of 10); and poor image quality as assessed by a standardized image-quality grading algorithm. For subjects with both eyes meeting inclusion criteria, the right eye was selected for analysis to prevent bias due to intereye correlation.

Measurement of Ocular Variables

IOP was measured three times before pupil dilation with Goldmann applanation tonometry, and these values were averaged for each eye. Blood pressure was measured twice and averaged. Mean RNFL thickness measurements were obtained from OCT (Cirrus 5000 HD-OCT; Carl Zeiss Meditec, Dublin, CA, USA). CCT and axial length (AL) measurements were obtained from A-scan ultrasound and recorded as the

average of 3 measurements (4000B A-Scan/Pachymeter; DGH Technology, Inc., Exton, PA, USA). Global mean deviation (MD) was recorded using the Humphrey Field Analyzer II Swedish Interactive Threshold Algorithm 24-2 (Carl Zeiss Meditec). Participants also underwent 6 × 6-mm optic nerve head scan using spectral domain-OCTA (Cirrus 5000 HD-OCT with Angioplex; Carl Zeiss Meditec). A single ONH scan was done for each eye of each participant.

Vessel Density Quantification

Two-dimensional en face OCT angiograms of the RPC layer were generated with automated segmentation software (Cirrus 11.0), with the RPC defined as the segment extending superficially from the inner limiting membrane to the posterior surface of the RNFL. En face images were then processed using custom software with an interactive interface in order to quantify the RPC vascular density using a previously described method.¹⁷ The software used a method combining a global threshold, Hessian filter, and adaptive threshold to generate binary vessel maps, which were used to calculate quantitative indices of blood flow in MATLAB (R2017a; MathWorks, Inc., Natick, MA, USA). The avascular zone of the ONH was manually selected to establish baseline background noise level for global thresholding, and the ONH was excluded from quantification. Large vessels greater than 32 μm in diameter were also excluded. VD was defined as the unitless ratio of the total image area occupied by white pixels in the binary vessel map to the total image area of all pixels.

Statistical Analysis

The ocular variables that we assessed were AL, CCT, IOP, RNFL thickness, and MD. Mean and standard deviation were calculated for each of the ocular variables, as well as for age and OCTA SS. Univariate linear regressions were performed for each pair of variables with peripapillary VD as well as with each other. A preliminary analysis of the relationship between mean arterial pressure and peripapillary VD was also performed, and no significant association was found.

We used multivariable linear regression models to assess the contributions of AL, CCT, IOP, visual field MD, and mean RNFL thickness to the dependent variable, peripapillary VD. The best-fit model was chosen using stepwise selection with cut-off point of $P = 0.05$. The relative contribution of each independent variable to the VD was assessed using the magnitude of standardized regression coefficients (SRC). Variance inflation coefficients were computed to assess for collinearity in the multivariable model. The model R^2 reflects the proportion of variation in peripapillary VD that is explained by the ocular variables in the model, along with age and SS. Locally weighted scatterplot smoothing (LOWESS) plots were generated to reflect the relationship between peripapillary VD and the ocular variables included in the multivariable model.¹⁸ LOWESS regression lines used localized smoothing, such that the relative strength of associations at different variable values can be visually appreciated. All analyses were performed using SAS 9.4 (SAS Institute, Cary, NC, USA).

We also performed the same univariate regressions and multivariable model selection procedure using peripapillary flux, defined as the average flow intensity within the detected vasculature in the binary vessel map, rather than VD to assess whether there was a difference between the two parameters. We have previously reported that the diagnostic accuracy of flux in glaucoma is comparable to that of VD.^{19,20} Analysis revealed no significant differences between determinants of peripapillary flux versus VD. Given that VD is the more commonly used parameter in OCTA analysis, we chose to focus on the determinants of VD rather than flux.

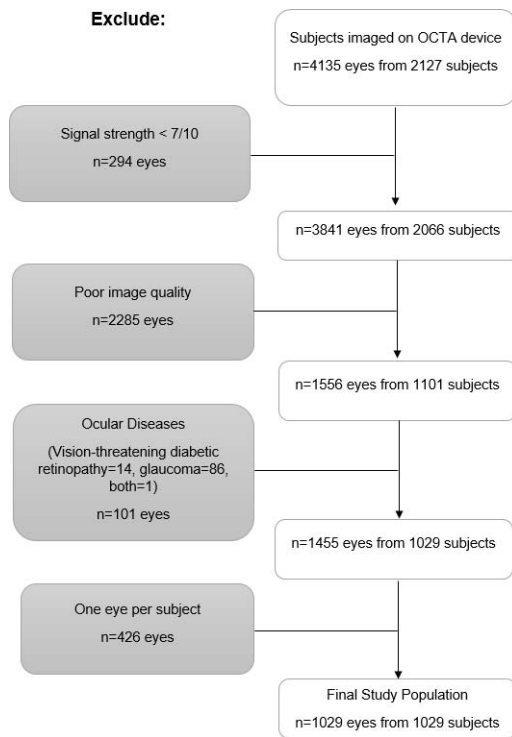


FIGURE 1. Flow chart of inclusion and exclusion criteria for imaged subjects.

RESULTS

Study Cohort

Of 2127 subjects, 4135 eyes received OCTA imaging. Two hundred ninety-four images were excluded due to SS less than 7 of 10. Because of poor image quality, 2285 images were excluded. Because of the presence of preexisting ocular disease, 101 images were excluded, of which 14 were due to vision-threatening diabetic retinopathy, 86 due to glaucoma, and 1 due to both (Fig. 1). The right eye scan was selected for the remaining subjects with imaging of both eyes, resulting in the further exclusion of 426 images. From 1029 subjects, 1029 eyes were analyzed. One hundred ninety-eight diabetic subjects were included in the analysis, 48 of whom had mild or moderate nonproliferative diabetic retinopathy. Excluded subjects had greater age (62 ± 11 , $P < 0.001$), greater AL (23.75 ± 1.16 , $P < 0.001$), poorer best-corrected visual acuity (24.71 ± 53.06 vs. 18.43 ± 5.33 , $P < 0.001$), and greater MD (-2.50 ± 4.75 , $P < 0.001$) than included subjects, with no significant difference in sex (63.7% vs. 64.1% female, $P = 0.792$), IOP (15.29 ± 3.61 vs. 15.19 ± 3.01 , $P = 0.184$), or CCT (532.59 ± 36.57 vs. 532.54 ± 34.98 , $P = 0.485$). Preliminary analysis revealed no significant association between image quality scores and peripapillary VD or ocular characteristics. Of the 1029 eyes analyzed, 369 (36%) were male and mean age was $58 (\pm 10)$ years.

Ocular Variables

Table 1 presents the mean and standard deviation for each of the ocular variables as well as age and SS,^{21,22} and the results of the univariate linear regression of each variable with VD as the dependent variable. In univariate analysis, the factors significantly correlated with lower peripapillary VD were older age ($\beta = -0.0017$ per year, $P < 0.001$), decreased SS ($\beta = 0.029$, $P <$

TABLE 1. Distribution of Ocular Variables and Univariate Linear Regressions With Peripapillary Vessel Density in Healthy African Americans

Variable	N	Mean*	Beta†	P Value†
VD	1029	0.346 ± 0.045	-	-
Age, y	1029	57.93 ± 9.89	-0.00170	<0.001
SS	1029	9.26 ± 0.84	0.0291	<0.001
IOP, mm Hg	1002	15.19 ± 3.01	-7.997×10^{-4}	0.090
CCT, μm	1001	532.5 ± 35.0	4.542×10^{-5}	0.264
AL, mm	1000	23.57 ± 0.97	-0.01439	<0.001
Mean RNFL thickness, μm	1021	91.97 ± 10.80	0.00270	<0.001
Visual field MD, dB	983	-1.11 ± 3.22	0.00177	<0.001

* Mean values are depicted as mean ± SD.

† Beta coefficients and P values calculated from univariate linear regression with vessel density.

0.001), longer AL ($\beta = -0.014$ per mm, $P < 0.001$), thinner mean RNFL thickness ($\beta = 0.0027$ per μm, $P < 0.001$), and more negative MD ($\beta = 0.0018$ per dB, $P < 0.001$). IOP ($P = 0.090$) and CCT ($P = 0.264$) were not significantly associated with VD.

Determinants of Peripapillary Vessel Density

The final multivariable model included AL and mean RNFL thickness, controlling for age and SS (Table 2).^{21,22} These four factors accounted for 69% of the variation in peripapillary VD (R^2). Thinner RNFL ($\beta = 0.0022$ per μm, $P < 0.001$, SRC = 0.543) and longer AL ($\beta = -0.0055$ per mm, $P < 0.001$, SRC = -0.117), were associated with lower peripapillary VD, respectively. Age ($\beta = -0.00088$ per year, $P < 0.001$, SRC = -0.196) and SS ($\beta = 0.021$, $P < 0.001$, SRC = 0.402) were also associated with lower peripapillary VD. The univariate association with peripapillary VD for MD was no longer significant in the multivariable model. Figure 2 presents the predicted values for peripapillary VD plotted against RNFL thickness in clustered 10-μm intervals with LOWESS regression lines and 95% confidence intervals. A reduction in peripapillary VD is seen with thinner RNFL. Figure 3 presents the same information for AL in 0.5-mm intervals, where a reduction in peripapillary VD is seen with increased AL.

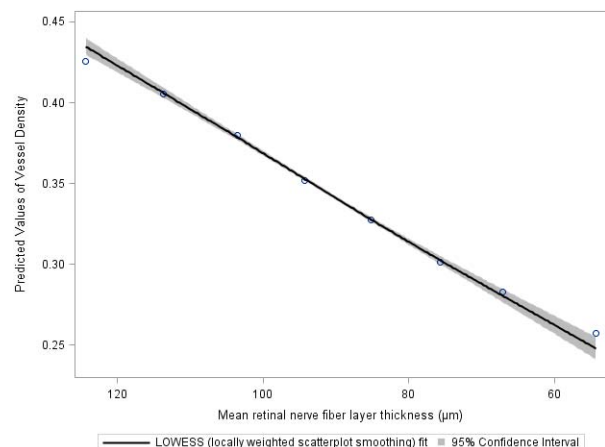


FIGURE 2. Predicted values of peripapillary VD versus mean RNFL thickness in healthy AA. The LOWESS plot is from a multivariable model controlling for age, SS, and AL. Plotted data points represent the average predicted VD values for each 10-μm thickness interval.

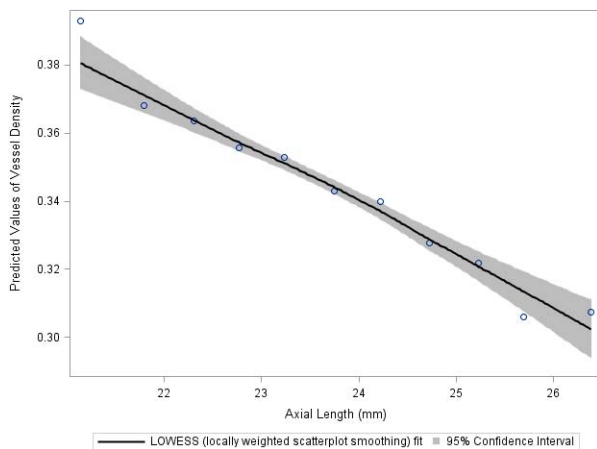


FIGURE 3. Predicted values of peripapillary VD versus AL in healthy AA. The LOWESS plot is from a multivariable model controlling for age, SS, and RNFL thickness. Plotted data points represent the average predicted VD values for each 0.5-mm AL interval.

DISCUSSION

To our knowledge, the African American Eye Disease Study is not only the largest but also the only population-based OCTA study to date. In this study of AA eyes without pre-existing disease, we evaluated the ocular determinants of peripapillary VD, a measure now being used as a marker for glaucoma disease. We found that, controlling for age and SS,^{21,22} longer AL and thinner RNFL predicted lower peripapillary VD. This population-based study underscores the importance of understanding the influence of ocular anatomical variation on peripapillary perfusion measurements and also offers a potential pathophysiologic explanation for axial elongation increasing risk for glaucoma.

Strong, positive associations between RNFL thickness and peripapillary VD have been previously reported,^{23,24} and support the idea that, in general, the quantity of perfused RPCs is proportional to the quantity of RNFL it is supplying.²⁵⁻²⁷ Prior histology and OCTA studies have demonstrated how RPCs run parallel to the RNFL and that their densities within a given eye are highly correlated.^{26,28} The current epidemiologic findings suggest that persons with greater RNFL thickness also have greater density of the RPCs. While we do not know if baseline peripapillary VD indicates future risk for glaucoma, there is some evidence that thin mean RNFL is a risk factor for the progression of visual field loss in glaucomatous eyes, as well as for the development of visual field deficits in glaucoma suspect eyes.²⁹⁻³³ There are currently no longitudinal data to determine whether peripapillary VD is a risk factor for functional progression of glaucoma. Given the strong, positive correlation between VD and RNFL thickness, this deserves further exploration in longitudinal studies.

While RNFL thickness has been established as a good clinical marker for glaucoma and its progression,³⁴ the strong relationship between RNFL thickness and peripapillary VD supports the newer findings that peripapillary VD is also a good clinical marker for glaucoma.^{19,20,35-37} However, what remains unclear is the temporal relationship between RNFL thinning and peripapillary VD reduction in glaucoma, or at least certain instances of glaucoma. It may be that thinning of the RNFL reduces metabolic demand for the RPCs. Alternatively, in at least some instances of glaucoma, vascular dysregulation and unstable ocular blood flow may lead to reperfusion injury, damage to the retinal ganglion cell axons, and resultant RNFL thinning.³⁸ Elucidating this temporal

TABLE 2. Multivariable Model* of Ocular Determinants of Radial Peripapillary Capillary Vessel Density in African Americans Without Pre-Existing Ocular Disease

Variable	Parameter	SRC†	P Value
	Estimates (95% CI)		
Mean RNFL thickness, μ m	0.0022 (0.0021, 0.0024)	0.542	<0.001
AL, mm	-0.0055 (-0.0070, -0.0035)	-0.118	<0.001

* Model controlled for SS and age. Model R^2 was 0.69.

† SRC, standardized regression coefficient.

relationship is essential to better understanding the pathogenesis of glaucomatous optic neuropathy.

Greater AL was the other ocular factor associated with lower peripapillary VD in our population, and this finding may provide insight into glaucoma pathogenesis. To date, the negative correlation between AL and peripapillary VD has only been demonstrated in small studies of young myopic patients in China.^{15,23,39} These findings are consistent with previous reports, which used fluorescein angiography to detect reduced retinal perfusion in myopic eyes.⁴⁰ Healthy myopic eyes have less retrobulbar blood flow associated with decreased peak flow velocity in the central retinal artery,⁴¹ smaller vessel diameter,^{42,43} and increased flow resistance.⁴⁴ A current hypothesis is that AL elongation causes these changes through mechanical stretching and thinning of the choroid, retina, and its vasculature.⁴⁵ Alternatively, the mechanical thinning of the choroid leading to reduced oxygen delivery to the retina may cause secondary retinal vasoconstriction and reduction in microcirculation.⁴⁵ A significant association between AL elongation and RNFL thinning has been shown in prior studies.^{46,47} However, our study demonstrates that despite the relationship between AL and RNFL thickness, there is an independent relationship between AL and VD, which is not explained by RNFL thinning. If the lower retinal perfusion in longer eyes were due to RNFL thinning alone, we would not expect AL to maintain its independent association with peripapillary VD in the multivariable model. One possible explanation is that axial elongation causes lower VD not only from RNFL thinning leading to a proportionally reduced need of RPCs, but also because there is a primary mechanical stretching of the retinal vasculature itself. In fact, it is possible this may indicate why greater AL is a risk factor for glaucoma. If longer eyes have lower peripapillary blood flow, they may be more susceptible to glaucomatous damage from IOP elevation or vascular factors. Further reduction in capillary blood flow within the lamina cribrosa and peripapillary area could diminish the diffusion of nutrients to adjacent astrocytes and retinal ganglion axons, leading to glaucomatous progression.⁴⁸⁻⁵¹ The findings of this study provide preliminary support for this idea, but longitudinal studies are needed to further explore this hypothesis.

An alternate explanation is that the association between axial elongation and lower peripapillary VD is a product of magnification error in the OCTA device.⁵² Longer eyes have larger scanning circle diameters, such that the area of vasculature that is quantified is actually larger than anticipated and the VD is lower as a result. However, magnification error would not account for the reduced ocular and retrobulbar blood flow observed in myopia in other studies, as they used modalities, such as laser doppler flowmetry and color doppler imaging, which would not be susceptible to magnification error.⁴¹⁻⁴⁵

Notably, we observed in our population that increasingly negative MD was significantly associated with lower peripapillary VD in univariate regressions but was no longer a significant association in the multivariable model. We did not observe R^2 values greater than 0.5 for MD with any other variable in the univariate regressions, nor did we observe a

significant value for the respective variance inflation factor (VIF) when included in the multivariable model, indicating that MD is not collinear with any other variable. Our data therefore suggest that any relationship between MD and peripapillary VD is better explained by the other factors in the final model. It is also possible that an independent contribution of MD to peripapillary VD could potentially be identified with a larger study population.

Our study controlled for age and SS in all analyses, as suggested by prior findings,^{21,22} and the significant association of these factors with peripapillary VD in our study supported the importance of doing so. Significant reduction in peripapillary VD has been reported in healthy eyes above age 60²¹ and a linear relationship between age and VD has also been reported in the macula in younger populations.¹³ We found that increasing age was associated with reduction of peripapillary VD, and age was a more significant predictor of peripapillary VD than was AL in our model. Further, we found that reduction in SS is associated with lower peripapillary VD. Most OCTA studies use a SS of six or seven as minimal inclusion criteria, as the manufacturer recommends SS of six or more to indicate adequate quality.⁵³ However, Lim et al.²² reported significant differences in macular VD when comparing images with SS from seven to nine, with no significant difference between SS nine and ten. Decreased SS causes attenuation of all signals, such that the device is less likely to detect blood flow signals in small vessels against the background noise threshold.⁵⁴ Our data support the recent findings that VD measurement is affected by SS even when using seven as the minimum inclusion criteria. Consequently, SS should be taken into account when analyzing OCTA images, especially when comparing images of differing SS. Further studies should be performed to determine the optimal minimum SS inclusion criteria for analysis in the peripapillary region.

An important limitation of our study is that we had to exclude a significant number of participants due to poor image quality. This was done to limit the variability in VD quantification from outside variables, such as artifacts, segmentation errors, and media opacities, but this may have led to some bias in our results. Second, our study consisted of participants who identified themselves as AA, but ancestry markers were not assessed. Future studies using ancestry markers would allow for a more well-defined study population.

In summary, this study demonstrates that thin RNFL and increased AL are independent ocular anatomic predictors of lower peripapillary VD in healthy AA eyes. Ocular anatomic variation should be considered when assessing peripapillary VD, and future research should further explore whether axial elongation increases risk for glaucoma by affecting the microcirculation supplying retinal ganglion axons.

Acknowledgments

Presented at the annual meeting of the Association for Research in Vision and Ophthalmology, Vancouver, British Columbia, Canada, April 28–May 2, 2019.

Supported by grants from the National Institutes of Health (Grants K23EY027855-01, GMR; U10EY023575, RV; K08EY027006, AHK; Bethesda, MD, USA), American Glaucoma Society Young Clinician Scientist Grant (GMR; San Francisco, CA, USA), unrestricted grant to the USC Department of Ophthalmology from Research to Prevent Blindness (New York, NY, USA), and research device from Carl Zeiss Meditec, Inc. (Dublin, CA, USA).

Disclosure: **A.J. Nelson**, None; **R. Chang**, None; **V. LeTran**, None; **B. Vu**, None; **B. Burkemper**, None; **Z. Chu**, None; **A. Fard**, Carl Zeiss Meditec (E); **A. Kashani**, Carl Zeiss Meditec (C); **B. Xu**, None; **R. Wang**, Carl Zeiss Meditec (C), P; **R. Varma**, None; **G.M. Richter**, None

References

1. Tielsch JM, Sommer A, Katz J, Royall RM, Quigley HA, Javitt J. Racial variations in the prevalence of primary open-angle glaucoma: the Baltimore Eye Survey. *JAMA J Am Med Assoc.* 1991;226:369–374.
2. Sommer A, Tielsch JM, Katz J, et al. Racial differences in the cause-specific prevalence of blindness in East Baltimore. *N Engl J Med.* 1991;325:1412–1417.
3. Siesky B, Harris A, Racette L, et al. Differences in ocular blood flow in glaucoma between patients of African and European descent. *J Glaucoma.* 2015;24:117–121.
4. Sample PA, Girkin CA, Zangwill LM, et al. The African Descent and Glaucoma Evaluation Study (ADAGES): design and baseline data. *Arch Ophthalmol.* 2019;127:1136–1145.
5. Racette L, Wilson MR, Zangwill LM, Weinreb RN, Sample PA. Primary open-angle glaucoma in blacks: a review. *Surv Ophthalmol.* 2003;48:295–313.
6. Girkin CA, Sample PA, Liebmann JM, et al. African Descent and Glaucoma Evaluation Study (ADAGES): II. Ancestry difference in optic disc, retinal nerve fiber layer, and macular structure in healthy subjects. *Arch Ophthalmol.* 2011;128:541–550.
7. Lee RY, Kao AA, Kasuga T, et al. Ethnic variation in optic disc size by fundus photography. *Curr Eye Res.* 2013;38:1142–1147.
8. Skaat A, De Moraes CG, Bowd C, et al. African Descent and Glaucoma Evaluation Study (ADAGES) racial differences in optic disc hemorrhage and beta-zone parapapillary atrophy. *Ophthalmology.* 2016;123:1476–1483.
9. Venugopal JP, Rao HL, Weinreb RN, et al. Repeatability of vessel density measurements of optical coherence tomography angiography in normal and glaucoma eyes. *Br J Ophthalmol.* 2018;102:352–357.
10. Rao HL, Pradhan ZS, Weinreb RN, et al. Optical coherence tomography angiography vessel density measurements in eyes with primary open-angle glaucoma and disc hemorrhage. *J Glaucoma.* 2017;26:888–895.
11. Rao HL, Pradhan ZS, Weinreb RN, et al. Relationship of optic nerve structure and function to peripapillary vessel density measurements of optical coherence tomography angiography in glaucoma. *J Glaucoma.* 2017;26:548–554.
12. Chen CL, Zhang A, Bojikian KD, et al. Peripapillary retinal nerve fiber layer vascular microcirculation in glaucoma using optical coherence tomography-based microangiography. *Invest Ophthalmol Vis Sci.* 2016;57:OCT475–OCT485.
13. Yu J, Jiang C, Wang X, et al. Macular perfusion in healthy chinese: an optical coherence tomography angiogram study. *Invest Ophthalmol Vis Sci.* 2015;56:3212–3217.
14. Rao HL, Pradhan ZS, Weinreb RN, et al. Determinants of peripapillary and macular vessel densities measured by optical coherence tomography angiography in normal eyes. *J Glaucoma.* 2017;26:491–497.
15. Wang X, Kong X, Jiang C, Li M, Yu J, Sun X. Is the peripapillary retinal perfusion related to myopia in healthy eyes? A prospective comparative study. *BMJ Open.* 2016;6:e010791.
16. McKean-Cowdin R, Fairbrother-Crisp A, Torres M, et al. The African American Eye Disease Study: design and methods. *Ophthalmic Epidemiol.* 2018;25:306–314.
17. Chu Z, Lin J, Gao C, et al. Quantitative assessment of the retinal microvasculature using optical coherence tomography angiography. *J Biomed Opt.* 2016;21:066008.
18. Cleveland W, Grosse E. Computational methods for local regression. *Stat Comput.* 1991;1:47–62.
19. Richter GM, Chang R, Situ B, et al. Diagnostic performance of macular versus peripapillary vessel parameters by optical coherence tomography angiography for glaucoma. *Trans Vis Sci Tech.* 2018;7(6):21.

20. Richter GM, Sylvester B, Chu Z, et al. Peripapillary microvasculature in the retinal nerve fiber layer in glaucoma by optical coherence tomography angiography: focal structural and functional correlations and diagnostic performance. *Clin Ophthalmol*. 2018;12:2285–2296.
21. Pinhas A, Linderman R, Mo S, et al. A method for age-matched OCT angiography deviation mapping in the assessment of disease-related changes to the radial peripapillary capillaries. *PLoS One*. 2018;13:e0197062.
22. Lim H Bin, Kim YW, Kim JM, Jo YJ, Kim JY. The importance of signal strength in quantitative assessment of retinal vessel density using optical coherence tomography angiography. *Sci Rep*. 2018;8:12897.
23. Li Y, Miara H, Ouyang P, Jiang B. The comparison of regional RNFL and fundus vasculature by OCTA in Chinese myopia population. *J Ophthalmol*. 2018;2018:3490962.
24. She X, Guo J, Liu X, et al. Reliability of vessel density measurements in the peripapillary retina and correlation with retinal nerve fiber layer thickness in healthy subjects using optical coherence tomography angiography. *Ophthalmologica*. 2018;240:183–190.
25. Yu PK, Cringle SJ, Yu DY. Correlation between the radial peripapillary capillaries and the retinal nerve fibre layer in the normal human retina. *Exp Eye Res*. 2014;129:83–92.
26. Scoles D, Gray DC, Hunter JJ, et al. In-vivo imaging of retinal nerve fiber layer vasculature: imaging histology comparison. *BMC Ophthalmol*. 2009;9:9.
27. Yu J, Gu R, Zong Y, et al. Relationship between retinal perfusion and retinal thickness in healthy subjects: an optical coherence tomography angiography study. *Invest Ophthalmol Vis Sci*. 2016;57:OCT204–OCT210.
28. Mansoori T, Sivaswamy J, Gamalapati JS, Balakrishna N. Topography and correlation of radial peripapillary capillary density network with retinal nerve fibre layer thickness. *Int Ophthalmol*. 2018;38:967–974.
29. Sehi M, Bhardwaj N, Chung YS, Greenfield DS. Evaluation of baseline structural factors for predicting glaucomatous visual-field progression using optical coherence tomography, scanning laser polarimetry and confocal scanning laser ophthalmoscopy. *Eye*. 2012;26:1527–1535.
30. Zhang X, Dastiridou A, Francis BA, et al. Baseline Fourier-domain optical coherence tomography structural risk factors for visual field progression in the Advanced Imaging for Glaucoma Study. *Am J Ophthalmol*. 2016;172:94–103.
31. Mohammadi K, Bowd C, Weinreb RN, Medeiros FA, Sample PA, Zangwill LM. Retinal nerve fiber layer thickness measurements with scanning laser polarimetry predict glaucomatous visual field loss. *Am J Ophthalmol*. 2004;138:592–601.
32. Lim JH, Park JS, Lee SY, Hong YJ. Incidence of and risk factors for glaucoma in lost-to-follow-up normal-tension glaucoma suspect patients. *BMC Ophthalmol*. 2016;16:62.
33. Colombo L, Bertuzzi F, Rulli E, Miglior S. Correlations between the individual risk for glaucoma and RNFL and optic disc morphometrical evaluations in ocular hypertensive patients. *J Glaucoma*. 2016;25:e455–e462.
34. Lin SC, Singh K, Jampel HD, et al. Optic nerve head and retinal nerve fiber layer analysis. A report by the American Academy of Ophthalmology. *Ophthalmology*. 2007;114:1937–1949.
35. Yarmohammadi A, Zangwill LM, Diniz-Filho A, et al. Optical coherence tomography angiography vessel density in healthy, glaucoma suspect, and glaucoma eyes. *Invest Ophthalmol Vis Sci*. 2016;57:OCT451–OCT459.
36. Mammo Z, Heisler M, Balaratnasingam C, et al. Quantitative optical coherence tomography angiography of radial peripapillary capillaries in glaucoma, glaucoma suspect, and normal eyes. *Am J Ophthalmol*. 2016;170:41–49.
37. Yarmohammadi A, Zangwill LM, Diniz-Filho A, et al. Relationship between optical coherence tomography angiography vessel density and severity of visual field loss in glaucoma. *Ophthalmology*. 2016;123:2498–2508.
38. Fan N, Wang P, Tang L, Liu X. Ocular blood flow and normal tension glaucoma. *Biomed Res Int*. 2015;2015:308505.
39. Mo J, Duan A, Chan S, Wang X, Wei W. Vascular flow density in pathological myopia: an optical coherence tomography angiography study. *BMJ Open*. 2017;7:e013571.
40. Avetisov E, Savitskaya N. Some features of optical microcirculation in myopia. *Ann Ophthalmol*. 1977;9:1261–1264.
41. Benavente-Pérez A, Hosking SL, Logan NS, Broadway DC. Ocular blood flow measurements in healthy human myopic eyes. *Graefes Arch Clin Exp Ophthalmol*. 2010;248:1587–1594.
42. La Spina C, Corvi F, Bandello F, Querques G. Static characteristics and dynamic functionality of retinal vessels in longer eyes with or without pathologic myopia. *Graefes Arch Clin Exp Ophthalmol*. 2016;254:827–834.
43. Patton N, Maini R, MacGillivray T, Aslam TM, Deary IJ, Dhillon B. Effect of axial length on retinal vascular network geometry. *Am J Ophthalmol*. 2005;140:648–653.
44. Dimitrova G, Tamaki Y, Kato S, Nagahara M. Retro-bulbar circulation in myopic patients with or without myopic choroidal neovascularisation. *Br J Ophthalmol*. 2002;86:771–773.
45. Grudzińska E, Modrzejewska M. Modern diagnostic techniques for the assessment of ocular blood flow in myopia: current state of knowledge. *J Ophthalmol*. 2018;2018:4694789.
46. Leung CKS, Mohamed S, Leung KS, et al. Retinal nerve fiber layer measurements in myopia: an optical coherence tomography study. *Invest Ophthalmol Vis Sci*. 2006;47:5171–5176.
47. Budenz DL, Anderson DR, Varma R, et al. Determinants of normal retinal nerve fiber layer thickness measured by stratus OCT. *Ophthalmology*. 2007;114:1046–1052.
48. Satilmis M, Orgül S, Doubler B, Flammer J. Rate of progression of glaucoma correlates with retrobulbar circulation and intraocular pressure. *Am J Ophthalmol*. 2003;135:664–669.
49. Quigley HA, Addicks EM, Green R, Maumenee AE. Optic nerve damage in human glaucoma II. The site of injury and susceptibility to damage. *Arch Ophthalmol*. 1981;99:635–649.
50. Downs JC. Optic nerve head biomechanics in aging and disease. *Exp Eye Res*. 2015;133:19–29.
51. Burgoyne CF. A biomechanical paradigm for axonal insult within the optic nerve head in aging and glaucoma. *Exp Eye Res*. 2011;93:120–132.
52. Huang D, Chopra V, Lu ATH, Tan O, Francis B, Varma R. Does optic nerve head size variation affect circumpapillary retinal nerve fiber layer thickness measurement by optical coherence tomography? *Invest Ophthalmol Vis Sci*. 2012;53:4990–4997.
53. Carl Zeiss Meditec, Inc. *Cirrus HD-OCT User Manual*. 4th ed. Dublin CA: Carl Zeiss Meditec; 2008.
54. Spaide RF, Fujimoto JG, Waheed NK, Sadda SR, Staurengi G. Optical coherence tomography angiography. *Prog Retin Eye Res*. 2018;64:1–55.

APPENDIX

Members of the African American Eye Disease Study Group:

Roberta McKean-Cowdin, Mina Torres, Alicia Fairbrother-Crisp, Farzana Choudhury, Xuejuan Jiang, Bruce Burkemper, Tengiz Adamashvili, Carlos Lastra, Elizabeth Corona, YuPing Wang, Jacqueline Douglass, Jaimie Barrera, and Judith Linton