

Position of Central Vascular Trunk and Shape of Optic Nerve Head in Newborns

Martha Kim,¹ So Young Kim,² Kyoung Min Lee,^{3,4} Sohee Oh,⁵ and Seok Hwan Kim^{3,4}

¹Department of Ophthalmology, Dongguk University Ilsan Hospital, Goyang, Korea

²Department of Ophthalmology, Soonchunhyang University Cheonan Hospital, Cheonan, Korea

³Department of Ophthalmology, Seoul National University College of Medicine, Seoul, Korea

⁴Department of Ophthalmology, Seoul National University Boramae Hospital, Seoul, Korea

⁵Department of Biostatistics, Seoul National University Boramae Hospital, Seoul, Korea

Correspondence: Seok Hwan Kim, Department of Ophthalmology, Seoul Metropolitan Government Seoul National University Boramae Medical Center, 39 Boramae Road, Dongjak-gu 156-707, Seoul, Korea; xcski@hanmail.net.

MK and SYK contributed equally to the work presented here and should therefore be regarded as equivalent authors.

Submitted: April 17, 2019

Accepted: July 6, 2019

Citation: Kim M, Kim SY, Lee KM, Oh S, Kim SH. Position of central vascular trunk and shape of optic nerve head in newborns. *Invest Ophthalmol Vis Sci*. 2019;60:3381-3387. <https://doi.org/10.1167/iovs.19-27363>

PURPOSE. To investigate the baseline position of the central vascular trunk (CVT) and the characteristics of the optic nerve head (ONH) in newborns.

METHODS. CVT position was evaluated based on fundus images obtained from newborns who had undergone eye-screening examinations. It was then graded according to the optic disc area as follows: grade 1, within central 4%; grade 2, within central 9%; grade 3, within central 16%; grade 4, within central 25%; grade 5, outside central 25% of optic disc area. The direction of the CVT position was determined in cases of grade 2 or more as superior, inferior, nasal, and temporal, relative to the optic disc center. The ovality index and the vertical cup-to-disc ratio were determined as well.

RESULTS. In 1000 fundus images from 1000 newborns, 87.1% showed grade 1 (95% confidence interval 84.7-88.8), and 10.7% showed grade 2. The most common CVT direction was central (87.1%, grade 1), followed by nasal (11.0%) and inferior (1.2%). The ovality index was 1.28 ± 0.09 (range, 1.01-1.61). The ONH shape was vertically oval and highly uniform. The average vertical cup-to-disc ratio was 0.29 ± 0.13 (range, 0.00-0.67).

CONCLUSIONS. The CVT of newborns was located in the central area of the ONH in most cases. The shape of the optic disc was vertically oval, and very similar among the newborns. Considering the high variability of ONH morphology and the diverse location of the CVT in adults, our result suggests that the shape of the ONH and the CVT position might change during eyeball growth.

Keywords: optic nerve head shape, central vascular trunk position, newborn, fundus photography

The morphology of the optic nerve head (ONH) is highly variable among individuals.¹⁻³ The ONH area shows an interindividual variability of approximately 1:7, and the ovality index (defined as the ratio of the largest diameter to the smallest diameter of the ONH), which is one of the morphologic parameters of the ONH, shows a variability of about 1:2 in the general population.⁴ Most studies on the ONH have been conducted with adult populations^{2,3,5,6}; there are only a few such studies dealing with infants.⁷⁻¹¹ Previous work has revealed that the optic nerve is incompletely developed at birth,^{12,13} and that it undergoes rapid development in infancy and early childhood.¹⁴ However, it is not certain whether the morphology of the ONH remains stable or changes during ONH development and eyeball growth.

Recently, our group reported that the shape of the ONH changes and that the central vascular trunk (CVT) of the ONH moves with myopic axial elongation in childhood.^{15,16} Because the CVT is embedded in the dense connective tissue of the lamina cribrosa (LC), positional change (i.e., shift) of the CVT could be a clue indicating the extent and the direction of underlying LC shift.^{16,17} We identified LC defect in the area opposite to the eccentric location of the CVT in the myopic eyes of healthy children, suggesting that changes in the CVT

position and ONH morphology could be related to the risk of later developing glaucoma in myopia.¹⁶ Subsequently, we showed that the position of the CVT relative to the center of the Bruch's membrane opening (BMO) was related to the initial damage location of myopic normal-tension glaucoma,¹⁷ based on the assumption that the CVT was originally located at the center of the ONH.

If structural change of the ONH during infancy or childhood is linked to the long-term risk of developing glaucoma, the evaluation of baseline morphologic characteristics of the ONH in newborns would be important in order to deduce changes of the ONH and deep structures, such as the LC, during eyeball growth. Therefore, the purpose of the current study was to investigate the position of the CVT and the morphologic characteristics of the ONH in newborns based on fundus photographs.

METHODS

Digital fundus images of the posterior polar retina were consecutively obtained from infant eye-screening examinations performed using the Retcam wide-field digital imaging system (Natus Medical Inc.; Pleasanton, CA, USA) on healthy newborns



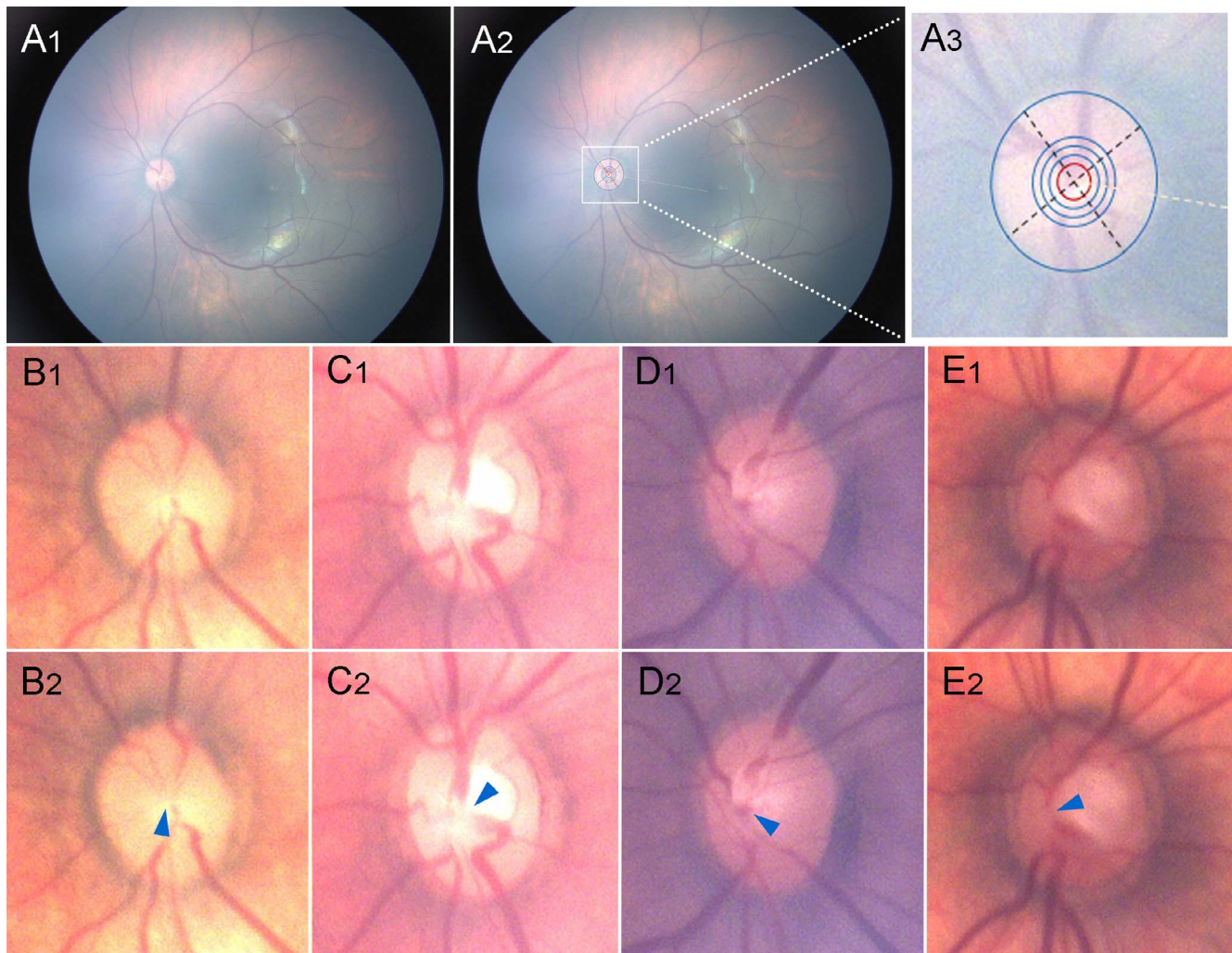


FIGURE 1. Measurement of central vascular trunk location from center. (A₁) Fundus photography obtained by RetCam. (A₂) Same fundus photography with overlapped measuring tool. (A₃) Magnified view of measuring tool. The extent of central vascular trunk location as measured by reference circles as follows: (1) grade 1 within central 4% (red circle), (2) grade 2 within central 9%, (3) grade 3 within central 16%, and (4) grade 4 within central 25% (blue circles). The direction of the central vascular trunk location was determined according to four quadrants. For this purpose, the temporal quadrant was aligned along the foveo-disc axis (gray dashed line). (B-E) Representative images. Central vascular trunk location of grade 1 (B), grade 2 (C), grade 3 (D), and grade 4 (E). Positions of central vascular trunks are demarcated as arrowheads (B₂-E₂).

within a week of birth in 28 local obstetrics and gynecology centers between July and September 2018. The infants' pupils were dilated with 1% tropicamide eye drops. Before the examination, topical anesthesia was instilled and an eyelid speculum was applied. The 130° lens of a digital fundus camera was used. One fundus photograph was acquired per each eye of each infant, as centered on the posterior pole, by a well-trained nurse of each center between 1 and 7 days after birth. All of the fundus images were sent to the Reading Center of Soonchunhyang University Cheonan Hospital, where they were screened by one pediatric ophthalmologist (SYK). The images contained no patient-identifiable information except sex, gestational age, and birth weight. Eyes with congenital abnormalities, retinal hemorrhages, or intraocular inflammation were excluded. Images of poor quality also were excluded. If images from both eyes of an infant were eligible, one eye was randomly selected. This study was performed in accordance with the tenets of the Declaration of Helsinki, and the study protocol was approved by the Soonchunhyang University Cheonan Hospital institutional review board.

Fundus images were independently assessed by two independent observers (MK and KML) to determine the position and direction of the CVT using a measuring tool (Fig. 1). The outermost measurement circle was fit to the disc margin, and the center of the circle was set as the 'center' of the disc. The position of the CVT was defined as its area of location in the optic disc (grade 1, within central 4% of optic disc area; grade 2, within central 9%; grade 3, within central 16%; grade 4, within central 25%; grade 5, outside of central 25%). The direction of CVT location was determined in cases of grade 2 or more as superior, inferior, nasal, or temporal relative to the center of the optic disc. The reference line was set as the line connecting the fovea and the ONH center, and each direction was a quadrant measuring 90°. In cases of disagreement between the two observers, a third observer (SHK) was consulted to achieve consensus.

The disc diameter and cup diameter were measured to determine the cup-to-disc ratio and ovality index using ImageJ software (<http://imagej.nih.gov/ij/>; provided in the public domain by the National Institutes of Health, Bethesda, MD, USA). The vertical and horizontal cup-to-disc ratios were

TABLE 1. Baseline Characteristics of Subjects

	All	Preterm Birth (<38 wk)	Full-Term Birth (≥38 wk)	P Value
N	1000	117	883	
Sex (male/female)	537/463	75/42	462/421	0.018
Gestational age, wk	39.0 ± 1.2	36.8 ± 0.7	39.3 ± 0.9	<0.001
Birth weight, g	3217.0 ± 450.4	2843.9 ± 474.6	3266.4 ± 423.4	<0.001
Ovality index	1.28 ± 0.09	1.30 ± 0.10	1.28 ± 0.09	0.004
vCD ratio	0.29 ± 0.13	0.29 ± 0.12	0.29 ± 0.13	0.717
hCD ratio	0.31 ± 0.14	0.30 ± 0.15	0.31 ± 0.13	0.900
Hypopigmentation, %	48.8	59.8	47.3	0.039
Crescent	20.6	24.8	20.0	0.183
Circular	28.2	35.0	27.3	0.075

hCD ratio, horizontal cup-to-disc ratio; vCD ratio, vertical cup-to-disc ratio.

determined as the ratio between the cup diameter and the disc diameter. The ovality index was defined as the ratio between the largest and smallest disc diameters. All of the measurements were performed independently by two masked observers (MK and KML), and the average values were used in the analysis.

The presence and the type of hypopigmented peripapillary lesion were evaluated by two masked observers (MK and KML). The circular type of hypopigmented lesion was defined as a 360° hypopigmented lesion around the optic disc, and the crescent type was defined as a less than 360° hypopigmented lesion. In cases of disagreement between the two observers (4 cases), a third observer (SHK) was consulted to achieve consensus.

Data Analysis

The normality of the distribution of the continuous variables was assessed by the Kolmogorov-Smirnov test. To obtain interobserver agreements for the located area of the CVT in the optic disc (grade 1~5) and the direction of the CVT position (superior, temporal, inferior, nasal), we calculated the weighted and unweighted kappa statistics, respectively. The interobserver reproducibility for the measurements of the continuous variables was assessed by calculation of the intraclass correlation coefficient (ICC) and coefficient of variation (CV) for variables with normal distribution, as well as by calculation of the concordance correlation coefficient (CCC) and CV for variables without normal distribution. Comparisons between two groups, full-term newborns and preterm newborns, were performed by X² test and independent t-test. Bootstrapping with 1000 replicates was used to obtain 95% bias-corrected accelerated confidence intervals (BCa CIs) for analysis of the grade of the CVT position. Differences of continuous variables with normal distribution were compared using the one-way

ANOVA test and the post hoc least significant difference test. Differences of continuous variables without normal distribution were compared with the Kruskal-Wallis test and the post hoc Dunn test with Bonferroni correction. Statistical analyses were performed with commercially available software (Stata version 14.0; StataCorp, College Station, TX, USA) and R statistical package version 3.4.3 (available in the public domain at <http://www.R-project.org>). A value of P < 0.05 was considered to represent statistical significance.

RESULTS

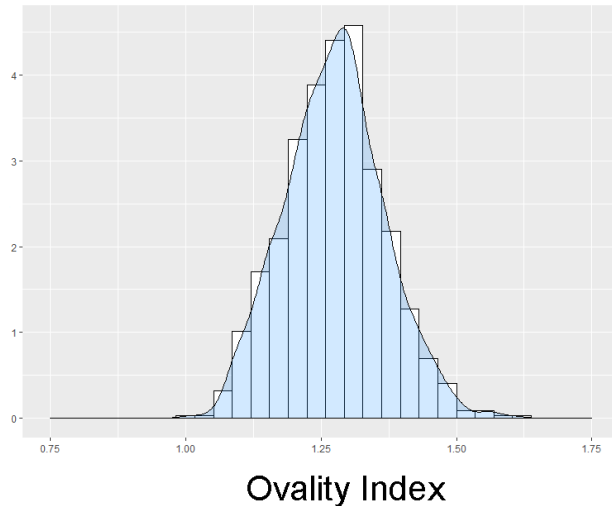
Initially, 1415 eyes of 1415 newborns were enrolled. Among these eyes, eight (0.6%) were excluded due to poor image quality, 398 (28.1%) due to retinal hemorrhage, and nine (0.6%) due to media opacity, optic disc abnormalities, or other retinal abnormalities. Finally, 1000 eyes of 1000 newborns were evaluated. Of the newborns, 537 were boys and 463 were girls. The mean gestational age was 39.0 ± 1.2 weeks, and the mean birth weight was 3217.0 ± 450.4 g. The mean day of image acquisition was 1.7 ± 1.2 (range, 1-7) after birth. Of the subjects, 48.8% showed hypopigmentations; 20.6% were crescent-shaped and 28.2% were circular (Supplementary Fig. S1). Subgroup analysis was performed by dividing the subjects into two groups according to gestational age, preterm birth (<38 weeks) and full-term birth (≥38 weeks). The ovality index was significantly larger in the preterm birth subjects than in the full-term birth subjects (P = 0.004). Also, the hypopigmentation was significantly more common in the preterm birth subjects than in the full-term birth subjects (P = 0.039, Table 1).

Table 2 shows the positional area and direction of CVT in the newborn ONH. The majority of newborns showed a centrally located CVT, 87.1% (BCa 95%CI, 84.7-88.8) were

TABLE 2. The Central Vascular Trunk Location Grade and Direction of Optic Nerve Head in Newborns

	N	%	Bias	Percentile 95%CI	BCa 95%CI
CVT Grade					
Grade 1	841	87.1	0.000	(85.0, 89.0)	(84.7, 88.8)
Grade 2	103	10.7	0.000	(8.7, 12.7)	(8.8, 12.7)
Grade 3	18	1.9	0.000	(1.1, 2.8)	(1.1, 2.8)
Grade 4	4	0.4	0.000	(0.1, 0.8)	(0.1, 0.8)
CVT direction					
Central	841	87.1	0.000	(85.0, 89.0)	(84.7, 88.8)
Nasal	106	11.0	0.000	(9.1, 13.0)	(9.2, 13.3)
Inferior	12	1.2	0.000	(0.6, 2.0)	(0.6, 2.0)
Temporal	6	0.6	0.000	(0.2, 1.1)	(0.2, 1.1)
Superior	1	0.1	0.000	(0.0, 0.3)	(0.0, 0.3)

Density



Density

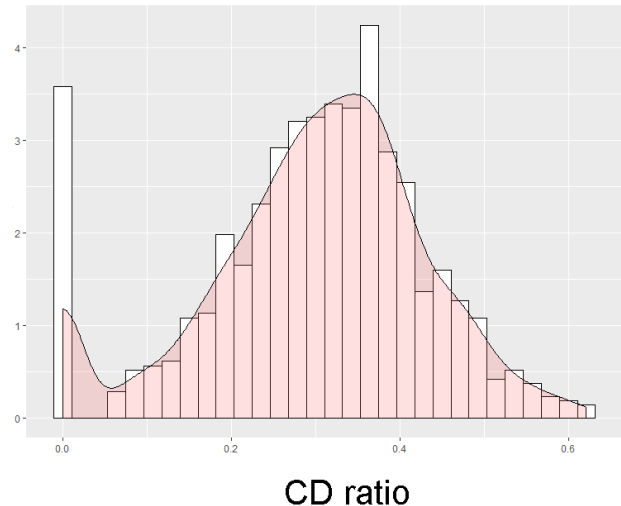


FIGURE 2. Ovality index and vertical cup-to-disc ratio distributions in newborns.

within the central 4% of the optic disc area (grade 1) and 97.7% were within the central 9% (grades 1 and 2). The most common direction of CVT location was central (87.1%, grade 1), followed by nasal (11.0%) and inferior (1.2%).

The shape of the ONH was vertically oval in almost all cases. The ovality index was 1.28 ± 0.09 (range, 1.01–1.61); 89.5% of the ONHs were within the 1.10 to 1.40 ovality index range (Fig. 2), indicating that the shape was highly uniform (Fig. 3).

The average horizontal and vertical cup-to-disc ratios were 0.31 ± 0.14 and 0.29 ± 0.13 , respectively. The vertical cup-to-disc ratio was significantly increased as the grade describing CVT location increased ($P < 0.001$), whereas the ovality index was not significantly related ($P = 0.813$) (Table 3).

The interobserver agreement on the CVT-location grading was excellent (weighted kappa statistic = 0.936 [0.868–1.000]), and the interobserver agreement on the CVT direction was good (kappa statistic = 0.846 [0.720–0.972]). The Kolmogorov-Smirnov test revealed that the normal distribution prevailed for the ovality index, whereas it did not for the vertical cup-to-disc ratio. The measurements of the ovality index and vertical cup-to-disc ratio showed good (ICC = 0.888 [0.839–0.924], CV = 2.9%) and moderate (CCC = 0.639 [0.550–0.713], CV = 23.5%) interobserver reproducibility, respectively.

DISCUSSION

In this study, we confirmed that the position of the CVT of the ONH was mostly in the central area in the newborns. We also

showed that the shape of the ONH was generally vertically oval and uniform. This finding supports our previous hypothesis that at birth, the CVT is located mostly in the center of the ONH.^{16,17} Additionally, these results imply that the shape of the ONH and location of the CVT can change over the course of eyeball growth after birth.

The mean ovality index of the neonatal ONH was 1.28, which is consistent with previous studies.^{8,9} We also found that ONH morphology was very similar among the newborns. Many previous studies conducted in Asia demonstrated different ovality indices for different age groups.^{6,18–20} Guo et al.²⁰ showed that the ovality index of Chinese children was 1.18 at the mean age of 11.4 ± 0.5 years (range, 10–13 years). Another study conducted in Beijing reported that the ovality index of adults was 1.08.¹⁹ This result was similar to those of other studies conducted with Singaporean Chinese adults (ovality index 1.1)¹⁸ and Japanese adults (ovality index 1.12).⁶ Taking these results together, we could cautiously deduce that the ovality index is decreased during infancy and early childhood. The larger ovality index of the preterm birth subjects relative to that of the full-term birth subjects in our study also supports this hypothesis.

Rimmer et al.¹² reported that the optic disc and retrobulbar optic nerve showed approximately 75% of growth at birth and 95% before the age of 1 year, based on 95 patients on whom autopsies were performed. Recently, Patel et al.¹⁴ also demonstrated a rapid increase of disc diameter between birth and 2 years using handheld spectral-domain optical coherence tomography (OCT) in a cross-sectional study. However, there

TABLE 3. Relationships Among the Central Vascular Trunk Location Grade, Vertical Cup-to-Disc Ratio and Ovality Index

	vCD Ratio				Ovality Index		
	N	Mean ± SD	P Value*	Post Hoc†	N	Mean ± SD	P Value
Grade 1	836	0.28 ± 0.13	<0.001		836	1.28 ± 0.09	0.813
Grade 2	99	0.31 ± 0.13			99	1.27 ± 0.08	
Grade 3	18	0.38 ± 0.09			18	1.30 ± 0.06	
Grade 4	4	0.50 ± 0.12			4	1.28 ± 0.09	
	957				957		

Grade 1 = Grade 2 < Grade 3; Grade 2 = Grade 3; Grade 3 = Grade 4. SD, standard deviation.

* Kruskal-Wallis test.

† Post hoc Dunn test with Bonferroni correction.



FIGURE 3. Randomly selected ONH images of 180 cases. The optic nerve head shape was vertically oval and highly uniform. Most cases had a centrally located central vascular trunk.

have been few studies demonstrating longitudinal changes of the ONH during ONH development and eyeball growth in infancy.¹¹ Considering the high variability of ONH morphology in adults,⁴ the uniform ONH shape in the newborns of our study suggested that not only does the size of the ONH increase during eyeball growth, but also, its shape dramatically changes.

According to an embryologic study, LC development starts in the fetus' fifth month, and by the eighth month, the LC morphology is similar to that of adults.²¹ However, if the size and the shape of the ONH changes during eyeball growth in infancy and early childhood, the underlying LC might change further according to ONH and optic nerve development. Taking into account the facts that the LC is a three-dimensional cylindrical structure consisting of dense connective tissue and that the CVT is embedded in the LC, CVT position might represent the relative alignment of the anterior circular portion of the LC with the BMO. In the present study, the CVT was located mostly in the center of the optic disc in newborns. Considering the high variability of CVT position in the adult ONH,¹⁷ the LC might expand and/or shift during eyeball growth and scleral expansion. This might be related to the development of an LC area that is vulnerable to glaucoma. Our previous study found that positional change of the LC relative

to the BMO is related to the development of LC defects in young myopic eyes, which may be related to glaucoma risk.^{16,17} Another study also showed that the eccentric location of the LC relative to the BMO center, as estimated from the position of the CVT, is related to the initial damage area of glaucoma.¹⁷

In our previous Boramae Myopia Cohort Study, we found that BMO diameter was relatively stable for 2-years follow-up from 9 years of mean age, whereas the deep structures of the ONH including the LC were shifted nasally and the peripapillary structures were changed dramatically during axial elongation due to myopic scleral expansion.¹⁵ Patel et al.¹⁴ also showed that BMO diameter increased rapidly during the first 2 years from birth and then relatively stabilized. Therefore, we cautiously speculate that BMO expansion may occur during infancy and early childhood along with scleral expansion, whereas scleral expansion alone may occur later, even during late childhood and early adolescence; the former would be accompanied mainly by emmetropization and the latter by myopization. Our speculation is supported by the schematic illustration in Figure 4. Further studies focusing on infancy and early childhood would be warranted.

Peripapillary hypopigmentation was the most common finding in the newborns that we studied. Almost half of the

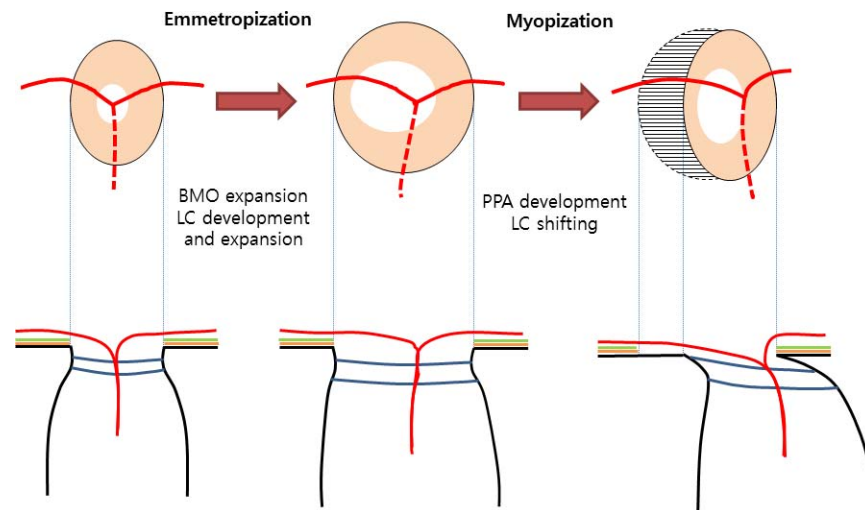


FIGURE 4. Schematic illustration showing optic nerve head and deep-structural changes during emmetropization and myopization.

cases (48.8%) showed peripapillary hypopigmented lesion, and they were categorized into two different shapes, crescent (20.6%) and circular (28.2%). Previous studies have reported that hyper- and hypopigmentary peripapillary rings, which are very similar to the dual-ring sign described in optic nerve hypoplasia, are a very common feature in preterm⁹ and full-term infants.¹⁰ Guevara and Juarez¹⁰ reported that the hypopigmentary ring was found in 94.21% of healthy newborns, and suggested that it could be a normal process for optic disc development that would disappear subsequently. This hypothesis is supported by our present finding that hypopigmentation was more common in the preterm group than in the full-term group. However, our previous study speculated on the presence of beta zone parapapillary atrophy (PPA) with Bruch's membrane as the result of misalignment between RPE layer and Bruch's membrane layer.²² Although we were not able to delineate the histologic characteristics of the hypopigmentary ring in this study, we cautiously hypothesized that at least some hypopigmentary rings in infants might represent beta-zone PPA with Bruch's membrane. Further study with OCT is warranted.

This study has several limitations. First, only normal fundus images of Korean newborns were included. Because it is known that optic disc parameters have racial differences,^{23,24} further study is needed with various ethnic groups to generalize our hypothesis. Second, we could not identify the actual BMO and deep structure of the ONH, because we used only fundus photographs. Moreover, in some eyes (up to 5%), the exact location of the CVT and/or the cup margin could not be identified due to ambiguity of fundus images, so they were excluded from the analysis. Longitudinal study using OCT for newborns would be necessary in order to track the development of the ONH and LC changes. Third, no control group of different ages was set up in the present study. It would be meaningful to compare the CVT position and morphologic variation of the ONH among different age groups. Instead of establishing a control group, we compared the results with several large-scale epidemiologic studies that had been conducted in Asia.^{6,18-20} Fourth, image misalignment according to the angle of measurement could have influenced the measurements of ONH and CVT position. However, the effects may be minimal, because the fundus photos had been taken by well-trained technicians. Last, we did not measure the axial length, refraction, or keratometry. Because of this, we used

cup-to-disc ratio and ovality index instead of disc diameter and cup diameter in this study.

In conclusion, the CVT of newborns was located in the center of the ONH in most cases. The shape of the optic disc was usually vertically oval, and very similar among the newborns. Our findings suggest that the ONH shape and deep structures would be changed during emmetropization in infancy and early childhood. This process could be related to the development of vulnerability to glaucomatous optic neuropathy.

Acknowledgments

Supported by a clinical research grant-in-aid from the Seoul Metropolitan Government Seoul National University (SMG-SNU) Boramae Medical Center (03-2019-3; Seoul, Korea).

Disclosure: **M. Kim**, None; **S.Y. Kim**, None; **K.M. Lee**, None; **S. Oh**, None; **S.H. Kim**, None

References

- Jonas JB, Gusek GC, Naumann GO. Optic disc, cup and neuroretinal rim size, configuration and correlations in normal eyes. *Invest Ophthalmol Vis Sci*. 1988;29:1151-1158.
- Wang Y, Xu L, Zhang L, Yang H, Ma Y, Jonas JB. Optic disc size in a population based study in northern China: the Beijing Eye Study. *Br J Ophthalmol*. 2006;90:353-356.
- Ramrattan RS, Wolfs RC, Jonas JB, Hofman A, de Jong PT. Determinants of optic disc characteristics in a general population: the Rotterdam Study. *Ophthalmology*. 1999;106:1588-1596.
- Jonas JB, Budde WM, Panda-Jonas S. Ophthalmoscopic evaluation of the optic nerve head. *Surv Ophthalmol*. 1999;43:293-320.
- Kang NH, Jun RM, Choi KR; for the Namil Study Group, Korean Glaucoma Society. Clinical features and glaucoma according to optic disc size in a South Korean population: the Namil study. *Jpn J Ophthalmol*. 2014;58:205-211.
- Mataki N, Tomidokoro A, Araie M, Iwase A. Morphology of the optic disc in the Tajimi Study population. *Jpn J Ophthalmol*. 2017;61:441-447.
- De Silva DJ, Cocker KD, Lau G, Clay ST, Fielder AR, Moseley MJ. Optic disk size and optic disk-to-fovea distance in preterm and full-term infants. *Invest Ophthalmol Vis Sci*. 2006;47:4683-4686.

8. Kandasamy Y, Smith R, Wright IM, Hartley L. Optic disc measurements in full term infants. *Br J Ophthalmol*. 2012;96:662-664.
9. Hackl S, Zeman F, Helbig H, Oberacher-Velten IM. Optic disc morphology in premature infants. *Br J Ophthalmol*. 2013;97:314-317.
10. Guevara DA, Juarez EJ. Clinical features of optic nerve head in healthy newborns. *Arch Soc Esp Ophthalmol*. 2017;92:54-57.
11. Tong AY, El-Dairi M, Maldonado RS, et al. Evaluation of optic nerve development in preterm and term infants using handheld spectral-domain optical coherence tomography. *Ophthalmology*. 2014;121:1818-1826.
12. Rimmer S, Keating C, Chou T, et al. Growth of the human optic disk and nerve during gestation, childhood, and early adulthood. *Am J Ophthalmol*. 1993;116:748-753.
13. Soo A, Taha S, Lally P, Kirmi O, Jones B, Thayyil S. Assessment of optic nerve development using post-mortem magnetic resonance imaging (MRI) in fetuses and newborns. *Prenat Diagn*. 2015;35:1262-1264.
14. Patel A, Purohit R, Lee H, et al. Optic nerve head development in healthy infants and children using handheld spectral-domain optical coherence tomography. *Ophthalmology*. 2016;123:2147-2157.
15. Kim M, Choung HK, Lee KM, Oh S, Kim SH. Longitudinal changes of optic nerve head and peripapillary structure during childhood myopia progression on OCT: Boramae Myopia Cohort Study Report 1. *Ophthalmology*. 2018;125:1215-1223.
16. Lee KM, Choung HK, Kim M, Oh S, Kim SH. Positional change of optic nerve head vasculature during axial elongation as evidence of lamina cribrosa shifting: Boramae Myopia Cohort Study Report 2. *Ophthalmology*. 2018;125:1224-1233.
17. Lee KM, Kim M, Oh S, Kim SH. Position of central retinal vascular trunk and preferential location of glaucomatous damage in myopic normal-tension glaucoma. *Ophthalmol Glaucoma*. 2018;1:32-43.
18. Bourne RR, Foster PJ, Bunce C, et al. The morphology of the optic nerve head in the Singaporean Chinese population (the Tanjong Pagar study): part 1-optic nerve head morphology. *Br J Ophthalmol*. 2008;92:303-309.
19. Jonas JB, Wang YX, Zhang Q, et al. Parapapillary gamma zone and axial elongation-associated optic disc rotation: the Beijing Eye Study. *Invest Ophthalmol Vis Sci*. 2016;57:396-402.
20. Guo Y, Liu LJ, Tang P, et al. Parapapillary gamma zone and progression of myopia in school children: the Beijing Children Eye Study. *Invest Ophthalmol Vis Sci*. 2018;59:1609-1616.
21. Wang J, Liu G, Wang D, Yuan G, Hou Y, Wang J. The embryonic development of the human lamina cribrosa. *Chin Med J (Engl)*. 1997;110:946-949.
22. Lee KM, Choung HK, Kim M, Oh S, Kim SH. Change of beta-zone parapapillary atrophy during axial elongation: Boramae Myopia Cohort Study Report 3. *Invest Ophthalmol Vis Sci*. 2018;59:4020-4030.
23. Allingham MJ, Cabrera MT, O'Connell RV, et al. Racial variation in optic nerve head parameters quantified in healthy newborns by handheld spectral domain optical coherence tomography. *J AAPOS*. 2013;17:501-506.
24. Girkin CA, McGwin G Jr, Sinai MJ, et al. Variation in optic nerve and macular structure with age and race with spectral-domain optical coherence tomography. *Ophthalmology*. 2011;118:2403-2408.