

Evaluation of Lens Capsule Stability Using Capsular Tension Ring, Iris Retractor, and Capsule Expander Using a Porcine Model With Zonular Dehiscence

Saori Yaguchi,¹ Shigeo Yaguchi,² and Hiroko Bissen-Miyajima¹

¹Department of Ophthalmology, Tokyo Dental College Suidobashi Hospital, Tokyo, Japan

²Department of Ophthalmology, Showa University School of Medicine, Tokyo, Japan

Correspondence: Shigeo Yaguchi, Department of Ophthalmology, Showa University School of Medicine, 1-5-8, Hatanodai Shinagawa-ku, Tokyo 142-8555, Japan; yaguchis@hotmail.co.jp.

Submitted: May 3, 2019

Accepted: July 16, 2019

Citation: Yaguchi S, Yaguchi S, Bissen-Miyajima H. Evaluation of lens capsule stability using capsular tension ring, iris retractor, and capsule expander using a porcine model with zonular dehiscence. *Invest Ophthalmol Vis Sci.* 2019;60:3507–3513. <https://doi.org/10.1167/iovs.19-27449>

PURPOSE. We evaluate the efficacy of capsular tension rings (CTRs), iris retractors (IRs), and capsule expanders (CEs) in stabilizing the lens capsule under different degrees of zonular dehiscence using a porcine model.

METHODS. We developed an experimental model that can be used to observe the dynamics of lens capsules with different degrees of zonular dehiscence during phacoemulsification and aspiration (PEA). PEA was performed without any aid (control) and with devices. A CTR was used for a dehiscence of 30°, 45°, 60°, 90°, 120°, 150°, and 180° and one to four IRs or one to three CEs were used for a dehiscence of 90°, 120°, and 180°. The retention rate, calculated as the area of the capsular bag during PEA divided by the area before zonular dissection, and the number of lens fragments dropped into the vitreous cavity during PEA were examined and compared among the control and experimental groups.

RESULTS. The retention rate increased significantly with the use of devices compared to the control ($P < 0.05$). The number of dropped lens fragments decreased by one or less with the use of CTR, one IR, or one CE for 90°, two IRs, or one or two CEs for 120°, and three or four IRs, or two or three CEs for 180° of zonular dehiscence.

CONCLUSIONS. The experimental porcine eye model with zonular dehiscence makes it possible to observe the entire configuration of the lens capsule, and demonstrates differences in the efficacy of capsular bag retention with CTR, IR, and CE.

Keywords: cataract surgery, weak zonule, capsule stabilization device, experimental evaluation, lens stability

Performing cataract surgery in patients with zonular instability presents many challenges, including increased risks of intraoperative complications, such as posterior capsule rupture, nucleus drop, and vitreous prolapse. Appropriate use of capsular stabilization devices enables surgeons to perform safe and successful phacoemulsification and aspiration (PEA) in patients with zonular instability.

Several types of capsular stabilization devices to manage lens subluxation have been reported. Hara et al.¹ introduced the equator ring, which was the initial prototype for the capsular tension ring (CTR). Nagamoto and Bissen-Miyajima developed the concept further,² resulting in the production and broad adoption of CTRs with various designs.^{3–5} Iris retractors (IRs) have been used to provide capsule support in cases of zonular dehiscence.^{6,7} We previously reported the use of a T-shaped capsular hook (capsule expander; CE) to suspend and stabilize the lens capsule and facilitate safe PEA.^{8,9}

Appropriate device selection relies on proper evaluation of lens instability caused by zonular compromise. It is very important to understand the dynamics of the lens capsule and how capsule stabilization devices retain the capsule in cases with several degrees of zonular dehiscence during PEA.

However, to our knowledge quantitative assessments of the efficacy of capsule stabilization devices in retaining the lens capsule in the presence of different degrees of zonular

dehiscence have not been reported. We developed an experimental model of zonular dehiscence using enucleated porcine eyes, which enables us to observe the configuration of the lens capsule with different degrees of zonular dehiscence during PEA after iris and zonular fibers are dissected by diathermy.¹⁰ We evaluated the efficacy of CTRs, IRs, and CEs under different degrees of zonular dehiscence in a porcine model.

METHODS

Experimental Model of Zonular Dehiscence

All procedures adhered to the ARVO Statement for the Use of Animals in Ophthalmic and Vision Research. No patients or living animals were involved in this preclinical study. We created the experimental model of zonular dehiscence using freshly extracted porcine eyes. Two stab incisions were made at 2 and 10 o'clock positions and the anterior chamber was filled with an ophthalmic viscosurgical device (OVD; Healon; Abbot Medical Optics, Santa Ana, CA, USA). The entire circumference of the iris root was dissected using diathermy inserted from one stab incision (OS3; Oertli Instruments, Berneck, Switzerland). The iris was centripetally stretched with capsule forceps inserted from the other stab incision, and the iris was



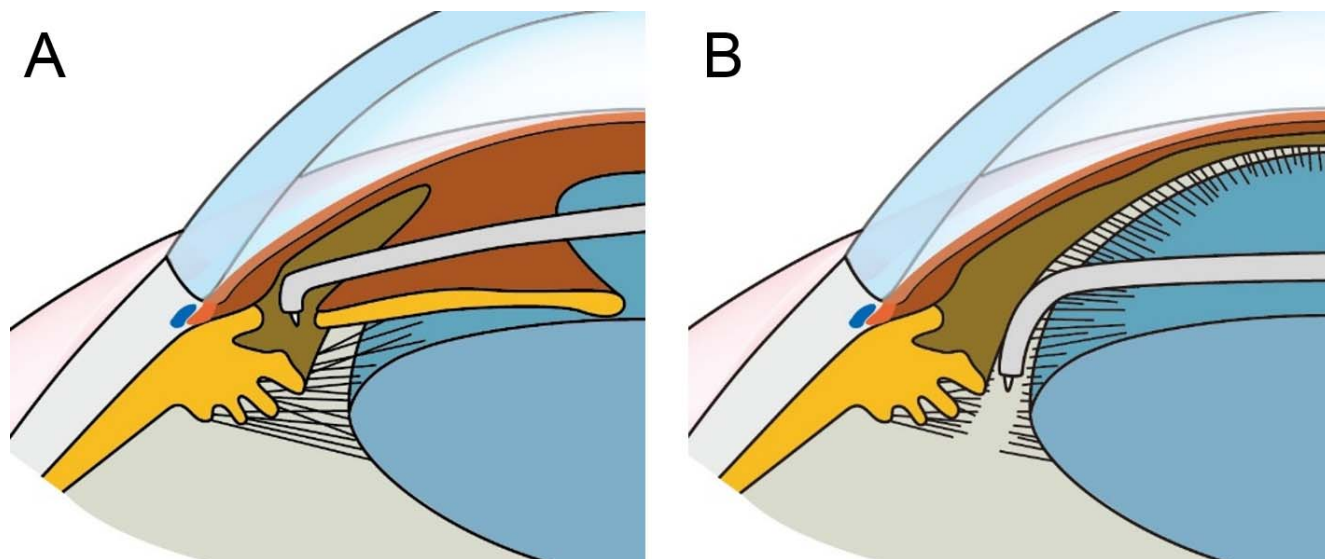


FIGURE 1. Creation of an experimental model of zonular dehiscence. The iris root was dissected using diathermy (A). The zonula was dissected to create a partial zonular dehiscence (B).

completely removed from the incision (Fig. 1A). The degree of zonular dehiscence was measured with a toric lens marker and marked at the corneal limbus. The tip of the diathermy probe was placed in the gap between the lens equator and ciliary process, and the zonula was dissected to create zonular dehiscence (Fig. 1B). The conditions used for dissection of the iris and zonula were DIA, 8 W, 50 Ω, and 500 Hz, with a high frequently cut capsule mode. Zonular dehiscences of 30°, 45°, 60°, 90°, 120°, 150°, and 180° were created.

CTR, IR, and CE Insertion and PEA

Following initial puncture with the cystotome (27-gauge needle), a 6.0 mm in diameter continuous curvilinear capsulorrhexis (CCC) was performed using a capsule forceps. Eyes with incomplete or largely decentered CCC, in which capsule stabilization devices could not be inserted or hooked, were excluded from the experiment. When CCC could not be performed because of severe lens movement in models with large zonular dehiscence, highly retentive and cohesive OVD (Healon5[®]; Abbot Medical Optics, Inc., IL, USA) was injected into the anterior chamber. Capsule stabilization devices,

specifically CTR (CTR130A0; Hoya Surgical Optics, Chino Hills, CA, USA), IR (Grieshaber Iris Retractor; Alcon Laboratories, Ft. Worth, TX, USA), or CE (Handaya Co., Ltd, Tokyo, Japan), were introduced. The numbers of CTRs, IRs, and CEs used in the models with different degrees of zonular dehiscence are shown in Table 1. The CTR was inserted in the capsular bag using an injector (Capsule tension ring injector; Geuder, G-32960; M.E. Technica, Tokyo, Japan). Equally spaced IRs were inserted in the area of zonular dehiscence under the anterior capsulorrhexis rim and the capsule was temporarily fixed to the scleral wall by adjusting the silicon rubber ring. We developed a CE to preserve the lens capsule integrity during PEA in eyes with weak zonules.⁸ The CE is flexible, 10.0 mm long, and fashioned from 5-0 polypropylene. The CE is shaped like an IR, but the contact portion is bent at 1.25 mm, with an end bifurcating to form a 2.0-mm T-shaped footpad (Fig. 2A). The CE simultaneously expands the capsular equator and the edge of the CCC by a T-shaped footpad (Fig. 2B). The CE was spaced equally in the area of zonular dehiscence, with the T-shaped end passing around the anterior capsular flap to fit the curvature of the equator, and the capsule was temporarily fixed to the scleral wall by adjusting the silicon rubber ring.

A 2.6-mm temporal corneal incision was created at the opposite side of the zonular dialysis and PEA (OS3) was performed with the aid of capsule stabilization devices (vacuum pressure: 300 mm Hg, flow rate, 24 mL/min; ultra sound power, 10%). PEA without devices was used as the control and five eyes were used for each group.

Evaluation of Capsule Retention

First, the anterior capsule area before the zonular dissection was measured (Fig. 3A). Next, images from the PEA video recording were captured for 30 seconds every 2 seconds from the beginning of the procedure using Windows Live Movie Maker (Microsoft Corporation, Redmond, WA, USA). In each captured image, the anterior capsule area was measured (Fig. 3B). The lens equator, which can be observed through the ciliary process, was traced using illustration software (Illustrator CC 2015; Adobe, San Jose, CA, USA). The surrounding area, defined as the anterior capsule area, was measured using a

TABLE 1. Number of CTRs, IRs, and CEs used in the Model With Different Degrees of Zonular Dehiscence

Capsule Stabilization Device	Number Used	Model With Zonular Dialysis	
CTR	0 (Control) 1	30°, 45°, 60°, 90°, 120°, 150°, and 180°	
IR	0 (Control) 1 2 3 4	90°, 120°, and 180° 90°, 120°, and 180° 120°, and 180° 180° 180°	
	CE	0 (Control) 1 2 3	90°, 120°, and 180° 90°, 120°, and 180° 120°, and 180° 180°

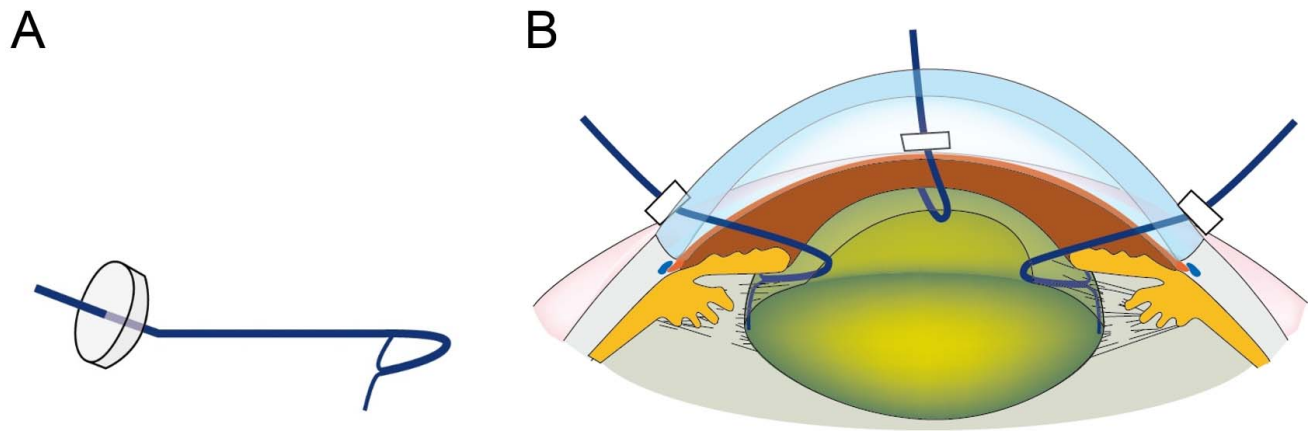


FIGURE 2. Capsule expander (CE). The contact portion of the CE is bent at 1.25 mm with an end bifurcating to form a 2.0-mm T shape (A). This footpad helps to simultaneously expand the capsular equator and the edge of the CCC (B).

computerized image analysis program, Image J (National Institutes of Health [NIH], Bethesda, MD, USA). Then, the capsule retention rate was calculated as the rate of the anterior capsule area during PEA over that before zonular dissection (Fig. 3C). The retention rate was calculated at 16 points per eye, and a total of 80 points for five eyes per group was used for the analysis. The retention rate was compared in each range of zonular dialysis among the control and experimental groups.

Number of Dropped Lens Fragments

The video recording of PEA was played back frame by frame with an interval of 0.033 seconds from the start to 30 seconds using Windows Live Movie Maker. The number of lens fragments dropped into the vitreous cavity from the zonular dehiscence during PEA was counted (Fig. 3D). Mean number of dropped lens fragments was compared for each range of zonular dialysis among the control and experimental groups.

Statistical Analyses

All results are expressed as mean ± SD. The data were processed for statistical analyses. Unpaired *t*-test with Welch's correction was used for comparison between the control and CTR, control and one IR, and control and one CE. The Kruskal-Wallis test followed by Dunn's multiple comparison test was used for comparison among the control and one to four IRs, and the control and one to three CEs. Differences were considered statistically significant at *P* < 0.05.

RESULTS

Anterior Capsule Area

Mean area of the anterior lens capsule before zonular dissection was 125.3 ± 5.8 mm².

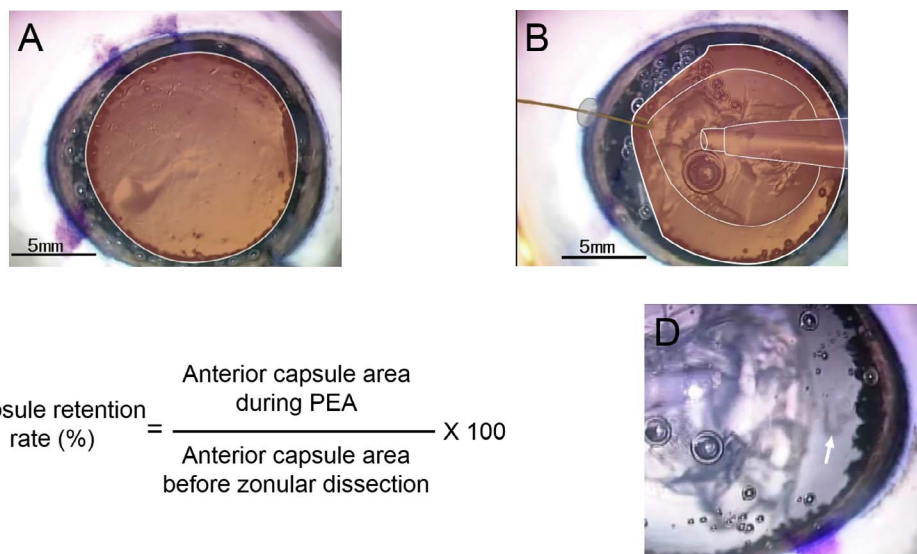


FIGURE 3. Evaluation of capsule retention. The anterior capsule before zonular dissection is shown in A. The lens equator, which can be observed through a ciliary process, is traced with a *white line*. The surrounding area is defined as the anterior capsule area. The anterior capsule with the use of one IR during PEA in an eye model with 120° of zonular dehiscence is shown in B. The capsule retention rate was calculated as the rate of the anterior capsule area during PEA over that before zonular dissection (C). The lens fragments dropped into the vitreous cavity (*white arrow*) are shown in D.

TABLE 2. Retention Rate and Mean Number of Dropped Lens Fragments During PEA in the Control Group With 30°, 45°, 60°, 90°, 120°, 150°, and 180° of Zonular Dehiscence

Degree of Zonular Dialysis	Retention Rate, %	Number of Dropped Nuclei
30°	98.88 ± 0.34	0.2 ± 0.4
45°	97.30 ± 0.90	0.2 ± 0.4
60°	93.38 ± 2.56	1.8 ± 1.1
90°	91.26 ± 2.54	2.4 ± 1.7
120°	83.16 ± 7.56	3.4 ± 1.5
150°	75.20 ± 9.97	4.2 ± 2.3
180°	68.99 ± 13.78	18.4 ± 11.9

Capsule Retention Rate and the Number of Dropped Nuclei in the Control Group With 30°, 45°, 60°, 90°, 120°, 150°, and 180° of Zonular Dehiscence

The retention rate and mean number of dropped lens fragments during PEA in the control group with 30°, 45°, 60°, 90°, 120°, 150°, and 180° of zonular dehiscence are shown in Table 2.

Effects of CTR

The retention rate and mean number of dropped lens fragments during PEA in the control and experimental groups with CTRs with 30°, 45°, 60°, 90°, 120°, 150°, and 180° of

zonular dehiscence are shown in Figure 4. The retention rate in the groups with CTRs increased significantly in all ranges of zonular dialysis compared to that in the control group ($P < 0.0001$). The number of dropped lens fragments decreased significantly in the CTR groups with 60° and 90° of zonular dehiscence compared to the control group (60°, $P = 0.0165$; 90°, $P = 0.0462$).

Effect of IR

The retention rate and number of dropped nuclei in the control group and with use of one, one or two, and one to four IRs for 90°, 120°, and 180°, respectively, of zonular dialysis are shown in Figure 5 and Table 3. The retention rate increased significantly with the use of IR compared to that in the control group ($P < 0.01$). The retention rate increased with the use of more IRs for 120° and 180° of zonular dialysis ($P < 0.01$). The number of dropped lens fragments decreased by one or less with the use of one, two, and three or four IRs for 90°, 120°, and 180°, respectively, of zonular dialysis.

Effect of CE

The retention rate and number of dropped nuclei in the control group and with use of one, one or two, and one to three CEs for 90°, 120°, and 180°, respectively, of zonular dialysis are shown in Figure 6 and Table 3. The retention rate increased significantly with the use of CE compared to that in the control group ($P < 0.01$). The retention rate increased with an increase in the number of CEs used for 120° and 180° of zonular dialysis ($P < 0.01$). The number of dropped lens

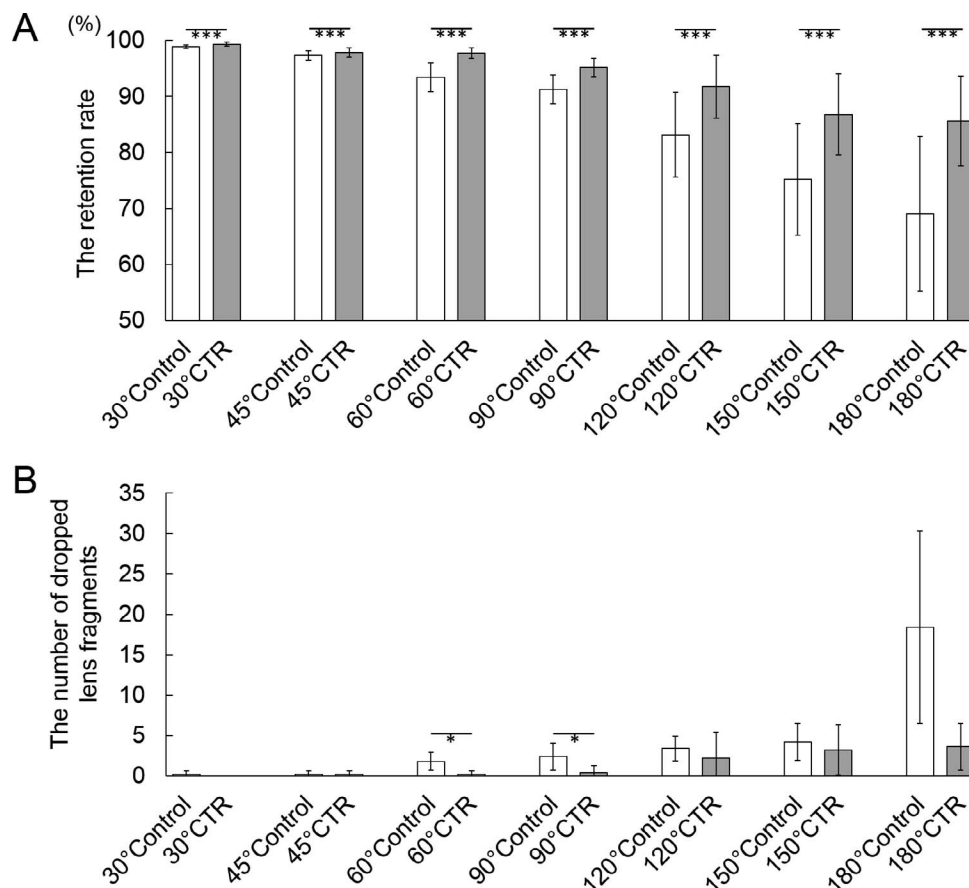


FIGURE 4. Effect of CTR. Retention rate (A) and mean number of dropped lens fragments (B) during PEA in the control and experimental groups with CTRs with 30°, 45°, 60°, 90°, 120°, 150°, and 180° of zonular dehiscence. * $P < 0.05$; *** $P < 0.0001$.

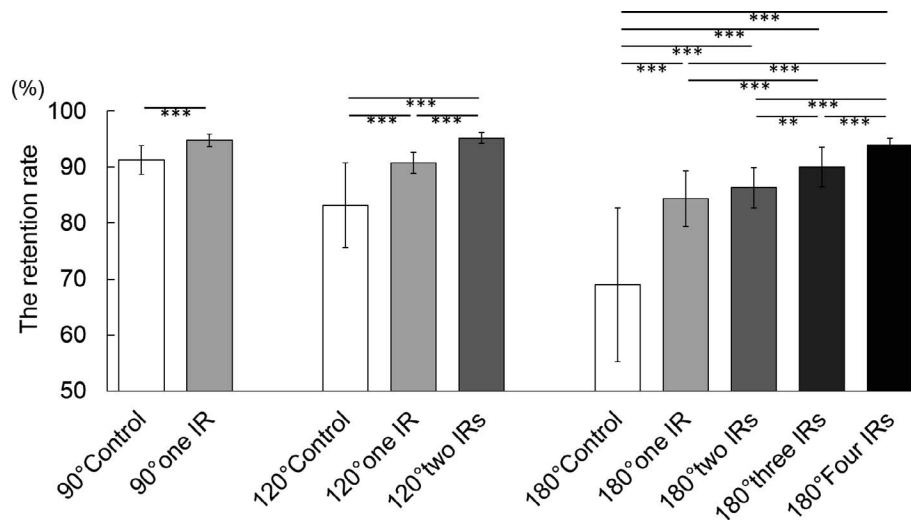


FIGURE 5. Retention rate in the control group and with the use of one, one or two, and one to four IRs for 90°, 120°, and 180°, respectively, of zonular dialysis. ***P* < 0.001; ****P* < 0.0001.

fragments decreased by one or less with the use of one, one or two, and two or three CEs for 90°, 120°, and 180°, respectively of zonular dialysis.

DISCUSSION

We developed an experimental eye model of zonular dehiscence by removing the entire iris and directly dissecting the partial zonula using a capsule diathermy inserted from a stab incision. Using this model, the dynamics of the whole lens capsule could be observed under several degrees of zonular dehiscence.

The Miyake-Apple posterior video analysis/photographic technique is a popular tool for research and teaching in the field of cataract IOL implantation.¹¹ The standard Miyake-Apple view technique uses the eye sectioned at the equator. The anterior half of the globe is affixed to a glass slide, and the anterior segment of the globe is observed from the posterior aspect. In the Miyake-Apple view microscope, posterior illumination is present inside the slide support with the prepared globe, and the support has a draining system to remove aspiration and irrigation fluids during the procedure. In creating the zonular dialysis in the Miyake-Apple video analysis, zonules within a localized area are directly cut with a metal knife from the posterior aspect.¹²

Compared to the Miyake-Apple video analysis, our experimental model does not require additional preparation, such as bisection of the eye. Additionally, maneuvers can be performed

through stab incisions, and zonular dehiscence can be created accurately with the intended range measured with a toric lens marker. Our model can be created in a closed environment and is less traumatic, so that the anatomic structure of the zonula and lens capsule can be better preserved. We believe our model can more accurately simulate the anterior chamber of cases with zonular dehiscence. Our model can be created using capsule diathermy, and the entire lens capsule can be observed through the cornea and recorded using an ordinal video recording system without a draining system. We believe our experimental model is feasible if capsule diathermy is performed.

We evaluated the stability of the lens capsule using CTR, IR, and CE by measuring the retention rate of the lens capsule and counting the number of dropped lens fragments during PEA. The PEA procedure was recorded from the beginning to the end. Mean PEA procedure times were 40.5 ± 11.3 seconds in the control groups, and 41.9 ± 11.5 seconds in the experimental groups with 30°, 45°, 60°, 90°, 120°, 150°, and 180° of zonular dehiscence. The video recording for 30 seconds from the beginning was used for analysis, because it was confirmed that 30 seconds was sufficient enough to remove almost all lens materials, except for lens materials that remained underneath the PEA incision. We believe our results reflected the differences in the way CTR, IR, and CE supported the lens capsule in cases with zonular dehiscence.

CTRs are placed in a capsular bag to expand the capsule equator and allow even distribution of the capsular bag to

TABLE 3. Number of Dropped Nuclei in the Control Group and With the Use of One to Four IRs or One to Three CEs for 90°, 120°, or 180° of Zonular Dehiscence

Capsule Stabilization Device	Number Used	Number of Dropped Nuclei		
		90° of Zonular Dehiscence	120° of Zonular Dehiscence	180° of Zonular Dehiscence
Control	0	2.4 ± 1.7	3.4 ± 1.5	18.4 ± 11.9
IR	1	0.4 ± 0.5	1.6 ± 1.5	2.8 ± 1.3
	2		1.0 ± 1.4	1.2 ± 0.8
	3			0.8 ± 1.3
	4			0.6 ± 0.5
CE	1	0.2 ± 0.4	0.4 ± 0.9	1.2 ± 0.8
	2		0.0 ± 0.0	0.4 ± 0.5
	3			0.2 ± 0.4

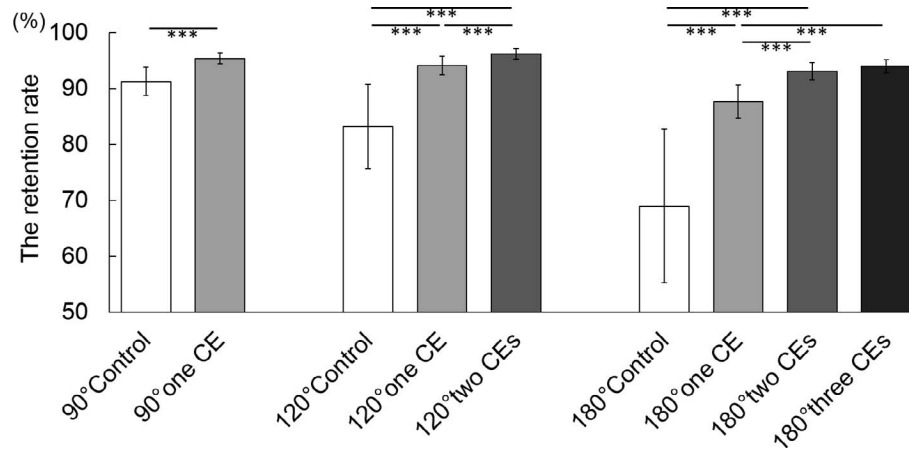


FIGURE 6. Retention rate in the control group and with the use of one, one or two, and one to three CEs for 90°, 120°, and 180°, respectively, of zonular dialysis. *** $P < 0.0001$.

support areas of zonular dehiscence by redistributing zonular tension around the capsule. Consequently, CTRs facilitate safe PEA, IOL insertion, and satisfactory postoperative IOL centration.

On the other hand, the IRs and CEs are temporally hooked and used to stretch the capsulorrhexis edge in areas of zonular dehiscence. IRs and CEs support the capsular bag relative to the sclera by adjusting the silicon rubber rings, so that the zonular-lens complex is supported in the anteroposterior direction.

Our experimental evaluation demonstrated that CTRs retain the lens capsule between 30° and 180° of zonular dehiscence. However, the fluctuation in retention rate, which is reflected in the SD, is larger with CTRs compared to IRs and CEs in 90°, 120°, and 180° of zonular dehiscence. For example, in the model with 120° of zonular dehiscence, the retention rate was $91.7\% \pm 5.6\%$, $90.7\% \pm 1.9\%$, $95.2\% \pm 1.0\%$, $94.1\% \pm 1.7\%$, and $96.2\% \pm 1.0\%$ with CTR, one IR, two IRs, one CE, and two CEs, respectively. This demonstrated that the lens capsule with CTR moved more freely relative to the ciliary body and the zonular complex during PEA compared to those with IRs and CEs because the anterior-posterior force in the plane of the capsule bag was weaker with CTR compared to that with IRs and CEs. Furthermore, lens fragments dropping through the zonular dehiscence could not be significantly prevented at greater than 120° of zonular dehiscence in eyes with CTR. The clinical indication of CTR is mild segmental zonulolysis (<4 clock hours) or mild generalized weakness.¹³ Our results demonstrated that retaining the lens capsule and preventing lens fragments from dropping are important factors when considering CTR insertion, and support the clinical indication of CTR.

Concerning the IRs and CEs, the retention rate increased with an increase in the number of devices used. The number of dropped lens fragments decreased by one or less with the use of one IR or one CE for 90°, two IRs or one or two CEs for 120°, and three or four IRs or two or three CEs for 180° of zonular dehiscence. Fewer CEs prevent the nuclei from dropping compared to IRs. It can be said that the large contact portion of CE, which is the 2.0-mm T-shaped tip, accurately fits the curvature of the lens equator, making it possible to expand the capsular equator and the edge of the CCC more firmly compared to IRs.

We could quantitatively assess the effect of CTR, IR, and CE in retaining the lens capsule with different degrees of zonular dehiscence using the experimental model. Our results and further experiments would be useful for deciding the

indication of capsule stabilization devices in eyes with zonular weakness.

In addition to observing the capsular bag and the effect of the capsule stabilization device during PEA, our experimental model was very useful for evaluating other surgical procedures, such as capsulotomy in cases with zonular dehiscence. Automated capsulotomy creation using a femtosecond laser and precision pulse technology was introduced recently as an alternative capsulotomy method, and has been reported to be very useful in cases with zonular weakness.^{14,15} Our model can be used to demonstrate the usefulness of these techniques in cases with several degrees of zonular dehiscence. Furthermore, the model will be helpful for CTR insertion training. The process of introducing the CTR into the capsular bag can differ, with variations in insertion timing, instruments, and rotation in the capsular bag. CTR insertion requires practice and knowledge of the techniques especially for trainees. Our experimental model can be used for teaching and training purposes. Our model also can be used to observe the behavior of the IOL haptics. Because the iris was completely removed, we could observe the dynamics of the IOL haptics inserted in the capsular bag. We believed our experimental model could be used for research on intra- and postoperative IOL rotation, especially in the toric IOL.

There were limitations to our study. First, the effects of CTR, IR, and CE on retaining the lens capsule depended on the relationship with the lens capsules. For example, the effect of lens capsule expansion may change depending on where the eyelet of the CTR is located. The centration, shape, and size of CCC also may modify the effect of lens capsule retention, especially when the IR and CE hook the capsulorrhexis edge. Although CTRs were inserted with the eyelet positioned at the middle of the zonular dehiscence and eyes with abnormal CCC were excluded from this study, further investigation may be needed. Furthermore, the results may vary with different locations of the PEA incision. The temporal incision was created at the opposite side of the zonular dialysis in this study. Further investigation with different locations of the PEA incision may be needed (i.e., superior or same side of the zonular dialysis).

Second, the properties of the porcine lens capsule are different from those of humans. We confirmed that the lens diameters with and without CTR in the porcine eye were comparable to the reported lens diameter in human eyes; the lens diameter of porcine eyes before PEA was 10.28 ± 0.22 mm measured through the vitreous cavity, and 10.78 ± 0.12 mm with CTR inserted in the lens capsule after PEA. In the

human eye, the lens diameter is 10.20 ± 0.38 mm when measured with the Miyake-Apple view¹⁶ and 10.53 ± 0.37 mm when measured with a capsule measuring ring.¹⁷ The capsule measuring ring comprises a 12.0-mm diameter polymethylmethacrylate ring with 0.2-mm thick appendixes instead of eyelets on both ends. The capsular bag diameter is measured at the slit-lamp by ascertaining the relative positions of the two appendixes. Although the diameter of the CTR used in the porcine eyes was 13.0 mm, we believed the diameters of lens capsules with CTR in porcine eye and lens capsules with a capsule measuring ring in human eyes were comparable. However, the porcine anterior capsule was thicker than that of humans. The anterior capsule in the porcine eye was barely torn radially, even when pulled strongly by IR or CE. Further, the residual zonula without zonular dialysis was strong and the vitreous had a thick consistency because the eye was extracted from a young pig. Lens fragments barely dropped from the zonular dialysis into the vitreous cavity in the porcine eye. Although the results of the porcine model cannot be applied to clinical cases, our results demonstrated the characteristics of CTR, IR, and CE in retaining the lens capsule in cases with zonular dehiscence.

Third, only the anterior view could be obtained with our model. The anterior-posterior movement of the lens capsule could not be evaluated because an oblique or side view could not be observed. To evaluate the effect of IR and CE in supporting the lens capsule in the anteroposterior direction, evaluation from the side view was necessary. We plan to use an endoscope to obtain the side view of the lens capsule in our model.

Fourth, in clinical cases, it is impossible to observe the actual range of the zonular dialysis and the dynamics of the lens capsule because the zonula and lens equator are behind the iris. The area of the lens capsule during PEA varies depending on the diameter of the pupil. We plan to examine the changes in the lens capsule with the assumption of the existence of the iris.

In conclusion, our experimental porcine eye model made it possible to observe the entire configuration of the lens capsule in different degrees of zonular dehiscence, and demonstrated the differences in the efficacy of retaining the capsular bag between CTR, IR, and CE during PEA. The model will be helpful to understand the dynamics of the capsular bag during PEA and to select the appropriate capsule stabilization devices under several degrees of zonular dehiscence.

Acknowledgments

The authors thank Keiichiro Minami for critical discussions.

Disclosure: **S. Yaguchi**, None; **S. Yaguchi**, P; **H. Bissen-Miyajima**, None

References

- Hara T, Hara T, Yamada Y. "Equator ring" for maintenance of the completely circular contour of the capsular bag equator after cataract removal. *Ophthalmic Surg.* 1991;22:358-359.
- Nagamoto T, Bissen-Miyajima H. A ring to support the capsular bag after continuous curvilinear capsulorhexis. *J Cataract Refract Surg.* 1994;20:417-420.
- Gimbel HV, Sun R, Heston JP. Management of zonular dialysis in phacoemulsification and IOL implantation using the capsular tension ring. *Ophthalmic Surg Lasers.* 1997;28:273-281.
- Menapace R, Findl O, Georgopoulos M, Rainer G, Vass C, Schmetterer K. The capsular tension ring: designs, applications, and techniques. *J Cataract Refract Surg.* 2000;26:898-912.
- Bayraktar S, Altan T, Küçükşümer Y, Yilmaz OF. Capsular tension ring implantation after capsulorhexis in phacoemulsification of cataracts associated with pseudoexfoliation syndrome. Intraoperative complications and early postoperative findings. *J Cataract Refract Surg.* 2001;27:1620-1628.
- Santoro S, Sannace C, Casella MC, Lavermicocca N. Subluxated lens: phacoemulsification with iris hooks. *J Cataract Refract Surg.* 2003;29:2269-2273.
- Sethi HS, Sinha A, Pal N, Saxena R. Modified flexible iris retractor to retract superior iris and support inferior capsule in eyes with iris coloboma and inferior zonular deficiency. *J Cataract Refract Surg.* 2006;32:715-716.
- Nishimura E, Yaguchi S, Nishihara H, Ayaki M, Kozawa T. Capsular stabilization device to preserve lens capsule integrity during phacoemulsification with a weak zonule. *J Cataract Refract Surg.* 2006;32:392-395.
- Yaguchi S, Yaguchi S, Asano Y, et al. Categorization and surgical techniques of weak zonule based on findings at capsulorhexis during cataract surgery. *J Clin Exp Ophthalmol.* 2015;6:407.
- Yaguchi Y, Yaguchi S, Yaguchi S, et al. Objective evaluation of zonular weakness: measurement of lens movement at the start of capsulorhexis using extracted porcine eyes. *J Clin Exp Ophthalmol.* 2016;7:541.
- Pereira FA, Werner L, Milverton EJ, Coroneo MT. Miyake-Apple posterior video analysis/photographic technique. *J Cataract Refract Surg.* 2009;35:577-587.
- Ahmed II, Cionni RJ, Kranemann C, Crandall AS. Optimal timing of capsular tension ring implantation: Miyake-Apple video analysis. *J Cataract Refract Surg.* 2005;31:1809-1813.
- Hoffman RS, Snyder ME, Devgan U, et al. Management of the subluxated crystalline lens. *J Cataract Refract Surg.* 2013;39:1904-1915.
- Waltz K, Thompson VM, Quesada G. Precision pulse capsulotomy: Initial clinical experience in simple and challenging cataract surgery cases. *J Cataract Refract Surg.* 2017;43:606-614.
- Chee SP, Wong MH, Jap A. Management of severely subluxated cataracts using femtosecond laser-assisted cataract surgery. *Am J Ophthalmol.* 2017;173:7-15.
- Vasavada A, Singh R. Relationship between lens and capsular bag size. *J Cataract Refract Surg.* 1998;24:547-551.
- Tehrani M, Dick HB, Krummenauer F, Pfirrmann G, Boyle T, Stoffelns BM. Capsule measuring ring to predict capsular bag diameter and follow its course after foldable intraocular lens implantation. *J Cataract Refract Surg.* 2003;29:2127-2134.