

Lowered Decorin With Aberrant Extracellular Matrix Remodeling in Aqueous Humor and Tenon's Tissue From Primary Glaucoma Patients

Sampath NikhalaShree,^{1,2} Gayathree Karthikkeyan,¹ Ronnie George,³ Balekudaru Shantha,³ Lingam Vijaya,³ Vineet Ratra,³ Konerirajapuram Natarajan Sulochana,¹ and Karunakaran Coral¹

¹R.S. Mehta Jain Department of Biochemistry and Cell Biology, KBIRVO, Vision Research Foundation, Sankara Nethralaya, Chennai, India

²School of Chemical and Biotechnology, SASTRA Deemed-to-be University, Thanjavur, India

³Smt Jadhavbai Nathmal Singhvee Glaucoma Services, Medical Research Foundation, Sankara Nethralaya, Chennai, India

Correspondence: Karunakaran Coral, R. S. Mehta Jain Department of Biochemistry and Cell Biology, Vision Research Foundation, Sankara Nethralaya, 41, College Road, Chennai - 600 006, India; ceeyem08@gmail.com.

Submitted: March 14, 2019

Accepted: September 29, 2019

Citation: NikhalaShree S, Karthikkeyan G, George R, et al. Lowered decorin with aberrant extracellular matrix remodeling in aqueous humor and Tenon's tissue from primary glaucoma patients. *Invest Ophthalmol Vis Sci*. 2019;60:4661-4669. <https://doi.org/10.1167/iovs.19-27091>

PURPOSE. To evaluate the inflammatory cytokine, growth factors, extracellular matrix (ECM) remodeling genes, profibrotic and antifibrotic molecules in patients undergoing glaucoma filtration surgery (GFS). Additionally, the effect of preoperative antiglaucoma medications (AGMs) and postoperative bleb status were related to these parameters.

METHODS. Tenon's tissue and aqueous humour (AH) were collected from 207 patients undergoing GFS with primary open-angle glaucoma (POAG) ($n = 77$), primary angle-closure glaucoma (PACG) ($n = 62$), and cataract controls ($n = 68$). Monocyte chemoattractant protein-1 (MCP-1), connective tissue growth factor (CTGF), transforming growth factor β 1/2 (TGF- β 1/2), lysyl oxidase (LOX), lysyl oxidase L2 (LOXL2), elastin (ELN), collagen type 1 α 1 (COL1A1), secreted protein acidic and rich in cysteine (SPARC), α -smooth muscle actin (α -SMA), and decorin (DCN) were determined in tenon's tissue by real-time PCR and in AH using ELISA.

RESULTS. A significant increase was observed in the transcripts of *MCP-1*, *TGF- β 2*, and *SPARC* in POAG and PACG ($P < 0.05$); *CTGF*, *TGF- β 1*, *LOX*, *LOXL2*, *ELN*, *COL1A1*, and *α -SMA* in PACG ($P < 0.05$) compared with control. *DCN* transcript was significantly decreased in POAG and PACG ($P < 0.05$) compared with control. The protein levels of CTGF, TGF- β 1/ β 2, ELN, SPARC, and LOXL2 was significantly elevated in POAG and PACG ($P < 0.05$); DCN was decreased ($P < 0.05$) compared with control. These parameters showed significant association with duration of preoperative AGMs and postoperative bleb status.

CONCLUSIONS. This study demonstrates increased expression of growth factors and ECM molecules, both at protein and transcript levels in GFS patients. A decreased DCN in AH seems striking, and if restored might have a therapeutic role in minimizing postoperative scarring to improve GFS outcome.

Keywords: glaucoma, aqueous humor, decorin, extracellular matrix

Glaucoma is a multifactorial progressive optic neuropathy characterized by loss of visual field, degeneration of retinal ganglion cells (RGCs), and their axons along with damage to the optic nerve head (ONH). It stands the second leading cause of blindness after cataract and accounts for 8% of global blindness as reported by the World Health Organization.¹⁻³ The population with glaucoma is estimated to increase to 111.8 million by 2040 globally, particularly impactful in Asia.⁴⁻⁶ Primary glaucoma is classified as primary open-angle glaucoma (POAG) and primary angle-closure glaucoma (PACG) with the latter significantly prevalent in India.⁵ Elevated intraocular pressure (IOP) caused due to decreased aqueous outflow through the trabecular meshwork (TM) is a major risk factor to develop glaucoma.⁷ The drainage of aqueous humour (AH) is reduced due to increased accumulation of extracellular matrix (ECM) in the juxtacanalicular TM.⁸

Treatment for glaucoma lies focused on reducing IOP that can be controlled by either limiting the AH production or by

increasing its outflow rate using antiglaucoma medications (AGMs), that is β -blockers, prostaglandin analogues, α -adrenergic agonists, cholinergic and carbonic anhydrase inhibitors.⁹⁻¹¹ However, patients with medically uncontrolled IOP are surgically treated by trabeculectomy, a filtration surgery.¹² Postoperative fibrosis and inflammation-related events are the key determinants of long-term surgical success following glaucoma filtration surgery (GFS). Antimetabolites such as mitomycin-C and 5-fluorouracil are commonly used during the initial stage of the surgery to prevent excessive postoperative scarring. Histopathological evidence state that failed fibrotic capsules reveals higher fibroblast population with increased production of ECM contributing to the pathophysiology.¹³

Transforming growth factor β (TGF- β)^{14,15} and its downstream mediator connective tissue growth factor (CTGF)¹⁶ play a crucial role in the pathogenesis of glaucoma and augment fibrosis. Besides, lysyl oxidase (LOX), that cross-links collagen and elastin (ELN) is reported to bind with TGF- β 1 and regulate



the ECM remodeling.¹⁷ There is a growing interest among researchers to inhibit these molecules as a therapeutic strategy. In support to this, recombinant monoclonal neutralizing antibody (mAb) to human TGF- β 2 (rhAnti-TGF- β 2 mAb),¹⁸ CTGF antibody (FG-3019),¹⁹ anti-LOX (GS-639556), and anti-LOXL2 (sintuzumab-GS-607601) are being explored in animal models.²⁰

Decorin (DCN), a small leucine-rich proteoglycan is an antagonist of TGF- β and CTGF that regulates cell proliferation, survival, and differentiation.²¹ It has shown promising effects by reducing subconjunctival scarring²² and IOP through fibrinolysis of the scarred TM²³ in animal models.²⁴ There is evidence that tissue-specific viral gene transfer of DCN reduce corneal scarring significantly²⁵ due to its inhibitory effect on TGF- β in corneal fibroblasts.²⁶ Despite these beneficial facts, the levels of DCN in AH is still not evaluated in relevance to glaucoma in human subjects.

Moreover, there is inadequate data on the transcript and protein level of these factors in AH and Tenon's tissue in POAG and PACG. This study aims to address this gap by measuring the inflammatory cytokine (monocyte chemoattractant protein-1 [MCP-1]), growth factors (TGF- β , CTGF), ECM remodeling genes (LOX, LOXL2, SPARC, COL1A1, ELN), profibrotic (α -smooth muscle actin [α -SMA]) and antifibrotic (DCN) molecules in tenon's tissue, and their corresponding protein levels in AH of POAG, PACG, and cataract control. Additionally, we investigated the association of these specific proteins with the duration of preoperative AGMs and postoperative bleb status.

MATERIALS AND METHODS

Patient Selection

This was a case-control study that adhered to the guidelines of the Declaration of Helsinki. The study was conducted by the Medical and Vision Research Foundations, India, and was approved by the Institutional Ethics Committee (ICH-GCP): study code 289-2011-P. Informed consent was obtained from the patients. Subjects were (1) 18 years or older and (2) either with POAG or PACG. The demographics and relevant clinical details of glaucoma and cataract control subjects are provided in Table 1. Patients with other ophthalmic conditions such as history of ocular trauma or uveitis, evidence of ocular surgery including laser before 3 months of sample collection, signs of intraocular inflammation, secondary or neovascular glaucoma, systemic use of steroids, intraoperative complications such as flap amputation, retrobulbar hemorrhage, and suprachoroidal hemorrhage were excluded from the study. Age-matched (difference in age within 5 years) cataract patients without glaucoma were enrolled as controls. None of the control subjects had a history of AGMs. Patients' age, sex, preoperative medications and its duration of administration, systemic illness, preoperative IOP, gonioscopy, disc findings, postoperative IOP, and bleb status were documented. The perioperative drug regimen includes application of 0.4 mg/mL mitomycin-C for 1 to 1.5 minutes and subsequent wash with plenty of saline. Prednisolone acetate was administered after the surgery and was continued in tapering doses for 8 to 12 weeks. The blebs were graded at postoperative day 1, day 7 after 6 weeks, and subsequent follow-ups. All patients underwent suture lysis protocol before bleb evaluation.

The estimated sample size for the study was calculated from the mean total protein in controls (0.292 ± 0.192), POAG (0.578 ± 0.360), and PACG (0.426 ± 0.126) mg/mL as mentioned in the reference study²⁷ with a significance level of 5%, power of 90%, and the effect size of 0.27 using G*Power

3.1 software, and was found to be minimum of 44 in each group.

Collection and Storage of Samples

AH samples approximately 25 to 100 μ L were collected through an anterior chamber paracentesis at the beginning of the surgical procedures, using a 30-gauge needle. The AH samples were transported on ice and centrifuged at 3000 rpm for 10 minutes at 4°C and immediately frozen in -80°C deep freezer until processing. Tenon's tissue excised from patients undergoing trabeculectomy were transferred in RNA later and stored at -80°C until processed for RNA extraction.

RNA Isolation and cDNA Conversion

Total RNA was extracted using TRIzol reagent (Life Technologies Corp., Grand Island, NY, USA) as per the manufacturer's instruction and was quantified using the Nanodrop spectrophotometer (Thermo Scientific, Waltham, MA, USA). Challenges faced during RNA extraction was due to the fibrotic nature and small size of the specimens. One microgram of total RNA was converted to cDNA using the iScript cDNA synthesis kit (Bio-Rad, Hercules, CA, USA).

Real-Time PCR Analysis

Quantitative PCR (qPCR) based on SYBR green chemistry was done using the Roche Light Cycler-96 PCR system (Roche, Basel, Switzerland). The mRNA fold change expression of genes namely, *MCP-1*, *CTGF*, *TGF- β 1/2*, *ELN*, *COL1A1*, *SPARC*, *LOX*, *LOXL2*, *α -SMA*, and *DCN* in each of PACG, POAG, and cataract tenon's tissue specimens were analyzed. The qPCR primers sequences are given in Table 2. Real-time PCR cycle conditions included the following steps: initial denaturation at 95°C for 5 minutes, followed by 50 cycles of denaturation at 95°C for 20 seconds, annealing at 60°C for 20 seconds, and extension at 72°C for 35 seconds. The comparative $2^{-(\Delta\Delta Ct)}$ method²⁸ was used to analyze the results of the genes of interest relative to the internal control gene (*18S rRNA*).

Enzyme-Linked Immunosorbent Assay (ELISA)

CTGF, TGF- β 1/ β 2, ELN, SPARC, LOXL2, and DCN were quantified in AH samples, according to the manufacturer's instructions, using specific ELISA kits (Quantikine Human TGF- β 1/ β 2, SPARC, LOXL2, and DCN immunoassay) purchased from R&D Systems (Minneapolis, MN, USA). Levels of CTGF (SEA010H) and ELN (SEB337Hu) in AH were determined by sandwich ELISA developed by USCN (Cloud-Clone Corp., Katy, TX, USA). The readings were taken at 450 nm in Spectramax plate reader (Molecular Devices, San Jose, CA, USA). Due to the lowered AH volume, CTGF, TGF- β 1/ β 2, ELN, and SPARC were measured in one set of samples, and LOXL2 and DCN were analyzed in another set of samples.

Statistical Analysis

The data were processed and analyzed using statistical analysis software GraphPad Prism 5.0 (GraphPad Software, Inc., San Diego, CA, USA). Descriptive statistics were used to report demographic characteristics. For nonparametric multiple comparisons, a nonparametric Kruskal-Wallis test followed by Mann-Whitney *U* test was performed. Data are expressed as mean \pm SEM or median. A *P* value of less than 0.05 was considered to be statistically significant.

TABLE 1. Clinical Demographics and Baseline Information of Patients

Parameters	Cataract (n = 68)	POAG (n = 77)	PACG (n = 62)	P Value
Age, y, mean ± SD	63.5 ± 9.5	59.4 ± 12.5	60.0 ± 10.8	0.08*
Sex, n (%)				0.0005†
Male	35 (51)	62 (81)	35 (56)	
Female	33 (49)	15 (19)	27 (44)	
Preoperative topical AGMs, n (%)				0.41†
β-blockers	Nil	68 (88)	57 (92)	
Prostaglandins		66 (86)	51 (82)	
α-adrenergics		46 (60)	40 (64)	
CAI		39 (51)	38 (61)	
Cholinergics		01 (01)	05 (08)	
Preoperative topical AGMs, n (%)				0.12†
Single	Nil	07 (09)	00 (00)	
Two		18 (23)	13 (21)	
Three		31 (40)	31 (50)	
Four		20 (26)	18 (29)	
Five		01 (01)	00 (00)	
Nil		00 (00)	00 (00)	
Duration of preoperative AGMs, n (%), y				0.23†
≤1	Nil	18 (24)	17 (27)	
>1–4		21 (27)	12 (19)	
>4–10		24 (31)	14 (23)	
>10		14 (18)	19 (31)	
Systemic illness, n (%)				0.02†
Hypertension	38 (56)	34 (44)	24 (39)	
Diabetes mellitus	35 (51)	33 (43)	17 (27)	
CVD/IHD	12 (18)	08 (10)	03 (05)	
Thyroid	10 (15)	01 (01)	07 (11)	
Hypercholesterolemia	06 (09)	12 (16)	03 (05)	
Arthritis	01 (01)	01 (01)	01 (02)	
Cerebrovascular accident	02 (03)	01 (01)	00 (00)	
Asthma	04 (06)	01 (01)	01 (02)	
No systemic illness	14 (21)	23 (30)	25 (40)	
CDR (mean ± SD)	-	(0.83 ± 0.09)	(0.82 ± 0.10)	0.62‡
Number of eyes with prior laser iridotomy (YAGPI), n (%)	-	-	54 (87)	-
Preoperative, IOP mm Hg, range (mean ± SD)	-	9–34 (17.1 ± 5.5)	12–30 (17.6 ± 4.2)	<0.0001‡ (POAG pre-IOP vs. post-IOP)
Postoperative, IOP mm Hg, range (mean ± SD)	-	2–30 (13.0 ± 4.9)	7–27 (15.1 ± 4.4)	0.0014‡ (PACG pre-IOP vs. post-IOP)
Postoperative bleb status, n (%) (day 1 follow-up)				0.54†
Diffuse	-	66 (86)	53 (85)	
Shallow		10 (13)	06 (10)	
Thin cystic		00 (00)	01 (02)	
Flat		01 (01)	02 (03)	
Postoperative bleb status, n (%) (≥6 months follow-up)				0.91†
Diffuse	-	60 (78)	45 (73)	
Shallow		03 (04)	03 (05)	
Thin cystic		09 (12)	09 (14)	
Flat		05 (06)	05 (08)	

CAI, carbonic anhydrase inhibitor; CVD, cardiovascular disease; IHD, ischemic heart disease; YAGPI, peripheral iridotomy; CDR, cup-to-disc ratio; NA, not applicable; $P < 0.05$ were considered statistically significant.

* Kruskal-Wallis test.

† χ^2 test.

‡ Mann-Whitney U test.

RESULTS

A total of 207 participants were recruited in this study; these included cataract controls ($n = 68$), POAG ($n = 77$), and PACG ($n = 62$). The demographic details of patients enrolled in the study are provided in Table 1.

mRNA Expression of Inflammatory Cytokine and Growth Factors in Tenon's Tissue

The transcript levels of the inflammatory cytokine *MCP-1*, which aid in monocyte infiltration and promote fibrosis was increased significantly in POAG ($P = 0.04$) and PACG ($P =$

TABLE 2. List of Primers Used in Transcript Studies (qPCR)

Gene	Accession No.	Forward Primer	Reverse Primer	Size, bp
<i>MCP-1</i>	NM_002982.3	5'ATGAAAGTCTCTGCGCCCTTCTG 3'	5'AGTCTTCGGAGTTTGGGTTGCTTG 3'	121
<i>CTGF</i>	NM_001901.2	5'TTAAGAAGGGCAAAAAGTGC 3'	5'CATACTCCACAGAATTTAGCTC 3'	112
<i>TGF-β1</i>	NM_000660.5	5'GGGACTATCCACCTGCAAGA 3'	5'CCTCCTTGCGTAGTAGTCG 3'	239
<i>TGF-β2</i>	NM_003238.3	5'AGATTTGCAGGTATTGATGG 3'	5'ATTTCTAAAGCAATAGGCCG 3'	192
<i>ELN</i>	NM_000501.3	5'TAAAGCAGCTAAATACGGTG 3'	5'AGGAAGCTCATTTTCTCTTC 3'	167
<i>COL1A1</i>	NM_000088.3	5'GCTATGATGAGAAATCAACCG 3'	5'TCATCTCCATTCTTCCAGG 3'	199
<i>SPARC</i>	NM_003118.3	5'AGTATGTGTAACAGGAGGAC 3'	5'AATGTTGCTAGTGTGATTGG 3'	143
<i>LOX</i>	NM_002317.6	5'ACGGCACTGGCTACTTCCAGTA 3'	5'TCTGACATCTGCCCTGTATGCT 3'	158
<i>LOXL2</i>	NM_002318.2	5'ACTGCAAGCACACGGAGGA 3'	5'AGGTTGAGAGGATGGCTCGA 3'	144
<i>α-SMA</i>	NM_001613.3	5'ACTGGGACGACATGGAAAAG 3'	5'TACATGGCTGGACATTGAA 3'	166
<i>DCN</i>	NM_001920.4	5'TCAAGTGACTTCTGCCACC 3'	5'GAGCGCACGTAGACACATCT 3'	128
<i>18S rRNA</i>	NR_003286.2	5'AACCCGTTGAACCCATT 3'	5'CCATCCAATCGGTAGTAGCG 3'	149

0.002) (Fig. 1A). *CTGF* was significantly increased in PACG ($P = 0.007$) with a nonsignificant increase in POAG compared with cataract control (Fig. 1B). *TGF-β1* was significantly elevated in PACG compared with control ($P = 0.01$) and compared with POAG ($P = 0.02$). *TGF-β2* was significantly increased in POAG ($P = 0.02$) and PACG compared with control ($P = 0.01$) (Figs. 1C, 1D). Increased expression of ECM modifying molecule *CTGF*, *TGF-β1*, and *TGF-β2* indicate predisposition to fibrosis.

mRNA Expression of ECM Remodeling Genes in Human Tenon's Tissue

We next evaluated the expression of the crucial genes of the ECM. *LOX* and *LOXL2* were increased in PACG ($P = 0.007$, $P = 0.03$) (Figs. 2A, 2B), likewise *ELN* and *COL1A1* were significantly increased in PACG ($P = 0.005$, $P = 0.04$) compared with control (Figs. 2C, 2D). Additionally *LOX* and *ELN* were significantly increased in PACG compared with POAG ($P = 0.03$, $P = 0.02$). *LOX*, *LOXL2*, *ELN*, and *COL1A1*, although increased in POAG, were not statistically significant. *SPARC* the matricellular protein was significantly increased in POAG and PACG ($P = 0.03$, $P = 0.008$) compared with control adding further evidence for the augmented matrix aberration in glaucomatous tenon's tissue.

mRNA Expression of Profibrotic and Antifibrotic Genes in Human Tenon's Tissue

The profibrotic gene *α-SMA* was increased significantly in PACG ($P = 0.02$) compared with cataract controls and in comparison with POAG ($P = 0.002$) (Fig. 3A). On the contrary, the antifibrotic gene *DCN* had a significantly decreased expression in POAG ($P = 0.01$) and PACG ($P = 0.005$) compared with cataract control (Fig. 3B).

As the number of patients with diabetes in POAG and cataract was twice when compared with PACG, we segregated the measured parameters into subgroups as with and without diabetes. The observations after segregating were similar with significance in *MCP-1*, *CTGF*, *TGF-β1*, *LOX*, *COL1A1*, and *SPARC* in POAG and PACG with diabetes (Supplementary Table S1). Among the cataract controls, *TGF-β2* alone displayed a significant increase in the diabetic cataract control group compared with nondiabetic cataract control.

Growth Factors and ECM Remodeling Protein Levels Increased in POAG and PACG Aqueous Humour

The AH concentrations of *CTGF* ($P = 0.02$, $P = 0.01$), *TGF-β1* ($P = 0.01$, $P < 0.001$), *TGF-β2* ($P = 0.002$, $P < 0.001$), *ELN* (P

$= 0.03$, $P = 0.01$), *SPARC* ($P = 0.02$, $P < 0.001$), and *LOXL2* ($P = 0.04$, $P = 0.03$) were significantly higher in POAG and PACG, respectively, compared with cataract control. Besides *SPARC* showed significant increase in PACG ($P = 0.04$) compared with POAG (Figs. 4A–4F). In contrast to the above, decorin concentrations were significantly reduced in POAG ($P = 0.03$) and PACG ($P = 0.007$) compared with cataract control (Fig. 4G). In the segregated analysis based on diabetes, we observed a similar trend in the protein levels (Supplementary Table S2). However, we did not observe significant increase in *TGF-β2* as seen in Tenon's tissue in the diabetic cataract control group. This could be due to the fact that the source of *TGF-β* is from two different ocular tissues. AH *TGF-β* is from the composite secretion of ciliary body, iris, and TM, whereas in the Tenon's tissue it is from the fibroblast and hence there could be differences in the level of transcription.

Effect of Preoperative AGMs on Specific Protein and Transcript Level

As seen in Table 1, most of the glaucoma patients are being administered with multiple AGMs. We examined the association of preoperative AGMs with the concentrations of the measured parameters. For this analysis, we selected all glaucoma patients (POAG and PACG) who were on AGMs and segregated them based on duration of medications as <1 , >1 to 4, >4 to 10, and >10 years (arrived based on the interquartile range of the duration of AGMs). We observed that with increase in duration of >10 years on AGMs, *TGF-β1* ($P = 0.03$), *TGF-β2* ($P = 0.0003$), *SPARC* ($P = 0.0002$), and *LOXL2* ($P = 0.007$) showed significant increase compared with control. *CTGF* ($P = 0.004$), *TGF-β1* ($P = 0.01$), *ELN* ($P = 0.03$), and *SPARC* ($P = 0.004$) showed an increase in <1 -year duration of AGMs. On the other hand, *DCN* was associated with a significant decrease in >1 - to 4-year ($P = 0.03$), >4 - to 10-year ($P = 0.009$), >10 -year ($P = 0.02$) durations of AGMs (Fig. 5). Similar to protein, the transcripts of *TGF-β1*, *TGF-β2*, *LOX*, *ELN*, *COL1A1*, and *SPARC* was increased, and *DCN* was decreased in Tenon's tissue with the duration of >10 years on AGMs (Supplementary Table S3).

Postoperative Bleb Status Showed Association With Specific Protein and Transcript Levels

As part of routine clinical care, postoperative examination are done by the surgeon by performing a slit lamp examination. They grade the bleb empirically based on morphological appearance as shallow, diffuse, flat, and cystic, and assess the bleb leakage by Seidel test. Postoperative bleb outcome at ≥ 6

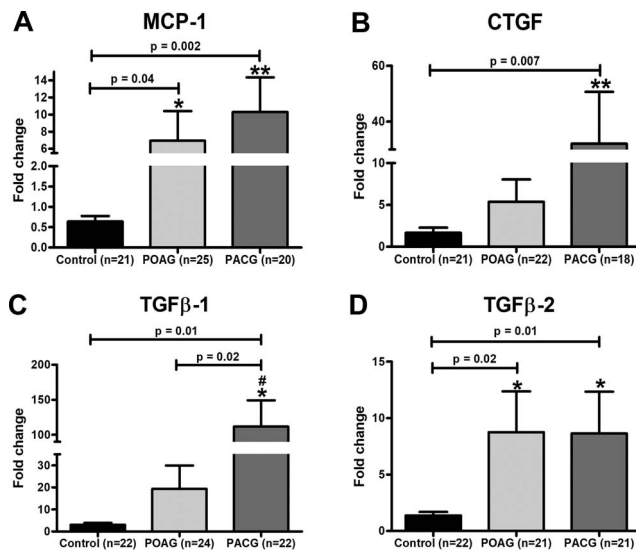


FIGURE 1. mRNA expression of inflammatory cytokine and growth factor genes in tenon's tissue. The panels show increased transcript levels of (A) *MCP-1*, (B) *CTGF*, (C) *TGF-β1*, and (D) *TGF-β2* in PACG and POAG tenon's tissue compared with cataract controls. Data are presented as a fold change over *18S rRNA*. Data were analyzed by nonparametric multiple comparisons, Kruskal-Wallis test followed by Mann-Whitney *U* test for statistical analysis. **P* < 0.05; ***P* < 0.01 compared with control; #*P* < 0.05 compared with POAG.

months' time point was used for this analysis. We observed that *CTGF*, *TGF-β1/β2*, *ELN*, *SPARC*, and *LOXL2* to be elevated in patients who had diffuse/shallow bleb outcome, whereas *CTGF* and *SPARC* were increased in patients who had an outcome of cystic bleb. *TGF-β1/β2* and *SPARC* were increased in patients who had an outcome of flat bleb (Figs. 6A–F). *DCN* showed significantly lowered protein levels in patients with diffuse/shallow and cystic bleb with an insignificant decrease in patients who had a flat bleb outcome compared to control (Fig. 6G). At the level of transcript in Tenon's tissue, increased *MCP-1*, *TGF-β2*, and *SPARC* were associated with flat bleb outcome, with decreased *DCN* in diffuse and cystic bleb outcome (Supplementary Table S4).

DISCUSSION

Enormous evidence suggests that there is an aberrant accrual of ECM components in TM, AH, ONH, and lamina cribrosa (LC) attributing to the pathology in glaucoma.^{29–32} Tenon's fibroblasts are the primary effector cells in the initiation and mediation of wound healing and fibrotic scar formation posttrabeculectomy.³³ In our gene and protein expression study, we found evident elevations of genes, that is, *MCP-1*, *CTGF*, *TGF-β1/2*, *LOX*, *LOXL2*, *ELN*, *COL1A1*, *SPARC*, and *α-SMA* compared with cataract control in POAG and PACG. Recent studies show diabetes to be associated with an increased risk of glaucoma.³⁴ In addition to this, we found that POAG and PACG patients with diabetes displayed an elevated expression of these parameters attributing the influence of diabetes.

Many studies have demonstrated elevated levels of inflammatory cytokines in the AH of glaucomatous eyes.³⁵ The induction of proinflammatory cytokines is due to the impairment of the blood-aqueous barrier and infiltration of inflammatory cells that secrete cytokines.³⁶ Moreover, chronic use of AGMs is reported to cause inflammation.³⁷ Kawai et al.³⁶ have reported that elevated levels of *MCP-1* as a risk factor for trabeculectomy failure. We also observed elevated *MCP-1*

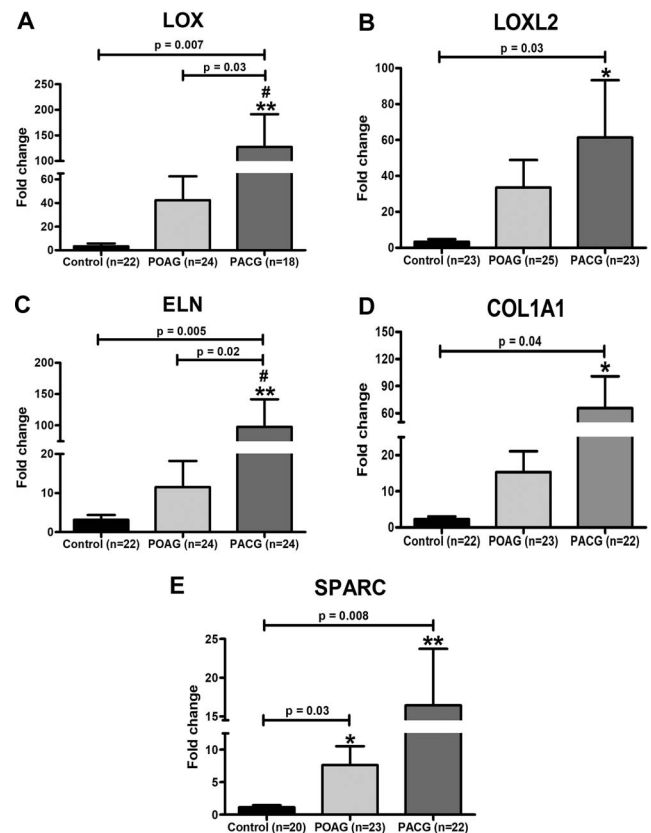


FIGURE 2. mRNA expression of ECM remodeling genes in tenon's tissue. The panel shows elevated transcript levels of (A) *LOX*, (B) *LOXL2*, (C) *ELN*, (D) *COL1A1*, and (E) *SPARC* in PACG and POAG tenon's compared with cataract controls. Data are presented as a fold change over *18S rRNA*. Data were analyzed by nonparametric multiple comparisons, Kruskal-Wallis test followed by Mann-Whitney *U* test for statistical analysis. **P* < 0.05; ***P* < 0.01 compared with control; #*P* < 0.05 compared with POAG.

expression in Tenon's tissue of glaucoma when compared with controls.

TGF-β has been the focus of glaucoma research for many years, as promising treatment strategies are being explored by inhibiting the pivotal role of *TGF-β* in the scarring process.^{18,38,39} It is considered that *TGF-β1* and *β2* classically stimulate scarring by a net increase in ECM,^{15,40} while simultaneously suppressing ECM proteolysis and breakdown.

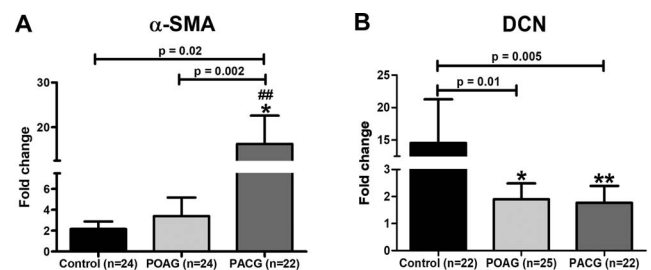


FIGURE 3. mRNA expression of the profibrotic and antifibrotic gene in tenon's tissue. A higher level of (A) *α-SMA* and lower expression of (B) *DCN* was observed in POAG and PACG eyes compared with cataract controls. Data are presented as a fold change over *18S rRNA*. Data were analyzed by nonparametric multiple comparisons, Kruskal-Wallis test followed by Mann-Whitney *U* test for statistical analysis. **P* < 0.05; ***P* < 0.01 compared with control. ##*P* < 0.01 compared with POAG.

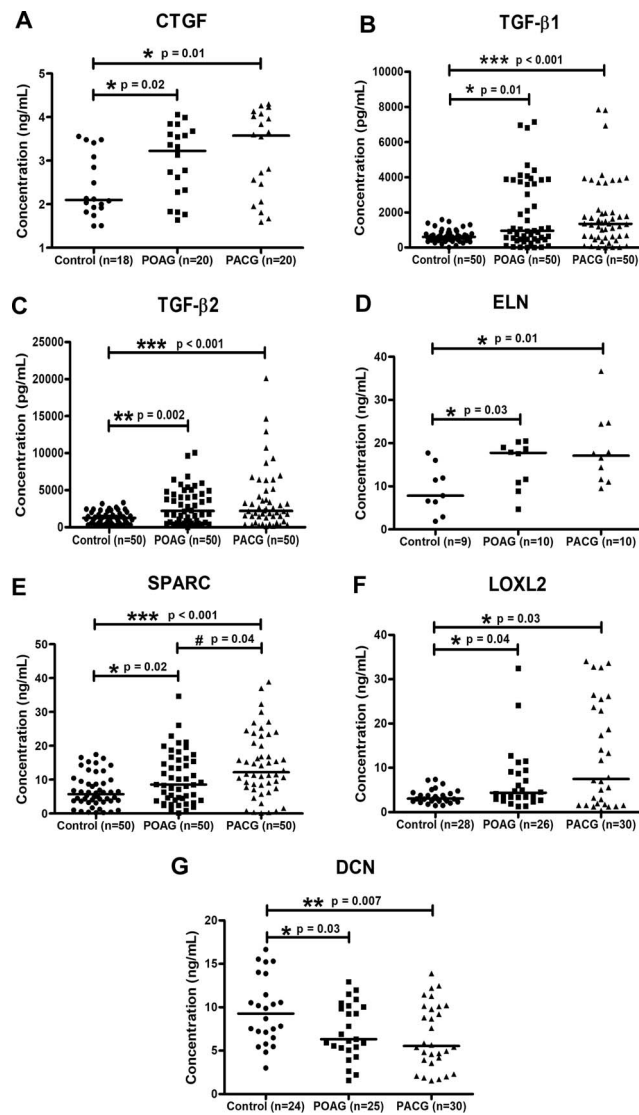


FIGURE 4. Protein expression of growth factors and ECM remodeling in AH. The panels show vertical scatter plot of ELISA (A) CTGF (B) TGF-β1, (C) TGF-β2, (D) ELN, (E) SPARC, (F) LOXL2, and (G) DCN in AH samples between cataract control, POAG, and PACG groups. Data were analyzed by nonparametric multiple comparisons, Kruskal-Wallis test followed by Mann-Whitney *U* test for statistical analysis. **P* < 0.05; ***P* < 0.01; ****P* < 0.001 compared with control; #*P* < 0.05 compared with POAG.

Similarly TGF-β's downstream mediator CTGF is actively involved in the pathogenesis of glaucoma. CTGF either alone or with TGF-β can induce ECM changes in the TM.⁴¹ We demonstrated elevated TGF-β1, TGF-β2, along with CTGF levels in AH and Tenon's tissue corroborating the earlier findings.⁴² CTGF is overexpressed in filtration blebs, signifying a vital role in the process of scarring after trabeculectomy. It acts as a mitogen in fibroblasts and causes overexpression of the ECM.¹⁶ We observed elevated TGF-β1 and TGF-β2 to be associated with flat bleb morphology. The use of CTGF antibody was recently reported to significantly decrease the expression of the profibrotic ECM genes in the glaucomatous TM and LC.⁴³

LOX also causes upregulation of TGF-β, thereby magnifying the fibrosis process.¹⁷ TGF-β, in turn, can increase LOX expression, resulting in ECM remodeling in human ocular fibroblasts.⁴⁴ LOX and LOXL2 are overexpressed in Tenon's

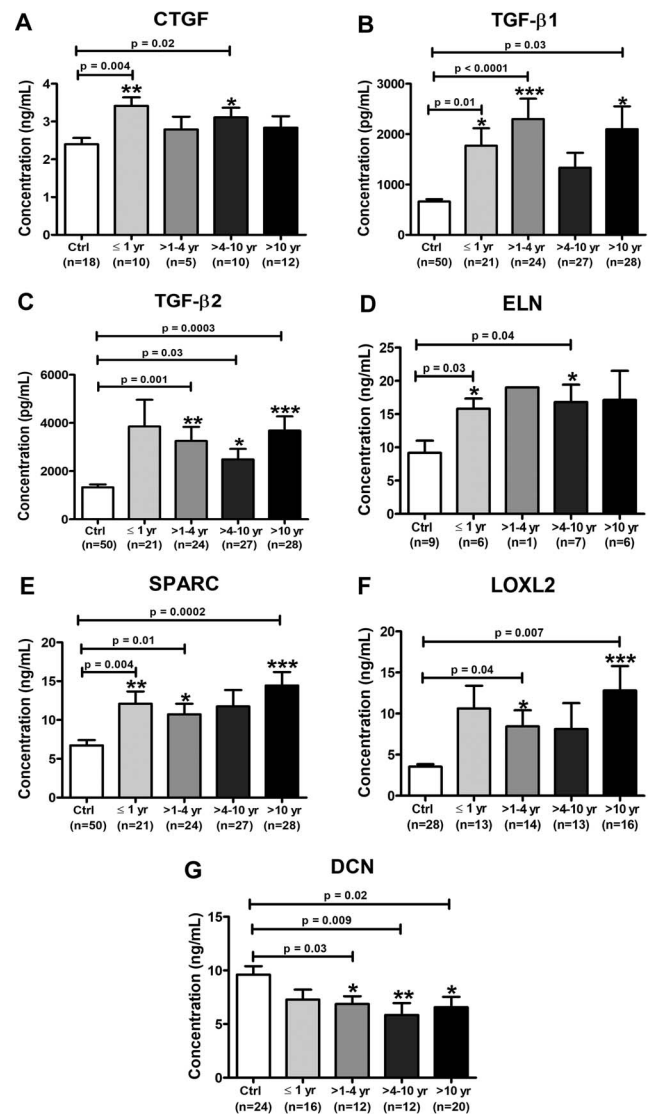


FIGURE 5. Effect of duration of preoperative AGMs on specific protein levels in AH proteins. The panels show protein levels (A) CTGF (B) TGF-β1, (C) TGF-β2, (D) ELN, (E) SPARC, (F) LOXL2, and (G) DCN in AH samples with duration (years) of preoperative medications. Data were analyzed by nonparametric multiple comparisons, Kruskal-Wallis test followed by Mann-Whitney *U* test for statistical analysis. **P* < 0.05; ***P* < 0.01; ****P* < 0.001.

capsule⁴⁵ with LOXL2 being associated with poor glaucoma surgical outcomes.⁴⁶ Addition of anti-LOXL2 (GS-607601) in rabbits undergoing glaucoma surgery reduced inflammation as well as fibrosis and prolonged bleb survival.⁴⁵ Thus, LOXL2 is another promising therapeutic target for reduced scar formation posttrabeculectomy. We found that LOX, LOXL2, along with ELN were increased in AH and Tenon's exhibiting the fact of pronounced ECM accumulation in glaucomatous eyes.

In addition to this, TGF-β1 induces the expression of type I collagen and SPARC.⁴² In the present study, we observed an increased expression of SPARC and collagen in tenon's tissue. In scarred human Tenon's capsule, increased expression of SPARC was found localized to the ECM and blood vessel walls.⁴⁷ There are reports that SPARC null-mice shows promising results by enhancing AH outflow⁴⁸ as well as reduce fibrosis and scarring in the animal model following GFS. A core function of SPARC is to regulate collagen I incorporation into

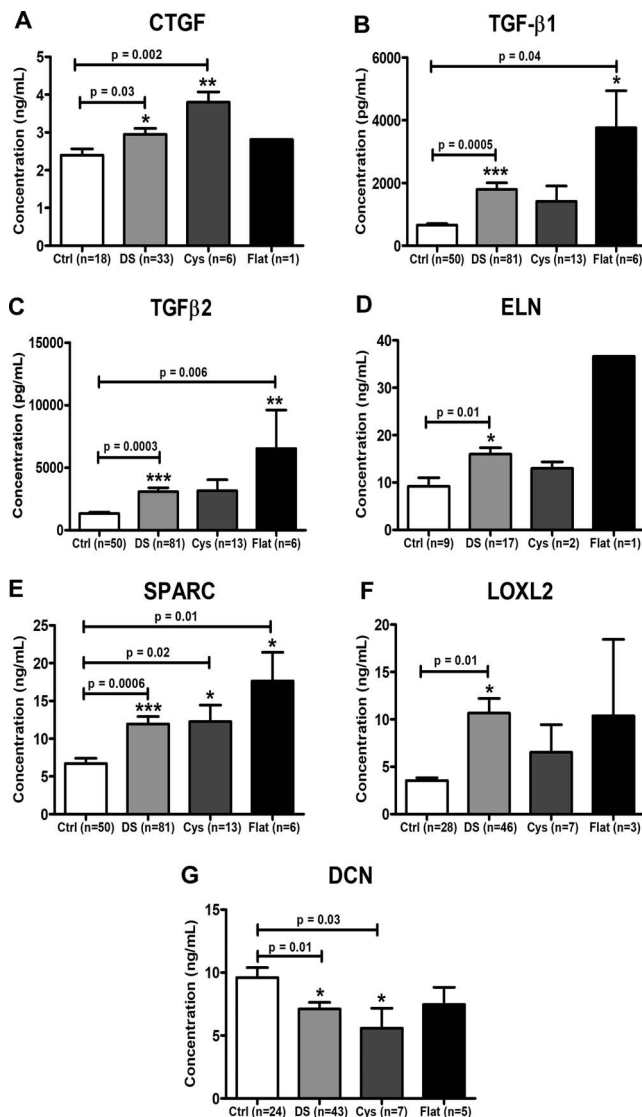


FIGURE 6. Effect of AH proteins on postoperative bleb status (≥ 6 months' time point). The panels show protein levels (A) CTGF, (B) TGF- β 1, (C) TGF- β 2, (D) ELN, (E) SPARC, (F) LOXL2, and (G) DCN in AH samples with diffuse and shallow (DS), cystic, and flat bleb group compared with control. There was a significant increase in TGF- β 1, TGF- β 2, and SPARC of flat bleb group compared with control. Data were analyzed by nonparametric multiple comparisons, Kruskal-Wallis test followed by Mann-Whitney U test for statistical analysis. * $P < 0.05$; ** $P < 0.01$; *** $P < 0.001$.

tissues and is considered as a chaperone for promoting collagen folding, secretion, maturation, and assembly into macromolecules in the ECM.^{49,50} The proinflammatory condition induced by prolonged use of topical medications has been reported to account for an elevation of SPARC expression in POAG and PACG iris.⁴⁹ This study further reveals increased SPARC with the durations of AGMs, possibly contributing to a profibrotic response.

Studies reveal that differentiation of fibroblasts to myofibroblasts produces α -SMA, a profibrotic protein that leads to extensive and uncontrolled matrix contraction.⁵¹ Our study additionally revealed increased α -SMA transcript levels in glaucoma. Amidst these augmented inflammatory and matrix modulators, decorin, a small proteoglycan and an endogenous antagonist that can bind to both TGF- β and CTGF,²⁴ was

significantly decreased in AH as well as in tenon's tissue. In the eye, decorin is present in the cornea,⁵² retina,⁵³ and TM.⁵⁴ Decorin is bound to the ECM and can scavenge TGF- β s directly, preventing its receptor interaction, thereby reducing corneal haze.²⁵ Grisanti et al.²² reported that decorin significantly decreased IOP levels and postsurgical fibrosis in a GFS model of rabbit, wherein no adverse effects, such as inflammation was observed.^{45,55} Recently, lowered decorin levels were reported in leaky blebs as the ECM in this region was sparse and hypocellular.⁵⁶ Decorin formulation has shown promising outcomes in the murine model showing reduced corneal opacity with antiscarring properties in patients with microbial keratitis.⁵⁷ The finding that decorin is lowered in Tenon's fibroblast and AH before surgery opens avenues for investigating decorin as a biomarker or as a therapeutic target to enhance its levels in patients undergoing trabeculectomy.

To the best of our knowledge, this is the first report to study specific proteins in patients with POAG and PACG. We also measured the levels of ELN, SPARC, and DCN in AH, which were not investigated in earlier studies. We showed that long-term AGMs were associated with elevated levels of TGF- β 1/ β 2, SPARC, and LOXL2 with lowered DCN. It appears that TGF- β 1/ β 2, CTGF, and SPARC with decreased DCN are more associated with cystic or flat bleb morphology in combination with other factors.

In conclusion, a decreased aqueous level of decorin and its expression in tenon's is a striking new finding in glaucoma. Although the exact reason for this decrease is unclear, we believe that administering decorin in prior treatment would help in further improving the surgical success by minimizing postoperative scarring.

Some potential constraints in our study are that failed bleb tissues or AH obtained during retractorabeculectomy were not analyzed. We faced difficulties during RNA isolation from Tenon's owing to the small size of the specimen with elastic nature.⁵⁸ A major impediment of testing AH is that only small sample volumes (25–100 μ L) can be collected from the human eyes; this is rarely adequate to test all proteins in the same sample.

CONCLUSION

This study reveals that glaucomatous group had increased expression of protein and transcript levels of MCP-1, CTGF, TGF- β 1/2, LOX, LOXL2, ELN, COL1A1, SPARC, and α -SMA in both POAG and PACG. There is an insistent demand for developing new therapies/drugs for reducing fibrosis induced by wound healing responses in the tissue surrounding the surgically treated area. Decreased aqueous levels of decorin is a notable new finding in glaucoma. We believe that administering decorin in prior treatment would help in further improving the surgical success by minimizing postoperative scarring.

Acknowledgment

Supported by funding from the Indian Council of Medical Research (ICMR: 5/4/6/4/Oph/12-NCD-II).

Disclosure: S. NikhalaShree, None; G. Karthikkeyan, None; R. George, None; B. Shantha, None; L. Vijaya, None; V. Ratra, None; K.N. Sulochana, None; K. Coral, None

References

1. Quigley H, Broman A. The number of people with glaucoma worldwide in 2010 and 2020. *Br J Ophthalmol.* 2006;90:262–267.

2. Rieck J. The pathogenesis of glaucoma in the interplay with the immune system. *Invest Ophthalmol Vis Sci.* 2013;54:2393-2409.
3. Pascolini D, Mariotti SP. Global estimates of visual impairment: 2010. *Br J Ophthalmol.* 2012;96:614-618.
4. Tham YC, Li X, Wong TY, Quigley HA, Aung T, Cheng CY. Global prevalence of glaucoma and projections of glaucoma burden through 2040: a systematic review and meta-analysis. *Ophthalmology.* 2014;121:2081-2090.
5. George R, Vijaya L. Prevalence of glaucoma in India: a review. *J Curr Glaucoma Pract.* 2007;1:7-11.
6. George R, Ve RS, Vijaya L. Glaucoma in India: estimated burden of disease. *J Glaucoma.* 2010;19:391-397.
7. Weinreb RN, Aung T, Medeiros FA. The pathophysiology and treatment of glaucoma: a review. *JAMA Clin Rev Educ.* 2014;311:1901-1911.
8. Goel M, Renata P, Lee R, Bhattacharya S. Aqueous humor dynamics: a review. *Open Ophthalmol J.* 2010;4:52-59.
9. Schwartz K, Budenz D. Current management of glaucoma. *Curr Opin Ophthalmol.* 2004;15:119-126.
10. Diggory P, Franks W. Medical treatment of glaucoma: a reappraisal of the risks. *Br J Ophthalmol.* 1996;80:85-89.
11. Schuman JS. Antiglaucoma medications: a review of safety and tolerability issues related to their use. *Clin Ther.* 2000;22:167-208.
12. Yoshiaki K, Kawase K, Matsushita H, Minobe M. Trabeculectomy with MMC: a comparative study with fluorouracil. *Arch Ophthalmol.* 1991;109:1693-1698.
13. Addicks EM, Quigley HA, Green WR, Robin AL. Histologic characteristics of filtering blebs in glaucomatous eyes. *Arch Ophthalmol.* 1983;101:795-798.
14. Fuchshofer R, Tamm ER. The role of TGF- β in the pathogenesis of primary open-angle glaucoma. *Cell Tissue Res.* 2012;347:279-290.
15. Prendes MA, Harris A, Wirostko BM, Gerber AL, Siesky B. The role of transforming growth factor β in glaucoma and the therapeutic implications. *Br J Ophthalmol.* 2013;97:680-686.
16. Esson DW, Neelakantan A, Iyer SA, et al. Expression of connective tissue growth factor after glaucoma filtration surgery in a rabbit model. *Invest Ophthalmol Vis Sci.* 2004;45:485-491.
17. Atsawasuwan P, Mochida Y, Katafuchi M, et al. Lysyl oxidase binds transforming growth factor- β and regulates its signaling via amine oxidase activity. *J Biol Chem.* 2008;283:34229-34240.
18. Mead AL, Wong TTL, Cordeiro MF, Anderson IK, Khaw PT. Evaluation of anti-TGF- β 2 antibody as a new postoperative anti-scarring agent in glaucoma surgery. *Invest Ophthalmol Vis Sci.* 2003;44:3394-3401.
19. Wang J-M, Hui N, Fan YZ, Xiong L, Sun N-X. Filtering bleb area and intraocular pressure following subconjunctival injection of CTGF antibody after glaucoma filtration surgery in rabbits. *Int J Ophthalmol.* 2011;4:480-483.
20. Van Bergen T, Marshall D, Van de Veire S, et al. The role of LOX and LOXL2 in scar formation after glaucoma surgery. *Invest Ophthalmol Vis Sci.* 2013;54:5788-5796.
21. Hill LJ, Ahmed Z, Logan A. Decorin treatment for reversing trabecular meshwork fibrosis in open-angle glaucoma. *Neural Regen Res.* 2016;11:922-923.
22. Grisanti S, Szurman P, Warga M, et al. Decorin modulates wound healing in experimental glaucoma filtration surgery: a pilot study. *Invest Ophthalmol Vis Sci.* 2005;46:191-196.
23. Hill LJ, Mead B, Blanch RJ, et al. Decorin reduces intraocular pressure and retinal ganglion cell loss in rodents through fibrolysis of the scarred trabecular meshwork. *Invest Ophthalmol Vis Sci.* 2015;56:3743-3757.
24. Vial C, Gutierrez J, Santander C, Cabrera D, Brandan E. Decorin interacts with connective tissue growth factor (CTGF)/CCN2 by LRR12 inhibiting its biological activity. *J Biol Chem.* 2011;286:24242-24252.
25. Mohan RR, Tandon A, Sharma A, Cowden JW, Tovey JCK. Significant inhibition of corneal scarring in vivo with tissue-selective, targeted AAV5 decorin gene therapy. *Invest Ophthalmol Vis Sci.* 2011;52:4833-4841.
26. Mohan RR, Gupta R, Mehan MK, Cowden JW, Sinha S. Decorin transfection suppresses profibrogenic genes and myofibroblast formation in human corneal fibroblasts. *Exp Eye Res.* 2010;91:238-245.
27. Nga AD, Yap S-L, Samsudin A, Abdul-Rahman PS, Hashim OH, Mimiwati Z. Matrix metalloproteinases and tissue inhibitors of metalloproteinases in the aqueous humour of patients with primary angle closure glaucoma: a quantitative study. *BMC Ophthalmol.* 2014;14:33.
28. Livak KJ, Schmittgen TD. Analysis of relative gene expression data using real-time quantitative PCR and the $2^{-\Delta\Delta CT}$ method. *Methods.* 2001;25:402-408.
29. Wallace DM, Brien CJO. The role of lamina cribrosa cells in optic nerve head fibrosis in glaucoma. *Exp Eye Res.* 2016;142:102-109.
30. Hernandez MR, Ye H. Glaucoma: changes in extracellular matrix in the optic nerve head. *Ann Med.* 1993;25:309-315.
31. Zhavoronkov A, Kanherkar RR, Izumchenko E, et al. Pro-fibrotic pathway activation in trabecular meshwork and lamina cribrosa is the main driving force of glaucoma. *Cell Cycle.* 2016;15:1643-1652.
32. Wallace DM, Pokrovskaya O, O'Brien CJ. The function of matricellular proteins in the lamina cribrosa and trabecular meshwork in glaucoma. *J Ocul Pharmacol Ther.* 2015;31:386-395.
33. Wang X, Fan YZ, Wang JM. Anti-proliferative effect of olmesartan on Tenon's capsule fibroblasts. *Int J Ophthalmol.* 2016;9:669-676.
34. Zhao Y, Chen X. Diabetes and risk of glaucoma: systematic review and a meta-analysis of prospective cohort studies. *Int J Ophthalmol.* 2017;10:1430-1435.
35. Du S, Huang W, Zhang X, Wang J, Wang W, Lam DSC. Multiplex cytokine levels of aqueous humor in acute primary angle-closure patients: fellow eye comparison glaucoma. *BMC Ophthalmol.* 2016;16:6.
36. Kawai M, Inoue T, Inatani M, et al. Elevated levels of monocyte chemoattractant protein-1 in the aqueous humor after phacoemulsification. *Invest Ophthalmol Vis Sci.* 2012;53:7951-7960.
37. Cvenkel B, Natasa A, Ihan A. Inflammatory molecules in aqueous humour and on ocular surface and glaucoma surgery outcome. *Mediators Inflamm.* 2010;2010:939602.
38. Cordeiro MF. Beyond mitomycin: TGF- β and wound healing. *Prog Retin Eye Res.* 2002;21:75-89.
39. Pfeiffer N, Voykov B, Renieri G, et al. First-in-human phase I study of ISTH0036, an antisense oligonucleotide selectively targeting transforming growth factor beta 2 (TGF- β 2), in subjects with open-angle glaucoma undergoing glaucoma filtration surgery. *PLoS One.* 2017;12:e0188899.
40. McDonnell F, Brien CO, Wallace D. The role of epigenetics in the fibrotic processes associated with glaucoma. *J Ophthalmol.* 2014;2014:750459.
41. Junglas B, Yu AHL, Welge-lu U, Tamm ER, Fuchshofer R. Connective tissue growth factor induces extracellular matrix deposition in human trabecular meshwork cells. *Exp Eye Res.* 2009;88:1065-1075.
42. Junglas B, Kuespert S, Seleem AA, et al. Connective tissue growth factor causes glaucoma by modifying the actin cytoskeleton of the trabecular meshwork. *Am J Pathol.* 2012;180:2386-2403.

43. Cells LC, Wallace DM, Clark AF, et al. Anti-connective tissue growth factor antibody treatment reduces extracellular matrix production in trabecular meshwork and lamina cribrosa cells. *Invest Ophthalmol Vis Sci.* 2013;54:7836-7848.
44. Sethi A, Mao W, Wordinger RJ, Clark AF. Transforming growth factor- β induces extracellular matrix protein cross-linking lysyl oxidase (LOX) genes in human trabecular meshwork cells. *Invest Ophthalmol Vis Sci.* 2011;52:5240-5250.
45. Yu-Wai-Man C, Khaw PT. Developing novel anti-fibrotic therapeutics to modulate post-surgical wound healing in glaucoma: big potential for small molecules. *Expert Rev Ophthalmol.* 2015;10:65-76.
46. Park HYL, Kim JH, Park CK. Lysyl oxidase-like 2 level and glaucoma surgical outcomes. *Invest Ophthalmol Vis Sci.* 2014;55:3337-3343.
47. Fuchshofer R, Kottler UBU, Ohlmann AVA, et al. SPARC is expressed in scars of the Tenon's capsule and mediates scarring properties of human Tenon's fibroblasts in vitro. *Mol Vis.* 2011;17:177-185.
48. Swaminathan SS, Oh D, Kang MH, et al. Secreted protein acidic and rich in cysteine (SPARC)-null mice exhibit more uniform outflow. *Invest Ophthalmol Vis Sci.* 2013;54:2035-2047.
49. Chua J, Seet LF, Jiang Y, et al. Increased SPARC expression in primary angle closure glaucoma iris. *Mol Vis.* 2008;14:1886-1892.
50. Huang W, Fan Q, Wang W, Zhou M, Laties AM, Zhang X. Collagen: a potential factor involved in the pathogenesis of glaucoma. *Med Sci Monit Basic Res.* 2013;19:237-240.
51. Gabbiani G. The myofibroblast in wound healing and fibrocontractive disease. *J Pathol.* 2003;200:500-503.
52. Fumlerbiirgh JL, Hevelone ND, Roth MR, et al. Decorin and biglycan of normal and pathologic human corneas. *Invest Ophthalmol Vis Sci.* 1998;39:1957-1964.
53. Inatani M, Tanihara H, Honjo M, Hangai M, Kresse H, Honda Y. Expression of proteoglycan decorin in neural retina. *Invest Ophthalmol Vis Sci.* 1999;40:1783-1791.
54. Tanihara H, Ohira A, Takahashi M, Honda Y, Suzuki S. Localization and possible gene expression of proteoglycan decorin in the trabecular meshwork. *Curr Eye Res.* 1995;14:727-730.
55. Gubbiotti MA, Vallet SD, Ricard-Blum S, Iozzo RV. Decorin interacting network: a comprehensive analysis of decorin-binding partners and their versatile functions. *Matrix Biol.* 2016;55:7-21.
56. Al-Beshri AS, Edward DP, Al Haiti K, Craven ER. Overhanging-dissecting blebs: immunohistochemical characterization. *J Glaucoma.* 2018;27:450-454.
57. Hill LJ, Moakes RJA, Vareechon C, et al. Sustained release of decorin to the surface of the eye enables scarless corneal regeneration. *NPJ Regen Med.* 2018;23:1-12.
58. Mahale A, Othman MW, Al Shahwan S, et al. Altered expression of fibrosis genes in capsules of failed ahmed glaucoma valve implants. *PLoS One.* 2015;10:e0122409.