

# Macular Vessel Density Measured With Optical Coherence Tomography Angiography and Its Associations in a Large Population-Based Study

Qi Sheng You,<sup>1-3</sup> Jonathan C. H. Chan,<sup>1</sup> Alex L. K. Ng,<sup>1</sup> Bonnie K. N. Choy,<sup>1</sup> Kendrick C. Shih,<sup>1</sup> Janice J. C. Cheung,<sup>1</sup> Jasper K. W. Wong,<sup>1</sup> Jennifer W. H. Shum,<sup>1</sup> Michael Y. Ni,<sup>4</sup> Jimmy S. M. Lai,<sup>1</sup> Gabriel M. Leung,<sup>4</sup> Chui Ming Gemmy Cheung,<sup>5</sup> Tien Yin Wong,<sup>5</sup> and Ian Y. H. Wong<sup>1,6</sup>

<sup>1</sup>Department of Ophthalmology, LKS Faculty of Medicine, The University of Hong Kong, Hong Kong

<sup>2</sup>Beijing Institute of Ophthalmology, Beijing Tongren Eye Center, Beijing Tongren Hospital, Capital Medical University, Beijing

<sup>3</sup>Casey Eye Institute, Oregon Health & Science University, Portland, Oregon, United States

<sup>4</sup>School of Public Health, LKS Faculty of Medicine, The University of Hong Kong, Hong Kong

<sup>5</sup>Singapore National Eye Center, Singapore

<sup>6</sup>Department of Ophthalmology, Hong Kong Sanatorium & Hospital, Hong Kong

Correspondence: Ian Y. H. Wong, Department of Ophthalmology, LKS Faculty of Medicine, The University of Hong Kong, Room 301, Level 3, Block B, Cyberport 4, Pokfulam, Hong Kong; [ianyhwong@gmail.com](mailto:ianyhwong@gmail.com).

Submitted: July 31, 2019  
Accepted: October 10, 2019

Citation: You QS, Chan JCH, Ng ALK, et al. Macular vessel density measured with optical coherence tomography angiography and its associations in a large population-based study. *Invest Ophthalmol Vis Sci*. 2019;60:4830-4837. <https://doi.org/10.1167/iov.19-28137>

**PURPOSE.** We investigate macular perfusion and the systemic and ocular associations in a population-based setting.

**METHODS.** In this cross-sectional study, 2018 adults residing in Hong Kong underwent detailed ophthalmic examinations after consenting to participate. Macular perfusion was measured with optical coherence tomography angiography (OCTA) using the split-spectrum amplitude decorrelation angiography algorithm. The parafoveal flow index and vessel area density were quantified using automated custom-built software.

**RESULTS.** Of the 2018 participants, the OCTA measurements were available for 1940, and 1631 (84.1%) had good quality scans. The right eyes of these 1631 participants (43.1% men) were included for final analysis. Mean age was 49.8 years (range, 18–92 years). Mean global macular vessel density was 47.3% and 55.1% for the superficial and deep retinal layers, respectively. In multivariate analysis, lower superficial vessel density remained significantly associated with lower signal strength index (SSI;  $P < 0.001$ , standardized  $\beta = 0.607$ ) and male sex ( $P < 0.001$ ,  $\beta = 0.162$ ), and borderline associated with older age ( $P = 0.09$ ,  $\beta = -0.045$ ) and longer axial length (AL;  $P = 0.09$ ,  $\beta = -0.037$ ), while lower deep layer vessel density was significantly associated with lower SSI ( $P < 0.001$ , standardized  $\beta = 0.667$ ), longer AL ( $P < 0.001$ ,  $\beta = -0.097$ ), and higher creatinine ( $P < 0.001$ ,  $\beta = -0.072$ ).

**CONCLUSIONS.** This large population-based study provided normative OCTA data of macular vessel density and demonstrated that a lower superficial retinal vessel density was significantly associated with lower SSI and male sex, while a lower deep layer retinal vessel density was significantly associated with lower SSI, longer AL, and higher level of creatinine. These associations must be considered when interpreting clinical quantitative OCTA data.

**Keywords:** macular vessel density, Macular vascular density, optical coherence tomography angiography, OCTA

The vascular system of the retina is essential for maintenance of normal visual function. Quantitative and qualitative assessment of the retinal vascular system is fundamental in the management of various retinal and choroidal vascular diseases, such as diabetic retinopathy, retinal artery or vein occlusions, and neovascular age-related macular degeneration (AMD). Fluorescein angiography (FA) and indocyanine green angiography (ICGA) have been used clinically to evaluate the retinal and choroidal vasculature. However, these imaging methods are two-dimensional and cannot differentiate retinal and choroidal layer vessels. In addition, both imaging methods are invasive with the need for intravenous dye injection, and are associated with possible complications, including extravasation of dye, inadvertent intra-arterial injection, pruritus, nausea, temporary

skin discoloration, and life-threatening anaphylactic reactions.<sup>1,2</sup>

Optical coherence tomography angiography (OCTA) is a novel noninvasive imaging technology that uses intrinsic blood flow motion contrast to produce angiographic data across the retina and choroid.<sup>3-5</sup> Previous studies have demonstrated high intravisit repeatability and intervisit reproducibility for OCTA measurements of parapapillary and macular perfusion.<sup>6-10</sup> Using OCTA, macular vessel density in healthy volunteers recently was quantified and its associations with age, sex, and refractive errors were assessed.<sup>11-14</sup> Studies also showed the clinical applicability of OCTA for diagnosis and management of glaucoma, and retinal and choroidal diseases.<sup>5,15-20</sup> However, these were hospital-based studies with relatively few subjects and potential selection bias. A population-based, rather than a



hospital-based, investigation has the advantage of being free of potential selection bias induced by referring doctors. Accordingly, we conducted the current study to measure the macular vessel density in a large population-based setting to determine normative values and understand associated ocular and systemic factors.

## METHODS

The study adhered to the Declaration of Helsinki and was approved by the institutional review board of the University of Hong Kong. All participants provided written informed consent.

In the present study, subjects were selected from family cohort members who were residing in several districts in Hong Kong (available in the public domain at <https://familycohort.sph.hku.hk/en/>). The family cohort has a random sample of 19,533 subjects across Hong Kong who have been followed in the cohort since 2008, with known background demographic data available. The study design, cohort characteristics, inclusion and exclusion criteria of the family cohort have been reported previously.<sup>21</sup> As subjects come from all 18 districts of Hong Kong in the family cohort, we randomly selected four districts for subject recruitment in the current study: Tin Shui Wai (TSW), Sham Shui Po (SSP), Kwun Tong (KT), and Tseung Kwan O (TKO). All adults aged 18 or older, residing in these four districts and who agreed to participate in the study were eligible for recruitment. The exclusion criteria included pregnant or lactating women, and those unable to consent or cooperate with OCTA scans due to severe sickness or any other reason.

After obtaining written consent, subjects were interviewed in person to complete a structured questionnaire on their sociodemographic profile, smoking and alcohol consumption habits, dietary habits, family history of illnesses, and past medical history. The questionnaire also assessed the subjects' knowledge towards common eye diseases, including cataract, glaucoma, and AMD. The questionnaire was in Chinese and trained research assistants conducted the interview in Chinese. The height, weight, and hip and waist circumference of each subject were measured and recorded. Body-mass index (BMI) then was calculated using the formula: weight (kg) / square of height (m<sup>2</sup>). The body fat percentage was assessed using a bioelectrical impedance analyzer (Karada Scan HBF-356; Omron Corporation, Kyoto, Japan), while blood pressure and heart rate were measured with an automated sphygmomanometer (Hem-7000; Omron Corporation). Mean arterial pressure (MAP) was defined as the diastolic blood pressure plus one-third of the pulse pressure. The ocular perfusion pressure (OPP) was defined as MAP minus IOP. The right and left ankle-brachial index (ABI) were measured with a dedicated automatic device (MESI ABPI MD, MESI Ltd., Slovenia). Fasting blood samples were obtained via venipuncture for complete blood count, renal function test, cholesterol level, high-density lipoprotein (HDL), low-density lipoprotein (LDL), triglyceride, glycated hemoglobin (HbA1c), and C-reactive protein (CRP). Two additional 5 mL tubes of blood samples were obtained for building up a biobank. For study purposes, arterial hypertension was defined as a systolic blood pressure  $\geq 140$  mm Hg or a diastolic blood pressure  $\geq 90$  mm Hg, or self-reported current treatment of arterial hypertension with antihypertensive medication. Diabetes mellitus was defined as HbA1c  $\geq 6.5\%$  or a history of diagnosis of diabetes mellitus or of insulin or oral hypoglycemic agent treatment for diabetes.

An ocular examination was performed for each subject, including presenting visual acuity (PVA), best-corrected visual acuity (BCVA), automatic and subjective refraction, IOP, slit-

lamp examination of the anterior segment, and fundusoscopic examination of the posterior segment.

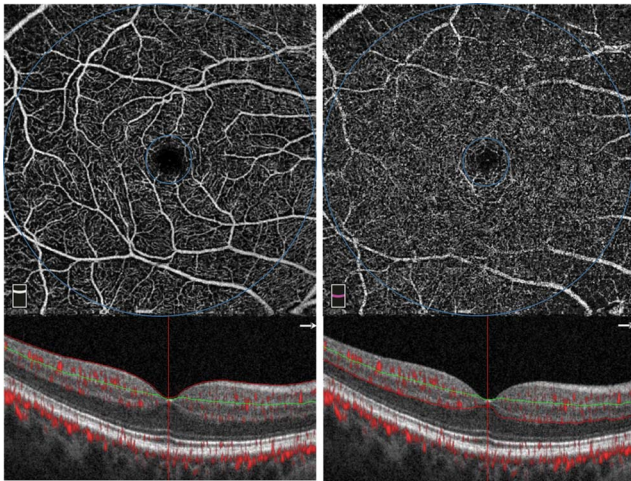
Visual acuity was tested using a logMAR chart (Lighthouse International, New York, NY, USA) at a distance of 4 m in a room with standardized illumination. PVA was measured with the subject's habitual glasses, if any. BCVA was measured with the best possible correction obtained with subjective refraction. IOP was measured with noncontact tonometry (NCT; TONOREF II; Nidek, Gamagori, Japan) three times and averaged to obtain the final value. Unreliable readings were discarded until three reliable readings were obtained.

Anterior segment examination was performed with a slit-lamp biomicroscope (SL-DC7 + DC4; Topcon, Oakland, NJ, USA), checking for any lid abnormalities (entropion, ectropion, lid mass, meibomian gland disorder), cornea status (clear or scar present), and presence of pterygium. A fluorescent stain then was applied to the ocular surface to assess for any punctate epithelial erosion, as well as tear break-up time. Following this, the pupils were dilated with phenylephrine hydrochloride 0.5%/tropicamide 0.5% (Mydrin-Pain; Santen, Osaka, Japan) to facilitate lens and posterior segment assessment. An image of each lens was captured using retroillumination and a slit-lamp mounted digital camera (Topcon) for the grading of any cataracts present, according to the Lens Opacity Classification System III (LOCS III). If the subject previously had cataract surgery, their lens status would be pseudophakic in the presence of an intraocular lens implant, or aphakic in the absence of a crystalline lens or intraocular lens implant. Posterior segment examination was performed by an ophthalmologist using binocular indirect ophthalmoscopy with a slit-lamp with a condenser lens (Digital Wide-Field Lens; Volk Optical, Inc., Mentor, OH, USA), while ultrawide field fundus photography (up to 200°) was recorded for each eye (Daytona Ultra-widefield Fundus Camera; Optos, Inc., Dunfermline, Scotland, UK). Keratometry, central corneal thickness, and white-to-white distance were obtained with a multi-purpose machine (OPD-Scan III Wavefront Aberrometer; Nidek), while the anterior chamber depth and axial length (AL) were measured with an ocular biometer (AL-Scan; Nidek).

OCTA was performed using a commercially available Avanti spectral-domain optical coherence tomography (SD-OCT) device (Optovue, Inc., Fremont, CA, USA) after pupil dilation. The device contained the AngioVue OCTA system (version 2017.1.0.151) and acquired volumetric OCTA scans of the central 6 × 6 mm macula area with a 304 × 304 A-scan sample density at an A-scan rate of 70-kHz and used the split-spectrum amplitude decorrelation angiography (SSADA) algorithm to generate angiograms.<sup>19,20</sup>

The automatically generated OCTA images were reviewed manually. Scans with a signal strength index (SSI)  $>50$  were included for quantitative analysis. Those with poor scan quality or obvious motion artifacts were excluded. The vessel density of the superficial and deep capillary networks was measured and assessed separately. The superficial retinal capillary network was set from 3  $\mu$ m below the internal limiting membrane to 15  $\mu$ m below the inner plexiform layer (IPL) and the deep capillary network was set from 15 to 70  $\mu$ m below the IPL. The vessel density was defined as the proportion of vessel area with blood flow over the total area measured (Fig. 1). Structural SD-OCT images were used for thickness measurement. The inner retinal thickness was measured from the internal limiting membrane (ILM) to the outer boundary of the inner nuclear layer. Full retinal thickness was measured from ILM to the outer boundary of the RPE.

Statistical analysis was performed using Statistical Package for Social Sciences software (SPSS for mac, version 25.0; IBM SPSS, Inc., Chicago, IL, USA). Descriptive statistics including mean, standard deviation (SD), median, range, and percentages



**FIGURE 1.** Illustration of OCTA measurement of macular vessel density on a  $6 \times 6$ -mm scan of a normal healthy participant. *Top* shows angiograms of the superficial (*left*) and deep (*right*) retinal layers. The *inner circle* (1-mm) demonstrates the central fovea. The *ring area* between the inner circle and outer circle (6-mm) was defined as the parafovea. *Bottom* demonstrates segmentation of the superficial (*left*) and deep (*right*) retinal layers located between the *horizontal red* and *green lines*. The *red dots* on bottom panel signify the blood flow signals on tomographic images.

were presented where appropriate. A paired *t*-test was used to compare the angiographic parameters between the right and left eyes. Since there was no significant difference in angiographic parameters between the two eyes, only the right eye of each participant was included in further analysis. The superficial and deep layer vessel densities are presented. In a second analytic step, we performed univariate linear regression analyses to determine the associations between the angiographic parameters and other ocular and systemic parameters. In a third step, we performed a multivariate analysis, with the angiographic parameters as dependent variables and with all those parameters that were associated with the angiographic parameters in the univariate analysis as independent variables. All *P* values were 2-sided and considered statistically significant if their values were  $<0.05$ .

## RESULTS

Of 2934 eligible subjects, 2018 (cooperation rate, 68.8%) entered into the survey from May 1, 2016 to December 31, 2017. Among these 2018 participants, 1940 (96.1%) underwent OCTA scans, 309 (15.9%) of which were excluded due to poor scan quality. The remaining 1631 (84.1%; 42.4% men, mean age  $\pm$  SD  $49.8 \pm 15.4$  years, range 18–90 years) participants with good quality OCTA scans were included for quantitative assessment. The prevalence of hypertension and diabetes mellitus was  $28.4 \pm 1.1\%$  and  $10.0 \pm 0.7\%$  respectively. For the right eye, mean BCVA was  $0.0 \pm 0.1$  logMAR (range,  $-0.3$ – $1.0$  logMAR), mean spherical equivalent (SE) refractive error was  $-1.3 \pm 2.9$  diopters (D; range,  $-16.3$ – $+9.8$  D), mean AL was  $24.3 \pm 1.4$  mm (range, 20.2–31.6 mm), and mean IOP was  $13.6 \pm 2.8$  mm Hg (range, 6.0–25.0). The prevalence of myopia (SE  $< -0.5$  D) and high myopia (SE  $< -6.0$  D or AL  $> 26.5$  mm) was  $51.4 \pm 1.2\%$  and  $12.3 \pm 0.8\%$ , respectively. The demographic characteristics and ocular parameters of the subjects are summarized in Table 1.

Compared to participants included for quantitative OCTA measurements, those excluded from the analysis due to lack of scan or insufficient image quality were significantly older

(mean age 49.8 vs. 61.6;  $P < 0.001$ ), with a significantly higher BMI (23.7 vs. 24.4;  $P = 0.003$ ), higher prevalence of diabetes mellitus (10.0% vs. 18.9%;  $P < 0.001$ ) and hypertension (28.4% vs. 46.8%;  $P < 0.001$ ), and higher prevalence of high myopia (12.3% vs. 25.6%;  $P < 0.001$ ), but did not vary significantly in sex proportion (43.1% vs. 43.2% male;  $P = 0.98$ ) and right eye IOP (13.6 vs. 13.4 mm Hg;  $P = 0.25$ ).

Mean superficial vessel density was 47.30%, 30.76%, and 49.21% for the whole measured area, central foveal area (central 1-mm diameter circle), and parafoveal area (1–6 mm diameter ring area), respectively. Mean superficial vessel density was highest in the superior quadrant (49.69%), followed by 49.54%, 49.19%, and 48.41% in the temporal, nasal, and inferior quadrants, respectively. The vessel density was higher in the deep retinal layer than in the superficial layer: 55.10%, 29.51%, and 59.35% for the whole measured area, central foveal area, and parafoveal area in the deep layer, respectively. In the deep retinal layer, it also was highest in the superior quadrant (59.94%), followed by 59.59%, 59.49%, and 58.41% in the nasal, inferior, and temporal quadrants, respectively. The superficial and deep layer vessel density for the different regions of the macula is summarized in Table 2.

The global vessel density of the whole measured area was significantly higher in women than in men in the superficial (47.91% vs. 46.50%;  $P < 0.001$ ) and deep (55.48% vs. 54.54%;  $P = 0.001$ ) layers (Fig. 2.) Mean global vessel density decreased significantly with aging starting from age 50, in the superficial and deep retinas. In the superficial layer, it was 47.65%, 48.53%, 48.64%, 47.53%, 46.24%, and 44.59% for age groups 18–29, 30–39, 40–49, 50–59, 60–69, and  $\geq 70$ , respectively ( $P < 0.001$ ), compared to 56.16%, 57.34%, 56.73%, 55.53%, 53.46%, and 50.08%, respectively, in the deep retinal layer ( $P < 0.001$ ). The retinal vessel density in the superficial and deep layers decreased 1.3% and 2.2%, respectively, every decade after 50 years of age (Table 3, Fig. 3).

In univariate linear regression analysis, lower superficial vessel density was significantly associated with older age, male sex, longer AL, worse BCVA, thinner inner retinal thickness, lower SSI, higher HbA1c level, higher MAP, higher creatinine level, and lower HDL level, but not significantly associated with smoking, drinking, heart rate, CRP level, triglyceride (TG) level, IOP, full retinal thickness, or central cornea thickness (CCT; Table 4, Figs. 4–6). In multivariate analysis, a lower superficial vessel density was still significantly associated with lower SSI and male sex, and borderline associated with older age and longer AL, while MAP, BCVA, inner retinal thickness, HbA1c level, creatinine, and HDL level were no longer significantly associated (Table 5).

In univariate linear regression analysis, lower deep retinal vessel density was significantly associated with lower SSI, older age, male sex, larger BMI, higher MAP, higher HbA1c, higher creatinine, worse BCVA, longer AL, and thinner inner retinal thickness and full retinal thickness, but not associated with smoking, drinking, cholesterol level, HDL, TG, heart rate, CRP, IOP, and CCT. In the multivariate model, a lower deep layer vessel density was still significantly associated with lower SSI ( $P < 0.001$ , standardized  $\beta = 0.667$ ), longer AL ( $P < 0.001$ ,  $\beta = -0.097$ ) and higher creatinine ( $P < 0.001$ ,  $\beta = -0.072$ ), but not significantly associated with the other parameters which were significant in univariate analysis.

## DISCUSSION

With the advantage of noninvasiveness, rapid scanning, and high resolution, OCTA is gaining widespread use in research and clinical assessment of patients.<sup>3,5</sup> Normative data are essential for quantitatively differentiating healthy from diseased

TABLE 1. Demographic and Ocular Characteristics (Right Eye) of the Study Population

Parameters	Mean	SD	Minimum	Maximum
Age (years)	49.8	15.4	18.0	90.0
Body height (cm)	161.6	8.6	137.0	185.7
Body weight (kg)	62.1	11.4	33.6	123.5
BMI	23.7	3.6	14.8	46.2
Systolic blood pressure (mm Hg)	124.3	18.7	80.0	217.0
Diastolic blood pressure (mm Hg)	75.5	11.3	43.0	143.0
IOP (mm Hg)	13.6	2.8	6.0	25.0
BCVA (logMAR)	0.0	0.1	-0.3	1.0
AL (mm)	24.3	1.4	20.2	31.6
CCT ( $\mu$ m)	546.0	39.2	399.0	669.0
OCT SSI	64.4	7.2	50.1	84.3
Cholesterol (mmol/L)	5.2	1.0	2.6	9.3
HDL (mmol/L)	1.6	0.6	0.7	19.5
TG (mmol/L)	1.9	1.5	0.3	21.9
LDL (mmol/L)	3.2	0.9	0.7	7.8
HbA1C (%)	5.8	0.7	4.1	12.6
Creatinine ( $\mu$ mol/L)	59.9	24.6	1.0	354.0
CRP (mg/L)	1.8	3.7	0.11	64.8
Sex (men)	692 (42.4%)			
Prevalence hypertension	28.4%			
Prevalence of diabetes mellitus	10.0%			
Prevalence of myopia	51.4%			
Prevalence of high myopia	12.3%			
Drinking proportion	699/1631 (42.9%)			
Smoking proportion	314/1631 (19.3%)			

status. Previous studies have reported normative macular vessel density data in healthy volunteers; however small, sample sizes and potential selection bias have precluded reliable assessment of systemic associations.<sup>11-14,22-24</sup> The current large-scale population-based study provides normative macular vessel density data measured with OCTA and its associations. The results showed that a lower superficial vessel density was significantly associated with older age, male sex, worse BCVA, longer AL, thinner inner retinal thickness, and higher HbA1c level. A lower deep layer vessel density was significantly associated with older age, worse BCVA, longer AL, thinner inner retina, and higher HbA1c level. These results should be considered when doing clinical studies with OCTA.

Mean macular capillary density found in the current study was slightly different but comparable with previous reports. Mean macular vessel density of the 1631 participants with a mean age of 50 (range, 18-92) years was 47.3% and 55.1% for the superficial and deep retinal layers, respectively. You et al.<sup>6</sup>

reported a mean global macular superficial vessel density of 53.8% in 15 healthy subjects with a mean age of 49 (range, 37-54) years, when measured and analyzed with the AngioVue system. In the study by Wang et al.,<sup>11</sup> 105 healthy participants with a mean age of 36 (range, 17-64) years were scanned with the AngioVue system. The images were exported and manually analyzed with Image J (National Institute of Health, Bethesda, MD, USA). Mean macular capillary vessel density was 45.8% and 44.4% for the superficial and deep retina layer, respectively.<sup>11</sup> Using the AngioVue system, Yu et al.<sup>13</sup> reported a parafoveal vessel density of 74.9% in 64 healthy Chinese subjects with a mean age of 38 (range, 20-62) years. However, as recently noted by Corvi et al.,<sup>8</sup> when comparing vessel density values, one must remember that different machines and even different versions of software might lead to different values, making the results not directly comparable or interchangeable.

TABLE 2. The Superficial and Deep Layer Macular Vessel Densities of Different Quadrants

	Global Vessel Density of Whole Image		Superior Hemi_Area	Inferior Hemi_Area	Temporal Quadrant	Superior Quadrant	Nasal Quadrant	Inferior Quadrant	
	Fovea	Para-Fovea							
Superficial layer (%)									
Mean	47.30	30.76	49.21	49.64	48.79	49.54	49.69	49.19	48.41
Median	47.76	30.81	49.89	50.28	49.39	50.25	50.39	50.00	48.77
SD	3.84	6.49	4.90	5.00	5.16	5.31	5.41	5.54	5.53
Minimum	31.83	10.22	34.27	30.60	31.74	27.34	30.53	27.26	28.30
Maximum	65.61	62.57	66.01	66.06	65.96	66.87	67.44	65.60	66.66
Deep layer (%)									
Mean	55.10	29.51	59.35	59.38	59.33	58.41	59.94	59.59	59.49
Median	55.92	29.04	59.94	60.05	60.11	59.24	60.82	60.28	60.37
SD	5.44	7.43	4.99	5.07	5.29	5.60	5.50	5.53	5.78
Minimum	26.14	8.84	29.83	31.87	27.77	22.56	24.15	24.00	27.80
Maximum	66.42	67.98	69.23	70.60	69.66	73.50	71.58	72.84	70.26

TABLE 3. The Global Superficial Macular Vessel Density Stratified by Age and Sex

Retina Layer	Age Group	N	Male and Female			Male				Female			
			Mean	95%CI for Mean		Mean	95% CI for Mean		Mean	95% CI for Mean			
				LB	UB		LB	UB		LB	UB		
Superficial	18-29	270	47.65	47.24	48.06	122	47.02	46.42	47.62	148	48.17	47.62	48.71
	30-39	149	48.53	47.98	49.08	58	48.12	47.20	49.05	91	48.79	48.10	49.48
	40-49	316	48.64	48.28	49.01	109	47.91	47.34	48.49	207	49.03	48.56	49.49
	50-59	492	47.53	47.20	47.86	212	46.87	46.35	47.40	280	48.02	47.61	48.44
	60-69	350	46.24	45.84	46.64	155	45.53	44.94	46.12	195	46.80	46.26	47.34
	70+	163	44.59	43.91	45.27	94	43.93	43.06	44.81	69	45.49	44.43	46.54
	Total	1740	47.30	47.12	47.48	750	46.50	46.22	46.78	990	47.91	47.68	48.14
Deep	18-29	270	56.16	55.58	56.75	122	55.66	54.74	56.57	148	56.58	55.83	57.33
	30-39	149	57.34	56.59	58.08	58	57.34	56.04	58.64	91	57.34	56.42	58.25
	40-49	316	56.73	56.20	57.26	109	56.61	55.64	57.57	207	56.79	56.15	57.42
	50-59	492	55.53	55.04	56.01	212	55.20	54.53	55.86	280	55.78	55.09	56.47
	60-69	350	53.46	52.89	54.03	155	53.10	52.23	53.97	195	53.74	52.99	54.49
	70+	163	50.08	49.15	51.01	94	49.85	48.63	51.07	69	50.39	48.91	51.87
	Total	1740	55.07	54.81	55.34	750	54.54	54.13	54.94	990	55.48	55.13	55.82

95% CI, 95% confidence interval; LB, lower bound; UB, upper bound.

Our finding that higher superficial and deep capillary densities were significantly associated with younger age were consistent with those of previous investigations. In addition to showing a general negative association between macular vessel density and age, with the advantage of a large study population and wide age range of subjects, we have demonstrated that vessel density was stable, or even slightly increased with aging, until age 50, at which point it started to decrease progressively at a rate of approximately 1.3% per decade (Table 2, Fig. 3).

In this study, superficial macular vessel density was higher in women than in men. Since men had a longer AL (24.5 vs. 24.1 mm;  $P < 0.001$ ) and older age (51.4 vs. 49.5 years;  $P = 0.01$ ) than women, we adjusted for age and AL in multivariate analysis. The results demonstrated that the association between lower vessel density and male sex remains significant even after adjustment for age and AL. The difference in superficial vessel density between men and women also remains significant after excluding the central 1-mm circle, which would cover the foveal avascular zone area. Mean parafoveal superficial vessel density was 49.8% in women and 48.3% in men ( $P < 0.001$ ). These results agreed with the study from Rao<sup>23</sup> and disagree with others. Borrelli et al.<sup>22</sup> reported a higher superficial vessel density in boys than in girls when measuring macular vessel densities with OCTA in children.

Wang et al.<sup>11</sup> demonstrated a higher superficial macular capillary density, but a lower deep macular capillary density in men than in women. Shahlaee et al.<sup>24</sup> reported no sex difference for macular vascular density measurements. The reason for the sex discrepancy among these studies remains unclear.

Another significant factor affecting macular vessel density was AL. Yang et al.<sup>25</sup> examined 33 highly myopic eyes and 47 mildly myopic or emmetropic eyes with OCTA, and found that microvessel density decreased significantly with AL. A significantly reduced retinal vessel density also was found in myopic eyes compared to healthy controls by several other groups.<sup>26-28</sup> These findings are consistent with our observation in this study in that the superficial and deep retinal vessel density decreases with AL, even after adjusting for age, sex, and inner retinal thickness. The impact of AL could be partially explained by the transverse magnification effect. A longer AL will lead to a larger scanning area in retina. Our recent study (unpublished) demonstrated that, away from central fovea, the superficial retinal vessel density increased from 0.3 to 1.5 mm. Starting from 1.5 mm outward, the superficial retinal vessel density decreased gradually in the temporal, superior, and inferior directions, while increasing in the nasal direction. On

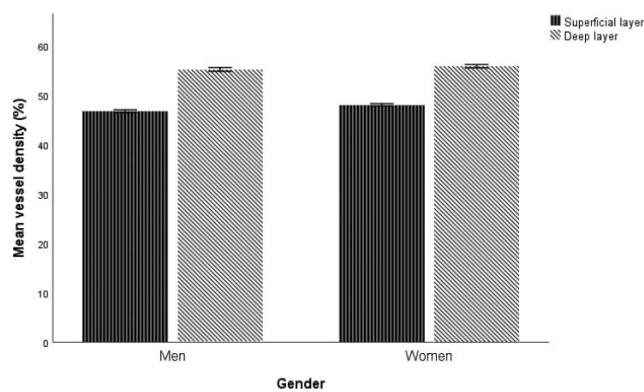


FIGURE 2. The overall vessel density measured with OCTA in 6 × 6-mm macular scan area was significantly higher in women ( $n = 939$ ) than in men ( $n = 692$ ) in the superficial and deep layers. Error bars: 95% confidence intervals.

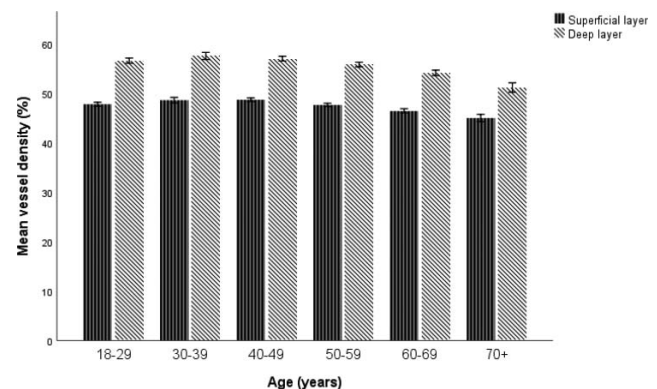


FIGURE 3. The overall vessel density measured with OCTA of the macular 6 × 6-mm scan area stratified by age. The vessel density was stable, or even slightly increased with aging, until age 50, at which point it started to decrease progressively. Error bars: 95% confidence intervals.

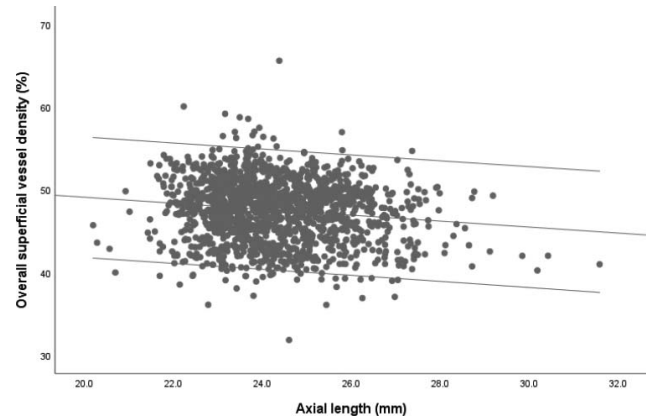
**TABLE 4.** Univariate Analysis of Superficial Macular Vessel Density Associations

Parameters	Standardized Coefficients $\beta$	P Value
Age	-0.219	<0.001
Sex	0.173	<0.001
AL	-0.135	<0.001
BCVA (logMAR)	-0.203	<0.001
Thickness of inner retina	0.116	<0.001
HbA1C	-0.143	<0.001
MAP	-0.115	<0.001
Creatinine	-0.099	<0.001
SSI	0.636	<0.001
HDL	0.062	0.014
Triglyceride	0.006	0.80
Cholesterol	0.033	0.20
Smoking or not	-0.026	0.30
BMI	-0.045	0.07
Drinking or not	-0.031	0.21
CRP	-0.013	0.64
HR	0.036	0.14
IOP	0.012	0.64
Thickness of total retina	0.013	0.60
CCT	0.007	0.79

HR, heart rate.

circular averaging, the superficial retinal vessel density decreased gradually from 1.5 mm outward away from central fovea. Considering that the peripheral edge of the 6 × 6-mm scan area has a lower superficial retinal vessel density and the transverse magnification effect of longer AL, it is understandable that the overall superficial retinal vessel density decreased with longer AL.

It is interesting to note that superficial and deep macular vessel densities were correlated with inner retinal thickness, but not with full retinal thickness, which is consistent with the findings of Yu et al.<sup>15</sup> This may be explained by the idea that the oxygen and nutrition demands of the inner retina are supplied by the central retinal arterial system, while those of the outer retina are mainly met by the choroidal vascular system, and partially by the deep retinal capillary plexus. It can be postulated that an increase in inner retinal thickness might lead to an increase in oxygen and nutrient demands, and hence, an increase retinal perfusion. Conversely, another

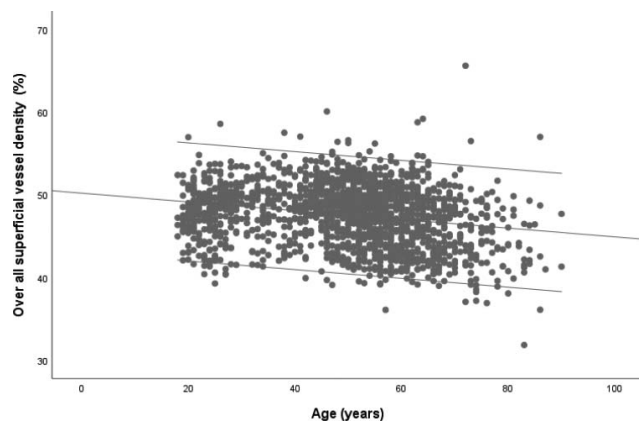


**FIGURE 5.** A Scatter plot demonstrates that the superficial retinal vessel density measured with OCTA on 6 × 6-mm macular scans decreased significantly with AL.

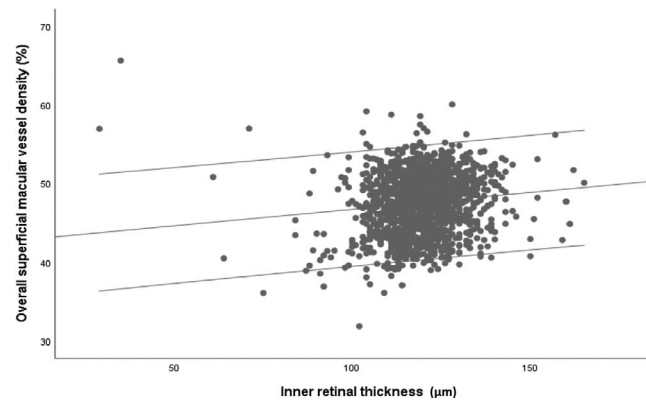
possible explanation is that an increase in superficial vessel density and volume can translate into an increase in inner retinal thickness.

It is noteworthy that, among all the parameters analyzed, SSI has the strongest impact on measured retinal vessel density. When we included SSI in the multivariate model, the lower superficial retinal vessel density was only significantly associated with lower SSI and male sex, not with other parameters, and the lower deep layer retinal vessel density was significantly associated with lower SSI, longer AL, and a higher level of creatinine. This result suggested that SSI must be taken into consideration when doing OCTA-measured retinal vessel density comparisons.

The current study has some limitations and some strengths. First, although the participation rates in this study are comparable with other population-based studies, the difference between participants and excluded subjects, as well as between subjects with gradable and ungradable OCTA, might still induce some selection bias. Second, despite OCTA providing an accurate method to measure the superficial retinal vessel density, the projection artifact embedded in the technology might lead to an overestimation of the deep retinal vessel density. The recently reported projection resolved algorithm might improve measurement precision in the future.<sup>19,29,30</sup> The strength of our study is that to our knowledge this is the first large population-based study



**FIGURE 4.** A scatter plot demonstrates that the superficial retinal vessel density measured with OCTA on 6 × 6-mm macular scans decreased significantly with age.



**FIGURE 6.** A scatter plot demonstrates that the overall superficial retinal vessel density measured with OCTA on 6 × 6-mm macular scans increased significantly with inner retinal thickness.

**TABLE 5.** Multivariable Analysis of Superficial Macular Vessel Density Associations

Parameters	Standardized Coefficients $\beta$	P Value
SSI	0.607	<0.001
Sex	0.162	<0.001
Age	-0.045	0.09
AL	-0.037	0.09
BCVA	-0.011	0.64
Thickness of inner retina	0.027	0.19
HbA1C	-0.002	0.91
HDL	-0.009	0.67
Creatinine	0.028	0.20
MAP	0.021	0.34

measuring macular vessel density with the relatively recent imaging technology of OCTA, which enabled us to analyze the systemic associations of macular perfusion. Therefore, our study adds to current knowledge of quantitative data of the normal retinal vascular system.

In conclusion, this large population-based study provided normative OCTA data of macular vessel density and demonstrated that a lower superficial retinal vessel density was significantly associated with lower SSI and male sex, while a lower deep layer retinal vessel density was significantly associated with lower SSI, longer AL, and a higher level of creatinine. These associations must be considered when interpreting clinical quantitative OCTA data.

### Acknowledgments

The authors thank Tristan T. Hormel from Oregon Health & Science University, Portland, Oregon, United States, for help in language editing during the paper review process.

Supported by the 'Chloe Ho Safeguarding Vision Initiative', the Jessie & George Ho Charitable Foundation and Hong Kong Jockey Club Charities Trust, which funded the establishment of the family cohort from 2007 to 2014. The funding organization had no role in the design or conduct of this research. The authors alone are responsible for the writing and content of this article.

Disclosure: **Q.S. You**, None; **J.C.H. Chan**, None; **A.L.K. Ng**, None; **B.K.N. Choy**, None; **K.C. Shih**, None; **J.J.C. Cheung**, None; **J.K.W. Wong**, None; **J.W.H. Shum**, None; **M.Y. Ni**, None; **J.S.M. Lai**, None; **G.M. Leung**, None; **C.M.G. Cheung**, None; **T.Y. Wong**, None; **I.Y.H. Wong**, None

### References

- Yannuzzi LA, Rohrer KT, Tindel LJ, et al. Fluorescein angiography complication survey. *Ophthalmology*. 1986;93:611-617.
- Stanga PE, Lim JI, Hamilton P. Indocyanine green angiography in chorioretinal diseases: indications and interpretation: an evidence-based update. *Ophthalmology*. 2003;110:15-21.
- Jia Y, Bailey ST, Hwang TS, et al. Quantitative optical coherence tomography angiography of vascular abnormalities in the living human eye. *Proc Natl Acad Sci U S A*. 2015;112:E2395-E2402.
- Jia Y, Tan O, Tokayer J, et al. Split-spectrum amplitude-decorrelation angiography with optical coherence tomography. *Optics Exp*. 2012;20:4710-4725.
- Spaide RF, Fujimoto JG, Waheed NK, Sadda SR, Staurengi G. Optical coherence tomography angiography. *Prog Retin Eye Res*. 2018;64:1-55.

- You Q, Freeman WR, Weinreb RN, et al. Reproducibility of vessel density measurement with optical coherence tomography angiography in eyes with and without retinopathy. *Retina*. 2017;37:1475-1482.
- Lei J, Durbin MK, Shi Y, et al. Repeatability and reproducibility of superficial macular retinal vessel density measurements using optical coherence tomography angiography en face images. *JAMA Ophthalmol*. 2017;135:1092-1098.
- Corvi F, Pellegrini M, Erba S, Cozzi M, Staurengi G, Giani A. Reproducibility of vessel density, fractal dimension, and foveal avascular zone using 7 different optical coherence tomography angiography devices. *Am J Ophthalmol*. 2018;186:25-31.
- Al-Sheikh M, Tepelus TC, Nazikyan T, Sadda SR. Repeatability of automated vessel density measurements using optical coherence tomography angiography. *Br J Ophthalmol*. 2017;101:449-452.
- Manalastas PIC, Zangwill LM, Saunders LJ, et al. Reproducibility of optical coherence tomography angiography macular and optic nerve head vascular density in glaucoma and healthy eyes. *J Glaucoma*. 2017;26:851-859.
- Wang Q, Chan S, Yang JY, et al. Vascular density in retina and choriocapillaris as measured by optical coherence tomography angiography. *Am J Ophthalmol*. 2016;168:95-109.
- Yarmohammadi A, Zangwill LM, Diniz-Filho A, et al. Optical coherence tomography angiography vessel density in healthy, glaucoma suspect, and glaucoma eyes. *Invest Ophthalmol Vis Sci*. 2016;57:451-459.
- Yu J, Gu R, Zong Y, et al. Relationship between retinal perfusion and retinal thickness in healthy subjects: an optical coherence tomography angiography study. *Invest Ophthalmol Vis Sci*. 2016;57:204-210.
- Yu J, Jiang C, Wang X, et al. Macular perfusion in healthy Chinese: an optical coherence tomography angiogram study. *Invest Ophthalmol Vis Sci*. 2015;56:3212-3217.
- Lu Y, Simonett JM, Wang J, et al. Evaluation of automatically quantified foveal avascular zone metrics for diagnosis of diabetic retinopathy using optical coherence tomography angiography. *Invest Ophthalmol Vis Sci*. 2018;59:2212-2221.
- Hwang TS, Gao SS, Liu L, et al. Automated quantification of capillary nonperfusion using optical coherence tomography angiography in diabetic retinopathy. *JAMA Ophthalmol*. 2016;134:367-373.
- Jia Y, Bailey ST, Wilson DJ, et al. Quantitative optical coherence tomography angiography of choroidal neovascularization in age-related macular degeneration. *Ophthalmology*. 2014;121:1435-1444.
- Jia Y, Wei E, Wang X, et al. Optical coherence tomography angiography of optic disc perfusion in glaucoma. *Ophthalmology*. 2014;121:1322-1332.
- Takusagawa HL, Liu L, Ma KN, et al. Projection-resolved optical coherence tomography angiography of macular retinal circulation in glaucoma. *Ophthalmology*. 2017;124:1589-1599.
- Jain N, Jia Y, Gao SS, et al. Optical coherence tomography angiography in choroideremia: correlating choriocapillaris loss with overlying degeneration. *JAMA Ophthalmol*. 2016;134:697-702.
- Leung GM, Ni MY, Wong PT, et al. Cohort profile: FAMILY cohort. *In the J Epidemiol*. 2017;46:e1.
- Borrelli E, Lonngi M, Balasubramanian S, et al. Macular microvascular networks in healthy pediatric subjects. *Retina*. 2019;39:1216-1224.
- Rao HL, Pradhan ZS, Weinreb RN, et al. Determinants of peripapillary and macular vessel densities measured by optical coherence tomography angiography in normal eyes. *J Glaucoma*. 2017;26:491-497.
- Shahlaee A, Samara WA, Hsu J, et al. In vivo assessment of macular vascular density in healthy human eyes using optical

- coherence tomography angiography. *Am J Ophthalmol*. 2016; 165:39-46.
25. Yang Y, Wang J, Jiang H, et al. Retinal microvasculature alteration in high myopia. *Invest Ophthalmol Vis Sci*. 2016; 57:6020-6030.
  26. Al-Sheikh M, Phasukkijwatana N, Dolz-Marco R, et al. Quantitative OCT angiography of the retinal microvasculature and the choriocapillaris in myopic eyes. *Invest Ophthalmol Vis Sci*. 2017;58:2063-2069.
  27. Fan H, Chen HY, Ma HJ, et al. Reduced macular vascular density in myopic eyes. *Chinese Medical J*. 2017;130:445-451.
  28. Sung MS, Lee TH, Heo H, Park SW. Association between optic nerve head deformation and retinal microvasculature in high myopia. *Am J Ophthalmol*. 2018;188:81-90.
  29. Hwang TS, Zhang M, Bhavsar K, et al. Visualization of 3 distinct retinal plexuses by projection-resolved optical coherence tomography angiography in diabetic retinopathy. *JAMA Ophthalmol*. 2016;134:1411-1419.
  30. Zhang M, Hwang TS, Campbell JP, et al. Projection-resolved optical coherence tomographic angiography. *Biomed Opt Express*. 2016;7:816-828.