

# Anti-Fumarase Antibody as a Predictor of Functional Efficacy of Anti-VEGF Therapy for Diabetic Macular Edema

Tatsuya Yoshitake, Tomaoki Murakami, Shin Yoshitake, Kiyoshi Suzuma, Yoko Dodo, Masahiro Fujimoto, and Akitaka Tsujikawa

Department of Ophthalmology and Visual Sciences, Kyoto University Graduate School of Medicine, Kyoto, Japan

Correspondence: Tomaoki Murakami, Department of Ophthalmology and Visual Sciences, Kyoto University Graduate School of Medicine, 54 Shogoin-Kawaracho, Sakyo, Kyoto 606-8507, Japan; mutomo@kuhp.kyoto-u.ac.jp.

Submitted: November 14, 2018  
Accepted: January 29, 2018

Citation: Yoshitake T, Murakami T, Yoshitake S, et al. Anti-fumarase antibody as a predictor of functional efficacy of anti-VEGF therapy for diabetic macular edema. *Invest Ophthalmol Vis Sci.* 2019;60:787-794. <https://doi.org/10.1167/iovs.18-26209>

**PURPOSE.** To evaluate whether baseline titers of anti-fumarase antibody are associated with visual prognosis after anti-VEGF treatment for diabetic macular edema (DME).

**METHODS.** In this retrospective study, we investigated 52 eyes of 52 DME patients who received intravitreal injections of anti-VEGF drugs (ranibizumab or aflibercept) after blood sampling at baseline. Optical coherence tomography (OCT) images were obtained at every monthly visit. The serum titer of anti-fumarase antibody at baseline was measured using ELISA. We evaluated the relationship between the titer of anti-fumarase antibody at baseline and visual acuity (VA) improvement at 12 months.

**RESULTS.** The serum titer of anti-fumarase IgG was related to the logMAR visual acuity (VA;  $R = 0.329$ ,  $P = 0.017$ ) and the disrupted ellipsoid zone (EZ;  $R = 0.364$ ,  $P = 0.008$ ) at baseline. The titer of this autoantibody was not associated with logMAR VA ( $R = -0.007$ ,  $P = 0.980$ ) but was associated with VA improvement ( $R = 0.465$ ,  $P < 0.001$ ) at 12 months upon anti-VEGF treatment. The transverse length of the disrupted EZ line was shortened at 12 months ( $P < 0.001$ ), and restoration of the EZ line was correlated to the autoantibody titer ( $R = 0.396$ ,  $P = 0.004$ ) compared with the decrease in central subfield (CSF) thickness. Multivariate analysis showed that pretreatment logMAR VA ( $\beta = 0.296$ ,  $P = 0.045$ ) and the autoantibody titer ( $\beta = 0.328$ ,  $P = 0.017$ ) were associated with VA improvement after anti-VEGF treatment. In contrast, the titer was not associated with logMAR VA at 12 months.

**CONCLUSIONS.** Anti-fumarase antibody is a novel serum biomarker predicting better functional efficacy of anti-VEGF treatment for DME.

**Keywords:** diabetic macular edema, anti-vascular endothelial growth factor, autoantibody

Diabetic retinopathy (DR) is one of the leading causes of severe visual loss worldwide, and proliferative diabetic retinopathy (PDR) and diabetic macular edema (DME) often threaten the vision of diabetic patients.<sup>1</sup> The recent development of anti-VEGF drugs has significantly improved visual prognosis in patients suffering from DME and has had beneficial effects on DR severity grades and several diabetic lesions, including capillary nonperfusion, hard exudates, and foveal photoreceptors.<sup>2-10</sup>

Clinicians have to consider socioeconomic burdens and severe complications (e.g., endophthalmitis and arteriothrombotic diseases) when approved drugs with great efficacy, that is, ranibizumab (Lucentis; Novartis Pharma AG, Basel, Switzerland) or aflibercept (Eylea; Bayer, Berlin, Germany) are applied.<sup>3-5,11,12</sup> This suggests the need to optimize the indications and dosing regimens of anti-VEGF treatments for DME.<sup>13,14</sup> Post hoc analyses of major clinical trials have elucidated the predictive parameters in systemic and ocular factors at baseline, for example, visual acuity (VA) and optical coherence tomography (OCT) findings, including serous retinal detachment (SRD), vitreomacular adhesion (VMA), and the absence of vitreoretinal abnormalities.<sup>15-17</sup> Interestingly, several publications have reported changes in the intraocular levels of angiogenic factors or inflammatory cytokines after anti-VEGF treatment.<sup>18-20</sup> However, the molecular biomarkers that predict visual outcomes after anti-VEGF treatment are largely unknown.

The blood-retinal barrier (BRB) is composed of integrated interactions between vascular endothelial cells and perivascular cells, decreases transcellular transport, and serves as the regulator of vascular hyperpermeability and the gateways of immune agents.<sup>21-23</sup> A healthy eye is an immunoprivileged site, and the BRB sequesters retinal autoantigens from humoral or cellular immunity.<sup>24,25</sup> Several publications have revealed that innate or acquired autoimmunity contributes to the pathogenesis of neovascular AMD and other chorioretinal diseases.<sup>26-29</sup> Similarly, a recent publication identified anti-fumarase antibody as a serum biomarker of the subgroups of DME as well as a pathological mechanism of autoimmune photoreceptor damage in DME.<sup>30</sup>

In this study, we investigated how the baseline titer of anti-fumarase antibody was associated with functional or anatomic outcomes after anti-VEGF therapy for DME.

## METHODS

### Patients

In this retrospective study, we consecutively reviewed patients with center-involved DME who received anti-VEGF treatment for at least 12 months. The patients were referred to Kyoto University Hospital from July 2014 to September 2017 for the baseline visit. The inclusion criteria at baseline were as follows:



center-involved DME, which received anti-VEGF treatment, (i.e., intravitreal ranibizumab [IVR] or intravitreal aflibercept [IVA] injections) for at least 12 months and blood sampling at baseline. When both eyes were treated with anti-VEGF therapy, the first eye participated. The exclusion criteria at baseline were media opacities affecting the VA, other chorioretinal diseases, treatment for DME within the previous 6 months, previous intraocular surgery other than cataract extraction, cataract surgery within the previous 3 months, and any history of autoimmune disease or malignancy. Further, several patients were lost before the 12-month visit due to inconvenience for the patient or the patient's desire to terminate treatment or change to other therapeutic strategies, drug tachyphylaxis, or additional treatments, (i.e., panretinal photocoagulation, vitrectomy [for vitreous hemorrhage], and cataract surgery). All research and measurements adhered to the tenets of the Declaration of Helsinki. The institutional review board and the Ethics Committee of Kyoto University Graduate School of Medicine approved the study protocol. All participants provided written informed consent before study enrollment.

### Intervention

Ranibizumab (0.5 mg) or aflibercept (2 mg) was intravitreally administered according to the 3+ pro re nata (PRN) regimen, as described in the Ranibizumab Monotherapy or Combined with Laser versus Laser Monotherapy for Diabetic Macular Edema (RESTORE) study.<sup>3</sup> After disinfection, anti-VEGF agents were injected 3.5 mm posterior to the limbus followed by instillation of antibiotics. Three monthly injections were followed by the PRN injections according to the retreatment criteria of the RESTORE study. After tachyphylaxis for one drug was suggested, we switched to the other drug.

### Measurement of the Serum Titer of Anti-Fumarase Antibody

An ELISA was performed to measure the titer of anti-fumarase IgG in the patients' sera, as described previously.<sup>30</sup> Briefly, sera were aliquoted and immediately stored at  $-80^{\circ}\text{C}$ . The bottom surface of the individual wells of a 96-well plate (Nunc Immunoplate Maxisorp; Thermo Scientific Inc., Waltham, MA, USA) was coated with recombinant human fumarase (1  $\mu\text{g}/\text{mL}$ ; RayBiotech Inc., Norcross, GA, USA) in 100 mM bicarbonate-carbonate buffer by overnight incubation at  $4^{\circ}\text{C}$ . After blocking (3% BSA in Tris-buffered saline containing 0.1% Tween-20 [TBS-T]), the patients' sera (1:1000 diluted in 3% BSA in TBS-T) were incubated for 2 hours. After rinsing with TBS-T, horseradish peroxidase (HRP)-labeled anti-human IgG secondary antibodies (1:5000) were serially incubated for 1 hour. The signals detected using 3,3',5,5'-tetramethylbenzidine (TMB; Nacalai Tesque, Inc., Kyoto, Japan) were measured at an absorption of 450 nm using an ARVO MX plate reader (PerkinElmer, Norwalk, CT, USA). All experiments were performed in duplicate, and the individual plates were calibrated using two different control serum specimens. The investigators were blinded during the procedures and outcome assessments.

### Optical Coherence Tomography

Before the comprehensive ophthalmic examination, the best-corrected decimal VA was measured and converted to logMAR VA for further analyses. OCT images were also obtained using spectral-domain (SD)-OCT (Spectralis OCT; Heidelberg Engineering, Heidelberg, Germany) at all monthly visits. Vertical and horizontal sectional images dissecting the fovea were acquired using the cross-hair mode ( $30^{\circ}$ ) according to

previously described methods.<sup>31</sup> The number for image averaging was 20 to 100 to acquire better images. We obtained three-dimensional images using the raster scan mode, followed by the construction of two-dimensional maps and automatic quantification of the mean central subfield (CSF) thickness, as described previously.<sup>31</sup>

We quantitatively assessed the two high-reflectance bands, ellipsoid zones of photoreceptors (EZ) that represent foveal photoreceptor status, on the vertical and horizontal sectional images. We measured the transverse length of the disrupted EZ within the central 1 mm on the vertical and horizontal images using the caliper tool in the Heidelberg Eye Explorer software (Heidelberg Engineering), as previously reported.<sup>32</sup> The mean percentage was used in the following investigations.

### Statistics

The results are expressed as the mean  $\pm$  standard deviation. The data were analyzed using Student's *t*-test or paired *t*-test to estimate the differences between two groups with normal distributions. Wilcoxon signed-rank test or the Mann-Whitney *U* test was applied to compare two groups with nonnormal distributions. We calculated Pearson's correlation coefficient to evaluate the statistical correlation. The intraclass correlation coefficient (ICC) or Kappa coefficient was applied for concordance in the quantitative or qualitative parameters, respectively. We employed multiple linear regression analysis using significant variables ( $P < 0.10$  in univariate analysis) as the independent variable.  $P < 0.05$  was considered statistically significant. SPSS version 24.0 was used for statistical analyses (SPSS, Inc., Chicago, IL, USA).

## RESULTS

### Relationship Between Anti-Fumarase Antibody Levels at Baseline and Visual Outcomes After Anti-VEGF Treatment for DME

We retrospectively reviewed 52 consecutive eyes of 52 patients who received anti-VEGF injections for DME. Five patients received this treatment in both eyes. The baseline characteristics are shown in Table 1. Among 115 eyes that met the inclusion criteria, nine were excluded at baseline. Fifty-four eyes were lost before the 12-month visit. Thirty-four or 17 eyes received IVR or IVA injections alone, respectively, whereas IVR treatment was switched to IVA treatment in an eye because of tachyphylaxis. LogMAR VA, CSF thickness, and the disrupted EZ line were significantly improved at the 12-month visit ( $P < 0.001$ ,  $P < 0.001$ , and  $P < 0.001$ , respectively).

We evaluated the relationship between baseline anti-fumarase antibody levels and visual outcomes at each time point. The titer of anti-fumarase IgG was related to logMAR VA at baseline ( $R = 0.327$ ,  $P = 0.017$ ) but not to any time points after treatment (Fig. 1). The pretreatment titer was associated with VA improvement at 6, 9, and 12 months ( $R = 0.377$ ,  $P = 0.006$ ;  $R = 0.362$ ,  $P = 0.008$ ;  $R = 0.465$ ,  $P < 0.001$ , respectively), whereas there was no correlation at 1 or 3 months (Fig. 2). The titer of the autoantibody was modestly associated with VA improvement at 12 months in 34 or 17 eyes treated with ranibizumab or aflibercept alone, respectively ( $R = 0.428$ ,  $P = 0.012$  or  $R = 0.575$ ,  $P = 0.016$ , respectively).

### Association Between Anti-Fumarase IgG and Structural Efficacy of anti-VEGF Treatment

We further investigated the relationship between this autoantibody and morphologic outcomes by OCT images. There were

TABLE 1. Baseline Characteristics

Parameter	
Age, y	65.9 ± 11.6
Men/women	33/19
Hemoglobin A1c, %	7.21 ± 0.97
Systemic hypertension, patients	28
LogMAR VA	0.335 ± 0.208
International classification	
Mild NPDR	2 eyes
Moderate NPDR	29 eyes
Severe NPDR	13 eyes
PDR	8 eyes
Pseudophakia	16 eyes
Panretinal photocoagulation	25 eyes
CSF thickness, μm	452 ± 100
Cystoid abnormalities	47 eyes
	(Kappa coefficient = 1.000)
Subretinal fluid	13 eyes
	(Kappa coefficient = 1.000)
Vitreoretinal abnormalities	4 eyes
	(Kappa coefficient = 1.000)
Disrupted EZ line, %	15.2 ± 21.2
	(ICC = 0.943)

NPDR, nonproliferative diabetic retinopathy.

no associations of anti-fumarase IgG titer with CSF thickness at baseline or 12 months or with the decrease in CSF thickness at 12 months (Fig. 3). The autoantibody titer was related to the transverse length of the disrupted EZ line at baseline ( $R = 0.364$ ,  $P = 0.008$ ) and the decrease in the disrupted EZ line at 12 months ( $R = 0.396$ ,  $P = 0.004$ ), whereas this autoantibody was not correlated with the EZ line at 12 months (Fig. 3). There were no differences in the titer of anti-fumarase IgG between cases with and without qualitative OCT findings (i.e., cystoid abnormalities, subretinal fluid, and vitreoretinal abnormalities at baseline; Table 2).

### Multivariate Analysis to Investigate Factors Predicting Functional Efficacy of Anti-VEGF Treatment

Univariate or multivariate analyses showed that logMAR VA at 12 months was associated with pretreatment VA alone (Table 3). According to univariate analyses, logMAR VA, the disrupted EZ line, and the titer of anti-fumarase IgG were related to VA improvement at 12 months (Table 4). Furthermore, we employed multivariate analyses to adjust for confounding factors and revealed that logMAR VA ( $\beta = 0.296$ ,  $P = 0.045$ ) and the serum titer of anti-fumarase IgG ( $\beta = 0.328$ ,  $P = 0.017$ )

at baseline were related to VA improvement at 12 months (Table 4).

## DISCUSSION

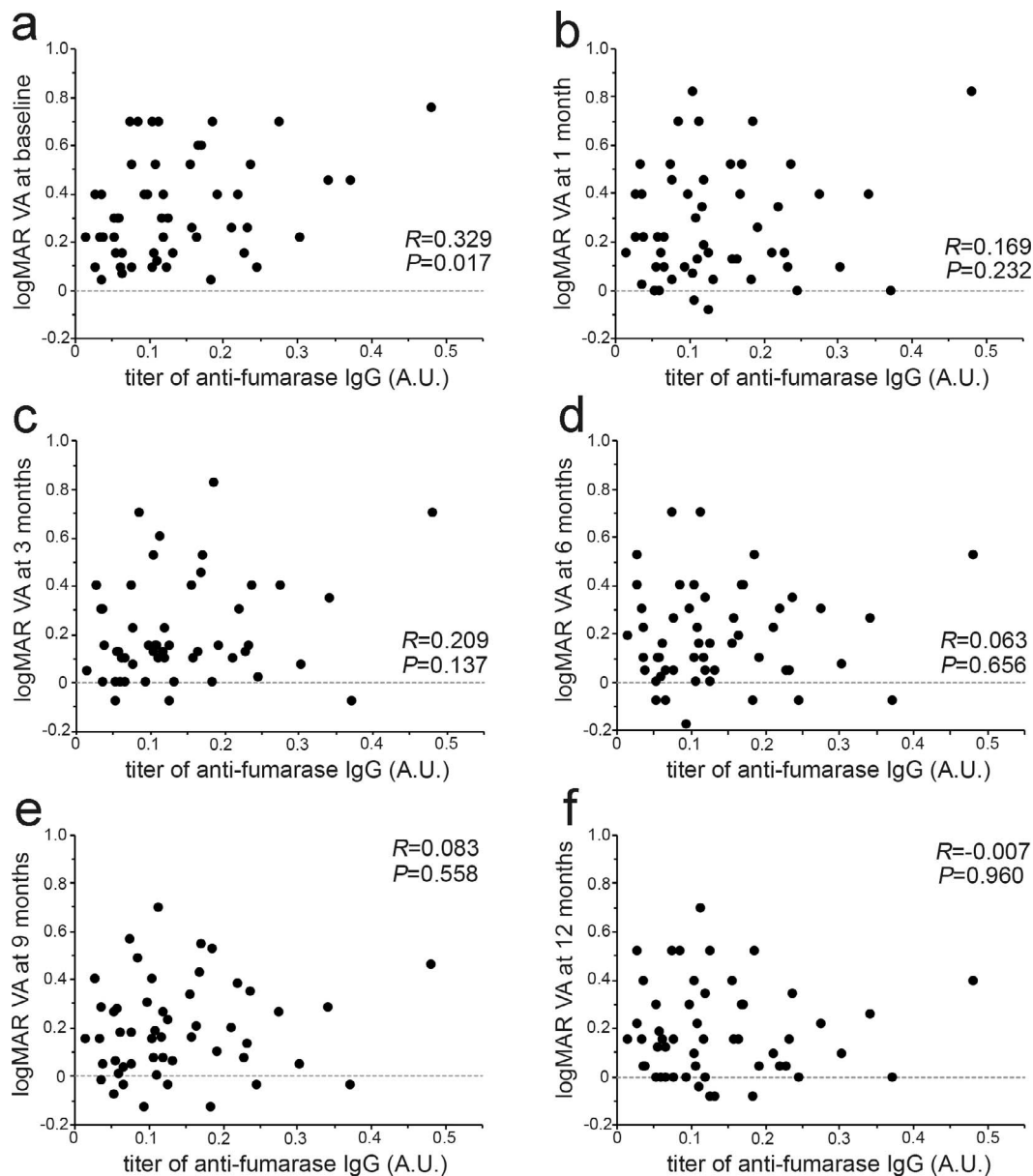
Anti-VEGF therapy is the first choice of treatment for DME, although other strategies (e.g., macular photocoagulation, steroids, and vitrectomy) still have beneficial effects and are combined in some cases.<sup>2,4,5,33-35</sup> This suggests that identifying prognostic factors after each treatment is crucial to progress toward personalized medicine. In this study, we demonstrate, for the first time, that the serum titer of anti-fumarase IgG at baseline is associated with greater VA improvement after anti-VEGF treatment for DME. This autoantibody is associated with poor VA and photoreceptor damage, and multivariate analyses demonstrated that anti-fumarase antibody predicts better functional efficacy after the adjustment for confounding factors. Diabetic patients may be able to know whether anti-VEGF treatment will be more effective for them upon blood sampling in the eye clinic or internal medicine clinic.

In this exploratory study, both poor VA and the serum titer of anti-fumarase IgG at baseline predicted VA improvement 12 months after anti-VEGF treatment for DME. Generally, pretreatment VA is positively associated with both VA and its improvement after anti-VEGF therapy.<sup>15,16</sup> These clinical trial data may allow us to speculate that visual impairment depends on both irreversible neurodegeneration and reversible retinal dysfunction, some of which may be improved by anti-VEGF treatment.<sup>22,36</sup> Anti-fumarase antibody can predict VA improvement but not VA per se after this treatment. We thus hypothesized that this autoantibody is related to remediable retinal dysfunction rather than neurodegeneration. Consistently, some patients with poor VA had lower levels of this autoantibody and may suffer from visual disturbance independent of autoantibody-related mechanisms.

Anti-fumarase antibody is clinically associated with visual impairment and photoreceptor damage in DME, and this autoantibody from DME patients promotes the structural and functional damage of photoreceptors in rodent models.<sup>30</sup> Recent publications documented gradual restoration of foveal photoreceptor status after anti-VEGF treatment for DME.<sup>9,10</sup> We therefore evaluated photoreceptor changes in this study and found that this autoantibody was associated not with the EZ status but rather with its improvement 12 months after anti-VEGF treatment. We speculate that anti-VEGF drugs block the extravasation of this autoantibody. Anti-VEGF treatment decreases the serum levels of this autoantibody.<sup>30</sup> These mechanisms might allow gradual restoration of photoreceptor damage or reverse other unknown mechanisms of visual dysfunction. Furthermore, future studies should compare photoreceptor restoration between individual chorioretinal

TABLE 2. Systemic and Ocular Characteristics and Their Association With the Serum Titers of Anti-Fumarase Antibody at Baseline

Parameter	Titers of Anti-Fumarase IgG, AU	Association With Titers of Anti-Fumarase IgG
Age, y	0.137 ± 0.097	$R = 0.085$ , $P = 0.551$
Sex, men/women	0.127 ± 0.089/0.155 ± 0.109	$P = 0.310$
Hemoglobin A1c, %	-	$R = -0.890$ , $P = 0.665$
Systemic hypertension, absent/present	0.112 ± 0.079/0.159 ± 0.106	$P = 0.088$
Phakia/pseudophakia	0.139 ± 0.107/0.132 ± 0.070	$P = 0.792$
DR severity, NPDR/PDR	0.134 ± 0.096/0.155 ± 0.107	$P = 0.567$
Panretinal photocoagulation, absent/present	0.107 ± 0.068/0.172 ± 0.114	$P = 0.021$
Cystoid abnormalities, absent/present	0.189 ± 0.169/0.131 ± 0.087	$P = 0.211$
Subretinal fluid, absent/present	0.125 ± 0.085/0.173 ± 0.123	$P = 0.118$
Vitreoretinal abnormalities, absent/present	0.134 ± 0.098/0.168 ± 0.077	$P = 0.504$



**FIGURE 1.** The relationship between anti-fumarase IgG titers at baseline and logMAR VA at baseline (a), 1 month (b), 3 months (c), 6 months (d), 9 months (e), and 12 months (f) after anti-VEGF treatment for DME. AU, arbitrary unit.

diseases<sup>37-39</sup> and should investigate the relationship between this autoantibody and photoreceptor damage in other retinal diseases.<sup>40</sup>

Recent post hoc analyses regarding prognostic factors reported that several OCT findings (e.g., SRD and the absence of vitreoretinal abnormalities) predict functional efficacy of anti-VEGF treatment for DME.<sup>15,16</sup> Because there were no differences in anti-fumarase IgG between cases with and without these findings, we considered that this autoantibody is a predictor independent of such OCT findings. The latest image modality, OCT angiography (OCTA), also revealed that capillary nonperfusion around the fovea predicts poor visual outcomes after anti-VEGF treatment for DME.<sup>41</sup> Future studies should elucidate whether anti-fumarase IgG is related to macular ischemic changes on OCTA images and whether the combination of these prognostic factors improves the accuracy of VA prediction after anti-VEGF therapy.

Anti-VEGF treatment is the first-line intervention for DME, although other therapeutic strategies (e.g., steroid, photocoagulation, and vitrectomy) can be applied to limited cases as a rescue protocol.<sup>2,4,5,33-35</sup> Post hoc analyses in the RISE and RIDE clinical trial showed that the prognostic factors in the sham-treated groups were different from those in the ranibizumab-treated group.<sup>16</sup> Vitreomacular abnormalities predict poor functional efficacy of anti-VEGF for DME, although epiretinal membrane peeling is a predictor of greater VA improvement in eyes that received vitrectomy.<sup>15,42</sup> A recent publication reported the progression of photoreceptor damage after vitrectomy in eyes with hyperreflective foci in the outer retinal layers compared with photoreceptor restoration after anti-VEGF therapy.<sup>9,10,43</sup> Because the individual interventions result in individual anatomic or functional efficacy, further investigations should elucidate whether anti-fumarase IgG can be a prognostic factor after other treatments.



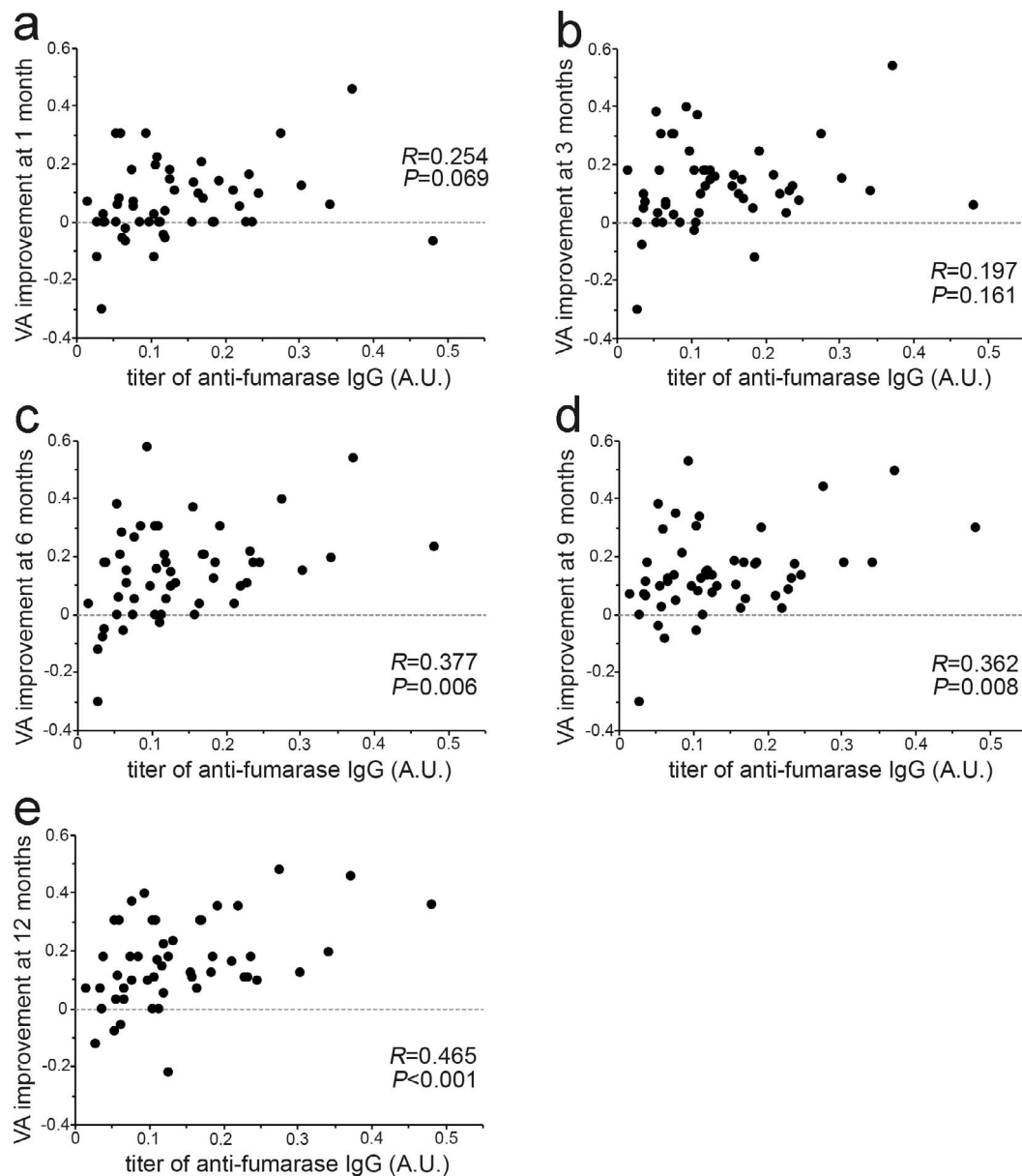


FIGURE 2. The association between anti-fumarase IgG titers at baseline and logMAR VA improvement at 1 month (a), 3 months (b), 6 months (c), 9 months (d), and 12 months (e) after anti-VEGF treatment for DME.

The incidence of DME can be associated with several lines of biomarkers, serum components regarding hyperglycemia or inflammation, proteomics or metabolomics in the intraocular humor, local or systemic miRNA, and ocular imaging.<sup>44</sup> In particular, the serum or intraocular levels of some proinflammatory cytokines are associated with the structural efficacy of anti-VEGF treatment in DME.<sup>20,45</sup> Retinal inflammatory biomarkers on OCT images are changed after anti-VEGF treatment in DME.<sup>46</sup> These publications are to some extent consistent with the association between anti-fumarase IgG and VA improvement in this study because cytokines and inflammatory cells regulate autoimmune responses.<sup>26</sup> Further investigation should elucidate the molecular mechanisms of autoantibodies and inflammatory responses before and after anti-VEGF therapy for DME.

There are several limitations of this exploratory study. Fifty-four cases (50.9%) were lost during the 12-month follow-up, and the number of cases was small, suggesting possible

selection bias. Participants were Asian and anti-VEGF drugs were injected according to the PRN regimen in a single center. This is a pilot retrospective study that raises more questions than answers but sets the groundwork for future studies. Additional prospective studies should confirm the generalizability to other races, other dosing regimens, and other institutes.<sup>4,5,14</sup>

In conclusion, we demonstrate, for the first time, that higher titers of anti-fumarase antibody at baseline are associated with better VA improvement after anti-VEGF treatment for DME, suggesting that anti-fumarase IgG is a novel serum biomarker of functional efficacy.

#### Acknowledgements

Supported by Grant-in-Aid for Scientific Research of the Japan Society for the Promotion of Science (17K11423, 18K19610; Tokyo, Japan).

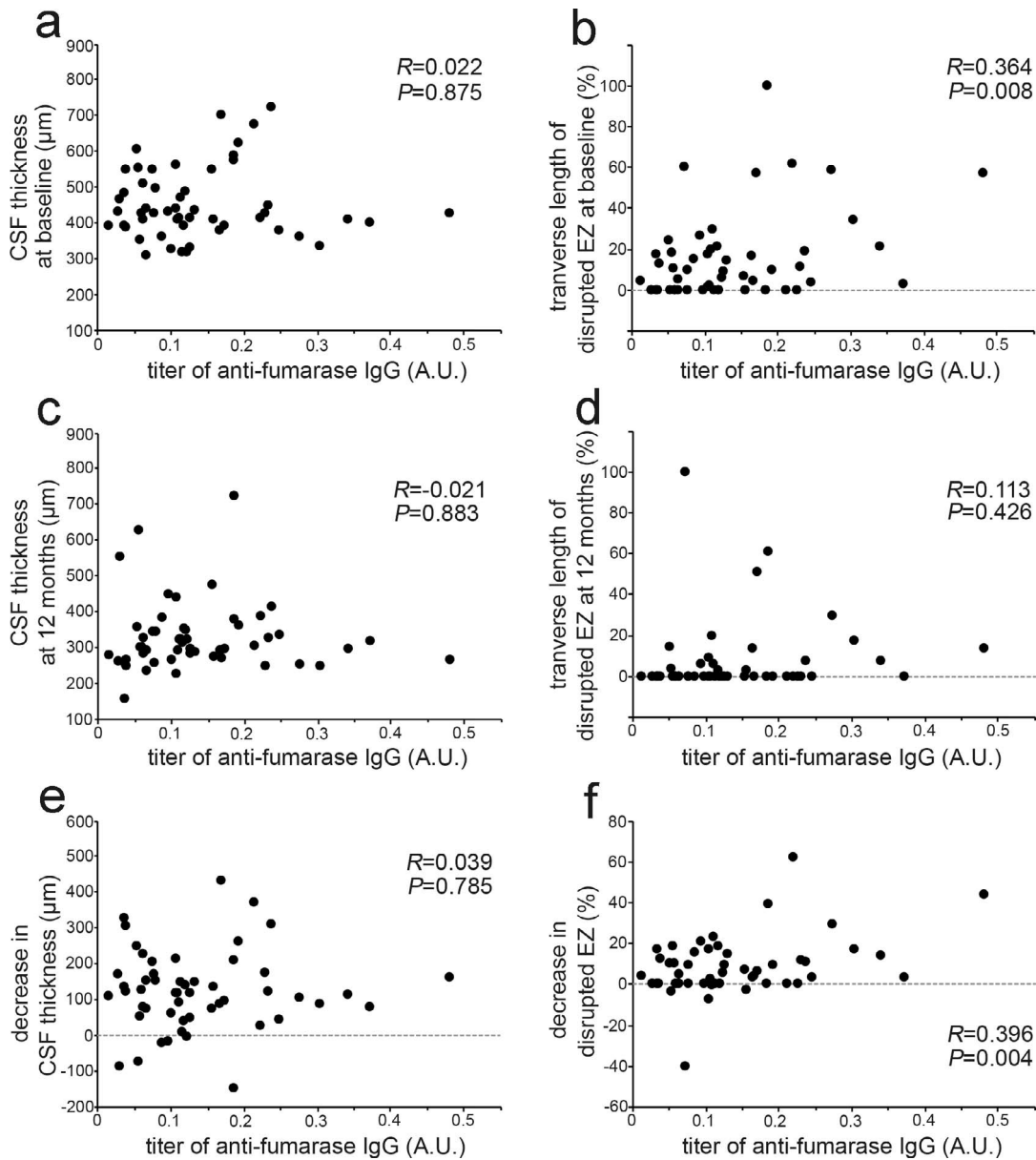


FIGURE 3. The relationship between anti-fumarase IgG titers at baseline and morphologic parameters based on SD-OCT images after anti-VEGF treatment for DME. Association of the titer with CSF thickness (a, c, e) or the transverse length of disrupted EZ line (b, d, f).

TABLE 3. Multivariate Regression Analysis to Determine the Predictors of logMAR VA at 12 Months

Parameter	Univariate			Multivariate		
	Unstandardized $\beta$	Standardized $\beta$	P Value	Unstandardized $\beta$	Standardized $\beta$	P Value
Age, y	-0.001	-0.047	0.741			
Sex, female	-0.016	-0.042	0.767			
Hemoglobin A1c, %	0.007	0.038	0.813			
Systemic hypertension	0.040	0.106	0.457			
LogMAR VA	0.652	0.718	<0.001	0.729	0.804	<0.001
PDR	0.024	0.047	0.741			
Pseudophakia	-0.091	-0.224	0.111			
Panretinal photocoagulation	0.071	0.189	0.180			
CSF thickness, $\mu\text{m}$	<0.001	0.054	0.703			
Cystoid abnormalities	-0.113	-0.178	0.206			
Subretinal fluid	0.005	0.011	0.939			
Vitreoretinal abnormalities	-0.048	-0.068	0.631			
Disrupted EZ line, %	0.002	0.250	0.074	-0.001	-0.166	0.624
The titer of anti-fumarase IgG, AU	-0.014	-0.007	0.960			

TABLE 4. Multivariate Regression Analysis to Determine the Predictors of Improvement of logMAR VA at 12 Months

Parameter	Univariate			Multivariate		
	Unstandardized $\beta$	Standardized $\beta$	P Value	Unstandardized $\beta$	Standardized $\beta$	P Value
Age, y	-0.002	-0.157	0.266			
Sex, female	-0.006	-0.019	0.891			
Hemoglobin A1c, %	-0.036	-0.228	0.146			
Systemic hypertension	0.011	0.038	0.790			
LogMAR VA	0.348	0.483	<0.001	0.214	0.296	0.045
PDR	0.098	0.239	0.088	0.066	0.159	0.237
Pseudophakia	-0.030	-0.092	0.517			
Panretinal photocoagulation	0.081	0.271	0.052	-0.017	-0.057	0.696
CSF thickness, $\mu\text{m}$	0.000	0.109	0.444			
Cystoid abnormalities	0.029	0.058	0.682			
Subretinal fluid	-0.001	-0.003	0.980			
Vitreoretinal abnormalities	0.068	0.122	0.388			
Disrupted EZ line, %	0.003	0.402	0.003	0.001	0.126	0.375
The titer of anti-fumarase IgG, AU	0.723	0.465	<0.001	0.509	0.328	0.017

Disclosure: **T. Yoshitake**, None; **T. Murakami**, Novartis (F); **S. Yoshitake**, None; **K. Suzuma**, Novartis (F), Bayer (F), Santen (F); **Y. Dodo**, None; **M. Fujimoto**, None; **A. Tsujikawa**, Novartis (F), Bayer (F), Santen (F), Canon (F)

## References

1. Yau JW, Rogers SL, Kawasaki R, et al. Global prevalence and major risk factors of diabetic retinopathy. *Diabetes Care*. 2012;35:556-564.
2. Elman MJ, Aiello LP, Beck RW, et al. Randomized trial evaluating ranibizumab plus prompt or deferred laser or triamcinolone plus prompt laser for diabetic macular edema. *Ophthalmology*. 2010;117:1064-1077.e35.
3. Mitchell P, Bandello F, Schmidt-Erfurth U, et al. The RESTORE study: ranibizumab monotherapy or combined with laser versus laser monotherapy for diabetic macular edema. *Ophthalmology*. 2011;118:615-625.
4. Nguyen QD, Brown DM, Marcus DM, et al. Ranibizumab for diabetic macular edema: results from 2 phase III randomized trials: RISE and RIDE. *Ophthalmology*. 2012;119:789-801.
5. Korobelnik JF, Do DV, Schmidt-Erfurth U, et al. Intravitreal aflibercept for diabetic macular edema. *Ophthalmology*. 2014;121:2247-2254.
6. Ip MS, Domalpally A, Hopkins JJ, Wong P, Ehrlich JS. Long-term effects of ranibizumab on diabetic retinopathy severity and progression. *Arch Ophthalmol*. 2012;130:1145-1152.
7. Campochiaro PA, Wykoff CC, Shapiro H, Rubio RG, Ehrlich JS. Neutralization of vascular endothelial growth factor slows progression of retinal nonperfusion in patients with diabetic macular edema. *Ophthalmology*. 2014;121:1783-1789.
8. Domalpally A, Ip MS, Ehrlich JS. Effects of intravitreal ranibizumab on retinal hard exudate in diabetic macular edema: findings from the RIDE and RISE phase III clinical trials. *Ophthalmology*. 2015;122:779-786.
9. Seo KH, Yu SY, Kim M, Kwak HW. Visual and morphologic outcomes of intravitreal ranibizumab for diabetic macular edema based on optical coherence tomography patterns. *Retina*. 2016;36:588-595.
10. Mori Y, Suzuma K, Uji A, et al. Restoration of foveal photoreceptors after intravitreal ranibizumab injections for diabetic macular edema. *Sci Rep*. 2016;6:39161.
11. Smiddy WE. Clinical applications of cost analysis of diabetic macular edema treatments. *Ophthalmology*. 2012;119:2558-2562.
12. Avery RL, Gordon GM. Systemic safety of prolonged monthly anti-vascular endothelial growth factor therapy for diabetic macular edema: a systematic review and meta-analysis. *JAMA Ophthalmol*. 2016;134:21-29.
13. Do DV, Nguyen QD, Boyer D, et al. One-year outcomes of the da Vinci Study of VEGF trap-eye in eyes with diabetic macular edema. *Ophthalmology*. 2012;119:1658-1665.
14. Prunte C, Fajnkuchen F, Mahmood S, et al. Ranibizumab 0.5 mg treat-and-extend regimen for diabetic macular oedema: the RETAIN study. *Br J Ophthalmol*. 2016;100:787-795.
15. Bressler SB, Qin H, Beck RW, et al. Factors associated with changes in visual acuity and central subfield thickness at 1 year after treatment for diabetic macular edema with ranibizumab. *Arch Ophthalmol*. 2012;130:1153-1161.
16. Sophie R, Lu N, Campochiaro PA. Predictors of functional and anatomic outcomes in patients with diabetic macular edema treated with ranibizumab. *Ophthalmology*. 2015;122:1395-1401.
17. Sadiq MA, Soliman MK, Sarwar S, et al. Effect of vitreomacular adhesion on treatment outcomes in the Ranibizumab for Edema of the Macula in Diabetes (READ-3) Study. *Ophthalmology*. 2016;123:324-329.
18. Wen J, Jiang Y, Zheng X, Zhou Y. Six-month changes in cytokine levels after intravitreal bevacizumab injection for diabetic macular oedema and macular oedema due to central retinal vein occlusion. *Br J Ophthalmol*. 2015;99:1334-1340.
19. Sohn HJ, Han DH, Kim IT, et al. Changes in aqueous concentrations of various cytokines after intravitreal triamcinolone versus bevacizumab for diabetic macular edema. *Am J Ophthalmol*. 2011;152:686-694.
20. Shimura M, Yasuda K, Motohashi R, Kotake O, Noma H. Aqueous cytokine and growth factor levels indicate response to ranibizumab for diabetic macular oedema. *Br J Ophthalmol*. 2017;101:1518-1523.
21. Harhaj NS, Antonetti DA. Regulation of tight junctions and loss of barrier function in pathophysiology. *Int J Biochem Cell Biol*. 2004;36:1206-1237.
22. Gardner TW, Antonetti DA, Barber AJ, LaNoue KF, Levison SW. Diabetic retinopathy: more than meets the eye. *Surv Ophthalmol*. 2002;47(Suppl 2):S253-S262.
23. Antonetti DA, Klein R, Gardner TW. Diabetic retinopathy. *N Engl J Med*. 2012;366:1227-1239.
24. Streilein JW. Ocular immune privilege: therapeutic opportunities from an experiment of nature. *Nat Rev Immunol*. 2003;3:879-889.

25. Shechter R, London A, Schwartz M. Orchestrated leukocyte recruitment to immune-privileged sites: absolute barriers versus educational gates. *Nat Rev Immunol.* 2013;13:206-218.
26. Ambati J, Atkinson JP, Gelfand BD. Immunology of age-related macular degeneration. *Nat Rev Immunol.* 2013;13:438-451.
27. Kleinman ME, Yamada K, Takeda A, et al. Sequence- and target-independent angiogenesis suppression by siRNA via TLR3. *Nature.* 2008;452:591-597.
28. Adamus G, Chew EY, Ferris FL, Klein ML. Prevalence of anti-retinal autoantibodies in different stages of Age-related macular degeneration. *BMC Ophthalmol.* 2014;14:154.
29. Adamus G. Are anti-retinal autoantibodies a cause or a consequence of retinal degeneration in autoimmune retinopathies? *Front Immunol.* 2018;9:765.
30. Yoshitake S, Murakami T, Suzuma K, et al. Anti-fumarase antibody promotes the dropout of photoreceptor inner and outer segments in diabetic macular oedema. *Diabetologia.* 2019;62:504-516.
31. Murakami T, Ueda-Arakawa N, Nishijima K, et al. Integrative understanding of macular morphologic patterns in diabetic retinopathy based on self-organizing map. *Invest Ophthalmol Vis Sci.* 2014;55:1994-2003.
32. Murakami T, Nishijima K, Akagi T, et al. Optical coherence tomographic reflectivity of photoreceptors beneath cystoid spaces in diabetic macular edema. *Invest Ophthalmol Vis Sci.* 2012;53:1506-1511.
33. Photocoagulation for diabetic macular edema. Early Treatment Diabetic Retinopathy Study report number 1. Early Treatment Diabetic Retinopathy Study research group. *Arch Ophthalmol.* 1985;103:1796-1806.
34. Jonas JB, Sofker A. Intraocular injection of crystalline cortisone as adjunctive treatment of diabetic macular edema. *Am J Ophthalmol.* 2001;132:425-427.
35. Lewis H, Abrams GW, Blumenkranz MS, Campo RV. Vitrectomy for diabetic macular traction and edema associated with posterior hyaloidal traction. *Ophthalmology.* 1992;99:753-759.
36. Abramoff MD, Fort PE, Han IC, Jayasundera KT, Sohn EH, Gardner TW. Approach for a clinically useful comprehensive classification of vascular and neural aspects of diabetic retinal disease. *Invest Ophthalmol Vis Sci.* 2018;59:519-527.
37. Spaide RF, Koizumi H, Freund KB. Photoreceptor outer segment abnormalities as a cause of blind spot enlargement in acute zonal occult outer retinopathy-complex diseases. *Am J Ophthalmol.* 2008;146:111-120.
38. Ojima Y, Tsujikawa A, Yamashiro K, Ooto S, Tamura H, Yoshimura N. Restoration of outer segments of foveal photoreceptors after resolution of central serous chorioretinopathy. *Jpn J Ophthalmol.* 2010;54:55-60.
39. Oishi A, Shimozone M, Mandai M, Hata M, Nishida A, Kurimoto Y. Recovery of photoreceptor outer segments after anti-VEGF therapy for age-related macular degeneration. *Graefes Arch Clin Exp Ophthalmol.* 2013;251:435-440.
40. Murakami T, Tsujikawa A, Ohta M, et al. Photoreceptor status after resolved macular edema in branch retinal vein occlusion treated with tissue plasminogen activator. *Am J Ophthalmol.* 2007;143:171-173.
41. Lee J, Moon BG, Cho AR, Yoon YH. Optical coherence tomography angiography of dme and its association with anti-VEGF treatment response. *Ophthalmology.* 2016;123:2368-2375.
42. Flaxel CJ, Edwards AR, Aiello LP, et al. Factors associated with visual acuity outcomes after vitrectomy for diabetic macular edema: diabetic retinopathy clinical research network. *Retina.* 2010;30:1488-1495.
43. Nishijima K, Murakami T, Hirashima T, et al. Hyperreflective foci in outer retina predictive of photoreceptor damage and poor vision after vitrectomy for diabetic macular edema. *Retina.* 2014;34:732-740.
44. Ting DS, Tan KA, Phua V, Tan GS, Wong CW, Wong TY. Biomarkers of diabetic retinopathy. *Curr Diab Rep.* 2016;16:125.
45. Brito P, Costa J, Gomes N, Costa S, Correia-Pinto J, Silva R. Serological inflammatory factors as biomarkers for anatomic response in diabetic macular edema treated with anti-VEGF. *J Diabetes Complications.* 2018;32:643-649.
46. Vujosevic S, Torresin T, Bini S, et al. Imaging retinal inflammatory biomarkers after intravitreal steroid and anti-VEGF treatment in diabetic macular oedema. *Acta Ophthalmol.* 2017;95:464-471.