

Parapapillary Choroidal Microvasculature Dropout Is Associated With the Decrease in Retinal Nerve Fiber Layer Thickness: A Prospective Study

Sigeng Lin, Huanhuan Cheng, Shaodan Zhang, Cong Ye, Xiafei Pan, Aizhu Tao, Xiang Xu, Jia Qu, and Yuanbo Liang

The Eye Hospital, School of Ophthalmology and Optometry, Wenzhou Medical University, Wenzhou, China

Correspondence: Yuanbo Liang, The Eye Hospital, School of Ophthalmology and Optometry, Wenzhou Medical University, No. 270, Xue Yuan Xi Road, Wenzhou, Zhejiang 325000, China; yuanboliang@126.com.

Jia Qu, The Eye Hospital, School of Ophthalmology and Optometry, Wenzhou Medical University, No. 270, Xue Yuan Xi Road, Wenzhou, Zhejiang 325000, China; 13806898805@163.com.

Submitted: November 1, 2018

Accepted: January 30, 2019

Citation: Lin S, Cheng H, Zhang S, et al. Parapapillary choroidal microvasculature dropout is associated with the decrease in retinal nerve fiber layer thickness: a prospective study. *Invest Ophthalmol Vis Sci*. 2019;60:838–842. <https://doi.org/10.1167/iovs.18-26115>

PURPOSE. To explore the correlation between longitudinal changes of peripapillary retinal nerve fiber layer (RNFL) thickness and the presence of parapapillary choroidal microvasculature dropout (MvD).

METHODS. This is a longitudinal cohort study. All patients with normal-tension glaucoma (NTG) were recruited from the Wenzhou Glaucoma Progression Study. The presence of MvD was determined using optical coherence tomography (OCT) angiography and the RNFL thickness was evaluated by spectral-domain OCT. All assessments were performed both at baseline and at every 3-month follow-up for at least 18 months.

RESULTS. Seventy-one eyes were included. The presence of MvD was observed in 23 NTG eyes (32.4%). Eyes with MvD had a thinner RNFL (68.8 ± 9.6 vs. $76.2 \pm 16.7 \mu\text{m}$, $P = 0.016$) and a faster rate of RNFL loss (-1.2 ± 1.5 vs. $-0.4 \pm 1.4 \mu\text{m}/\text{y}$, $P = 0.036$) compared with those without MvD. In a univariate analysis of rates of RNFL loss, the presence of MvD at baseline ($\beta = -0.83 \pm 0.38$, $P = 0.033$) was significantly associated with progressive RNFL loss. After adjusting for age, female sex, mean follow-up IOP, axial length, central corneal thickness, and mean deviation, the presence of MvD at baseline ($\beta = -0.85 \pm 0.41$, $P = 0.041$) was significantly associated with faster rates of RNFL loss in the multivariate analysis.

CONCLUSIONS. There is a significant correlation between the presence of MvD and decrease in RNFL thickness in NTG patients. Our study further supported that the presence of MvD is a predictor of longitudinal RNFL damage in glaucoma.

Keywords: low-tension glaucoma, optical coherence tomography, choriocapillaris

POAG is a multifactorial progressive disease that can result in irreversible blindness. The pathophysiology of this disease is not yet fully understood.¹ Accumulating evidence suggests that retinal vessel perfusion may play an important role in the onset and progression of POAG.^{2,3} Previous studies^{4–6} showed lower retinal vessel perfusion density in patients with POAG compared with that of healthy subjects. POAG is clinically categorized as high-tension glaucoma (HTG) and normal-tension glaucoma (NTG). Xu et al.⁷ demonstrated that peripapillary vessel density is significantly lower in NTG than in HTG. NTG may be more strongly associated with vascular pathogenesis, rather than IOP.⁸ However, the underlying mechanism of NTG requires further exploration.

Optical coherence tomography angiography (OCTA) is a noninvasive imaging technology that can detect retinal microvasculature and the deep choroid of healthy patients or those with eye disorders.^{9–11} Recently, several studies^{12–15} using OCTA discovered the microvasculature dropout (MvD) in glaucoma patients with β -zone parapapillary atrophy. MvD is defined as the sectorial loss of choriocapillaris. Lee et al.¹³ showed that agreement of MvD by OCTA was in accord with using indocyanine green angiography. Suh et al.¹⁵ found that presence of MvD was significantly associated with a thinner retinal nerve fiber layer (RNFL), suggesting that MvD is a biomarker for POAG progression. However, there are no

prospective studies exploring the relation between the presence of MvD and the rates of RNFL loss. Here, we examine the presence of MvD at baseline and RNFL changes in patients with NTG in a longitudinal study.

METHODS

This is a longitudinal cohort study. Patients with NTG were recruited from the Wenzhou Glaucoma Progression Study (WGPs), which is a longitudinal study that provides free glaucoma screenings for the Wenzhou community.^{16,17} Written informed consent was obtained from all of the patients. This study was approved by the Ethics Committee of the Wenzhou Medical University, and adheres to the tenets of the Declaration of Helsinki.

Subjects

Glaucoma was defined according to the classifications set by the International Society for Geographical and Epidemiological Ophthalmology (ISGEO) and the Collaborative Normal-Tension Glaucoma Study.^{18,19} The definition of NTG includes an open anterior chamber angle as assessed by gonioscopy, untreated IOP less than 24 mm Hg, a glaucomatous optic disc, and no



secondary causes for glaucoma. Visual field (VF) tests were confirmed on two consecutive reliable tests. Results with fixation loss rates less than 20% or false-positive and false-negative error rates less than 15% were considered reliable VF tests, and were included for further analysis.

The inclusion criteria for this study were as follows: present visual acuity of 6/20 or higher, spherical equivalent (SE) range of -10.0 to $+3.0$ diopter (D), and 18 years of age and older. Patients were excluded if they had a history of ocular surgery (except for glaucoma or uncomplicated cataract intervention), nonglaucomatous optic neuropathy, or severe systemic diseases (except for diabetes mellitus and hypertension).

All patients underwent a comprehensive ophthalmic examination, including presenting visual acuity, Goldmann applanation tonometry, refractive error, slit-lamp biomicroscopy, gonioscopy, dilated fundus examination, measurement of central corneal thickness (CCT) and axial length (AL) by the Lenstar LS 900 biometer (Haag Streit, Bern, Switzerland), stereo disc photography, red-free fundus photography (Visucam 200; Carl Zeiss Meditec, Inc., Dublin, CA, USA), standard automated perimetry (Humphrey Field Analyzer; 24-2 Swedish interactive threshold algorithm; Carl-Zeiss Meditec, Inc.), spectral-domain OCT (SD-OCT; Carl Zeiss Meditec, Inc.), and OCTA (Avanti; Optovue, Inc., Fremont, CA, USA). Medical history of the participants was collected, including clinical records on diabetes mellitus and systemic hypertension. Systolic and diastolic blood pressures (BPs) and pulse rate (PR) were measured at the time of OCTA imaging. The mean arterial pressure (MAP) was calculated as $(\text{diastolic BP} + 1/3 [\text{systolic BP} - \text{diastolic BP}])$. Mean ocular perfusion pressure (MOPP) was calculated as $[2/3 [\text{MAP} - \text{IOP}]]$. OCT and OCTA were repeated at every 3-month follow-up for at least 18 months.

Spectral-Domain OCT Imaging

RNFL thickness was measured using SD-OCT at baseline and at every 3-month follow-up. The details of SD-OCT imaging have been described in a previous study.²⁰ The peripapillary RNFL parameters were automatically analyzed using the OCT version 6.5 software (Carl Zeiss Meditec, Inc.). Patients who completed at least three RNFL measurements of RNFL thickness by OCT imaging were included in this analysis. Poor-quality images with signal strength less than 6 or failed segmentation were excluded.

OCT Angiography Imaging and Determination of the MvD

OCTA images of the optic disc were acquired at baseline visits for enrolled patients. Each image with an area of 4.5×4.5 mm on optic disc was obtained using two volumetric raster patterns, including one horizontal priority and one vertical priority. Images were discarded due to the following situations: (1) the strength index was less than 48; (2) the scan quality was less than 6; and (3) residual artifacts affected optic disc boundaries. Deep retinal layer microvasculature dropout was assessed on the en face images. The specific details have been described in a previous study.¹⁵ MvD was defined as focal sectorial capillary dropout without any visible microvascular network.

Each MvD image was assessed by two independent observers (SL and HC), who were masked from the participant's clinical background. Disagreements between the two observers were resolved by a senior glaucoma specialist (YL).

Statistical Analysis

All statistical analyses were carried out using SPSS (version 12.0; SPSS, Inc., Chicago, IL, USA). The interobserver

agreement of the presence of the MvD was assessed by calculating the kappa coefficient. The comparison of continuous variables between groups with and without MvD was performed using the Student's *t*-test or the Mann-Whitney *U* test, and the categorical variables were analyzed using the χ^2 test. Rates of RNFL loss was calculated using serial measurements of RNFL with a linear regression. A linear mixed model with random intercepts and random slopes was used to assess the predictive factors of rates of RNFL loss. This model was applied if both eyes came from the same individual. Baseline assessments of age, sex, self-reported diabetes mellitus and hypertension, SE, IOP, BP measurement, AL, CCT, presence of MvD, and results of visual field and RNFL thickness were concluded to be predictive factors. Mean IOP during follow-ups was also included in the analysis. In univariate models, only one variable was included to analyze the association between baseline RNFL thickness and rates of RNFL loss (interaction with follow-up time). The predictive factors were also included to evaluate the RNFL rate in the multivariate model, when these factors presented the $P < 0.4$ in univariate models. Statistical significance level was set to $P < 0.05$.

RESULTS

Eighty eyes of 62 patients with NTG met the initial inclusion criteria. Nine were excluded due to poor quality OCTA or SD-OCT images. Ultimately, 71 eyes of 56 patients (23 males and 33 females) were included in the study.

Table 1 summarizes the clinical examinations of patients. Among the 71 eyes, 23 eyes of the 21 patients were found to have MvD (32.4%) at baseline. Interobserver agreement of MvD was good ($k = 0.87$). At baseline and follow up visits, there was no significant difference between eyes with and without MvD for age, sex, follow-up period, IOP at follow-up, SE, AL, CCT, self-reported diabetes mellitus and systemic hypertension, systolic BP, diastolic BP, and PR.

The baseline data showed, compared with eyes without MvD, MvD eyes had a thinner RNFL thickness (68.8 ± 9.6 vs. 76.2 ± 16.7 μm , $P = 0.016$), worse VF MD (-7.1 ± 5.2 vs. -4.5 ± 3.8 dB, $P = 0.027$), worse pattern standard deviation (PSD; 8.1 ± 4.3 vs. 5.2 ± 3.3 dB, $P = 0.012$), higher IOP (16.0 ± 3.2 vs. 13.8 ± 3.3 mm Hg, $P = 0.008$), and lower MOPP (47.5 ± 7.5 vs. 51.7 ± 7.9 mm Hg, $P = 0.037$). Faster rate of RNFL loss (-1.2 ± 1.5 vs. -0.4 ± 1.4 $\mu\text{m}/\text{y}$, $P = 0.036$) was also observed in MvD eyes compared with non-MvD eyes, respectively, during the follow-up.

Table 2 summarizes the predictive factors of baseline RNFL thickness and RNFL rates in univariate models. In univariate analysis of baseline RNFL thickness, the presence of MvD ($\beta = -7.30 \pm 3.02$, $P = 0.018$) and lower VF MD ($\beta = -0.76 \pm 0.32$, $P = 0.021$) were significantly associated with thinner baseline RNFL thickness. In univariate analysis of rates of RNFL loss, the presence of MvD ($\beta = -0.83 \pm 0.38$, $P = 0.033$) and female sex ($\beta = -1.03 \pm 0.35$, $P = 0.004$) were significantly associated with faster rates of RNFL loss.

Table 3 shows a multivariate model of rates of RNFL loss. Even after adjusting for age, mean follow-up IOP, AL, CCT, and MD, the presence of MvD at baseline ($\beta = -0.85 \pm 0.41$, $P = 0.041$) and female sex ($\beta = -0.82 \pm 0.39$, $P = 0.040$) were still significantly related to faster rates of RNFL loss in the multivariate analysis.

DISCUSSION

The present study shows that NTG eyes with MvD tend to have a thinner RNFL than those without MvD. In either the univariate or multivariate model of RNFL loss rate, MvD was

TABLE 1. Clinical Characteristics of the Eyes With or Without Microvasculature Dropout

Clinical Characteristics	Eyes With MvD (23 Eyes From 21 Patients)	Eyes Without MvD (48 Eyes From 41 Patients)	P Value
Age, y (patients)	60.8 ± 15.8	60.1 ± 12.3	0.652*
Sex, male/female (patients)	6/15	20/21	0.123†
Follow-up period, mo	23.9 ± 4.3	25.1 ± 2.9	0.277‡
Self-reported of diabetes mellitus, <i>n</i> (%) (patients)	1 (4.8)	9 (22.0)	0.058†
Self-reported of systemic hypertension, <i>n</i> (%) (patients)	4 (19.0)	14 (34.1)	0.215†
SE, D	−0.8 ± 2.8	−0.5 ± 2.3	0.650‡
IOP at baseline, mm Hg	16.0 ± 3.2	13.8 ± 3.3	0.008‡
IOP at follow-up, mm Hg	15.4 ± 2.1	14.4 ± 2.4	0.087‡
Systolic BP, mm Hg (patients)	119.0 ± 13.1	125.1 ± 16.5	0.145‡
Diastolic BP, mm Hg (patients)	71.2 ± 10.0	73.5 ± 10.3	0.386‡
MOPP, mm Hg	47.5 ± 7.5	51.7 ± 7.9	0.037*
PR, bpm (patients)	74.5 ± 13.5	74.9 ± 11.0	0.704‡
AL, mm	23.9 ± 1.1	23.7 ± 1.3	0.572*
CCT, μm	530.1 ± 28.5	544.8 ± 39.3	0.079‡
Baseline MD, dB	−7.1 ± 5.2	−4.5 ± 3.8	0.027*
Baseline PSD, dB	8.1 ± 4.3	5.2 ± 3.3	0.012*
Baseline RNFL thickness, μm	68.8 ± 9.6	76.2 ± 16.7	0.016‡
Rate of RNFL loss, μm/y	−1.2 ± 1.5	−0.4 ± 1.4	0.036‡

Boldface presents the significance.

* Mann-Whitney *U* test.

† X² test.

‡ Independent samples *t*-test.

significantly associated with progressive RNFL loss. The present results suggest a significant relationship between MvD and the progression of glaucomatous optic neuropathy in patients with NTG.

The baseline data in the study are consistent with those of Suh et al.¹⁵ and Lee et al.,²¹ who report that thinner circumpapillary RNFL thickness was observed in eyes with MvD. Our results further imply the involvement of MvD in glaucomatous neuropathy.

The prospective design of our study enabled us to find that MvD is associated with RNFL thinning. This study demonstrated that eyes with MvD tended to have a faster rate of RNFL loss. Consistent with our results, a previous retrospective study by Park et al.²² also reported that eyes with MvD are more likely to

have RNFL thinning during the past 5 years. However, causality cannot be established based on our current data. MvD may be either the source or the result of a RNFL defect, or even may be an accompanying phenomenon. On one hand, eyes with disc hemorrhage have a higher prevalence of MvD. Therefore, MvD may damage optic nerve head and promote glaucomatous progression.²² On the other hand, there is a unique structure in the central nervous system called neurovascular coupling. Neuron activity may sensitively regulate the local blood flow.²³ Defects in the RNFL may decrease the demand for blood supply, and therefore lead to the MvD.²⁴ In addition, recent studies^{25,26} demonstrated that lamina cribrosa (LC) promotes the onset of glaucomatous optic nerve damage, and the deformation of LC may eventually lead to the presence of MvD.

TABLE 2. Univariate Linear Mixed-Effects Model of Retinal Nerve Fiber Layer at Baseline and Rate in Glaucomatous Eyes

Variables	Effect on Baseline RNFL Thickness		Effect on Rate of RNFL Thickness	
	β1 ± Standard Error	P Value	β2 ± Standard Error	P Value
Age, per 10-y older	0.32 ± 1.17	0.784	−0.13 ± 0.14	0.384
Sex, female	1.84 ± 2.86	0.538	−1.03 ± 0.35	0.004
Self-reported of diabetes mellitus (yes versus no)	6.80 ± 3.71	0.071	0.25 ± 0.47	0.592
Self-reported of systemic hypertension (yes versus no)	−1.13 ± 3.17	0.724	0.22 ± 0.39	0.577
SE, per 1 D lower	0.70 ± 0.60	0.242	−0.01 ± 0.08	0.869
Baseline IOP, per 1 mm Hg higher	−0.67 ± 0.43	0.123	0.01 ± 0.05	0.815
Mean follow-up IOP, per 1 mm Hg higher	−0.63 ± 0.63	0.324	0.07 ± 0.08	0.320
Systolic BP, per 1 mm Hg higher	−0.04 ± 0.09	0.645	0.00 ± 0.01	0.515
Diastolic BP, per 1 mm Hg higher	−0.06 ± 0.15	0.686	0.01 ± 0.02	0.646
MOPP, per 1 mm Hg higher	−0.00 ± 0.19	0.999	0.01 ± 0.02	0.551
PR, per 1 bpm higher	−0.19 ± 0.13	0.136	0.01 ± 0.02	0.819
AL, per 1 mm higher	−1.56 ± 1.22	0.207	0.24 ± 0.15	0.116
CCT, per 10 μm higher	0.58 ± 0.40	0.147	0.06 ± 0.05	0.258
Presence of MvD at baseline (yes versus no)	−7.30 ± 3.02	0.018	−0.83 ± 0.38	0.033
Baseline MD, per 1 dB lower	−0.76 ± 0.32	0.021	−0.04 ± 0.04	0.364
Baseline PSD, per 1 dB higher	−0.62 ± 0.38	0.109	−0.04 ± 0.05	0.358
Baseline RNFL thickness, per 1 μm lower	N/A	N/A	−0.00 ± 0.02	0.565

Boldface presents the significance.

TABLE 3. Multivariate Linear Mixed-Effects Model of Rate of Retinal Nerve Fiber Layer Loss in Glaucomatous Eyes

Variables	Effect on Rate of RNFL Thickness	
	$\beta \pm$ Standard Error	P Value
Age, per 10-y older	-0.10 ± 0.16	0.535
Sex, female	-0.82 ± 0.39	0.040
Mean follow-up IOP, per 1 mm Hg higher	0.12 ± 0.08	0.130
AL, per 1 mm higher	0.11 ± 0.18	0.541
CCT, per 10 μ m higher	0.00 ± 0.05	0.965
Presence of MvD at baseline (yes versus no)	-0.85 ± 0.41	0.041
Baseline MD, per 1 dB lower	-0.01 ± 0.04	0.130

Boldface presents the significance.

In our study, MvD at baseline was more frequent in eyes with glaucomatous progression during follow-up (Fig.). This tentatively suggests a prior onset of MvD to the RNFL thickness. Further investigations are needed for a complete understanding of the underlying mechanisms.

This study found that higher IOP and lower MOPP are associated with the presence of MvD in patients with NTG. A study by Zhang et al.²⁷ showed that lower choroidal thickness is associated with increased IOP in patients with glaucoma. In addition, Lee et al.¹⁴ demonstrated that the presence of MvD has a significant association with smaller mean juxtapapillary choroidal thickness compared with eyes without MvD. In a previous study, Drance et al.²⁸ reported that sex was related to glaucoma progression in NTG. Our study found that female patients with NTG tend to have a faster RNFL loss.

The strengths of this study are listed below. First, this is a longitudinal cohort study to explore the relation between MvD and progressive RNFL loss with at least 18 months of follow-up. Second, to overcome the effect of IOP, only patients with NTG were included to investigate the role of MvD in glaucoma progression.

The present study has several limitations. First, the sample size was not very large. Furthermore, we did not have any healthy patients as control subjects. However, it has been demonstrated that no prevalence of MvD was observed in the eyes of healthy patients.¹⁸ Second, we evaluated the presence of MvD using a qualitative method, which may lead to variation in results. However, our results produced a good interobserver agreement ($\kappa = 0.87$), indicating this to be of little concern. Finally, our follow-up periods were not long enough for a long-term glaucoma progression assessment. Further studies are required to elucidate the mechanism between MvD and glaucomatous damage.

In conclusion, MvD at baseline was significantly related to progressive RNFL thinning in patients with NTG. Our study further supported that the presence of MvD is a predictor of longitudinal glaucoma structural damage.

Acknowledgments

Supported by Wenzhou Medical University Research Fund (No. QTJ13009; Wenzhou, Zhejiang, China), Zhejiang Province Health Innovation Talents project (No. 2016025; Wenzhou, Zhejiang, China), and Public Project of Zhejiang Province (No. 2017C33117; Wenzhou, Zhejiang, China).

Disclosure: **S. Lin**, None; **H. Cheng**, None; **S. Zhang**, None; **C. Ye**, None; **X. Pan**, None; **A. Tao**, None; **X. Xu**, None; **J. Qu**, None; **Y. Liang**, None

References

- Weinreb RN, Khaw PT. Primary open-angle glaucoma. *Lancet*. 2004;363:1711-1720.
- De Moraes CG, Liebmann JM, Levin LA. Detection and measurement of clinically meaningful visual field progression in clinical trials for glaucoma. *Prog Retin Eye Res*. 2016;56:107-147.
- Kwon YH, Fingert JH, Kuehn MH, Alward WL. Primary open-angle glaucoma. *N Engl J Med*. 2009;360:1113-1124.
- Mammo Z, Heisler M, Balaratnasingam C, et al. Quantitative optical coherence tomography angiography of radial peripapillary capillaries in glaucoma, glaucoma suspect and normal eyes. *Am J Ophthalmol*. 2016;170:41-49.
- Triolo G, Rabiolo A, Shemonski ND, et al. Optical coherence tomography angiography macular and peripapillary vessel perfusion density in healthy subjects, glaucoma suspects, and glaucoma patients. *Invest Ophthalmol Vis Sci*. 2017;58:5713-5722.
- Akil H, Chopra V, Alsheikh M, et al. Swept-source OCT angiography imaging of the macular capillary network in glaucoma [published online ahead of print August 9, 2017]. *Br J Ophthalmol*. doi:10.1136/bjophthalmol-2016-309816.
- Xu H, Zhai R, Zong Y, et al. Comparison of retinal microvascular changes in eyes with high-tension glaucoma

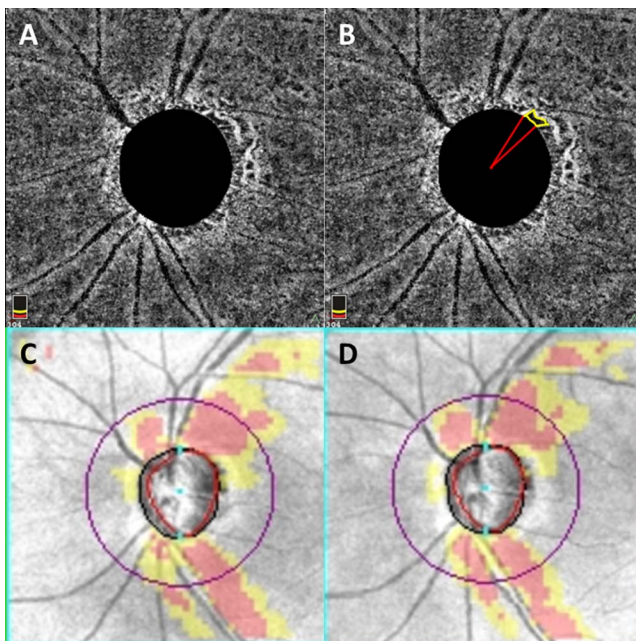


FIGURE. A representative case with microvasculature dropout. A 76-year-old woman with NTG showing the MvD at baseline. (A) The original OCTA image and (B) yellow outline indicating the location of MvD, (C) baseline RNFL loss, and (D) during 2 years' follow-up, the progressive RNFL thinning.

- or normal-tension glaucoma: a quantitative optic coherence tomography angiographic study. *Graefes Arch Clin Exp Ophthalmol*. 2018;256:1179-1186.
8. Yamamoto T, Kitazawa Y. Vascular pathogenesis of normal-tension glaucoma: a possible pathogenetic factor, other than intraocular pressure, of glaucomatous optic neuropathy. *Prog Retin Eye Res*. 1998;17:127-143.
 9. Maltsev DS, Kulikov AN, Chhablani J. Topography-guided identification of leakage point in central serous chorioretinopathy: a base for fluorescein angiography-free focal laser photocoagulation. *Br J Ophthalmol*. 2018;102:1218-1225.
 10. Parodi MB, Romano F, Cicinelli MV, et al. Retinal vascular impairment in best vitelliform macular dystrophy assessed by means of optical coherence tomography angiography. *Am J Ophthalmol*. 2018;187:61-70.
 11. Kim K, Kim ES, Yu SY. Optical coherence tomography angiography analysis of foveal microvascular changes and inner retinal layer thinning in patients with diabetes. *Br J Ophthalmol*. 2018;102:126-1231.
 12. Lee EJ, Kim TW, Kim JA, Kim JA. Central visual field damage and parapapillary choroidal microvasculature dropout in primary open-angle glaucoma. *Ophthalmology*. 2018;125:588-596.
 13. Lee EJ, Lee KM, Lee SH, Kim TW. Parapapillary choroidal microvasculature dropout in glaucoma: a comparison between optical coherence tomography angiography and indocyanine green angiography. *Ophthalmology*. 2017;124:1209-1217.
 14. Lee SH, Lee EJ, Kim TW. Topographic correlation between juxtapapillary choroidal thickness and parapapillary deep-layer microvasculature dropout in primary open-angle glaucoma. *Br J Ophthalmol*. 2018;102:1134-1140.
 15. Suh MH, Zangwill LM, Manalastas PI, et al. Deep retinal layer microvasculature dropout detected by the optical coherence tomography angiography in glaucoma. *Ophthalmology*. 2016;123:2509-2518.
 16. Liang Y, Jiang J, Ou W, et al. Effect of community screening on the demographic makeup and clinical severity of glaucoma patients receiving care in urban China. *Am J Ophthalmol*. 2018;195:1-7.
 17. Jiang J, Zhang C, Peng X, et al. Senile eye disease screening program in downtown Wenzhou: intraocular pressure. *Zhonghua Yan Ke Za Zhi*. 2018;11;54:586-592.
 18. Foster PJ, Buhrmann R, Quigley HA, Johnson GJ. The definition and classification of glaucoma in prevalence surveys. *Br J Ophthalmol*. 2002;86:238-242.
 19. Collaborative Normal-Tension Glaucoma Study Group. Comparison of glaucomatous progression between untreated patients with normal-tension glaucoma and patients with therapeutically reduced intraocular pressures. *Am J Ophthalmol*. 1998;126:487-497.
 20. Nassif N, Cense B, Park BH et al. In vivo human retinal imaging by ultrahighspeed spectral domain optical coherence tomography. *Opt Lett*. 2004;29:480-482.
 21. Lee EJ, Kim TW, Kim JA, Kim JA. Parapapillary deep-layer microvasculature dropout in primary open-angle glaucoma eyes with a parapapillary γ -zone. *Invest Ophthalmol Vis Sci*. 2017;58:5673-5680.
 22. Park HYL, Jin WK, Chan KP. Choroidal microvasculature dropout is associated with progressive retinal nerve fiber layer thinning in glaucoma with disc hemorrhage. *Ophthalmology*. 2018;125:1003-1013.
 23. Shih AY, Driscoll JD, Drew PJ, Nishimura N, Schaffer CB, Kleinfeld D. Two-photon microscopy as a tool to study blood flow and neurovascular coupling in the rodent brain. *J Cereb Blood Flow Metab*. 2012;32:1277-1309.
 24. Alnawaiseh M, Lahme L, Müller V, Rosentreter A, Eter N. Correlation of flow density, as measured using optical coherence tomography angiography, with structural and functional parameters in glaucoma patients. *Graefes Arch Clin Exp Ophthalmol*. 2018;256:1-9.
 25. Lee EJ, Kim TW, Kim M, Girard MJ, Mari JM, Weinreb RN. Recent structural alteration of the peripheral lamina cribrosa near the location of disc hemorrhage in glaucoma. *Invest Ophthalmol Vis Sci*. 2014;28;55:2805-2815.
 26. Kim YK, Park KH. Lamina cribrosa defects in eyes with glaucomatous disc haemorrhage. *Acta Ophthalmol*. 2016;94:e468-e473.
 27. Zhang X, Cole E, Pillar A, et al. The effect of change in intraocular pressure on choroidal structure in glaucomatous eyes. *Invest Ophthalmol Vis Sci*. 2017;58:3278-3285.
 28. Drance S, Anderson DR, Schulzer M. Risk factors for progression of visual field abnormalities in normal-tension glaucoma. *Am J Ophthalmol*. 2001;131:699-708.