

Concentric Choriocapillaris Flow Deficits in Retinitis Pigmentosa Detected Using Wide-Angle Swept-Source Optical Coherence Tomography Angiography

Manabu Miyata, Akio Oishi, Tomoko Hasegawa, Maho Oishi, Shogo Numa, Yuki Otsuka, Akihito Uji, Shin Kadomoto, Masayuki Hata, Hanako Ohashi Ikeda, and Akitaka Tsujikawa

Department of Ophthalmology and Visual Sciences, Kyoto University Graduate School of Medicine, Sakyo-ku, Kyoto, Japan

Correspondence: Manabu Miyata, Department of Ophthalmology and Visual Sciences, Kyoto University Graduate School of Medicine, Shogoin Kawahara-cho 54, Sakyo-ku, Kyoto 606-8507, Japan; miyatam@kuhp.kyoto-u.ac.jp.

Submitted: November 8, 2018
Accepted: February 20, 2019

Citation: Miyata M, Oishi A, Hasegawa T, et al. Concentric choriocapillaris flow deficits in retinitis pigmentosa detected using wide-angle swept-source optical coherence tomography angiography. *Invest Ophthalmol Vis Sci*. 2019;60:1044–1049. <https://doi.org/10.1167/iovs.18-26176>

PURPOSE. We investigate whether choriocapillaris deficits can be visualized in patients with retinitis pigmentosa (RP) using wide-angle swept-source optical coherence tomography angiography (OCTA), and whether angiography or structure en face images depict a wider area of residual choriocapillaris.

METHODS. This cross-sectional study included 43 eyes of 43 consecutive patients with RP with a visual acuity ≥ 0.1 , and 12 healthy eyes of 12 volunteers. Using an OCTA device (PLEX Eite 9000), we obtained angiography and structure en face images in the choriocapillaris. The residual choriocapillaris area in a 12×12 mm macular cube was measured manually.

RESULTS. In patients with RP, the residual choriocapillaris area was 113.1 ± 41.9 and 64.0 ± 47.8 mm² in angiography and structure images, respectively ($P < 0.001$). Concentric and vermicular choriocapillaris flow deficits were observed in 10 (23%) and 17 (40%) eyes of RP patients, respectively; no deficits were observed in 16 eyes (37%). Mean age was higher in eyes with concentric, vermicular, and nondeficit choriocapillaris. No healthy eye showed choriocapillaris deficits.

CONCLUSIONS. Using wide-angle swept-source OCTA, concentric and vermicular choriocapillaris flow deficits were observed in the eyes of RP patients. A comparison of angiography and structure en face images of the choriocapillaris in RP cases suggests that angiography images can evaluate a wider area of the choriocapillaris than structure images.

Keywords: retinitis pigmentosa, swept-source OCT, choriocapillaris, optical coherence tomography angiography, retinal pigment epithelium

Retinitis pigmentosa (RP) is a progressive hereditary disease characterized by the primary impairment of rod photoreceptors. Its symptoms include concentric visual field loss, night blindness, and vision loss.¹ Recent advances in retinal imaging, especially optical coherence tomography (OCT), have enabled detailed evaluations of the inner retina,^{2,3} RPE,^{4,5} choroid,^{6,7} and photoreceptors.^{8,9} However, evaluation of the choriocapillaris, which directly nourishes the outer retina has been challenging.

OCT angiography (OCTA) is a fast, noninvasive, safe, cost-effective, and easily performed imaging method that provides depth-resolved information of retinal and choroidal blood flow in cases of various diseases^{10–15} that cannot be acquired using OCT. For instance, macular microvascular changes were shown in patients with RP using spectral-domain OCTA.^{14,15} Recently, our research group detected choriocapillaris deficits in patients with another inherited retinal dystrophy, Bietti crystalline dystrophy, using spectral-domain OCTA.¹⁶ Although previous studies showed that choriocapillaris blood flow in RP cases was not different from the blood flow of controls,^{14,17} it is unlikely that the choriocapillaris is totally preserved in RP cases considering that choriocapillaris loss was observed histopathologically.¹⁸ Also, previous studies were limited by the angle of view provided by spectral-domain OCTA.

The performance of OCT devices is improving continuously; wide-angle OCTA is an example of such technological progress. While the angle of view was limited to 3×3 mm ($10^\circ \times 10^\circ$) in previous OCTA models, a recent device enabled imaging of a 12×12 mm ($40^\circ \times 40^\circ$) area at once. Considering that visual field deficits and photoreceptor cell death start in the midperipheral retina and progress in a concentric manner in RP pathology, the new wide-angle OCTA technology may facilitate acquisition of data that can show perifoveal choriocapillaris changes. Furthermore, the latest model uses longer wavelengths for light sources (1050 nm in swept-source OCTA) compared to conventional spectral-domain OCTA (840 nm); therefore, it is superior for acquiring images beneath the RPE in detail. Some reports have confirmed the superiority of swept-source OCTA to demarcate the full extent of choroidal neovascularization compared to spectral-domain OCTA.^{19,20} Taken together, swept-source and wide-angle OCTA would be suitable techniques to estimate the choriocapillaris blood flow in RP cases. Nevertheless, the superiority of angiography or structure en face images for evaluating the choriocapillaris has not been investigated in RP to our knowledge. We investigated whether choriocapillaris deficits can be visualized in patients with RP using en face wide-angle and swept-source OCTA images, and whether angiography or structure en face images can more widely show the residual choriocapillaris area.



MATERIALS AND METHODS

This cross-sectional study was part of an ongoing genotype-phenotype study that was approved by the ethics committee at the Kyoto University Graduate School of Medicine (Kyoto, Japan). Healthy eyes were selected by another study using OCTA approved by the same committee. Study protocols adhered to the tenets of the Declaration of Helsinki. After receiving an explanation of the possible risks and benefits of participation, participating individuals provided written informed consent.

Participants

We recruited consecutive patients with retinal degenerative disease who visited the Department of Ophthalmology and Visual Sciences at Kyoto University Graduate School of Medicine between July 2018 and August 2018. All patients underwent a comprehensive ophthalmologic examination, including autorefractometry, best-corrected visual acuity (VA) using a decimal VA chart (Landolt chart), axial length (AL) using an IOLMaster (Carl Zeiss Meditec, Inc., Dublin, CA, USA), as well as indirect ophthalmoscopy, slit-lamp biomicroscopy, color fundus photography, and fundus autofluorescence using a wide-field scanning laser ophthalmoscope (Optos, Optos PLC; Dunfermline, UK; Figs. 1K–N), and spectral-domain OCT (Spectralis HRA+OCT; Heidelberg Engineering, Heidelberg, Germany). A Humphrey field analyzer (Carl Zeiss Meditec) was used to calculate mean deviation (MD) values, using the 10-2 Swedish Interactive Threshold Algorithm standard program, to evaluate macular sensitivity. LS-C (Mayo Co., Nagoya, Japan) and Neuropack MEB-2204 (Nihon Kohden, Tokyo, Japan) systems were used to record electroretinograms. Retinal specialists used the data from these clinical examinations to diagnose RP.

Using an OCTA device (PLEX Eite 9000, Carl Zeiss Meditec, Dublin, CA, USA), angiography and structure en face images also were acquired from patients who met our criteria. Our inclusion criterion was an RP diagnosis with a VA \geq 0.1, because, in our experience, it is difficult to obtain high-quality OCTA images in patients with RP and a low VA.¹⁴ Exclusion criteria were the presence of other ocular diseases except for refractive errors, cataracts, or pseudophakia; poor en face image quality resulting in ungradable data; and sectoral RP. When both eyes of a patient were eligible, the right eye was selected for analysis and the interocular difference also was analyzed. To interpret the angiography and structure en face images in patients with RP, data of age- and AL-matched healthy unilateral eyes from volunteers were reviewed. We obtained angiography and structure en face images and measured the AL for volunteers via the same methods used for the patients.

Acquisition of En Face Images of the Choriocapillaris and Analysis of the Residual Choriocapillaris

Trained examiners obtained angiography and structure en face images within a 12 × 12-mm area, the maximum square range in this modality, centered on the fovea (300 A- and 300 B-scans) using a PLEX Elite 9000 that uses a swept laser source with a central wavelength of 1050 nm and operates at 100,000 A-scans per second. A fully-automated segmentation algorithm using built-in software was applied to the three-dimensional structural OCT data to segment the choriocapillaris slab as reported previously (20 μ m thick starting 29 μ m posterior to the RPE or Bruch's membrane fit reference; the default setting

in this device).²¹ When a significant segmentation error occurred, we manually modified the segmentation.

We compared angiography (Figs. 1A–E) and structure (Figs. 1F–J) en face images in the same choriocapillaris slab. One investigator (MM) used Image J software (National Institutes of Health, Bethesda, MD, USA) to manually measure the residual choriocapillaris area in the en face images of a 12 × 12 mm macular cube (144 mm²; Fig. 2). Based on the appearance of the angiography images, we divided eyes into concentric (Figs. 1A, 1B, concentric group), vermicular (Fig. 1C, vermicular group), and nondeficit (Fig. 1D, nondeficit group) categories.

Statistical Analysis

Data are presented as means \pm SD when applicable. We converted decimal VA values to logMAR for statistical analyses. Paired and unpaired *t*-tests and χ^2 tests were used for comparisons between groups when applicable. The three groups were compared via 1-way ANOVA and post hoc analysis with Tukey's or Games-Howell tests, in accordance with results of the variance equality assessment. Spearman's rank correlation coefficients were used to analyze the associations among visual function (logMAR and MD value), age, AL, and the residual choriocapillaris area in angiography and structure en face images. Because we considered that evaluation of the residual choriocapillaris is underestimated in the vermicular and nondeficit groups due to the angle of view in the 12 × 12 mm square, we also performed a subanalysis, but only in the concentric group. All statistical analyses were performed using SPSS version 21 software (IBM Corp., Armonk, NY, USA). *P* < 0.05 was considered statistically significant.

RESULTS

We enrolled 43 patients (age, 47.4 \pm 15.8 years; 25 women). For all eyes, en face images were suitable for analysis without the necessity for segmentation modification. Table 1 shows the ocular characteristics of the study population. There were no significant interocular differences in study parameters. The residual choriocapillaris was significantly larger in angiography than in structure images (113.1 \pm 41.9 and 64.0 \pm 47.8 mm², respectively, *P* < 0.001). Concentric choriocapillaris flow deficits (concentric group) were observed in 10 (23%) of 43 eyes in angiography images within the 12 × 12 mm macular square. Vermicular or partial choriocapillaris deficits (vermicular group) were observed in 17 eyes (40%). No choriocapillaris flow deficits (nondeficit group) were observed in 16 eyes (37%). Also, none of the 12 age- and AL-matched healthy eyes of the 12 volunteers (age, 47.7 \pm 22.5 years, *P* = 0.97; AL, 24.70 \pm 1.26, *P* = 0.25) showed choriocapillaris deficits (Figs. 1E, 1J). When comparing concentric, vermicular, and nondeficit groups, age was higher when comparing the concentric to the vermicular group (*P* = 0.04) and the vermicular to the nondeficit group (*P* = 0.03; Table 2).

Table 3 shows the correlation between visual function and other study parameters. The residual choriocapillaris areas in angiography and structure images were not significantly correlated with logMAR and MD values. Subanalyses of the concentric group (*n* = 10), in which the border of the residual choriocapillaris area can be marked accurately, revealed that the residual choriocapillaris area of the angiography images was correlated with MD values (*P* = 0.03, *r* = 0.70); however, it was not correlated with logMAR (*P* = 0.81). Structure images of the residual choriocapillaris area showed the same trend, although the correlation was not statistically significant (with MD, *P* = 0.11 and with logMAR, *P* = 0.39).

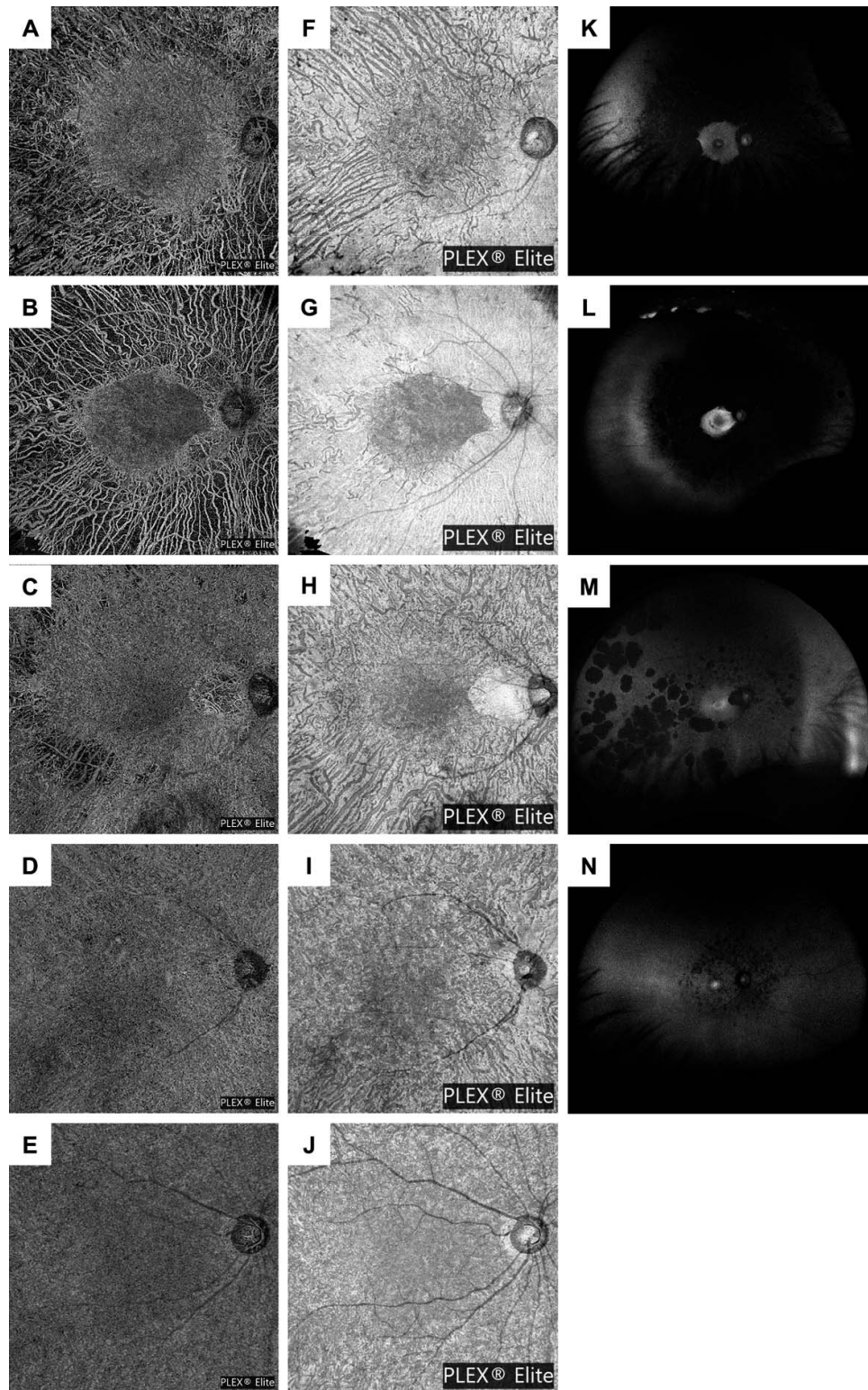


FIGURE 1. Representative angiography and structure en face images of choriocapillaris layers and images acquired with a wide-field scanning laser ophthalmoscope in eyes with RP and a healthy eye. (A–E) Representative angiography en face images. (F–J) Representative structure en face images. (K–N) Representative autofluorescent images taken with a wide-field scanning laser ophthalmoscope as references. (A, F, K) Concentric choriocapillaris deficits were observed in the right eye of a 50-year-old male patient with a visual acuity of 0.3. The choriocapillaris areas of the angiography and structure en face images were 48.5 and 23.3 mm², respectively. (B, G, L) Concentric choriocapillaris deficits were observed in the right eye of a 64-year-old female patient with a visual acuity of 0.9. The choriocapillaris areas of the angiography and structure en face images were 24.4 and 18.5 mm², respectively. (C, H, M) Vermicular (partial) choriocapillaris deficits were observed in the right eye of a 46-year-old female patient with a visual acuity of 1.0. The choriocapillaris areas of the angiography and structure en face images were 126.5 and 39.2 mm², respectively. (D, I, N) No deficits were observed in the right eye of a 23-year-old male patient with a visual acuity of 0.3. The choriocapillaris areas of the angiography and structure en face images were 144.0 and 118.2 mm², respectively. (E, J) No choriocapillaris deficits were observed in the right eye of a 42-year-old normal volunteer without eye disease.

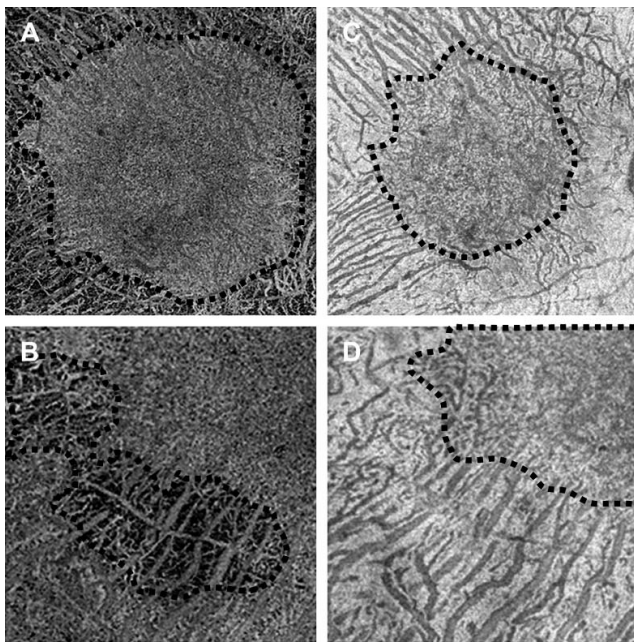


FIGURE 2. Representative magnified angiography and structure en face images of choriocapillaris layers used to draw border lines to separate areas with and without choriocapillaris. (A, B) Representative angiography en face images. (C, D) Representative structure en face images. The border lines (*broken lines*) could be drawn to separate areas with and without choriocapillaris in the right eye of a patient of the concentric group (A, C), corresponding to Figure 1A and 1F, and in the right eye of a patient of the vermicular group, corresponding to tempo-inferior lesions of Figure 1C and 1H. The degree of magnification is the same as in (A) and (C), and in (B) and (D).

DISCUSSION

We demonstrated concentric and vermicular choriocapillaris flow deficits in patients with RP using wide-angle swept-source OCTA. These findings could not be detected by conventional angle OCTA with an image area of $3 \times 3 \text{ mm}^2$ because the maximum circle area detectable in a $3 \times 3 \text{ mm}$ square is 7.1 mm^2 , based on a 1.5-mm diameter, and the minimum area of the residual choriocapillaris area was 22.7 mm^2 in our study population. Thus, in our study, angiography en face images (OCTA) revealed more vasculature data than structure en face images (OCT). Furthermore, the border of the choriocapillaris

was more clearly demarcated in angiography images. Considering that OCTA represents a motion decorrelation signal that arises from the blood flow in the retina, we assert that the choriocapillaris area depicted in angiography en face images is more accurate than that depicted with structure en face images. RP was a good model to compare the appearance of the choriocapillaris area in angiography and structure images because of its pattern of concentric damage of the retina and choroid.

Previous cross-sectional studies using spectral-domain OCTA with a $3 \times 3 \text{ mm}$ image area showed that the choriocapillaris blood flow in patients with RP was not different from those of controls.^{14,17} A recent longitudinal study showed no changes in the choriocapillaris blood flow in a $3 \times 3 \text{ mm}$ area during 1.3 ± 0.5 years of follow-up.²² However, changes in choriocapillaris deficits would be difficult to detect using narrow-angle OCTA. Also, our results indicated that choriocapillaris damage occurs concentrically. Even in a $12 \times 12 \text{ mm}$ image area, concentric and vermicular choriocapillaris deficits were observed in only 23% and 40% of the cases, respectively. Hence, observations using narrow-angle OCTA may miss these changes entirely. OCTA with a wider angle than that used in our study is needed to detect the deficits in more cases. Central choriocapillaris blood flow remains until late-stage RP, at least until visual acuity declines to <0.4 . Meanwhile, in the early stages when choriocapillaris changes may occur only in the periphery, even the $12 \times 12 \text{ mm}$ OCTA detected no changes in 37% of our cases. Overall, the current wide-field OCTA technology would be suitable to evaluate the choriocapillaris status in moderate stages of RP.

Our results indicated that visual function was not correlated with the residual choriocapillaris area. This could be because we could not evaluate the residual choriocapillaris outside the $12 \times 12 \text{ mm}$ area, which corresponds to $40 \times 40^\circ$. Thus, measurements of the residual choriocapillaris area in our study would have a ceiling effect. If the whole residual choriocapillaris area could be evaluated, the results may be more informative. In fact, in the subanalysis of the concentric group in which the whole residual choriocapillaris area was evaluated, there was a significant correlation between the residual choriocapillaris area and MD values despite the small sample size ($n = 10$).

There were no interocular differences in the study parameters, including the residual choriocapillaris area. These findings indicated that damage to the choriocapillaris progresses with similar speed between both eyes in patients with RP. A previous study reported that interocular symmetry generally

TABLE 1. Characteristics of the Patients with RP

Clinical Values	Selected Eyes	Fellow Eyes	P Value (Interocular Difference)
N		43	
Age (years)		47.4 ± 15.8	
Female sex, eyes (%)		25 (58)	
Right eye, N	43	0	
LogMAR	0.19 ± 0.27	0.23 ± 0.32	0.18
Mean deviation value (dB)	-16.40 ± 9.79	-16.97 ± 10.01	0.15
Axial length (mm)	24.12 ± 1.58	24.07 ± 1.60	0.31
Residual choriocapillaris area in angiography images within $12 \times 12 \text{ mm}$ (mm^2)	113.1 ± 41.9	112.3 ± 43.6	0.51
Residual choriocapillaris area in structure images within $12 \times 12 \text{ mm}$ (mm^2)	64.0 ± 47.8	64.2 ± 49.4	0.89

Data are presented as mean \pm SD where applicable. The interocular differences were analyzed using paired *t*-tests (statistical significance, $P < 0.05$).

TABLE 2. Comparison Among Concentric, Vermicular, and Nondeficit Groups

Clinical Values	Concentric, Group (1)	Vermicular, Group (2)	Nondeficit, Group (3)	P Value		
				(1) vs. (2)	(2) vs. (3)	(1) vs. (3)
N (%)	10 (23)	17 (40)	16 (37)			
Age (years)	61.3 ± 10.1	49.2 ± 11.9	36.8 ± 15.5	0.04*	0.03*	< 0.001*
Female sex, N	5	11	9	0.88	0.75	0.95
LogMAR	0.31 ± 0.25	0.11 ± 0.27	0.20 ± 0.27	0.61	0.15	0.54
Mean deviation value (dB)	-18.30 ± 7.85	-15.11 ± 10.92	-16.59 ± 10.00	0.90	0.70	0.91
Axial length (mm)	23.63 ± 1.55	24.31 ± 1.65	24.22 ± 1.57	0.99	0.55	0.64
Residual choriocapillaris area in angiography images within 12 × 12 mm (mm ²)	44.7 ± 20.2	124.1 ± 19.1	144.0 ± 0	0.002*	0.002*	< 0.001*
Residual choriocapillaris area in structure images within 12 × 12 mm (mm ²)	23.0 ± 12.5	61.9 ± 42.8	91.9 ± 48.8	0.16	0.006*	< 0.001*

Data are presented as mean ± SD where applicable. Eyes with concentric, vermicular, and no choriocapillaris flow deficits observed in angiography images were assigned into concentric, vermicular, and nondeficit groups, respectively. One-way ANOVA was used for comparison.

* Statistical significance (P < 0.05).

exists in patients with RP; however, there were interocular difference variations with the use of various visual field analyzer metrics.²³ Other methods might lead to interocular differences in residual choriocapillaris area measurements.

Our study had some limitations. First, we could not evaluate eyes with low visual acuity because it is challenging to obtain OCTA images suitable for analysis in such cases, based on our previous experience.^{14,16} Although PLEX Elite has a tracking-eye system, the system often could not obtain OCTA images with acceptable quality in such eyes. If we could obtain images of eyes in patients with low vision, the prevalence of concentric and vermicular choriocapillaris flow deficits would likely increase, and the correlation between the residual choriocapillaris area and visual function may change. Second, the angle of the images remained limited while using PLEX Elite technology. Thus, we could not assess the whole residual choriocapillaris area in eyes without flow deficits. Further improvements to OCTA modalities may resolve the aforementioned problems. Third, the sample size, particularly in the subanalysis of the concentric group, was small. Further studies with larger sample sizes are required for a better understanding. Fourth, genetic effects could not be analyzed because of the small sample size with complete genetic diagnoses.

In conclusion, using wide-angle and swept-source OCTA, concentric and vermicular choriocapillaris blood flow deficits were observed in patients with RP. A comparison of angiography and structure en face images of the choriocapillaris in RP cases suggested that angiography images can

evaluate a wider area of the choriocapillaris than structure images.

Acknowledgments

Supported by a grant-in-aid for scientific research (number 18K09444) from the Japan Society for the Promotion of Science, Tokyo, Japan. This organization did not have role in the design or conduct of this research.

Disclosure: M. Miyata, None; A. Oishi, None; T. Hasegawa, None; M. Oishi, None; S. Numa, None; Y. Otsuka, None; A. Uji, None; S. Kadomoto, None; M. Hata, None; H.O. Ikeda, None; A. Tsujikawa, None

References

- Hartong DT, Berson EL, Dryja TP. Retinitis pigmentosa. *Lancet*. 2006;368:1795-1809.
- Vamos R, Tatrai E, Nemeth J, Holder GE, DeBuc DC, Somfai GM. The structure and function of the macula in patients with advanced retinitis pigmentosa. *Invest Ophthalmol Vis Sci*. 2011;52:8425-8432.
- Oishi A, Ogino K, Nakagawa S, et al. Longitudinal analysis of the peripapillary retinal nerve fiber layer thinning in patients with retinitis pigmentosa. *Eye (Lond)*. 2013;27:597-604.
- Oishi A, Ogino K, Makiyama Y, Nakagawa S, Kurimoto M, Yoshimura N. Wide-field fundus autofluorescence imaging of retinitis pigmentosa. *Ophthalmology*. 2013;120:1827-1834.
- Ogura S, Yasukawa T, Kato A, et al. Wide-field fundus autofluorescence imaging to evaluate retinal function in patients with retinitis pigmentosa. *Am J Ophthalmol*. 2014;158:1093-1098.
- Miyata M, Hata M, Ooto S, et al. Choroidal and retinal atrophy of Bietti crystalline dystrophy patients with CYP4V2 mutations compared to retinitis pigmentosa patients with EYS mutations. *Retina*. 2017;37:1193-1202.
- Hirashima T, Miyata M, Ishihara K, et al. Choroidal vasculature in Bietti crystalline dystrophy with CYP4V2 mutations and in retinitis pigmentosa with EYS mutations. *Invest Ophthalmol Vis Sci*. 2017;58:3871-3878.
- Birch DG, Locke KG, Felius J, et al. Rates of decline in regions of the visual field defined by frequency-domain optical coherence tomography in patients with RPGR-mediated X-linked retinitis pigmentosa. *Ophthalmology*. 2015;122:833-839.
- Miyata M, Ogino K, Gotoh N, et al. Inner segment ellipsoid band length is a prognostic factor in retinitis pigmentosa

TABLE 3. Correlation Between Visual Function and Other Pertinent RP Parameters

Clinical Values	LogMAR		Mean Deviation Value	
	P	r	P	r
Age	0.76		0.94	
Axial length	0.50		0.07	-0.28
Residual choriocapillaris area in angiography images within 12 × 12 mm	0.46		0.62	
Residual choriocapillaris area in structure images within 12 × 12 mm	0.07	-0.29	0.21	

* Statistical significance (P < 0.05).

- associated with EYS mutations: 5-year observation of retinal structure. *Eye (Lond)*. 2016;30:1588-1592.
10. Coscas GJ, Lupidi M, Coscas F, Cagini C, Souied EH. Optical coherence tomography angiography versus traditional multimodal imaging in assessing the activity of exudative age-related macular degeneration: a new diagnostic challenge. *Retina*. 2015;35:2219-2228.
 11. de Carlo TE, Bonini Filho MA, Chin AT, et al. Spectral-domain optical coherence tomography angiography of choroidal neovascularization. *Ophthalmology*. 2015;122:1228-1238.
 12. Miyata M, Ooto S, Hata M, et al. Detection of myopic choroidal neovascularization using optical coherence tomography angiography. *Am J Ophthalmol*. 2016;165:108-114.
 13. de Oliveira Dias JR, Zhang Q, Garcia JMB, et al. Natural history of subclinical neovascularization in nonexudative age-related macular degeneration using swept-source OCT angiography. *Ophthalmology*. 2018;125:255-266.
 14. Sugahara M, Miyata M, Ishihara K, et al. Optical coherence tomography angiography to estimate retinal blood flow in eyes with retinitis pigmentosa. *Sci Rep*. 2017;7:46396.
 15. Inooka D, Ueno S, Kominami T, et al. Quantification of macular microvascular changes in patients with retinitis pigmentosa using optical coherence tomography angiography. *Invest Ophthalmol Vis Sci*. 2018;59:433-438.
 16. Miyata M, Oishi A, Hasegawa T, et al. Choriocapillaris flow deficit in Bietti crystalline dystrophy detected using optical coherence tomography angiography. *Br J Ophthalmol*. 2018;102:1208-1212.
 17. Battaglia Parodi M, Cicinelli MV, Rabiolo A, et al. Vessel density analysis in patients with retinitis pigmentosa by means of optical coherence tomography angiography. *Br J Ophthalmol*. 2017;101:428-432.
 18. Henkind P, Gartner S. The relationship between retinal pigment epithelium and the choriocapillaris. *Trans Ophthalmol Soc U K*. 1983;103(Pt 4):444-447.
 19. Novais EA, Adhi M, Moulton EM, et al. Choroidal neovascularization analyzed on ultrahigh-speed swept-source optical coherence tomography angiography compared to spectral-domain optical coherence tomography angiography. *Am J Ophthalmol*. 2016;164:80-88.
 20. Miller AR, Roisman L, Zhang Q, et al. Comparison between spectral-domain and swept-source optical coherence tomography angiographic imaging of choroidal neovascularization. *Invest Ophthalmol Vis Sci*. 2017;58:1499-1505.
 21. Sacconi R, Borrelli E, Corbelli E, et al. Quantitative changes in the ageing choriocapillaris as measured by swept source optical coherence tomography angiography [published online ahead of print October 25, 2018]. *Br J Ophthalmol*. doi: 10.1136/bjophthalmol-2018-313004.
 22. Jauregui R, Park KS, Duong JK, Mahajan VB, Tsang SH. Quantitative progression of retinitis pigmentosa by optical coherence tomography angiography. *Sci Rep*. 2018;8:13130.
 23. Tee JLL, Yang Y, Kalitzeos A, et al. Characterization of visual function, interocular variability and progression using static perimetry-derived metrics in RPGR-associated retinopathy. *Invest Ophthalmol Vis Sci*. 2018;59:2422-2436.