

Retinal Microvasculature in Amblyopic Children and the Quantitative Relationship Between Retinal Perfusion and Thickness

Wuhe Chen,¹ Jiangtao Lou,² Frank Thorn,^{1,3} Yingjie Wang,² Jieli Mao,² Qingya Wang,² and Xiping Yu¹

¹School of Ophthalmology and Optometry, Eye Hospital of Wenzhou Medical University, Wenzhou, Zhejiang, China

²School of Ophthalmology and Optometry, Wenzhou Medical University, Wenzhou, Zhejiang, China

³Department of Brain and Cognitive Sciences, Massachusetts Institute of Technology, Cambridge, Massachusetts, United States

Correspondence: Xiping Yu, School of Ophthalmology and Optometry, Eye Hospital of Wenzhou Medical University, 270 Xueyuan Road, Wenzhou, Zhejiang 325000, China; yu-xiping@163.com.

Submitted: December 11, 2018

Accepted: February 25, 2019

Citation: Chen W, Lou J, Thorn F, et al. Retinal microvasculature in amblyopic children and the quantitative relationship between retinal perfusion and thickness. *Invest Ophthalmol Vis Sci.* 2019;60:1185–1191. <https://doi.org/10.1167/iov.18-26416>

PURPOSE. To quantify retinal vascular density in amblyopic children and to investigate the relationship between superficial and deep retinal vessel density and retinal thickness.

METHOD. In this prospective cross-sectional study, 85 amblyopic children (5–12 years) and 66 age-matched control subjects participated at a pediatric ophthalmology clinic. Macular vessel densities of the superficial and deep capillary plexuses (SCP, DCP, respectively) and retinal thickness were measured by clinical optical coherence tomographic angiography (OCTA). Vessel density and retinal thickness were compared between amblyopic groups and the control group, and correlations among these two variables were analyzed.

RESULTS. Of the 85 amblyopic children, 52 children had anisometropic amblyopia, 16 had strabismic amblyopia, and 17 had bilateral amblyopia. The foveal and parafoveal macular vessel density in the SCP was lower in amblyopic than control children ($P \leq 0.008$). Compared to strabismic and bilateral amblyopias, anisometropic amblyopia SCP differed the most from controls ($P \leq 0.005$). Macular vessel density in the DCP of amblyopic children was similar to controls. Multiple linear regression analyses showed SCP vessel density was positively correlated with inner retinal thickness in the fovea ($P < 0.001$) and in the temporal, nasal, and inferior quadrants of the parafovea ($P \leq 0.008$).

CONCLUSIONS. Macular vessel density is decreased in anisometropic amblyopia, and to a lesser extent, the other amblyopias. Retinal small vessel density was correlated with the thickness of the macular inner retina. The causality of retinal change (i.e., whether it is primary or secondary to the onset of amblyopia) has not yet been determined.

Keywords: optical coherence tomographic angiography, retinal blood flow, retinal thickness, amblyopia

Amblyopia is the second most common cause of reduced vision in children, with myopia being the first. Amblyopia affects approximately 1.6% to 3.6% of the population.¹ The pathophysiology of this condition has not been fully defined, but the functional changes involved in amblyopic development can occur at various levels of the visual pathway. Most striate cortex neurons in kittens and monkeys with strabismic and anisometropic amblyopia respond to the dominant eye.² In addition to cortical deficits, cells in the lateral geniculate nucleus layers of amblyopic eyes are less developed than those in the dominant eye layers.³ Retinal involvement in amblyopia has always been doubted. Several studies using optical coherence tomography (OCT) have evaluated macular structural parameters, but the results are inconsistent. Previous studies^{4,5} reported a relationship between retinal perfusion and retinal thickness in healthy subjects. The evaluation of these two variables in amblyopia might demonstrate an amblyopic deficiency at the retina level.

OCT angiography (OCTA) is a new, noninvasive imaging technique that provides depth-resolved visualization of the retinal microvasculature. The newest OCT application updates

allow us to identify the superficial retinal capillary plexus (SCP), the deep retinal capillary plexus (DCP), and the choroid. Several authors reported decreased SCP and DCP vessel density for amblyopic eyes.^{6,7} However, the projection artifacts in the DCP might exist in the previous studies. This is an especially propitious time to perform OCTA studies because recent software advances of certain OCTA systems can now largely eliminate imaging artifacts in the DCP. The purpose of this study is to use OCTA to compare retinal thickness and vascularity in the macula of amblyopic children with control children, and to evaluate any interaction between retinal vessel density and thickness. If macular structure or perfusion are shown to be affected by amblyopia, it could pose serious challenges to our current understanding and definition of amblyopia.

METHODS

Subjects

This prospective, cross-sectional study was conducted from July 1, 2017, through August 31, 2018, at the Wenzhou Medical



University Affiliated Eye Hospital. The protocol was approved by The Ethics Board of the Wenzhou Medical University and was performed according to the tenets of the Declaration of Helsinki for research involving human subjects. Signed parental informed consent forms were returned to the researchers before examinations were performed on the children.

Amblyopic (85) and normal control (66) children were recruited. Amblyopia was defined based on the American Academy of Ophthalmology's preferred practice pattern (PPP)⁸: unilateral amblyopia best corrected visual acuity (BCVA) ≥ 2 lines interocular difference and bilateral amblyopia BCVA worse than 20/30 in both eyes for ages >5 . Inclusion criteria were children with unilateral amblyopia caused by anisometropia or strabismus, or bilateral amblyopia caused by high hyperopia or astigmatism, age between 5 and 12 years, and central fixation as determined by ophthalmoscopy. The control group was composed of children whose BCVA was equal to or better than 20/20 in both eyes. Children with myopia greater than -0.50 diopters (D) and patients with neurologic diseases, ocular conditions such as glaucoma or retinal disorders, and nystagmus were also excluded. In addition, children who had undergone strabismus surgery were excluded. Amblyopic children enrolled in the study were in their initial visits or were being treated but still met the criteria of amblyopia.

All subjects underwent a comprehensive ophthalmologic examination, which included subjective refraction (for amblyopic children, completed after cycloplegia), BCVA, slit-lamp examination, funduscopy, and an orthoptic evaluation. A biometer (Lenstar S 900; Haag-Streit AG, Koeniz, Switzerland) was used to measure axial length (AL). Retinal thickness and vascular density at the macula were measured by OCTA (Optovue, Inc., Fremont, CA, USA). For bilateral amblyopia and normal control subjects, the data from the right eye were selected for analysis.

OCTA Data Acquisition and Processing

OCTA scans were obtained using a spectral-domain system with optical software (AngioVue version 2017.1.0.155; Optovue, Inc.) with a light source at 840 nm, a bandwidth of 45 nm, and an A-scan rate of 70,000 scans per second. Angioretina (3×3 mm) and the crossline module procedures were performed for both eyes in each subject.

Macular OCTA scans (3×3 mm) were acquired by two repeated B-scans at 304 raster positions, and each B-scan consisted of 304 A-scans. Two volumetric raster scans were taken consecutively, one with a horizontal priority (x -fast) and one with a vertical priority (y -fast). Each scan was automatically segmented to visualize the retinal SCP and DCP. SCP-OCTA images were segmented with the inner boundary at the internal limiting membrane (ILM) and the outer boundary at 10 μm above the inner plexiform layer (IPL). DCP images were segmented with an inner boundary 10 μm above the IPL and the outer boundary 10 μm below the outer plexiform layer (OPL). The 3D projection artifacts removal algorithms (Optovue, Inc.) were implemented in the updated optical software (Optovue, Inc.) to remove "false" blood flow signals from the DCP.

Vessel densities were calculated as the percent of each region of interest occupied by the vessel area within that region. The five regions of interest were based on the Early Treatment Diabetic Retinopathy Study contours and included the fovea and the parafovea divided into temporal, superior, nasal, and inferior quadrants. The foveal region was circular with a 1-mm diameter, centered on the fovea. The parafoveal region was an annulus with a 3-mm outer diameter and a 1-mm

inner diameter centered at the fovea (Fig., panel A). The automated software (Optovue, Inc.) was also used to calculate the area (mm^2) of the foveal avascular zone (FAZ). All scans were reviewed to ensure correct segmentation and sufficient image quality (quality index ≥ 8). Poor-quality scans were excluded from the analysis.

Retinal thickness at the macula was measured by the crossline module. The scan length and depth were 8 and 2.388 mm, respectively, with the posterior pole volume scan having two lines that crossed horizontally and vertically, each centered at the fovea. The images obtained were reviewed by a masked ophthalmologist (WC). The horizontal and vertical scans from each subject with the highest quality at the foveal center were selected for evaluation. Custom software⁹ for automatic segmentation into layers was developed to measure the mean inner and outer retinal thicknesses at the fovea and at the parafoveal four quadrants. The foveal and parafoveal regions were defined as the same region as in the OCTA images. Inner retinal thickness was measured from the ILM to the outer boundary of the inner nuclear layer, and the outer retinal thickness was measured from inner boundary of the OPL to the outer boundary of the retinal pigment epithelium (Fig., panel B).

Statistical Analysis

Statistical analyses were performed with statistical software (SPSS version 19.0; SPSS Inc, Chicago, IL, USA). Unless otherwise stated, the means and standard deviations of continuous variables were calculated. Visual acuity data were converted to the logMAR format for statistical calculations and analyses. Refraction data were converted into spherical equivalents (SEs), calculated as the spherical dioptric power plus one-half of the cylindrical dioptric power. Analysis of covariance (ANCOVA) was used to evaluate retinal thickness and vascular density differences between amblyopic groups and the control group, while adjusting for the possible effects of AL and age, and sex. Subsequently, baseline multiple comparison imbalances in the groups were adjusted for AL, age, and sex. Unpaired t -tests, Mann-Whitney tests, and χ^2 tests were used to compare demographic variables, SE refractive errors, and ALs between amblyopic groups and the control group when appropriate. Paired t -tests were performed to compare the two eyes of unilateral amblyopic eyes. Multiple linear regression analyses determined if age, sex, visual acuity, AL, and retinal thickness were associated with the vascular variables. Two-sided $P \leq 0.05$ was considered statistically significant.

RESULTS

We included 85 children (median 8 years old, interquartile range [IQR] 7–9 years) with amblyopia and 66 age-matched control subjects (median 8 years, IQR 7–9 years, Table 1). Of the 85 amblyopic children, 52 had anisometropic amblyopia, 16 had strabismic amblyopia, and 17 had bilateral amblyopia. There were no significant differences in age or sex between the amblyopic and control groups ($P = 0.149$ and 0.191 , respectively). As expected, SE, AL, and visual acuity were significantly different between the amblyopic and control eyes, as well as with the fellow eyes ($P < 0.001$ or all comparisons). There was no significant difference in visual acuity or AL between fellow eyes and control eyes ($P \geq 0.128$, Table 1). However, the SEs of fellow eyes were slightly but significantly higher than control eyes ($P = 0.001$). The refractive status of the different types of amblyopias are presented in Supplemental Table S1.

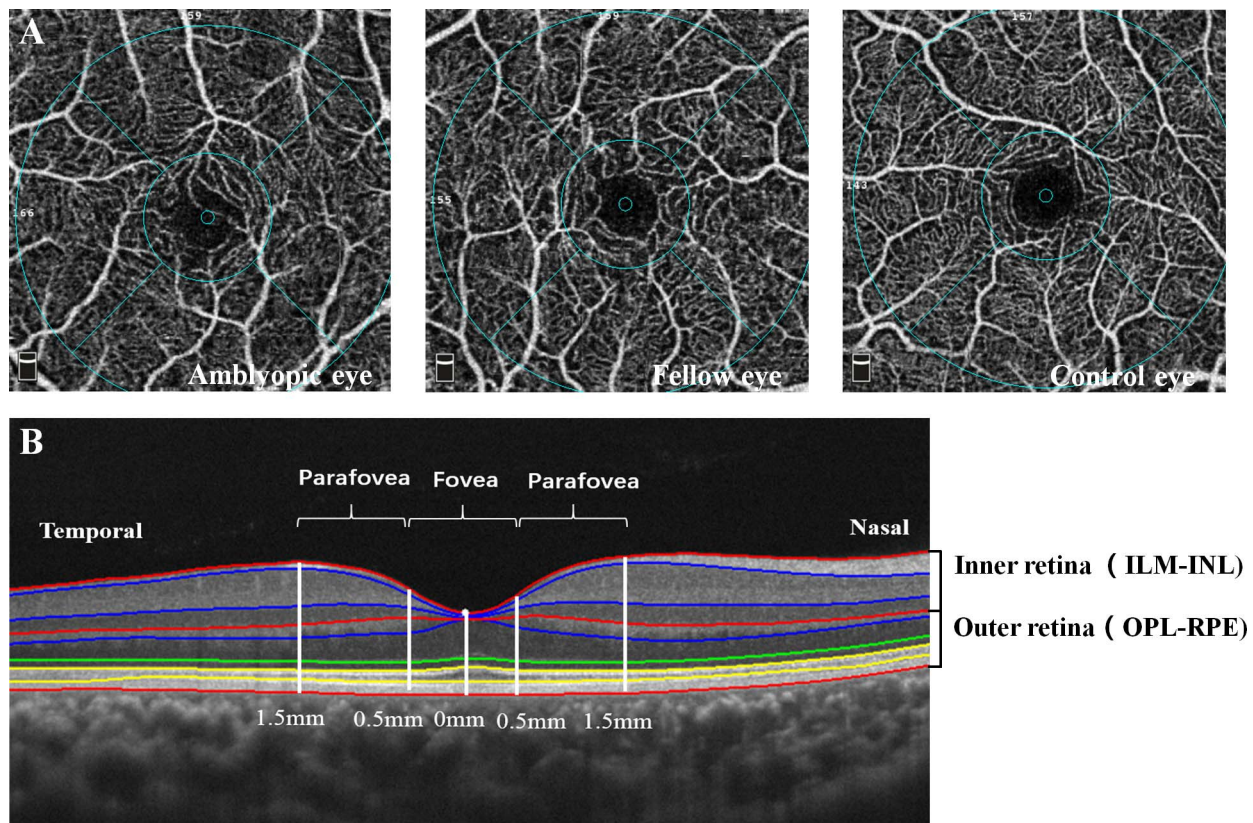


FIGURE. Optical coherence tomographic angiography scans of macular microvasculature and thickness. **(A)** Examples of central 3 × 3 mm macular of the superficial capillary plexus scans from an amblyopic eye, fellow eye, and control eye. Macular vessel density was separately calculated for the fovea and the parafovea as well as the temporal, superior, nasal, and inferior parafoveal quadrants based on the Early Treatment Diabetic Retinopathy Study contour. **(B)** Macular image obtained at the horizontal meridian shows eight intraretinal layers. ILM-INL: inner retina from the internal limiting membrane (ILM) to the outer boundary of the inner nuclear layer (INL); OPL-RPE: outer retina from the inner boundary of outer plexiform layer (OPL) to the outer boundary of the RPE.

In the 3 × 3 mm scans, the foveal SCP vessel density was 22.7% ± 6.0% in the amblyopic group and 25.3% ± 5.5% in the control group (Table 2). After adjusting for age, AL, and sex, the difference in the foveal SCP between the amblyopic and control group, -3.17%, was significant ($P = 0.008$). The SCP parafoveal vessel density was also smaller in the amblyopic group than in the control group (49.6% ± 3.8% versus 51.7% ± 2.6% respectively) with a difference of -2.76% ($P < 0.001$) after adjusting for age, AL, and sex. The SCP vessel density in all four quadrants of the parafovea were similarly lower in the amblyopia group than in the control group (Table 2).

The foveal DCP vessel density of the amblyopic and control groups were 32.8% ± 6.3% and 34.2% ± 5.9% respectively (Table 2). After adjusting for age, AL, and gender, the difference was -1.64% ($P = 0.189$). The parafoveal DCP vessel density was 51.9% ± 4.3% in the amblyopic group and 53.0% ± 3.7% in the

control group, with a difference of -0.83% ($P = 0.312$) after adjusting for age, AL, and sex. The vessel density in each of the four parafoveal quadrants of the DCP followed a similar pattern for amblyopic and control groups ($P \geq 0.141$, Table 2). There was also no significant difference in the area of the FAZ between the amblyopic and control groups ($P = 0.193$).

Macular vessel densities of the different types of amblyopia were also evaluated. For anisometropic amblyopic eyes, the SCP vessel density at the fovea, the overall parafovea, and the four parafoveal quadrants were all less than for normal control eyes ($P \leq 0.005$, Table 3). For strabismus amblyopic eyes compared with normal eyes, there was no difference in the foveal SCP vessel density ($P = 0.148$). For the overall parafovea and for all quadrants except the temporal quadrant, SCP vessel density was lower than for the control eyes ($P \leq 0.049$, Table 3). For bilateral amblyopic eyes compared with control eyes,

TABLE 1. Patient Demographics and Refractive Status

Variables	Amblyopia Eyes (n = 85)	Fellow Eyes (n = 68)	Control Eyes (n = 66)	P Value		
				AE vs. CE	AE vs. FE	FE vs. CE
Age, median (IQR), y	8 (7, 9)	8 (7, 9)	8 (7, 9)	0.149	NA	0.149
Sex (boys/girls)	43/42	43/42	39/27	0.191	NA	0.191
SE, median (IQR), D	+4.53 ± 0.39	+0.91 ± 1.92	0.16 ± 0.04	<0.001	<0.001	0.001
LogMAR VA (IQR)	0.39 (0.22, 0.69)	0.0 (0.0, 0.0)	0.0 (0.0, 0.0)	<0.001	<0.001	0.128
AL, mm	21.72 ± 1.30	22.99 ± 1.18	23.19 ± 0.74	<0.001	<0.001	0.223

AE, amblyopic eyes, FE, fellow eyes, CE, control eyes.

TABLE 2. Macular Vessel Density in Amblyopic and Control Subjects

Retinal Region	Vessel Density, Mean \pm SD, %			Difference (95% CI)*	P Value*
	Amblyopia	Control			
SCP					
Fovea	22.7 \pm 6.0	25.3 \pm 5.5		-3.17 (-5.49, -0.86)	0.008
Parafovea	49.6 \pm 3.8	51.7 \pm 2.6		-2.76 (-4.09, -1.42)	<0.001
T	48.7 \pm 4.1	50.8 \pm 2.8		-2.87 (-4.31, -1.44)	<0.001
S	50.6 \pm 4.2	52.4 \pm 2.9		-2.36 (-3.88, -0.84)	0.003
N	49.14 \pm 4.4	51.0 \pm 3.4		-2.68 (-4.28, -1.08)	0.001
I	50.1 \pm 4.1	52.7 \pm 3.0		-3.00 (-4.50, -1.49)	<0.001
DCP					
Fovea	32.8 \pm 6.3	34.2 \pm 5.9		-1.64 (-4.08, 0.81)	0.189
Parafovea	51.9 \pm 4.3	53.0 \pm 3.7		-0.83 (-2.45, 0.79)	0.312
T	52.8 \pm 3.9	53.2 \pm 3.7		-0.82 (-2.33, 0.70)	0.288
S	51.6 \pm 5.0	53.3 \pm 3.8		-1.35 (-3.15, 0.45)	0.141
N	53.0 \pm 4.3	53.6 \pm 4.1		-0.05 (-1.72, 1.63)	0.956
I	50.5 \pm 4.9	52.1 \pm 4.4		-1.07 (-2.97, 0.83)	0.267
FAZ	0.30 \pm 0.09	0.28 \pm 0.10		0.026 (-0.013, 0.065)	0.193

CI, confidence interval; T, temporal; S, superior; N, nasal; I, inferior; FAZ, foveal avascular zone measured as mm².

* Difference (95% CI) and P value were adjusted for axial length, age, and sex.

there were no differences in the foveal and overall parafoveal SCP vessel densities ($P = 0.718$ and 0.092 , respectively); however, one of the quadrants was less dense than the control eyes (temporal, $P = 0.014$, Table 3).

There were no differences in the overall DCP macular vessel densities or in any of the quadrants ($P \geq 0.060$, Table 3) for any type of amblyopia compared to the control group. There was also no difference in the area of the FAZs between any of the amblyopia groups and the controls.

When comparing the amblyopic to the fellow eyes in the unilateral amblyopic groups, the foveal and overall parafoveal SCP vessel densities in the anisometropic amblyopic eyes were slightly, but significantly, less than in the fellow eyes ($P = 0.025$ and 0.023 respectively, Table 4). SCP vessel density at the parafoveal temporal quadrant was also less in the amblyopic eyes than the fellow eyes ($P = 0.009$), but not for the other three quadrants ($P \geq 0.067$). For children with strabismic amblyopia, there were no significant differences in foveal or parafoveal SCP vessel density between the two eyes ($P \geq$

0.779 , Table 4). There were also no differences between the paired eyes for DCP vessel density or the area of the FAZ ($P \geq 0.097$, Table 4).

We also compared the vessel density in the fellow eyes of amblyopia patients with control eyes (Supplementary Table S2). For the SCP, the vessel density was lower at every point for the fellow eyes than for the control eyes, reaching statistical significance for the fovea ($P = 0.023$) and for the parafoveal inferior quadrant ($P = 0.047$). None of the DCP regions or the FAZ were significantly different between the two groups.

There were no significant differences between the amblyopic and control groups in the thicknesses of the inner and outer retinas at either the fovea or the parafovea ($P \geq 0.056$, Supplementary Tables S3, S4). However, multiple linear regression analyses showed that SCP and DCP vessel densities in the fovea were positively correlated with the inner retinal thickness (standard $\beta = +0.615$ and $+0.653$ respectively, $P < 0.001$ each). Also, the area of the FAZ was negatively correlated with the inner foveal thickness (standard $\beta = -0.709$, $P <$

TABLE 3. Macular Vessel Density in Different Types of Amblyopic and Control Subjects

Retinal Region	Vessel Density, Mean \pm SD, %				P Value*		
	Control Subjects	Anisometropic Amblyopia	Strabismic Amblyopia	Bilateral Amblyopia	AA vs. CG	SA vs. CG	BA vs. CG
SCP							
Fovea	25.3 \pm 5.5	22.0 \pm 6.3	23.1 \pm 6.3	24.7 \pm 3.7	0.005	0.148	0.718
Parafovea	51.7 \pm 2.6	49.2 \pm 4.0	50.0 \pm 3.9	50.6 \pm 2.6	<0.001	0.031	0.092
T	50.8 \pm 2.8	48.2 \pm 4.4	50.0 \pm 3.6	49.2 \pm 3.3	<0.001	0.187	0.014
S	52.4 \pm 2.9	50.1 \pm 4.4	50.3 \pm 5.2	52.0 \pm 2.2	0.003	0.043	0.620
N	51.0 \pm 3.4	48.8 \pm 4.7	48.9 \pm 4.7	50.3 \pm 3.0	0.001	0.027	0.255
I	52.7 \pm 3.0	49.7 \pm 4.4	50.8 \pm 4.1	50.8 \pm 3.4	<0.001	0.049	0.052
DCP							
Fovea	34.2 \pm 5.9	32.4 \pm 6.4	31.9 \pm 6.0	35.1 \pm 5.9	0.229	0.206	0.644
Parafovea	53.0 \pm 3.7	52.0 \pm 4.4	53.1 \pm 3.1	50.6 \pm 4.7	0.249	0.977	0.137
T	53.2 \pm 3.7	52.9 \pm 4.1	53.1 \pm 3.3	52.3 \pm 4.1	0.313	0.678	0.177
S	53.3 \pm 3.8	51.8 \pm 5.1	52.8 \pm 3.4	49.6 \pm 5.8	0.139	0.672	0.060
N	53.6 \pm 4.1	53.1 \pm 4.3	53.9 \pm 3.7	51.8 \pm 4.9	0.859	0.685	0.429
I	52.1 \pm 4.4	50.4 \pm 5.1	52.8 \pm 3.5	48.7 \pm 5.0	0.130	0.624	0.127

AA, anisometropic amblyopia; SA, strabismic amblyopia; BA, bilateral amblyopia; CG, control group.

* P values were adjusted for baseline imbalances in the groups including axial length, age, and sex.

TABLE 4. Macular Vessel Density in Amblyopic and Fellow Eyes

Retinal Region	Vessel Density, Mean \pm SD, %			Vessel Density, Mean \pm SD, %		
	Anisometropic Amblyopia			Strabismic Amblyopia		
	AE	FE	<i>P</i> Value	AE	FE	<i>P</i> Value
SCP						
Fovea	22.0 \pm 6.3	23.2 \pm 6.5	0.025	23.1 \pm 6.4	22.8 \pm 5.4	0.794
Parafovea	49.2 \pm 4.1	50.9 \pm 3.4	0.023	50.0 \pm 3.9	50.2 \pm 3.9	0.799
T	48.2 \pm 4.4	50.1 \pm 3.4	0.009	50.0 \pm 4.0	49.5 \pm 2.8	0.595
S	51.8 \pm 5.0	51.7 \pm 3.9	0.894	50.3 \pm 5.3	50.7 \pm 2.6	0.774
N	48.8 \pm 4.7	50.2 \pm 3.8	0.073	48.9 \pm 4.7	48.9 \pm 4.7	0.632
I	49.7 \pm 4.4	51.4 \pm 4.2	0.067	50.8 \pm 4.2	50.8 \pm 5.1	0.787
DCP						
Fovea	32.4 \pm 6.4	33.5 \pm 7.7	0.142	31.9 \pm 6.0	31.7 \pm 6.2	0.861
Parafovea	52.0 \pm 4.4	52.4 \pm 3.7	0.567	53.1 \pm 3.1	53.0 \pm 3.2	0.853
T	52.9 \pm 4.1	52.4 \pm 3.9	0.526	53.1 \pm 3.3	53.4 \pm 3.4	0.731
S	51.8 \pm 5.1	52.4 \pm 3.9	0.420	52.8 \pm 3.4	52.9 \pm 3.8	0.892
N	53.1 \pm 4.3	53.3 \pm 3.8	0.685	53.9 \pm 3.7	53.8 \pm 3.1	0.894
I	50.4 \pm 5.1	51.3 \pm 4.6	0.228	52.8 \pm 3.5	51.7 \pm 4.1	0.355
FAZ	0.30 \pm 0.10	0.29 \pm 0.10	0.130	0.32 \pm 0.09	0.30 \pm 0.08	0.097

0.001). For the parafoveal temporal, nasal, and inferior quadrants, SCP vessel density was positively correlated with the corresponding inner retinal thickness (standard β = +0.312, +0.244, and +0.251, respectively; $P \leq 0.008$). In contrast, no vascular variables were significantly correlated with outer retinal thickness ($P > 0.05$).

Decreased visual acuity was weakly but significantly associated with lower foveal SCP vessel density (standard β = -0.268, $P = 0.001$) and with the parafoveal temporal, nasal, and inferior quadrants (standard β = -0.257, -0.205, and -0.249 respectively; $P \leq 0.044$). Decreased visual acuity was also correlated with the enlarged area of the FAZ (standard β = +0.195, $P = 0.008$).

DISCUSSION

Our OCTA demonstrated that amblyopic eyes have significantly lower vessel density in the SCP, with a 3.17% mean reduction at the fovea and 2.76% at the parafovea in amblyopic children. These differences were greatest in anisometropic amblyopia and least in bilateral amblyopia. Better visual acuity is slightly related to higher SCP vessel density. We did not find significant differences between amblyopes and controls for macular DCP vessel density or for the FAZ.

Our data are not in perfect agreement with previous studies.^{6,7,10} Lonngi et al.⁶ and Yilmaz et al.⁷ reported decreased SCP and DCP vessel density for amblyopic eyes, but not for the FAZ in amblyopic eyes. Sobral et al.¹⁰ found decreased SCP vessel density and an enlarged FAZ in amblyopic eyes. The variation among studies may be due to variation in subjects' age, differences in ethnicity, random variation, or image projection artifacts existing in the previous studies. The influence of projection artifacts on visualization of deeper retinal vascular plexuses is a major issue.¹¹ In 2018, the updated optical software (Optovue, Inc.) redefined the SCP and DCP boundaries and 3D projection artifacts removal algorithms were implemented to remove "false" blood flow signals in the DCP. Lonngi et al.⁶ and possibly others⁹⁻¹⁰ did not use the updated software, and the differences in analytical software might have caused the inconsistency among studies in the estimates of macular vessel density in the DCP. In our study, SCP vasculature was compromised more than the DCP in relation to the abnormal amblyogenic factors such as visual

experience or the central visual system defect caused by these factors.

Our study showed that amblyopic eyes differed more significantly from control eyes than from fellow eyes. Previous studies have suggested that the development of both eyes is affected in people with unilateral amblyopia and that the fellow eye is not equivalent to a normal healthy eye.^{12,13} Lonngi et al.⁶ included some fellow eyes as control eyes, and this may have introduced an artifact into their results. Our data showed that in fellow eyes, the SCP was slightly less dense than in control eyes at each site measured, and the differences were significant at several sites. Meier et al.¹² proposed that the sensitivity of the fellow eye is impacted for visual functions that rely on the binocular cortex. The fellow eye deficits are an important reminder that more effective treatments for amblyopia may target the binocular origin of this condition.

We note that vascular density was less in the fovea and the four parafoveal quadrants of the anisometropic amblyopes than in the bilateral amblyopes, even though both disorders are the result of hyperopic defocus. Animal experiments have shown a much greater loss in central visual system responsiveness in a monocularly deprived eye than binocularly deprived eyes.¹⁴⁻¹⁸ This has been attributed primarily to interocular inhibition while the binocular loss involves mainly higher cortical areas. Monocular deprivation also has a much greater effect on patient visual acuity. In other studies, severe losses in primary visual cortex neuron responsiveness can cause atrophy of retinal ganglion cells through the transneuronal degeneration of neurons in the lateral geniculate nucleus.^{19,20} Reduced retinal ganglion cell size and number could lead to a thinner inner retina and less need for a dense vasculature. That hypothesis is consistent with our finding that vascular density was less in the anisometropic amblyopes than in the bilateral amblyopes.

Our result showed that density loss in the macular vasculature was greater in anisometropic amblyopia than in strabismic amblyopia and bilateral amblyopia. Al-Haddad²¹ found that retinal nerve fiber layer thickness may be affected by refractive amblyopia but not by strabismus amblyopia. The standard visual acuity loss in anisometropic amblyopes is primarily due to grating resolution acuity and contrast sensitivity losses which are limited by factors within the primary visual system between the retina and the striate cortex.^{22,23} In strabismus amblyopia, grating visual acuity and

contrast sensitivity losses represent a relatively small part of their overall visual loss.^{22,24} Strabismus amblyopia shows a great loss in Vernier acuity relative to simple grating acuity^{22,24} and strong spatial distortions for foveal vision.²⁵ These spatial distortions involve higher cortical functions and underly most of the strabismus amblyopes visual acuity loss. Since the main visual loss in anisotropic amblyopia involves contrast sensitivity and grating resolution reduction due to poor information transmission between retina and striate cortex, anisotropic amblyopia is more likely to involve the retina. We recommend that studies referring to amblyopia should not mix different types of amblyopia because this will confound the observations and result in inconsistency among the results of different studies.

We found a positive correlation between the thickness of the inner retina and macular perfusion in agreement with the fact that the oxygen and nutrition demands of the inner retina are met by the retinal arterial system, while those of the outer retina are met by the choroidal vascular system. This result is consistent with Cheung et al.⁵ who focused only on the SCP, knowing that shadow graphic projection artifacts made DCP data uninterpretable.²⁵ We also found that thinner foveal thickness was associated with an enlarged FAZ. This finding reflects the fact that a deeper foveal pit results in a wider lateral displacement of the superficial retinal layers and hence a larger FAZ.^{26,27}

Many studies have examined macular topography in amblyopia. Li et al.²⁸ performed a meta-analysis of retinal changes in unilateral amblyopia and found a thicker foveola in amblyopic eyes than in normal controls. They speculated that blurred vision causes insufficient stimulation to the amblyopic eye, and this affects normal maturation of macula structure and the related movement of Henle fibers away from the fovea. Bruce et al.¹³ speculated that increased foveal thickness is likely a result of changes at the photoreceptor level. Liu et al.²⁹ claimed that choroid thickness must increase to supply additional blood to the thicker retina in amblyopia. The analyses above are logical but refer only to the outer retina. The retinal dimensions described in the present study involve only the inner retina of amblyopes. So our results are not inconsistent with the above studies.

A drawback in our study is that anisotropic amblyopia is much more common in China, thus, strabismus and bilateral amblyopia sample sizes were relatively small. Also, a cross-sectional study cannot determine if the vascular differences we observed are primary or secondary to anisotropic amblyopia. However, a longitudinal study starting with two-year-old hyperopic children to answer the causality question would be very challenging.

CONCLUSIONS

We found lower macula vascular density in the SCP of amblyopic eyes, especially in anisotropic amblyopia. Even though the macular thickness in the amblyopic eyes was not significantly reduced, there was a positive correlation between macular vessel density and inner retinal thickness. The main visual loss in anisotropic amblyopia involves contrast sensitivity and grating resolution reduction due to poor information transmission between retina and striate cortex.^{22,23} Based on this finding and our results, anisotropic amblyopia is more likely to induce structural and physiological changes in the retina. More studies with large sample sizes are needed to examine retinal morphology and perfusion in amblyopia. If macular structure or perfusion are shown to be affected by amblyopia, it will require revision of our current understanding and definition of amblyopia. The revised

understanding must recognize changes in the retina that contribute to the structural and functional abnormalities that are present in the rest of the visual pathway.

Acknowledgments

The authors thank Shenghai Huang, Yuanyuan Zhou, Meiping Xu, Jinjing Zhou, Jinling Xu, MD, Suzhong Xu, and Hui Chen at Wenzhou Medical University Affiliated Hospital, for their collaboration with the authors on this study.

Supported by the Zhejiang Provincial Natural Science Foundation of China Grant No. LQ18H120005 (WC), Wenzhou Municipal Science and Technology Bureau Grant No. Y20170782 (WC), Wenzhou Municipal Science and Technology Bureau Grant No. Y20160150 (XY), and Eye hospital of Wenzhou Medical University Grant No. YNCX 201404 (XY).

Disclosure: **W. Chen**, None; **J. Lou**, None; **F. Thorn**, None; **Y. Wang**, None; **J. Mao**, None; **Q. Wang**, None; **X. Yu**, None

References

1. Simons K. Amblyopia characterization, treatment, and prophylaxis. *Surv Ophthalmol.* 2005;50:123-166.
2. Wiesel TN, Hubel DH. Single-cell responses in striate cortex of kittens deprived of vision in one eye. *J Neurophysiol.* 1963; 26:1003-1017.
3. Wiesel TN, Hubel DH. Effects of visual deprivation on morphology and physiology of cells in the cats lateral geniculate body. *J Neurophysiol.* 1963;26:978-993.
4. Yu J, Gu R, Zong Y, et al. Relationship between retinal perfusion and retinal thickness in healthy subjects: an optical coherence tomography angiography study. *Invest Ophthalmol Vis Sci.* 2016;57:OCT204-OCT210.
5. Cheung CY, Li J, Yuan N, et al. Quantitative retinal microvasculature in children using swept-source optical coherence tomography: the Hong Kong Children Eye Study [published online ahead of print June 28, 2018]. *Br J Ophthalmol.* doi:10.1136/bjophthalmol-2018-312413.
6. Longi M, Velez FG, Tsui I, et al. Spectral-domain optical coherence tomographic angiography in children with amblyopia. *JAMA Ophthalmol.* 2017;135:1086-1091.
7. Yilmaz I, Ocak OB, Yilmaz BS, Inal A, Gokyigit B, Taskapili M. Comparison of quantitative measurement of foveal avascular zone and macular vessel density in eyes of children with amblyopia and healthy controls: an optical coherence tomography angiography study. *J AAPOS.* 2017;21:224-228.
8. American Academy of Ophthalmology Pediatric Ophthalmology/Strabismus Panel. *Preferred Practice Pattern Guidelines Amblyopia.* San Francisco, CA: American Academy of Ophthalmology; 2012.
9. Liu X, Shen M, Huang S, Leng L, Zhu D, Lu F. Repeatability and reproducibility of eight macular intra-retinal layer thicknesses determined by an automated segmentation algorithm using two SD-OCT instruments. *PLoS One.* 2014;9:e87996.
10. Sobral I, Rodrigues TM, Soares M, et al. OCT angiography findings in children with amblyopia. *J AAPOS.* 2018;22:286-289 e282.
11. Tang F, Cheung CY. Quantitative retinal optical coherence tomography angiography in patients with diabetes without diabetic retinopathy. *Invest Ophthalmol Vis Sci.* 2017;58: 1766.
12. Meier K, Giaschi D. Unilateral amblyopia affects two eyes: fellow eye deficits in amblyopia. *Invest Ophthalmol Vis Sci.* 2017;58:1779-1800.
13. Bruce A, Pacey IE, Bradbury JA, Scally AJ, Barrett BT. Bilateral changes in foveal structure in individuals with amblyopia. *Ophthalmology* 2013;120:395-403.

14. Hyvarinen J, Carlson S, Hyvarinen L. Early visual deprivation alters modality of neuronal responses in area 19 of monkey cortex. *Neurosci Lett*. 1981;26:239-243.
15. Hyvarinen J, Hyvarinen L. Blindness and modification of association cortex by early binocular deprivation in monkeys. *Child Care Health Dev*. 1979;5:385-387.
16. Hyvarinen J, Hyvarinen L. Higher functions and plasticity in visual pathways. *Acta Ophthalmol Suppl*. 1983;157:9-17.
17. Hyvarinen J, Hyvarinen L, Farkkila M, Carlson S, Leinonen L. Modification of visual functions of the parietal lobe at early age in the monkey. *Med Biol*. 1978;56:103-109.
18. Murphy KM, Mitchell DE. Bilateral amblyopia after a short period of reverse occlusion in kittens. *Nature*. 1986;323:536-538.
19. Pearson HE, Labar DR, Payne BR, Cornwell P, Aggarwal N. Transneuronal retrograde degeneration in the cat retina following neonatal ablation of visual cortex. *Brain Res*. 1981;212:470-475.
20. Pearson HE, Thompson TP. Atrophy and degeneration of ganglion cells in central retina following loss of postsynaptic target neurons in the dorsal lateral geniculate nucleus of the adult cat. *Exp Neurol*. 1993;119:113-119.
21. Al-Haddad CE, Mollayess GM, Cherfan CG, Jaafar DF, Bashshur ZF. Retinal nerve fibre layer and macular thickness in amblyopia as measured by spectral-domain optical coherence tomography. *Br J Ophthalmol*. 2011;95:1696-1699.
22. Levi DM, Klein S. Hyperacuity and amblyopia. *Nature*. 1982;298:268-270.
23. Levi DM, McKee SP, Movshon JA. Visual deficits in anisometropia. *Vision Res*. 2011;51:48-57.
24. Levi DM, Klein S. Differences in Vernier discrimination for grating between strabismic and anisometropic amblyopes. *Invest Ophthalmol Vis Sci*. 1982;23:398-407.
25. Hess RF, Field DJ. Is the spatial deficit in strabismic amblyopia due to loss of cells or an uncalibrated disarray of cells? *Vision Res*. 1994;34:3397-3406.
26. Tan CS, Lim LW, Chow VS, et al. Optical coherence tomography angiography evaluation of the parafoveal vasculature and its relationship with ocular factors. *Invest Ophthalmol Vis Sci*. 2016;57:OCT224-OCT234.
27. Samara WA, Say EA, Khoo CT, et al. Correlation of foveal avascular zone size with foveal morphology in normal eyes using optical coherence tomography angiography. *Retina*. 2015;35:2188-2195.
28. Li J, Ji P, Yu M. Meta-analysis of retinal changes in unilateral amblyopia using optical coherence tomography. *Eur J Ophthalmol*. 2015;25:400-409.
29. Liu Y, Dong Y, Zhao K. A meta-analysis of choroidal thickness changes in unilateral amblyopia. *J Ophthalmol*. 2017;2017:2915261.