

Anatomic Response to Intravitreal Dexamethasone Implant and Baseline Aqueous Humor Cytokine Levels in Diabetic Macular Edema

Marc Figueras-Roca,^{1,2} Anna Sala-Puigdollers,^{1,2} Javier Zarranz-Ventura,^{1,2} Carmen Alba-Linero,¹ Socorro Alforja,^{1,2} Cristina Esquinas,³ Blanca Molins,² and Alfredo Adán^{1,2}

¹Institut Clínic d'Oftalmologia (ICOF), Hospital Clínic, Barcelona, Spain

²August Pi i Sunyer Biomedical Research Institute (IDIBAPS), Barcelona, Spain

³Respiratory Department, Hospital Universitari Vall d'Hebrón, Barcelona, Spain

Correspondence: Marc Figueras-Roca, Institut Clínic d'Oftalmologia (ICOF), Hospital Clínic, Sabino de Arana 1, Barcelona 08028, Spain; mafguer@clinic.cat.

Submitted: November 16, 2018

Accepted: March 3, 2019

Citation: Figueras-Roca M, Sala-Puigdollers A, Zarranz-Ventura J, et al. Anatomic response to intravitreal dexamethasone implant and baseline aqueous humor cytokine levels in diabetic macular edema. *Invest Ophthalmol Vis Sci.* 2019;60:1336-1343. <https://doi.org/10.1167/iov.18-26215>

PURPOSE. To determine whether baseline cytokine aqueous humor (AH) levels are associated with diabetic macular edema (DME) anatomic response to dexamethasone intravitreal implant (DEX) injection.

METHODS. This was a prospective cohort study of DME cases receiving DEX treatment. Seventy patients were recruited with center-involving DME with spectral-domain (SD) optical coherence tomography (OCT) detection of central macular thickness (CMT) ≥ 300 μm on macular cube 518×128 - μm scan protocol (Cirrus SD-OCT). DEX injection and anterior chamber tap to obtain an AH sample were performed at the same time. Multiplex immunoassay was carried out for interleukin (IL)-1 β , IL-3, IL-6, IL-8, IL-10; monocyte chemoattractant protein (MCP)-1; interferon gamma-induced protein (IP)-10; tumor necrosis factor (TNF)- α ; and vascular endothelial growth factor (VEGF). A follow-up visit and OCT exam were undertaken 6 to 8 weeks afterward. The association between AH cytokine baseline levels and change in CMT and macular volume (MV) was defined as main outcome measure.

RESULTS. Multivariate linear regression analysis showed a higher decrease in MV to be associated (R_s of 0.512) with four baseline items: higher MCP-1 ($\beta = -0.4$; $P = 0.028$), higher CMT ($\beta = -0.003$; $P = 0.024$), decreased visual acuity ($\beta = -0.7$; $P = 0.040$), and a diffuse retinal thickening (DRT) OCT pattern ($\beta = -1.3$; $P < 0.001$). Logistic regression found DRT also to be associated with higher odds of a good MV response (odds ratio, 31.96; 95% confidence interval [CI] 7.11-143.72; $P < 0.001$).

CONCLUSIONS. Even though visual acuity response and anatomic effect are not always correlated in DME, we found that baseline elevated MCP-1 AH levels and DRT pattern were biomarkers that predicted a future favorable anatomic response to DEX.

Keywords: cytokine, diabetic macular edema, intravitreal dexamethasone

Diabetic macular edema (DME) is the most common cause of vision loss in diabetes mellitus (DM) patients with diabetic retinopathy (DR) in a developed society.¹⁻³ DME formation is driven by capillary leakage and fluid accumulation within retinal tissue causing thickening, macular malfunction, and visual impairment. Cellular events such as leukostasis, abnormal leukocyte adherence, and increased vascular permeability take place under the control of intracellular mediators such as cytokines, chemokines, and growth factors.^{4,5} Thus, DME patients have been shown to have increased aqueous humor (AH) levels of molecules such as intercellular adhesion molecule-1 (ICAM-1); interleukin (IL)-1 β , IL-6, IL-8; interferon gamma-induced protein-10 (IP-10); monocyte chemoattractant protein-1 (MCP-1); and vascular endothelial growth factor (VEGF), with comparatively lower levels of IL-10 and IL-12 than in diabetic patients without DME.^{6,7} In addition, recent studies have reported that some agents, such as ICAM-1, IL-8, and MCP-1, may even be objectively correlated to DME severity based on optical coherence tomography (OCT) measurements.⁶⁻⁸

Current DME management involves intravitreal injection of different drugs as first-line therapy in sight-threatening disease. Anti-VEGF agents first and steroids, which are commonly used as a second-line approach, are both nowadays licensed for DME treatment. The mechanism of action of anti-VEGF drugs directly involves intraocular VEGF blockade with subsequent inhibition of angiogenesis and also inflammation.^{4,9} On the other hand, the effect of steroids is based on the inhibition of phospholipase A2, thus blocking an upstream component of the molecular pathway of inflammation and therefore affecting the expression of additional agents such as tumor necrosis factor alpha (TNF- α), ICAM-1, and its resulting inflammatory mediators.¹⁰ Even though anti-VEGF drugs (bevacizumab, ranibizumab, and aflibercept) show some slight differences in blocking VEGF isoforms, their efficacy in DME is similar in patients with relatively good vision.¹¹⁻¹⁵ However, the DME clinical response to steroids, such as dexamethasone 0.7-mg intravitreal implant (DEX) (Ozurdex; Allergan, Inc., Irvine, CA, USA), differs significantly from that for anti-VEGF agents, not



only because of its mechanism of action but also by its prolonged activity due to its sustained intraocular release.^{10,14–16} Moreover, DEX has indeed proven to be effective, in terms of both visual acuity and macular anatomy, in DME cases that did not respond to prior anti-VEGF treatment, thus enforcing the importance of its different mechanism of action.^{17,18}

Given such differences between DME intravitreal therapies, several studies have investigated how these drugs change the intraocular milieu of inflammatory and pro-permeability mediators. Previous reports have claimed that intravitreal bevacizumab (IVB) decreases AH VEGF levels with no effect on IL-6, IL-8, IP-10, and MCP-1.^{14,19} Moreover, intravitreal ranibizumab (IVR) (Lucentis; Genentech, Inc., San Francisco, CA, USA) has also been shown not to affect AH levels of different molecules such as IL-1Ra, IL-5, IL-6, IL-8, IP-10, MCP-1, and TNF- α .²⁰ On the other hand, steroid agents have proven to have an impact on the distribution of several mediators. For example, intravitreal triamcinolone acetonide has been reported to differentially decrease intraocular IL-6, IP-10, MCP-1, and platelet-derived growth factor (PDGF)-AA when compared to IVB in DME.¹⁹ Similarly, significant associations have also been described between the DEX effect on DME thickening and several AH levels of inflammatory mediators such as insulin-like growth factor binding protein (IGFBP)-1, IGFBP-3, prolactin, matrix metalloproteinase (MMP)-9, endocrine-gland VEGF (EG-VEGF), endostatin, angiopoietin-2, persephin, MIP-1, thrombospondin (THSP)-2, hepatocyte growth factor (HGF), IL-8, and C-X-C motif ligand (CXCL)-16.²¹ Finally, recent studies have even described an association between baseline levels of some AH agents such as ICAM-1 and eotaxin-1 with DME response to IVR objectively measured by OCT.²²

In summary, the main objective of this study was to determine the relationship between baseline AH levels of several cytokines and growth factors and DME anatomic response to DEX, quantitatively measured by OCT. Moreover, additional clinically relevant baseline characteristics, including treatment status, DME OCT patterns, and other ocular comorbidities were investigated.

METHODS

Study and Participants

This was an observational, prospective, 2-month follow-up study. Participants were adults with type 1 or 2 diabetes and DR with center-involving DME as defined by the international scale,^{23,24} with Early Treatment Diabetic Retinopathy Study (ETDRS)-defined central macular thickness (CMT) ≥ 300 μm on spectral-domain (SD) OCT (Cirrus SD OCT; Carl Zeiss Meditec, Inc., Dublin, CA, USA). Selection for DEX treatment was based on common clinical practice standards: on one hand, previously anti-VEGF-treated patients with poor response and, on the other hand, treatment-naïve DME cases that could not cope with monthly treatment regimens. Exclusion criteria included proliferative DR, prior intraocular surgery of any kind beyond uncomplicated cataract removal, intravitreal injection of any anti-VEGF agent within 3 months, and any steroid drug injection within 6 months prior to the inclusion date. Whenever DME was bilaterally present, the eye with a higher CMT determined by SD-OCT was selected as the study eye. The study took place from January 2015 to February 2018 and was approved by the local Institutional Review Board (Ethics and Clinical Investigation Committee, Hospital Clínic of Barcelona) and carried out according to the Declaration of Helsinki. All participants provided written informed consent to join the study.

Study Protocol

Each patient received DEX injection with undiluted AH fluid collection (0.1 mL) at the same time by an anterior chamber tap. All intravitreal injections were performed by a retina specialist under topical anesthesia and sterile conditions after povidone iodine 5% was instilled on THE conjunctival fornix. Taps were performed using a 30-gauge needle with a tuberculin syringe through a limbal paracentesis. DEX implant was then injected 4 mm from the limbus on the superotemporal quadrant and the optic nerve head perfusion checked. Topical ofloxacin 0.3% three times a day was administered on the same day and 3 days afterward. All AH specimens were immediately transferred to a sterile tube and stored at -70°C until assayed.

Nine different immune mediators were measured in the AH samples: proinflammatory agents (IL-1 β , IL-3, IL-6, IL-8, MCP-1, IP-10), type 1 cytokines (TNF- α), type 2 cytokines (IL-10), and growth factors (VEGF). These molecules were selected based on previously published studies regarding AH levels of cytokines, chemokines, and growth factors in DME.^{6,7} The Luminex platform (Millipore MilliPlex Human Cytokine/Chemokine kit; Merck Millipore, Inc., Burlington, MA, USA) was used to measure such molecule levels in AH samples using an assay plate layout consisting of seven standards in duplicate (3.2–2000 pg/mL), one blank well (for background fluorescence subtraction), two internal quality control samples in duplicate, and 25 μL duplicates of each sample. The MilliPlex method was performed as recommended by the manufacturer. Zero values were statistically handled as a third of the provided detection limit. Uncertainty regarding the reliability of three cytokine measurements (IL-1 β , IL-3, and IL-10) was found due to their determinations generally staying at the lower sensitivity limit for the immunoassay. These molecules were finally excluded from the analysis.

Every participant underwent a complete ocular examination to assess DME severity prior to treatment and in the first follow-up visit to be scheduled 6 to 8 weeks after AH sampling and DEX injection. It included a comprehensive ophthalmic assessment, concomitant diseases and treatments, best-corrected visual acuity (BCVA) by Snellen chart recording (and conversion to logMAR for statistical analysis), IOP measurement, slit-lamp and fundus examination under pupil dilation, DR grading per the international-based scale,²⁵ and SD-OCT examination using a standard macular cube 518×128 - μm protocol. The analysis of OCT images included the determination of quantitative parameters such as CMT and MV determined with the built-in manufacturer software, as well as qualitative features such as DME patterns classified as diffuse retinal thickening (DRT), cystoid macular edema, serous retinal detachment, epiretinal membrane, and hyperreflective retinal spots as defined by previously published studies.^{25–28}

Study Outcomes

Changes in CMT and MV after treatment were set as primary study outcomes. In addition, all patients were categorized into responders and nonresponders on both CMT and MV characteristics in a similar manner to that reported in already published investigations. A CMT responder was defined as a patient with 50% or greater reduction in excess CMT (>300 μm) from baseline to 6 to 8 weeks follow-up.²² An MV responder was defined in the same way as a patient with a 10% or greater reduction in MV.²²

Statistical Analysis

Absolute frequencies and percentages were used to describe categorical variables. The description of quantitative variables

TABLE 1. Baseline Characteristic Features

Characteristics	Value
Demographic, <i>n</i> = 70	
Age, mean (SD) [range], years	71 (9.1) [51–89]
Sex, no. (%)	
Male	37 (52.9)
Female	33 (47.1)
Laterality, no. (%)	
Right	34 (48.6)
Left	36 (51.4)
Lens status, no. (%)	
Phakic	39 (55.7)
Pseudophakic	31 (44.3)
Intraocular pressure, mean (SD) mm Hg	16.9 (3)
Best-corrected visual acuity	
Snellen, mean (range)	20/63 (20/25–20/800)
LogMAR, mean (SD) [range]	0.6 (0.4) [0.1–2]
OCT features	
Central macular thickness, mean (SD) [range], μm	453.2 (116.1) [302–924]
Macular volume, mean (SD) [range], mm^3	12.1 (2.1) [7–17.2]
Grading of diabetic retinopathy, no. (%)	
Mild	20 (28.6)
Moderate	37 (52.9)
Severe	13 (18.6)
Duration of diabetes, mean (SD) [range], years	13.5 (8.4) [1–40]
HbA _{1c} , mean (SD) [range], %, <i>n</i> = 44	7.7 (1.5) [5.5–12.3]
Prior DME treatment, no. (%)	
Yes	44 (62.9)
No	26 (37.1)
Previous DME treatment, sole or combination, no. (%), <i>n</i> = 44	
Intravitreal anti-VEGF	25 (56.8)
Intravitreal DEX implant	22 (50)
Intravitreal TCA	6 (13.6)
Macular laser	11 (25)

Abbreviations: HbA_{1c}, hemoglobin A_{1c}; TCA, triamcinolone acetonide.

was performed using mean, standard deviation (SD), median, and interquartile interval. The Kolmogorov-Smirnov test was used to assess the normality of distributions. Changes in clinical features between baseline and 6- to 8-week visits were analyzed using a paired *t*-test. Linear relationships between changes in CMT and MV during follow-up and cytokine levels at baseline were carried out by Spearman correlation coefficient analysis. Cytokine concentrations were log-transformed in order to decrease variability for the two multivariate models. Back stepwise linear regression models were developed including changes in CMT and MV during follow-up as dependent variables. Variables with a significance <0.1 in the univariate analysis were included as independent factors. Adjusted *R*_s and regression for each model was also provided.

TABLE 2. Changes in Clinical Features Between Baseline and 6- to 8-Weeks Visit

Study Characteristic	Baseline	6–8 Weeks	Change	<i>P</i> Value*
Best-corrected visual acuity				
LogMAR, mean (SD)	0.61 (0.41)	0.55 (0.42)	–0.07 (0.17)	0.001
IOP, mean (SD), mm Hg	16.91 (3.03)	19 (4.65)	2.07 (4.67)	<0.001
OCT features				
CMT, mean (SD), μm	453 (116)	324 (80)	–129 (–116)	<0.001
MV, mean (SD), mm^3	12.13 (2.10)	10.76 (1.41)	–1.37 (1.28)	<0.001

* Statistically significant at *P* < 0.05.

Similarly, two back stepwise logistic regression models were carried out including CMT and MV responder as dependent variables. The Hosmer-Lemeshow goodness-of-fit test was performed to assess the overall fit of the model. For all the tests *P* values <0.05 were considered statistically significant. The statistical package R Studio 2.5 (www.R-project.org) was used for the statistical analyses.²⁹

RESULTS

Seventy cases from 70 participants were included in the study and analysis. Baseline characteristics are summarized in Table 1. DME evaluation was performed 6 to 8 weeks after DEX injection at a mean (SD) of 49 (19) days. DME ophthalmologic assessment changes with DEX, including BCVA, IOP, CMT, and MV, are shown in Table 2. Mean logMAR (SD) BCVA improved from 0.61 (0.41) to 0.55 (0.42) whereas CMT and MV both decreased from 453 μm (116) and 12.13 mm^3 (2.10) to 324 μm (80) and 10.76 mm^3 (1.41), respectively. There was a rise in mean IOP (SD) from baseline 16.91 mm Hg (3.03) to 19 mm Hg (4.65) at follow-up, which was also statistically significant.

Statistically significant correlations were found between MV change and baseline AH levels of IL-6 (*r* = –0.36; *P* = 0.002), IL-8 (*r* = –0.34; *P* = 0.004), IP-10 (*r* = –0.28; *P* = 0.021), and MCP-1 (*r* = –0.31; *P* = 0.009), with no correlations being observed between any AH mediator and CMT change (Table 3; Fig.). The multivariate linear regression model (Table 4) showed that higher baseline MV (β = –2.4; *P* < 0.001) and presence of prior panretinal photocoagulation (PRP) (β = –105.7; *P* < 0.001) were associated with a higher decrease in CMT (*R*_s of 0.309). On the other hand, a higher decrease in MV was associated (*R*_s of 0.512) with higher baseline MCP-1 (β = –0.4; *P* = 0.028), higher CMT prior to treatment (β = –0.003; *P* = 0.024), decreased baseline BCVA per increased logMAR determination (β = –0.7; *P* = 0.040), and presence of DRT (β = –1.3; *P* < 0.001). No other baseline AH mediators or other variables were associated with CMT or MV change.

Regarding DME response to DEX as a categorized variable, 59 of 70 participants (84.3%) were found to be CMT responders based on the definition previously described. Thirty-three of 70 were defined as responders according to MV change. Backwise logistic regression models showed that the existence of a baseline DRT pattern of DME (odds ratio [OR], 31.96; 95% CI 7.11–143.72; *P* < 0.001) and a decreased BCVA at baseline per increased logMAR determination (OR, 9.24; 95% CI 1.06–80.58; *P* = 0.044) were independently related to MV response (Hosmer-Lemeshow *P* = 0.42). No baseline variable or AH mediator was found to be associated with being defined as a responder by CMT change.

DISCUSSION

Assessing macular edema response to intravitreal treatment is one of the most challenging topics nowadays in retinal disease.

TABLE 3. Baseline AH Mediator Levels and Correlation to DME Anatomic Response

Intraocular Mediator	AH Level, Median (IQI), pg/mL	Correlation to CMT Change*	P Value†	Correlation to MV Change*	P Value†
IL-6	6.3 (1; 32.4)	-0.22	0.071	-0.36	0.002
IL-8	14.1 (6.7; 30.4)	-0.23	0.060	-0.34	0.004
IP-10	240.5 (163.6; 597.7)	-0.17	0.156	-0.28	0.021
MCP-1	3212.9 (2097.2; 6933.1)	-0.14	0.261	-0.31	0.009
TNF- α	0.3 (0.2; 2.2)	-0.08	0.511	-0.02	0.855
VEGF	73.1 (8.8; 190.4)	0.15	0.249	0.05	0.724

Abbreviation: IQI, interquartile interval.
 * Spearman correlation coefficient.
 † Statistically significant at $P < 0.05$.

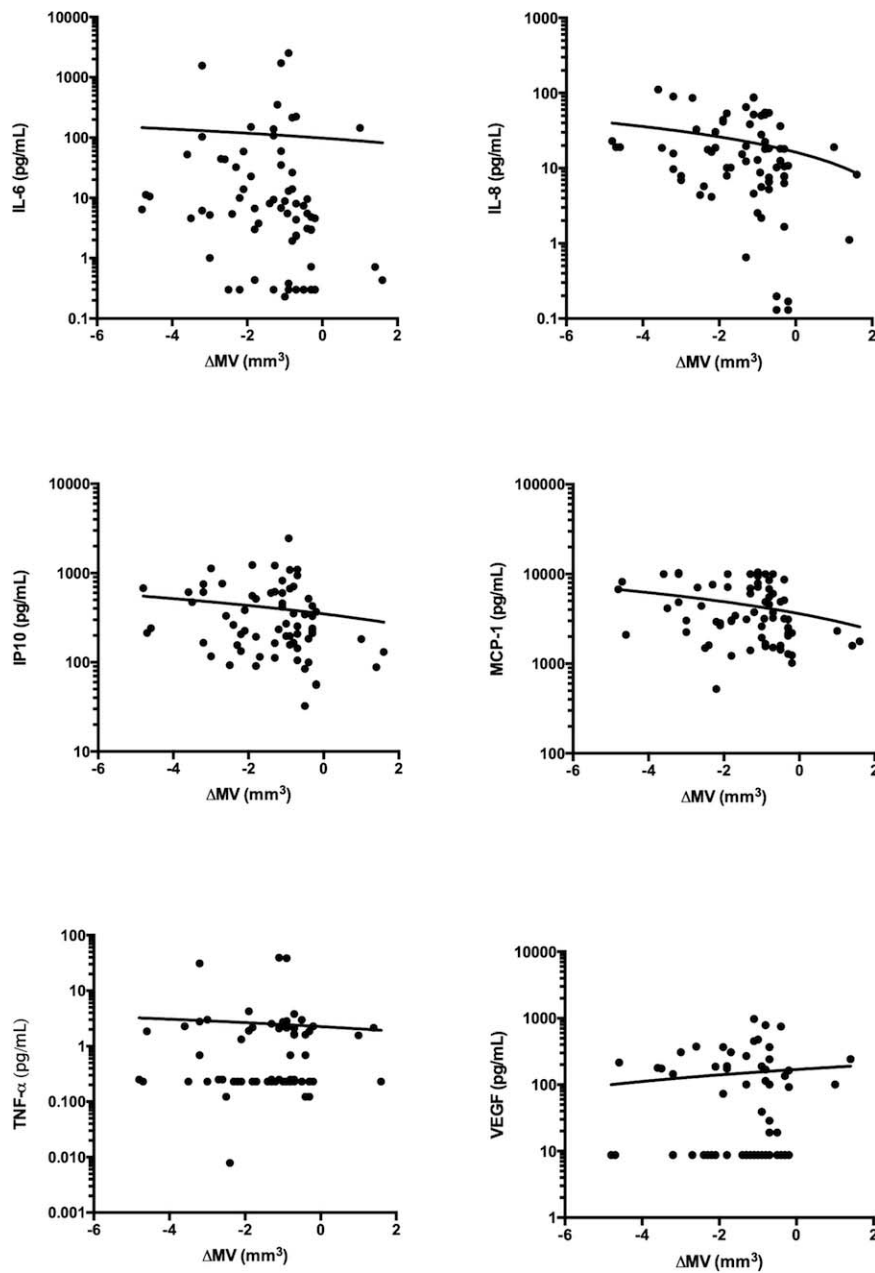


FIGURE. Series of scatter plots representing correlations between cytokine (IL-6, IL-8, IP-10, MCP-1, TNF- α , and VEGF) aqueous humor levels (pg/mL) and OCT-based macular volume (mm³) change (Δ MV) due to intravitreal dexamethasone implant injection for DME. Showing drawn line as correlation. Note that y-axis set on logarithmic scale.

TABLE 4. Univariate and Multivariate Linear Regression Models for Change in Disease Severity Measures

Baseline Variable	Univariate CMT			Multivariate CMT*			Univariate MV			Multivariate MV†		
	β	CI 95%	P Value‡	β	CI 95%	P Value‡	β	CI 95%	P Value‡	β	CI 95%	P Value‡
Demographics												
Age	-1.8	-4.9 to 1.3	0.246				0.003	-0.03 to 0.04	0.845			
Sex	9.9	-46 to 65.8	0.725				-0.3	-0.9 to 0.3	0.285			
Diabetes duration	2.3	-1.1 to 5.7	0.184				0.01	-0.03 to 0.1	0.599			
HbA _{1c}	12.8	-14.1 to 39.7	0.343				0.1	-0.2 to 0.4	0.523			
Previous IVT	6.8	-5.1 to 64.6	0.814				0.4	-0.3 to 1	0.278			
Anti-VEGF	13.8	-44.4 to 72	0.637				0.5	-0.1 to 1.1	0.123			
DEX	-34.1	-93.7 to 25.5	0.258				-0.2	-0.9 to 0.4	0.478			
TCA	-93.4	-190.6 to 3.7	0.059				-0.4	-1.5 to 0.7	0.507			
Prior macular laser	-48.4	-124.3 to 27.4	0.207				0.2	-0.6 to 1	0.635			
Prior PRP	-101.2	-161.6 to -40.9	0.001	-105.7	-159.5 to -51.8	<0.001	-0.4	-1.1 to 0.3	0.249			
Eye assessment												
Laterality	28.6	-26.9 to 84	0.308				-0.01	-0.6 to 0.6	0.983			
BCVA, logMAR	-124.3	-185.8 to -62.8	<0.001				-1.5	-2.2 to -0.9	<0.001	-0.7	-1.3 to -0.03	0.040
IOP	3.5	-5.9 to 12.9	0.462				0.03	-0.1 to 0.1	0.599			
Phakic status	-34.4	-91 to 22.2	0.229				-0.4	-1 to 0.3	0.250			
DR grading	-20.6	-57.9 to 16.7	0.274				-0.4	-0.8 to -0.04	0.031			
CMT							-0.005	-0.007 to -0.002	<0.001	-0.003	-0.01 to -0.0003	0.024
MV	-21.2	-35.3 to -11	<0.001	-24	-35 to -12.9	<0.001						
AH mediator levels§												
Log IL-6	-8.7	-20.7 to 3.2	0.148				-0.1	-0.3 to -0.004	0.044			
Log IL-8	-19.8	-38 to -1.7	0.033				-0.3	-0.5 to -0.1	0.007			
Log IP-10	-30.4	-62.1 to 1.4	0.061				-0.4	-0.7 to -0.01	0.046			
Log MCP-1	-28.8	-67.7 to 10.1	0.144				-0.5	-0.9 to -0.1	0.023	-0.4	-0.7 to -0.04	0.028
Log TNF-α	-0.3	-19.2 to 18.6	0.977				0.03	-0.2 to 0.2	0.773			
Log VEGF	10.8	-8.6 to 30.2	0.268				0.06	-0.1 to 0.3	0.528			
OCT DME pattern												
DRT	-61.7	-124.1 to 0.7	0.053				-1.7	-2.2 to -1.2	<0.001	-1.3	-1.7 to -0.8	<0.001
CME	-12.4	-87.6 to 62.8	0.743				1.2	0.5 to 1.9	0.001			
SRD	4.7	-77.6 to 86.9	0.910				-0.8	-1.7 to 0.02	0.046			
ERM	-33.1	-121.8 to 55.5	0.457				-0.6	-1.5 to 0.3	0.168			
HRS	-13.6	-128.5 to 101.4	0.814				0.3	-0.9 to 1.5	0.587			

Abbreviations: β, beta coefficient; CME, cystoid macular edema; ERM, epiretinal membrane; HRS, hyperreflective retinal spots; IVT, intravitreal treatment; SRD, serous retinal detachment.

* Adjusted $R_s = 0.309$; change in CMT (μm) = $187.6 - [24 \times \text{MV} (\text{mm}^2)] - [105.7 \text{ in case of PR}]$.

† Adjusted $R_s = 0.512$; change in MV (mm^3) = $3.72 - [0.4 \times \log \text{MCP1}] - [0.7 \times \text{BCVA} (\log\text{MAR})] - [0.003 \times \text{CMT} (\mu\text{m})] - [1.3 \text{ in case of DRT}]$.

‡ Statistically significant at $P < 0.05$.

§ Log transformation of each AH mediator to reduce variability.

Even though BCVA remains the main outcome in most studies and keeps a direct relation to the patient perception of visual health, its clinical application is limited by myriad confounding factors such as macular ischemia and chronic tissue damage, frequently associated with advanced stages of DR and long-standing DME. On the other hand, CMT is still considered the objective quantitative gold-standard indicator of macular edema severity. However, it can have important variability errors when measuring retinal thickness in the ETDRS 1-mm-diameter subfield.²⁹ Moreover, due to its reduced area, CMT does not always correctly reflect generalized macular thickening if the central subfield is spared. Nonetheless, MV has recently emerged as a better indicator of macular edema severity and its response to treatment overcoming some traditionally important existing biases in both BCVA and CMT.^{6,8,22}

The key point of the present study is therefore to present results of DEX treatment for DME based on MV in addition to CMT, similarly to recently published studies on the effect of anti-VEGF drugs in DME.²² For instance, some published reports on DEX and DME have already shown CMT changes to be correlated to several AH cytokines, but again, important biases related to the use of CMT as a surrogate marker of treatment response limit the extent of their conclusions.²¹ Our study found MV change with DEX to be correlated to several AH mediators such as IL-6, IL-8, IP-10, and MCP-1, with no association to CMT change (Table 3; Fig.). When multivariate linear regression models were applied, MV change was found to keep the association to MCP-1 AH levels as well as a DRT pattern of DME cases on OCT, all together with baseline CMT and BCVA. Interestingly, this model performed a notable predictability of MV change ($R_s = 0.512$), contrary to that of CMT change ($R_s = 0.309$) that was mainly related to baseline MV and existing PRP (Table 4). It remains unclear whether prior PRP itself could influence CMT response but not MV response, given the existing CMT interpretation biases. Finally, when response to treatment was categorized in a dichotomized manner, no association was observed regarding CMT; nevertheless, MV changes kept the OCT diffuse pattern of DME and baseline BCVA as predictors.

As a whole, our results suggest that two items, MCP-1 and DRT, bear an important predictive value of overall macular edema response to DEX therapy and could therefore be proposed as effective biomarkers prior to treatment. On the other hand, the baseline CMT role regarding MV change has to be carefully considered, as both items are extracted from the same OCT images and therefore biases could exist. In fact, MV has also been found to influence CMT. In a similar way, the association between low BCVA and increased MV response is consistent with everyday clinical practice but also has to be carefully handled, taking into consideration all confounders affecting visual function in DME and DR.

MCP-1, also referred to as chemokine (C-C motif) ligand 2 (CCL2), is a chemokine inducing monocyte and macrophage infiltration to tissues with angiogenic properties.³⁰ In vivo models of blood-retinal barrier and DR have even experimentally shown MCP-1 to be directly involved in retinal microglia activation, thus highlighting its crucial role in this situation.³¹ Although MCP-1 is widely considered to be associated with DME,^{6,7} there is a paucity of information regarding its AH level response to intravitreal steroid injection in such a setting or its relation to retinal thickening changes with treatment.^{19,21} Interestingly, however, some published reports found MCP-1 AH level to decrease with DEX injection for retinal vein occlusion-derived macular edema.³² By means of the current results, we have proven MCP-1 to be directly related to MV change in DME under DEX treatment. This finding is consistent with the general understanding of the steroid effect on DME

and, moreover, highlights this molecule as a crucial role-playing agent in DME.

Contrary to MCP-1 behavior, VEGF levels have not been found to have any correlation to DEX effect on DME by OCT measurements. Previous reports on this topic also failed to find an association between DEX and VEGF ocular isoforms,^{21,32} despite existing publications on other steroid agents such as triamcinolone acetonide.¹⁹ Interestingly, Hillier et al.²² recently reported VEGF AH levels to be inversely correlated to DME MV response to IVR. This paradoxical point, which is reinforced by our findings, suggests the existence of many more acting mediators in DME besides VEGF.

On the other hand, DME presenting with a diffuse thickening of the retina has also been found to be predictive of MV response to DEX. OCT-based patterns of DME have been a well-studied issue, especially regarding their relation to AH mediators and response to treatment. For instance, serous retinal detachment has been the most widely reported pattern to be associated with intraocular inflammation by means of increased AH mediator levels, such as IL-6,^{26,27,33} but also showing the predictive value of better BCVA response to DEX treatment.³⁴ However, diffuse macular thickening is also associated with increased AH levels of several cytokines^{6,26} and has even been related to increased peripheral blood serum levels of IL-6.³⁵ With such a background, our finding of DRT as an independent predictive variable of MV change is important, as this is an OCT-derived feature that can be easily identified in a routine clinical practice setting and has been proven to increase the odds of an MV response defined as $\geq 10\%$ reduction in such parameter.

Limitations

The present study has some limitations. First, although AH is the most used intraocular specimen nowadays to study retinal diseases,^{5,36,37} the analysis of the vitreous fluid should be considered the ideal sample in such cases.^{38,39} However, unless vitreoretinal surgery is mandatory due to DR complications, obtaining vitreous samples for research purposes in DME is nowadays not practical nor ethically fully feasible. Therefore, AH is considered the most adequate biological sample for looking for intraocular biomarkers in DME, as claimed by several recent investigations.^{6,21,22} Second, lacking an AH sample obtained in the immediate follow-up could have limited the extent of our conclusions since it could have determined how the searched mediators changed with DEX end of action and DME eventual relapse. This point may set up subsequent investigations to come to further validate our findings. Third, this study evaluated a large number of cytokines and thus statistical errors related to multiple testing could have occurred, even if appropriate controlling measures and multivariate analysis were undertaken accordingly. Finally, our series lacks an angiographic macular evaluation with conventional fundus fluorescein angiography, as seen in similar previous reports,²² which could limit the outcomes reported due to undetected macular ischemia, especially regarding BCVA outcomes.

CONCLUSIONS

In summary, our data enforce the general understanding of DME as a complex entity with myriad involved correlated agents. Through complex analysis, some of these items can be considered biomarkers of disease severity and, in this case, even of DME response to DEX treatment. Apart from the suggested limitations of this work, these findings may contribute to understanding the effect of steroid drugs in the intraocular media of DME cases and could set interesting

starting points for future investigations. We have highlighted the role of MCP-1 as a crucial molecule in the DME process, which may be able to predict MV change with DEX treatment and therefore be considered in individualized treatment algorithms based on baseline analysis of biologic samples. Moreover, an OCT-based DME feature, DRT, has shown potential value in predicting treatment response. The data presented support a possible future reality in DME management in which imaging and biologic features may be used in a form of personalized medicine to predict response to treatment.

Acknowledgments

Disclosure: **M. Figueras-Roca**, Allergan (R); **A. Sala-Puigdollers**, Allergan (R); **J. Zarranz-Ventura**, Allergan (R), **C. Alba-Linero**, None; **S. Alforja**, None; **C. Esquinas**, None; **B. Molins**, None; **A. Adán**, Allergan (R)

References

- Klein R, Klein BE, Moss SE. Visual impairment in diabetes. *Ophthalmology*. 1984;91:1-9.
- Klein R, Klein BE, Moss SE, et al. The Wisconsin Epidemiologic Study of Diabetic Retinopathy XV: the long-term incidence of macular edema. *Ophthalmology*. 1995;102:7-16.
- Chen E, Looman M, Laouri M, et al. Burden of illness of diabetic macular edema: literature review. *Curr Med Res Opin*. 2010;26:1587-1597.
- Tang J, Kern TS. Inflammation in diabetic retinopathy. *Prog Retin Eye Res*. 2011;30:343-358.
- Vujosevic S, Simó R. Local and systemic inflammatory biomarkers of diabetic retinopathy: an integrative approach. *Invest Ophthalmol Vis Sci*. 2017;58:BIO68-BIO75.
- Dong N, Xu B, Chu L, et al. Study of 27 aqueous humor cytokines in type 2 diabetic patients with or without macular edema. *PLoS One*. 2015;10:e0125329.
- Jonas JB, Jonas RA, Neumaier M, et al. Cytokine concentration in aqueous humor of eyes with diabetic macular edema. *Retina*. 2012;32:2150-2157.
- Hillier RJ, Ojaimi E, Wong DT, et al. Aqueous humor cytokine levels as biomarkers of disease severity in diabetic macular edema. *Retina*. 2017;37:761-769.
- Fogli S, Mogavero S, Egan CG, et al. Pathophysiology and pharmacological targets of VEGF in diabetic macular edema. *Pharmacol Res*. 2016;103:149-157.
- Dugel PU, Bandello F, Loewenstein A. Dexamethasone intravitreal implant in the treatment of diabetic macular edema. *Clin Ophthalmol*. 2015;16:1321-1335.
- Wells JA, Glassman AR, Ayala AR, et al.; Diabetic Retinopathy Clinical Research Network. Aflibercept, bevacizumab, or ranibizumab for diabetic macular edema. *N Engl J Med*. 2015;372:1193-1203.
- Wells JA, Glassman AR, Ayala AR, et al.; Diabetic Retinopathy Clinical Research Network. Aflibercept, bevacizumab, or ranibizumab for diabetic macular edema: two-year results from a comparative effectiveness randomized clinical trial. *Ophthalmology*. 2016;123:1351-1359.
- Papadopoulos N, Martin J, Ruan Q, et al. Binding and neutralization of vascular endothelial growth factor (VEGF) and related ligands by VEGF Trap, ranibizumab and bevacizumab. *Angiogenesis*. 2012;15:171-185.
- Chang-Lin JE, Attar M, Acheampong AA, et al. Pharmacokinetics and pharmacodynamics of a sustained-release dexamethasone intravitreal implant. *Invest Ophthalmol Vis Sci*. 2011;52:80-86.
- Boyer DS, Yoon YH, Belfort RJ, et al. Three-year, randomized, sham-controlled trial of dexamethasone intravitreal implant in patients with diabetic macular edema. *Ophthalmology*. 2014;121:1904-1914.
- Boyer DS, Faber D, Gupta S, et al. Dexamethasone intravitreal implant for treatment of diabetic macular edema in vitrectomized patients. *Retina*. 2011;31:915-923.
- Busch C, Zur D, Fraser-Bell S, et al. Shall we stay, or shall we switch? Continued anti-VEGF therapy versus early switch to dexamethasone implant in refractory diabetic macular edema. *Acta Diabetologica*. 2018;55:789-796.
- Iglicki M, Busch C, Zur D, et al. Dexamethasone implant for diabetic macular edema in naive compared with refractory eyes: the International Retina Group Real-Life 24-Month Multicenter Study. The IRGREL-DEX Study. *Retina*. 2019;39:44-51.
- Sohn HJ, Han DH, Kim IT, et al. Changes in aqueous concentrations of various cytokines after intravitreal triamcinolone versus bevacizumab for diabetic macular edema. *Am J Ophthalmol*. 2011;152:686-694.
- Shiraya T, Kato S, Araki F, et al. Aqueous cytokine levels are associated with reduced macular thickness after intravitreal ranibizumab for diabetic macular edema. *PLoS One*. 2017;12:e0174340.
- Campochiaro PA, Hafiz G, Mir TA, et al. Pro-permeability factors in diabetic macular edema; the Diabetic Macular Edema Treated with Ozurdex Trial. *Am J Ophthalmol*. 2016;168:13-23.
- Hillier RJ, Ojaimi E, Wong DT, et al. Aqueous humor cytokine levels and anatomic response to intravitreal ranibizumab in diabetic macular edema. *JAMA Ophthalmol*. 2018;136:382-388.
- Wilkinson CP, Ferris FL, Klein RE, et al. Proposed international clinical diabetic retinopathy and diabetic macular edema disease severity scales. *Ophthalmology*. 2003;110:1677-1682.
- Wu L, Fernandez-Loaiza P, Sauma J, et al. Classification of diabetic retinopathy and diabetic macular edema. *World J Diabetes*. 2013;4:290-294.
- Kim BY, Smith SD, Kaiser PK. Optical coherence tomographic patterns of diabetic macular edema. *Am J Ophthalmol*. 2006;142:405-412.
- Kim JY, Jeong YJ, Park SP. Different concentrations of aqueous cytokines according to diabetic macular edema patterns as determined by optical coherence tomography. *J Clin Exp Ophthalmol*. 2014;5:380.
- Kim M, Kim Y, Lee SJ. Comparison of aqueous concentrations of angiogenic and inflammatory cytokines based on optical coherence tomography patterns of diabetic macular edema. *Indian J Ophthalmol*. 2015;63:312-317.
- Kang JW, Chung H, Chan Kim H. Correlation of optical coherence tomographic hyperreflective foci with visual outcomes in different patterns of diabetic macular edema. *Retina*. 2016;36:1630-1639.
- Campbell RJ, Coupland SG, Buhrmann RR, et al. Effect of eccentric and inconsistent fixation on retinal optical coherence tomography measures. *Arch Ophthalmol*. 2007;125:624-627.
- Meleth AD, Agron E, Chan CC, et al. Serum inflammatory markers in diabetic retinopathy. *Invest Ophthalmol Vis Sci*. 2005;46:4295-4301.
- Rangasamy S, McGuire PG, Franco Nitta C, et al. Chemokine mediated monocyte trafficking into the retina: role of inflammation in alteration of the blood-retinal barrier in diabetic retinopathy. *PLoS One*. 2014;20:e108508.
- Rezar-Dreindl S, Eibenberger K, Pollreis A, et al. Effect of intravitreal dexamethasone implant on intra-ocular cytokines

- and chemokines in eyes with retinal vein occlusion. *Acta Ophthalmol.* 2017;95:e119-e127.
33. Bandyopadhyay S, Bandyopadhyay SK, Saha M, et al. Study of aqueous cytokines in patients with different patterns of diabetic macular edema based on optical coherence tomography. *Int Ophthalmol.* 2017;38:241-249.
 34. Zur D, Igllicki M, Busch C, et al. OCT biomarkers as functional outcome predictors in diabetic macular edema treated with dexamethasone implant. *Ophthalmology.* 2017;125:267-275.
 35. Figueras-Roca M, Molins B, Sala-Puigdollers A, et al. Peripheral blood metabolic and inflammatory factors as biomarkers to ocular findings in diabetic macular edema. *PLoS One.* 2017; 12:e0173865.
 36. Cheng Y, Feng J, Zhu X, et al. Cytokines concentrations in aqueous humor of eyes with uveal melanoma. *Medicine (Baltimore).* 2019;98:e14030.
 37. Agrawal R, Balne PK, Wei X, et al. Cytokine profiling in patients with exudative age-related macular degeneration and polypoidal choroidal vasculopathy. *Invest Ophthalmol Vis Sci.* 2019;60:376-382.
 38. Suzuki Y, Nakazawa M, Suzuki K, et al. Expression profiles of cytokines and chemokines in vitreous fluid in diabetic retinopathy and central retinal vein occlusion. *Jpn J Ophthalmol.* 2011;55:256-263.
 39. Ghodasra DH, Fante R, Gardner TW, et al. Safety and feasibility of quantitative multiplexed cytokine analysis from office-based vitreous aspiration. *Invest Ophthalmol Vis Sci.* 2016; 57:3017-3023.