

# Topical Treatment With Brimonidine and Somatostatin Causes Retinal Vascular Dilation in Patients With Early Diabetic Retinopathy From the EUROCONDOR

Jakob Grauslund,<sup>1-3</sup> Ulrik Frydkjaer-Olsen,<sup>1,2</sup> Tunde Peto,<sup>2,4</sup> Jimena Fernández-Carneado,<sup>5</sup> Berta Ponsati,<sup>5</sup> Cristina Hernández,<sup>6</sup> José Cunha-Vaz,<sup>7</sup> and Rafael Simó<sup>6</sup>; for the EUROCONDOR

<sup>1</sup>Department of Ophthalmology, Odense University Hospital, Odense, Denmark

<sup>2</sup>Department of Clinical Research, University of Southern Denmark, Odense, Denmark

<sup>3</sup>Steno Diabetes Center Odense, Odense University Hospital, Odense, Denmark

<sup>4</sup>Centre for Public Health, Institute of Clinical Sciences, Queen's University Belfast, Belfast, United Kingdom

<sup>5</sup>BCN Peptides, Barcelona, Spain

<sup>6</sup>Diabetes and Metabolism Research Unit, Institut de Recerca Hospital Universitari Vall d'Hebron (VHIR), Barcelona, Spain

<sup>7</sup>Association for Innovation and Biomedical Research on Light and Image (AIBILI), and University of Coimbra, Coimbra, Portugal

Correspondence: Jakob Grauslund, Department of Ophthalmology, Odense University Hospital, Sdr. Boulevard 29, Odense DK-5000, Denmark; jakob.grauslund@rsyd.dk.

Please see appendix for members of the EUROCONDOR.

Submitted: December 20, 2018

Accepted: April 23, 2019

Citation: Grauslund J, Frydkjaer-Olsen U, Peto T, et al.; for the EUROCONDOR. Topical treatment with brimonidine and somatostatin causes retinal vascular dilation in patients with early diabetic retinopathy from the EUROCONDOR. *Invest Ophthalmol Vis Sci*. 2019;60:2257-2262. <https://doi.org/10.1167/iavs.18-26487>

**PURPOSE.** Structural retinal microvascular changes have been identified as risk markers of diabetic retinopathy (DR). In order to estimate the retinal response of neuroprotective eye drops, we aimed to evaluate the effect of topical retinal neuroprotection on retinal microvascular changes in early DR.

**METHODS.** Patients with type 2 diabetes with no or early DR were randomized 1:1:1 to topical treatment with placebo, brimonidine, or somatostatin in a 96-week prospective, phase II to III, European multicenter trial. Retinal vascular calibers were measured semiautomatically in digital fundus images by certified graders at baseline and follow-up and summarized as central retinal arteriolar and venular equivalent (CRAE and CRVE).

**RESULTS.** Of 449 patients originally included, 297 completed the study with gradable retinal images. Median age and duration of diabetes was 64.5 and 9.9 years, and 65.7% were male. At baseline, Early Treatment Diabetic Retinopathy Study levels were 10 (no DR, 42.8%), 20 (minimal DR, 28.3%), and 35 (mild DR, 29.0%), and CRAE and CRVE did not differ between groups. As opposed to patients with no or minimal DR at baseline, patients with mild DR in the active groups developed a larger retinal arteriolar (brimonidine: +6.2  $\mu\text{m}$ ,  $P = 0.006$ ; somatostatin: +7.2  $\mu\text{m}$ ,  $P = 0.006$ ) and venular (brimonidine: +13.9  $\mu\text{m}$ ,  $P = 0.01$ ; somatostatin: +14.3  $\mu\text{m}$ ,  $P = 0.0001$ ) caliber in contrast to those in the placebo group.

**CONCLUSIONS.** Topical treatment with brimonidine and somatostatin causes retinal arteriolar and venular dilation in patients with type 2 diabetes and preexisting early DR. Upcoming studies should elaborate on the potential of these findings in arresting early DR.

**Keywords:** diabetic retinopathy, topical, retinal vasculature, brimonidine, somatostatin

Diabetic retinopathy (DR) is the most common complication in diabetes<sup>1</sup> and among the leading cause of blindness among working age adults in the Western world.<sup>2</sup> DR has traditionally been considered a microvascular disease, but recent evidence has implicated retinal neurodegeneration as an early event that may even precede vascular dysfunction.<sup>3,4</sup> At present, retinal photocoagulation and intravitreal therapy with vascular endothelial growth factor inhibitors are considered the gold standard treatment in DR<sup>5-7</sup>; but given the invasive nature of the treatments, these are only considered in patients with sight-threatening DR.

Topical treatment with a neuroprotective agent would be an appealing approach to prevent or arrest DR at an early stage. This concept has been supported by experimental data demonstrating a prevention of retinal neurodegeneration by topical administration of neuroprotective drugs.<sup>8-10</sup> The European Consortium for the Early Treatment of Diabetic Retinopathy (EUROCONDOR) aimed to test the effect of

topically administered brimonidine and somatostatin on retinal neurodysfunction in patients with type 2 diabetes with no or early DR.<sup>11</sup> The study reported that in patients with preexisting retinal neurodysfunction, topical neuroprotection arrested further loss of retinal function as measured by multifocal electroretinography implicit time.<sup>12</sup>

It would also be important to investigate the structural vascular effects of topical neuroprotective treatment. However, as demonstrated by the Diabetes Control Complications Trial (DCCT), even a strong systemic intervention like strict glycemic regulation would take 3 years to affect the level of DR.<sup>13</sup> Hence, more subtle preclinical endpoints for vascular dysfunction are needed. In this aspect, the retinal vascular calibers, which can be measured noninvasively, have been associated with<sup>14,15</sup> and even predictive of sight-threatening DR.<sup>16</sup>

In order to explore the effect of topical neuroprotection on the retinal vasculature of patients with type 2 diabetes and early



DR, the aim of the present study was to evaluate the result of 2 years of treatment with brimonidine and somatostatin on the retinal vascular calibers in a randomized, clinical trial.

## METHODS

### Study Subjects

The EUROCONDOR [NCT01726075] was a European multicenter, 96-week prospective, interventional, phase II to III, randomized controlled clinical trial that aimed to evaluate the effect of topical neuroprotection to arrest or prevent early retinal neurodegeneration in DR.<sup>11</sup> In a study including 11 European centers, a total of 449 patients were recruited and randomized 1:1:1 to topical treatment twice daily (BID) with placebo, brimonidine tartrate 0.2%, or somatostatin 0.1%. Criteria of inclusion were: type 2 diabetes with no, minimal, or mild DR (Early Treatment Diabetic Retinopathy Study [ETDRS] levels 10, 20, or 35, respectively),<sup>17</sup> duration of type 2 diabetes for at least 5 years, and age between 45 and 75 years. Exclusion criteria included previous retinal photocoagulation, retinal degenerative diseases (i.e., glaucoma), and refractive error or  $\pm 5$  diopters or more, hazy ocular media, inadequate pupil dilation, renal failure (creatinine  $>124 \mu\text{m/L}$ ) or HbA1c  $>10\%$  (86 mmol/mol) in the previous 6 months.

For each patient, one eye was identified as the study eye by a central reading center (Coimbra Ophthalmology Reading Centre, Coimbra, Portugal), which also provided grading of the level of DR at baseline and follow-up.

The study was approved and funded by the European Commission Seventh Framework Program (Grant Agreement No. FP7-278040). At all centers, the study was conducted in accordance with the tenets of the Declaration of Helsinki with approvals of the local scientific ethical committees and written informed consent from all patients.

### Retinal Vascular Caliber Analysis

Mydriatic cameras (TRC-50IA, -50IX, -50EX, -50DX, -50DX Type IA, or NW6S; Topcon Corp., Tokyo, Japan) or a fundus camera (FF450 PLUS IR; Carl Zeiss Meditec, Jena, Germany) were used to capture  $30^\circ$  to  $35^\circ$  modified ETDRS-field 1 images including the optic disc of the study eye. These were subsequently used for retinal vascular caliber measurements.<sup>18</sup> Images were analyzed by IVAN (Department of Ophthalmology and Visual Science, University of Wisconsin, Madison, WI, USA), which is a semiautomatic software program that has previously been validated.<sup>19</sup>

The optic disc is automatically detected by the software, and vessel calibers are traced in a zone of 0.5 to 1.0 disc-diameters from the optic disc margin. After manual adjustment by the grader, retinal vascular calibers are summarized into the central retinal arteriolar and venular equivalent (CRAE and CRVE) according to the "Big 6-formula" that includes the six largest arterioles and venules.<sup>20</sup>

At baseline, images were graded by a single, trained grader (UFO), and at follow-up images were graded at a certified retinal image grading center (Yamagata University, Yamagata, Japan).

### Clinical Examinations

Patients were treated in each eye with 1 drop BID (placebo or somatostatin 0.1% or brimonidine tartrate 0.2%) and followed for 96 weeks with comprehensive ophthalmic examinations every 24 weeks as previously described.<sup>12</sup>

Of 449 patients invited at baseline, 297 (66.1%) completed the study with gradable retinal images at baseline and follow-

up. Of the 153 patients that were not included in the present study, reasons for noninclusion included dropout during study ( $n = 109$ ), lack of retinal images at follow-up ( $n = 17$ ), and nongradable retinal images at baseline ( $n = 10$ ) or follow-up ( $n = 17$ ). Among nonparticipants, there was a higher number of patients allocated to treatment with brimonidine (43.4% vs. 28.6%,  $P = 0.009$ ), but otherwise participants and nonparticipants did not differ according to age, duration of diabetes, sex, glycemic regulation, blood pressure, body mass index, level of DR, CRAE, or CRVE (Table 1).

### Statistical Methods

Descriptive statistics were calculated for all parameters. Continuous data are presented as median (with range), and categorical data are given as percentage. Development in retinal vascular calibers and level of DR were given as differences between follow-up and baseline.

To test for differences in unpaired, continuous data, we used nonparametric tests including Mann-Whitney  $U$  test (two groups), Kruskal-Wallis test (multiple, nonordered groups) and Cuzick's test for trend (multiple, ordered groups). Wilcoxon matched-pairs signed-rank test was used to test for differences between baseline and follow-up in matched paired of observations. Finally,  $\chi^2$  test was used to test for differences in categorical data.

Statistical analysis was performed by statistical software (Stata 15.1; StataCorp LLC, College Station, TX, USA), and  $P$  values below 0.05 were considered statistically significant.

## RESULTS

Among the 297 participants of the study, median age and duration of diabetes at baseline was 64.5 and 9.9 years, and 65.7% were male. Median levels of HbA1c, blood pressure, and body mass index were 7.0%, 135/78 mm Hg and 30.0 kg/m<sup>2</sup>, respectively. Baseline ETDRS levels of DR were 10 (42.8%), 20 (28.3%), or 35 (29.0%), and CRAE and CRVE was 146.6  $\mu\text{m}$  and 214.8  $\mu\text{m}$ , respectively.

Number of patients in each treatment group were 108 (36.4%), 85 (28.6%), and 104 (35.0%) for placebo, brimonidine, and somatostatin, respectively. Among treatment groups, patients did not differ at baseline according to age, sex, duration of diabetes, HbA1c, blood pressure, body mass index, CRAE (146.7  $\mu\text{m}$ , 147.1  $\mu\text{m}$ , and 145.2  $\mu\text{m}$ ,  $P = 0.68$ ) or CRVE (215.6  $\mu\text{m}$ , 212.7  $\mu\text{m}$ , and 215.7  $\mu\text{m}$ ,  $P = 0.89$ ; Table 2). Likewise, there was no difference in CRAE according to baseline level of DR (level 10, 144.1  $\mu\text{m}$ ; level 20, 147.7  $\mu\text{m}$ ; level 35, 148.2  $\mu\text{m}$ ;  $P = 0.10$ ), but there was a trend toward a higher CRVE for patients with increasing levels of DR (level 10, 213.7  $\mu\text{m}$ ; level 20, 214.4  $\mu\text{m}$ ; level 35, 216.1  $\mu\text{m}$ ;  $P = 0.056$ ).

During 24 months of topical treatment, there was a median increase of CRAE and CRVE of 1.0  $\mu\text{m}$  ( $P = 0.01$ ) and 2.6  $\mu\text{m}$  ( $P = 0.0002$ ) in the overall population. Changes in retinal vascular calibers depended on baseline level of DR and treatment group (Table 3). Overall, patients with higher levels of DR at baseline developed a higher CRAE (level 10,  $-1.0 \mu\text{m}$ ; level 20,  $-1.0 \mu\text{m}$ ; level 35,  $+6.1 \mu\text{m}$ ;  $P = 0.001$ ; Fig. 1) and CRVE (level 10,  $+1.3 \mu\text{m}$ ; level 20,  $+1.4 \mu\text{m}$ ; level 35,  $+10.3 \mu\text{m}$ ;  $P = 0.001$ ; Fig. 2) at follow-up. Even though there was no general difference between treatment groups in the alteration of CRAE (placebo,  $+1.8 \mu\text{m}$ ; brimonidine,  $+1.9 \mu\text{m}$ ; somatostatin,  $-0.2 \mu\text{m}$ ;  $P = 0.98$ ) or CRVE (placebo,  $+3.7 \mu\text{m}$ ; brimonidine,  $+1.3 \mu\text{m}$ ; somatostatin,  $+2.4 \mu\text{m}$ ;  $P = 0.78$ ), it was demonstrated that the development of wider retinal vascular calibers in higher levels of DR depended on the treatment regimen; patients treated with placebo did not increase in CRAE ( $P = 0.17$ ) or CRVE ( $P =$

TABLE 1. Baseline Characteristics in Patients With and Without Gradable Images\*

Patient Characteristics	Completed Study With Gradable Retinal Images	Did Not Include or With Ungradable Images	P Value
Patients, <i>n</i>	297	153	
Age, y	64.5 (45.4–76.0)	63.7 (45.8–75.7)	0.46
Duration of diabetes, y (range)	9.9 (4.9–40.4)	10.7 (4.6–31.7)	0.18
Male sex, %	65.7	67.1	0.76
HbA1c, % (range)	7.0 (5.0–10.0)	7.0 (5.4–10.8)	0.86
Systolic blood pressure, mm Hg (range)	135 (95–183)	135 (98–186)	0.34
Diastolic blood pressure, mm Hg (range)	78 (55–103)	77 (50–115)	0.87
Body mass index, kg/m <sup>2</sup> (range)	30.1 (20.1–53.9)	29.7 (19.7–53.7)	0.67
Level of DR, %			0.91
10	42.8	41.3	
20	28.3	25.9	
35	29.0	32.9	
Treatment group, %			0.009†
Placebo	36.4	28.0	
Brimonidine	28.6	43.4	
Somatostatin	35.0	28.7	
Central retinal arteriolar equivalent, μm (range)	146.6 (110.4–184.6)	146.9 (111.6–196.0)	0.66
Central retinal venular equivalent, μm (range)	214.8 (160.0–283.9)	217.1 (162.3–290.8)	0.99

Data presented as median (with minimum and maximum) or percent. Level of DR defined according to Early Treatment Diabetic Retinopathy Study scale.

\* For patients that completed the study with gradable retinal images at baseline and follow-up as compared to those that did not complete the study or had ungradable retinal images at baseline or follow-up.

† Statistically significant ( $P < 0.05$ ).

0.56) with increasing baseline levels of DR. In contrast, there was a DR-dependent arteriolar widening in patients treated with somatostatin ( $P = 0.01$ ), and a venular dilation in patients treated with brimonidine ( $P = 0.048$ ) and somatostatin ( $P = 0.01$ ).

At follow-up, level of DR improved, remained unchanged and worsened in 28.0% ( $n = 83$ ), 65.7% ( $n = 195$ ), and 6.4% ( $n = 19$ ) patients, respectively. There were no differences in rates of improvement, unchanged conditions, and DR worsening between patients in the different treatment groups (placebo, 28.7% vs. 66.7% vs. 4.6%; brimonidine, 25.9% vs. 63.5% vs. 10.6%; somatostatin, 28.9% vs. 66.4% vs. 4.8%,  $P = 0.47$ ). Of patients with a potential to improve or worsen more than one level of DR from baseline, this was only found in 23.3% (20 of 86 with ETDRS 35 at baseline) and 1.2% (2 of 127 with ETDRS

10 at baseline), respectively. There was no difference in CRAE ( $P = 0.51$ ) or CRVE ( $P = 0.75$ ) when patients were compared according to development in DR during the study.

## DISCUSSION

In a 96-week, prospective, randomized trial evaluating the retinal effect of topical neuroprotective treatment, we concluded that in patients with preexisting mild DR, brimonidine and somatostatin both induced retinal vascular dilation as opposed to placebo.

Our results are in contrast with the earlier conception that topical treatment is inadequate to induce a vascular retinal effect given the corneal barrier and the intraocular distance between the anterior and posterior part of the eye. However,

TABLE 2. Baseline Characteristics of Study Patients\*

Patient Characteristics	Placebo	Brimonidine	Somatostatin	P Value
Patients, <i>n</i>	108	85	104	
Age, y (range)	63.9 (46.8–76.0)	64.4 (50.4–74.3)	64.6 (45.4–75.3)	0.73
Duration of diabetes, y (range)	9.8 (5.4–37.3)	9.9 (5.3–40.4)	10.0 (4.9–30.6)	0.78
Male sex, %	68.5	65.9	62.5	0.65
HbA1c, % (range)	7.0 (5.0–10.0)	7.1 (5.4–10.0)	7.0 (5.4–9.7)	0.59
Systolic blood pressure, mm Hg (range)	135 (104–180)	138 (95–164)	150 (108–183)	0.77
Diastolic blood pressure, mm Hg (range)	80 (55–103)	78 (58–103)	75 (55–101)	0.26
Body mass index, kg/m <sup>2</sup> (range)	29.8 (20.4–48.5)	29.8 (20.1–53.9)	30.4 (21.6–47.7)	0.87
Level of DR, %				0.70
10	44.4	37.7	45.2	
20	28.7	25.9	26.0	
35	26.9	31.8	28.9	
Central retinal arteriolar equivalent, μm (range)	146.7 (122.7–183.5)	147.1 (114.2–183.5)	145.2 (110.4–184.6)	0.68
Central retinal venular equivalent, μm (range)	215.6 (160.0–276.0)	212.7 (174.1–265.6)	215.7 (162.8–283.9)	0.89

Data presented as median (with minimum and maximum) or per cent. Level of DR defined according to Early Treatment Diabetic Retinopathy Study scale.

\* For the 297 patients that completed the study with gradable retinal images at baseline and follow-up according to treatment group.

TABLE 3. Development in Retinal Vascular Caliber\*

Level of DR	Central Retinal Arteriolar Equivalent, $\mu\text{m}$				Central Retinal Venular Equivalent, $\mu\text{m}$			
	Placebo (n = 108)	Brimonidine (n = 85)	Somatostatin (n = 104)	All (n = 297)	Placebo (n = 108)	Brimonidine (n = 85)	Somatostatin (n = 104)	All (n = 297)
10	-0.5 (P = 0.97)	+0.6 (P = 0.78)	-1.7 (P = 0.50)	-1.0 (P = 0.85)	+2.2 (P = 0.23)	+1.5 (P = 0.64)	-0.4 (P = 0.82)	+1.3 (P = 0.31)
20	+2.9 (P = 0.20)	-2.5 (P = 0.30)	-1.8 (P = 0.89)	-1.0 (P = 0.71)	+3.8 (P = 0.046)†	-2.0 (P = 0.24)	+1.5 (P = 0.63)	+1.4 (P = 0.37)
35	+5.2 (P = 0.14)	+6.2 (P = 0.006)†	+7.2 (P = 0.006)†	+6.1 (P = 0.0001)†	+4.0 (P = 0.11)	+13.9 (P = 0.01)†	+14.3 (P = 0.0001)†	+10.3 (P < 0.0001)†
P‡	0.17	0.07	0.01†	0.0001†	0.56	0.048†	0.0001†	0.0001†

Data presented as median, and level of DR defined according to Early Treatment Diabetic Retinopathy Study scale.

\* In 297 patients with type 2 diabetes during 96 weeks of topical treatment according to treatment group and baseline level of DR.

† Statistically significant (P < 0.05).

‡ Test for trend of development in central retinal arteriolar and venular equivalent across different levels of DR.

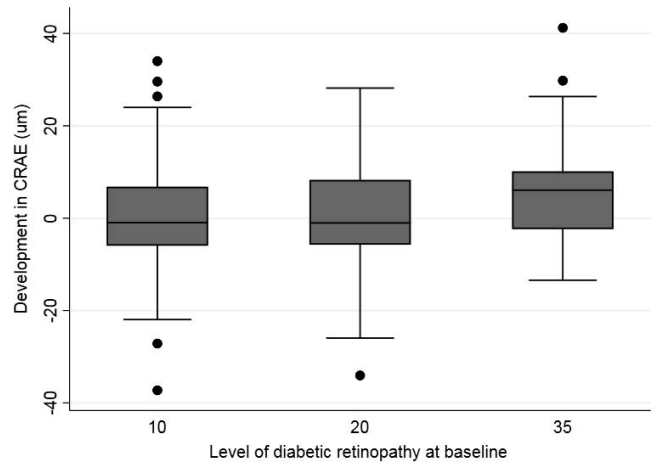


FIGURE 1. Development in CRAE during 96 weeks of topical treatment according to Early Treatment Diabetic Retinopathy Study levels of DR at baseline. There was a higher development with more advanced DR (level 10, -1.0  $\mu\text{m}$ ; level 20, -1.0  $\mu\text{m}$ ; level 35, +6.1  $\mu\text{m}$ ; P = 0.001).

this concept has been challenged by animal studies<sup>8,9</sup> as well as a 1-week trial by Tilma and Bek<sup>21</sup> demonstrating retinal arteriolar narrowing in 22 patients with type 1 diabetes treated with topical latanoprost. In the present study, we demonstrate a long-term effect of the retinal vasculature by two independent neuroprotective drugs, even though the study period might not have been long enough to arrest or prevent development of DR. As indicated by the DCCT in type 1 diabetes, this would likely take at least 3 years, which was the reason that EUROCONDOR was designed to study surrogate markers of early vascular and neurogenic dysfunction.

Retinal vascular calibers have been identified as early biomarkers of retinal structural dysfunction in diabetes.<sup>14,22,23</sup> In a 16-year prospective study of patients with type 1 diabetes, Broe et al.<sup>16</sup> reported that a 10- $\mu\text{m}$  retinal arteriolar narrowing and venular dilation independently predicted long-term proliferative DR, nephropathy, and peripheral neuropathy with odds ratios of 1.4 to 3.0. Likewise, the Wisconsin Epidemiological Study of Diabetic Retinopathy found that a 10  $\mu\text{m}$  retinal venular (but not arteriolar) dilation in 4 years, associated with a higher risk of various DR-endpoints in the following 6 years.<sup>24</sup>

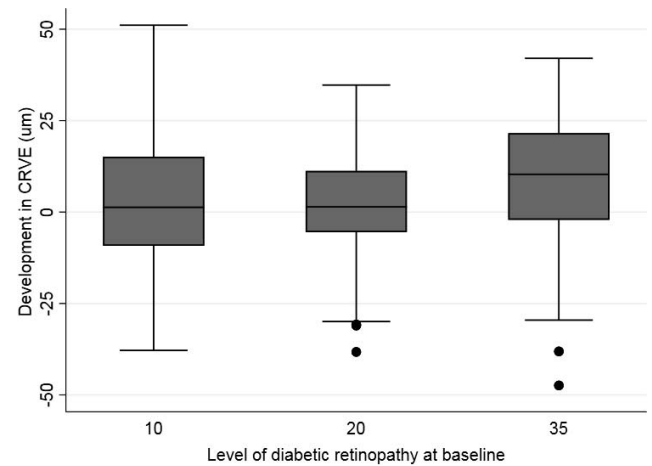


FIGURE 2. Development in CRVE during 96 weeks of topical treatment according to Early Treatment Diabetic Retinopathy Study levels of DR at baseline. There was a higher development with more advanced DR (level 10, +1.3  $\mu\text{m}$ ; level 20, +1.4  $\mu\text{m}$ ; level 35, +10.3  $\mu\text{m}$ ; P = 0.001).

Both of these studies identify retinal vascular dilation as a risk factor of DR-progression, which might seem in opposition with our findings of a retinal vascular dilation in response to neuroprotective treatment. However, comparisons are difficult given that most patients in the studies by Broe et al.<sup>16</sup> and Klein et al.<sup>24</sup> had no or minimal DR, whereas our results were found in patients with preexisting mild DR at baseline. In addition, Broe et al.<sup>16</sup> only evaluated patients with type 1 diabetes as opposed to type 2 diabetes in the EUROCONDOR.

In the EUROCONDOR, we have previously reported that there was no association between baseline levels of DR and CRAE, but patients with moderate NPDR had a higher CRVE (ETDRS 10, 214.5  $\mu\text{m}$ ; ETDRS 20, 213.2  $\mu\text{m}$ ; ETDRS 35, 216.6  $\mu\text{m}$ ;  $P = 0.04$ ) although this could not be considered clinically significant.<sup>18</sup> Noticeably, in the present study only patients with preexisting DR developed arteriolar and venular widening, and we demonstrate that this was influenced by the topically administered agent. This is in alignment with the principal findings of the EUROCONDOR which report that neuroprotective treatment was only effective in patients with preexisting retinal neurodysfunction.<sup>12</sup> In particular, patients with mild NPDR in both neuroprotective groups had a retinal venular dilation of more than three times of that in the placebo group. This effect size is likely to be clinically relevant. To illustrate, the retinal venular dilation induced by topical neuroprotection in our patients with preexisting mild DR (+13.9–14.3  $\mu\text{m}$ ) has the same size as the difference in CRVE between an average 50- and 85-year-old person, in which the former would be 13  $\mu\text{m}$  wider.<sup>25</sup>

There is no clear mechanistic explanation of the topically induced vascular dilation in patients with moderate NPDR, but it could potentially be given by compensatory increased blood flow to prevent peripheral nonperfusion which is strongly associated with DR progression<sup>26</sup> and poor treatment outcome.<sup>27</sup> Another potential explanation was proposed by Ludovico et al.<sup>28</sup> that demonstrated retinal vasodilation in 50% of patients with early diabetes and suggested that a lack of vasodilation could be a harmful response. While hypoxia induces retinal vasodilation in healthy eyes,<sup>29</sup> lack of dilation in diabetes can be caused by basement membrane thickening or pericyte loss, which may lead to capillary dropout and closure.<sup>30</sup> One of the main reasons of the lack of vasodilation in nontreated diabetic eyes can be attributed to the impairment of the neurovascular unit, which prevents vasodilation, thus impeding to adapt to the higher metabolic demands that exist in the diabetic retina. Consequently, the neuroactive drugs used in EUROCONDOR may have a favorable effect by improving the neurovascular unit function. This effect results in vasodilation and, therefore, improved autoregulation and delayed capillary dropout. However, with the data at hand, we cannot conclude if treatment-induced retinal vascular dilation in mild DR is a specific consequence of topical neuroprotection with brimonidine and somatostatin, or if this would also be observed with other interventions.

It can be difficult to compare retinal vascular calibers between studies. For instance, Drobnjak et al.<sup>31</sup> reported median CRAE and CRVE of 163.3 and 251.0  $\mu\text{m}$ , which were substantial higher than the baseline finding of our study (146.6 and 214.8  $\mu\text{m}$ ).<sup>31</sup> Unbalances might be explained by differences in ages, populations, methodology, and by the fact that diabetes was only present in a subset of patients in the study by Drobnjak et al.<sup>31</sup>

Strengths of the present study include the prospective, randomized design and the long follow-up with repeated measurements over time. On the other hand, limitations should be acknowledged. First, we did not include retinal flow measurements which could have provided additional information regarding retinal perfusion. Second, there was a higher

than expected dropout which may limit the generalizability of the results. Third, retinal vascular calibers were measured by different graders at baseline and follow-up.

In conclusion, the present study demonstrated retinal vascular dilation induced by long-term topical neuroprotection in 297 patients with type 2 diabetes and mild DR. The concept that eye drops may induce retinal vascular changes would be appealing in order to prevent or delay DR in the early phases, and upcoming prospective studies would be needed to translate this into clinical care.

### Acknowledgments

Supported by the European Union's Seventh Framework Programme for research, technological development and demonstration under Grant Agreement No. 278040. U. Frydkjaer-Olsen was supported by Fight for Sight Denmark, The Region of Southern Denmark, and University of Southern Denmark.

Disclosure: **J. Grauslund**, None; **U. Frydkjaer-Olsen**, None; **T. Peto**, None; **J. Fernández-Carneado**, BCN Peptides (E); **B. Ponsati**, BCN Peptides (E); **C. Hernández**, None; **J. Cunha-Vaz**, None; **R. Simó**, None

### References

1. Grauslund J, Green A, Sjolie AK. Prevalence and 25 year incidence of proliferative retinopathy among Danish type 1 diabetic patients. *Diabetologia*. 2009;52:1829–1835.
2. Liew G, Michaelides M, Bunce C. A comparison of the causes of blindness certifications in England and Wales in working age adults (16–64 years), 1999–2000 with 2009–2010. *BMJ Open*. 2014;4:e004015.
3. Jonsson KB, Frydkjaer-Olsen U, Grauslund J. Vascular changes and neurodegeneration in the early stages of diabetic retinopathy: which comes first? *Ophthalmic Res*. 2016;56:1–9.
4. Simo R, Hernandez C; European Consortium for the Early Treatment of Diabetic Retinopathy. Neurodegeneration in the diabetic eye: new insights and therapeutic perspectives. *Trends Endocrinol Metab*. 2014;25:23–33.
5. Diabetic Retinopathy Study Research Group. Preliminary report on effects of photocoagulation therapy. *Am J Ophthalmol*. 1976;81:383–396.
6. Early Treatment Diabetic Retinopathy Study Research Group. Photocoagulation for diabetic macular edema. Early Treatment Diabetic Retinopathy Study report number 1. *Arch Ophthalmol*. 1985;103:1796–1806.
7. Wells JA, Glassman AR, Ayala AR, et al. Aflibercept, bevacizumab, or ranibizumab for diabetic macular edema: two-year results from a comparative effectiveness randomized clinical trial. *Ophthalmology*. 2016;123:1351–1359.
8. Hernandez C, Bogdanov P, Corraliza L, et al. Topical administration of GLP-1 receptor agonists prevents retinal neurodegeneration in experimental diabetes. *Diabetes*. 2016; 65:172–187.
9. Hernandez C, Bogdanov P, Sola-Adell C, et al. Topical administration of DPP-IV inhibitors prevents retinal neurodegeneration in experimental diabetes. *Diabetologia*. 2017;60: 2285–2298.
10. Hernandez C, Garcia-Ramirez M, Corraliza L, et al. Topical administration of somatostatin prevents retinal neurodegeneration in experimental diabetes. *Diabetes*. 2013;62:2569–2578.
11. Santos AR, Ribeiro L, Bandello F, et al. Functional and structural findings of neurodegeneration in early stages of diabetic retinopathy: cross-sectional analyses of baseline data of the EUROCONDOR project. *Diabetes*. 2017;66:2503–2510.

12. Simo R, Hernandez C, Porta M, et al. Effects of topically administered neuroprotective drugs in early stages of diabetic retinopathy: results of the EUROCONDOR clinical trial. *Diabetes*. 2019;68:457–463.
13. Diabetes Control and Complications Trial Research Group. The effect of intensive treatment of diabetes on the development and progression of long-term complications in insulin-dependent diabetes mellitus. *New Eng J Med*. 1993; 329:977–986.
14. Grauslund J, Hodgson L, Kawasaki R, Green A, Sjolie AK, Wong TY. Retinal vessel calibre and micro- and macrovascular complications in type 1 diabetes. *Diabetologia*. 2009;52: 2213–2217.
15. Klein R, Klein BE, Moss SE, Wong TY. Retinal vessel caliber and microvascular and macrovascular disease in type 2 diabetes: XXI: the Wisconsin Epidemiologic Study of Diabetic Retinopathy. *Ophthalmology*. 2007;114:1884–1892.
16. Broe R, Rasmussen ML, Frydkjaer-Olsen U, et al. Retinal vessel calibers predict long-term microvascular complications in type 1 diabetes: the Danish Cohort of Pediatric Diabetes 1987 (DCPD1987). *Diabetes*. 2014;63:3906–3914.
17. Early Treatment Diabetic Retinopathy Study Research Group. Grading diabetic retinopathy from stereoscopic color fundus photographs—an extension of the modified Airlie House classification. ETDRS report number 10. *Ophthalmology*. 1991;98:786–806.
18. Frydkjaer-Olsen U, Soegaard Hansen R, Simo R, et al. Correlation between retinal vessel calibre and neurodegeneration in patients with type 2 diabetes mellitus in the European Consortium for the Early Treatment of Diabetic Retinopathy (EUROCONDOR). *Ophthalmic Res*. 2016;56:10–16.
19. Hubbard LD, Brothers RJ, King WN, et al. Methods for evaluation of retinal microvascular abnormalities associated with hypertension/sclerosis in the Atherosclerosis Risk in Communities Study. *Ophthalmology*. 1999;106:2269–2280.
20. Knudtson MD, Lee KE, Hubbard LD, Wong TY, Klein R, Klein BE. Revised formulas for summarizing retinal vessel diameters. *Curr Eye Res*. 2003;27:143–149.
21. Tilma KK, Bek T. Topical treatment for 1 week with latanoprost but not diclofenac reduces the diameter of dilated retinal arterioles in patients with type 1 diabetes mellitus and mild retinopathy. *Acta Ophthalmol*. 2012;90:750–755.
22. Klein R, Klein BE, Moss SE, et al. Retinal vascular abnormalities in persons with type 1 diabetes: the Wisconsin Epidemiologic Study of Diabetic Retinopathy: XVIII. *Ophthalmology*. 2003;110:2118–2125.
23. Cheung N, Rogers SL, Donaghue KC, Jenkins AJ, Tikellis G, Wong TY. Retinal arteriolar dilation predicts retinopathy in adolescents with type 1 diabetes. *Diabetes Care*. 2008;31: 1842–1846.
24. Klein R, Myers CE, Lee KE, Gangnon R, Klein BE. Changes in retinal vessel diameter and incidence and progression of diabetic retinopathy. *Arch Ophthalmol*. 2012;130:749–755.
25. Myers CE, Klein R, Knudtson MD, et al. Determinants of retinal venular diameter: the Beaver Dam Eye Study. *Ophthalmology*. 2012;119:2563–2571.
26. Silva PS, Dela Cruz AJ, Ledesma MG, et al. Diabetic retinopathy severity and peripheral lesions are associated with nonperfusion on ultrawide field angiography. *Ophthalmology*. 2015;122:2465–2472.
27. Torp TL, Kawasaki R, Wong TY, Peto T, Grauslund J. Peripheral capillary non-perfusion in treatment-naive proliferative diabetic retinopathy associates with postoperative disease activity 6 months after panretinal photocoagulation [published online ahead August 1, 2018]. *Br J Ophthalmol*. <https://doi.org/10.1136/bjophthalmol-2018-312195>.
28. Ludovico J, Bernardes R, Pires I, Figueira J, Lobo C, Cunha-Vaz J. Alterations of retinal capillary blood flow in preclinical retinopathy in subjects with type 2 diabetes. *Graefes Arch Clin Exp Ophthalmol*. 2003;241:181–186.
29. Sousa DC, Leal I, Moreira S, Dionisio P, Abegao Pinto L, Marques-Neves C. Hypoxia challenge test and retinal circulation changes - a study using ocular coherence tomography angiography. *Acta Ophthalmol*. 2018;96:e315–e319.
30. Marques IP, Alves D, Santos T, et al. Multimodal imaging of the initial stages of diabetic retinopathy. different disease pathways in different patients. *Diabetes*. 2019–653.
31. Drobnyak D, Munch IC, Glumer C, et al. Retinal vessel diameters and their relationship with cardiovascular risk and all-cause mortality in the Inter99 Eye Study: a 15-year follow-up. *J Ophthalmol*. 2016;2016:6138659.

## APPENDIX

### Members of the EUROCONDOR

Scientific Institute San Raffaele, Milan, Italy: Francesco Bandello.

Association for Innovation and Biomedical Research on Light and Image, Coimbra, Portugal: José Cunha-Vaz.

Moorfields Eye Hospital, London, United Kingdom: Catherine Egan.

Vall d'Hebron University Hospital, Barcelona, Spain: José García-Arumí.

University of Aston, Birmingham, United Kingdom: Jonathan Gibson.

University of Liverpool, Liverpool, United Kingdom: Simon Harding.

International Diabetes Federation Europe, Brussels, Belgium: Sehnaz Karadeniz.

University of Ulm, Ulm, Germany: Gabriele Lang.

Hôpital Lariboisière-APHP, Paris, France: Pascale Massin.

University of Padova, Padova, Italy: Edoardo Midena.

BCN Peptides, Barcelona, Spain: Berta Ponsati.

University of Turin, Turin, Italy: Massimo Porta.

Cheltenham General Hospital, Cheltenham, United Kingdom: Peter Scanlon, Stephen Aldington.

Vall d'Hebron Research Institute, Barcelona, Spain: Rafael Simó, Cristina Hernández.

University of Southern Denmark, Odense, Denmark: Jakob Grauslund, Ulrik Frydkjaer-Olsen.