

Association of Aberrant Posterior Vitreous Detachment and Pathologic Tractional Forces With Myopic Macular Degeneration

Kai Yuan Tey,^{1,2} Qiu Ying Wong,¹ Yee Shan Dan,¹ Andrew S. H. Tsai,³ Daniel S. W. Ting,^{1,3} Marcus Ang,^{1,3} Gemmy Chiu Ming Cheung,^{1,3} Shu Yen Lee,³ Tien Yin Wong,^{1,3} Quan V. Hoang,^{1,3,4} and Chee Wai Wong^{1,3}

¹Singapore Eye Research Institute, Singapore

²Tasmanian School of Medicine, Tasmania, Australia

³Singapore National Eye Centre, Duke-NUS Medical School, Singapore

⁴Department of Ophthalmology, Columbia University College of Physicians and Surgeons, New York, NY, United States

Correspondence: Quan V. Hoang, Singapore Eye Research Institute, Singapore National Eye Centre, Duke-NUS Medical School, 20 College Rd, 169856, Singapore; donny.hoang@singhealth.com.sg.

QVH and KYT contributed equally to this paper.

Received: October 24, 2020

Accepted: December 12, 2020

Published: June 7, 2021

Citation: Tey KY, Wong QY, Dan YS, et al. Association of aberrant posterior vitreous detachment and pathologic tractional forces with myopic macular degeneration. *Invest Ophthalmol Vis Sci.* 2021;62(7):7. <https://doi.org/10.1167/iovs.62.7.7>

PURPOSE. The purpose of this study was to assess whether the tractional elements of pathologic myopia (PM; e.g. myopic traction maculopathy [MTM], posterior staphyloma [PS], and aberrant posterior vitreous detachment [PVD]) are associated with myopic macular degeneration (MMD) independent of age and axial length, among highly myopic (HM) eyes.

METHODS. One hundred twenty-nine individuals with 239 HM eyes from the Myopic and Pathologic Eyes in Singapore (MyoPES) cohort underwent ocular biometry, fundus photography, swept-source optical coherence tomography, and ocular B-scan ultrasound. Images were analyzed for PVD grade, and presence of MTM, PS, and MMD. The χ^2 test was done to determine the difference in prevalence of MMD between eyes with and without PVD, PS, and MTM. Multivariate probit regression analyses were performed to ascertain the relationship between the potential predictors (PVD, PS, and MTM) and outcome variable (MMD), after accounting for possible confounders (e.g. age and axial length). Marginal effects were reported.

RESULTS. Controlling for potential confounders, eyes with MTM have a 29.92 percentage point higher likelihood of having MMD ($P = 0.003$), and eyes with PS have a 25.72 percentage point higher likelihood of having MMD ($P = 0.002$). The likelihood of MMD increases by 10.61 percentage points per 1 mm increase in axial length ($P < 0.001$). Subanalysis revealed that eyes with incomplete PVD have a 22.54 percentage point higher likelihood of having MMD than eyes with early PVD ($P = 0.04$).

CONCLUSIONS. Our study demonstrated an association between tractional (MTM, PS, and persistently incomplete PVD) and degenerative elements of PM independent of age and axial length. These data provide further insights into the pathogenesis of MMD.

Keywords: pathologic myopia, myopic macular degeneration, posterior vitreous detachment, myopic traction maculopathy, posterior staphyloma

Pathologic myopia (PM) is a major cause of blindness among patients with high myopia (HM), presently afflicting 1.7 to 3.1% of East Asians,¹⁻³ and typically affects middle-aged to elderly myopes.⁴ This is particularly worrisome as it is widely accepted that in addition to an epidemic of myopia, there is also an epidemic of HM, particularly in developed countries in East and Southeast Asia.⁵ By 2050, it is estimated that 4.8 billion people will have myopia worldwide, of which almost a billion will have HM.⁶ PM manifests clinically in two distinct forms — tractional and degenerative, namely myopic traction maculopathy (MTM) and myopic macular degeneration (MMD), respectively.⁷ Although prior studies have provided insights into the pathogenesis of both forms of PM independently,^{4,7,8} and the two

forms of PM often occur concurrently, there is a paucity of studies that seek to determine if tractional PM predisposes an eye to degenerative PM.

MTM represents a spectrum of traction-based PM, including separation of the retinal layers known as macular retinoschisis, partial or full-thickness macular hole, and foveal retinal detachment (RD).⁷⁻¹¹ In contrast, MMD represents a spectrum of degenerative-based PM, including choroidal atrophy and myopic choroidal neovascularization (CNV).^{4,9} MTM is known to be strongly associated with persistent vitreous adhesion, vitreomacular traction, and posterior staphyloma (PS),^{8,12-15} whereas for MMD, the pathogenic pathway is less clear, aside from its association with ageing and greater axial length (AL).^{4,7,16,17}



Interestingly, not all highly myopic eyes develop degenerative PM changes, even in the same individual with comparable AL in both eyes.⁴ This observation could be attributed to several factors, many of which are tractional in origin. The presence of PS, which is commonly seen in eyes with PM,⁹ could exert tractional forces on the macula both tangentially and in the anterior-posterior direction. These forces may, over time, contribute to atrophic changes in the retina and choroid resulting in MMD.¹⁵ Additionally, MTM represents the inability of the retina to withstand the various tractional forces,⁸ that if left unresolved, may ultimately lead to atrophy of the retinal tissue. Beyond PS and MTM, the vitreous itself could be a factor, as an attached posterior hyaloid normally serves as a mechanism to buffer and equally distribute forces on the posterior segment.¹⁸ Abnormal vitreous changes, such as premature vitreous liquefaction and aberrant posterior vitreous detachment (PVD), have been well-described in the myopic eye.^{18–20} Specifically, a persistently incomplete PVD (in which there is vitreofoveal separation, but persistent posterior hyaloid attachment at the optic nerve) may very well represent the end-stage of an aberrant or aborted PVD versus a transient state that ends in complete PVD, as often seen in emmetropic eyes.^{21–23}

Thus, with the reasons cited above, we postulate that the tractional elements of PM (persistently incomplete PVD, MTM, and PS) are associated with the degenerative elements of PM (MMD) independent of age and axial length, and evaluate this hypothesis with a cross-sectional study utilizing multimodal imaging in a cohort of highly myopic subjects. Presently, there is no definitive treatment for MMD.²⁴ If tractional elements (which have definitive treatments)²⁴ are shown to contribute to MMD development and progression, early intervention for tractional elements of PM may prevent the onset and progression of MMD.

METHODS

We conducted a cross-sectional analysis of participants recruited from the Myopic and Pathologic Eyes in Singapore (MyoPES) cohort at the Singapore National Eye Centre. In brief, the MyoPES cohort is composed of Singaporean adults aged 21 years or older, with at least one eye with HM, defined as manifest spherical equivalent of ≥ 5.0 diopters (D) of myopia and/or AL ≥ 25.0 mm. All MyoPES cohort subjects underwent a complete eye history and examination, which included: (1) ocular biometry, (2) fundus photography (color and autofluorescence), and (3) swept-source optical coherence tomography (SS-OCT). For the present study, participants were recruited from the MyoPES cohort from November 2017 to the end of September 2018 to undergo additional ocular B-scan ultrasonography, based on a standardized protocol. Participants who had any existing or previous ocular diseases in either eye that could have a potentially confounding effect on measurements from SS-OCT and B-scan ultrasound were excluded from the study. Such conditions included corneal opacities, uveitis, dense cataracts, vitreous hemorrhage, diabetic retinopathy/diabetic macular edema, central serous chorioretinopathy, previous retinal laser photocoagulation or photodynamic therapy, previous and co-existing RD, retinal dystrophies, macular scarring from any cause other than myopic maculopathy, retinopathy due to any cause other than myopia, previous retinal vein or artery occlusion, and ocular ischemic syndrome. This study was performed with approval from the SingHealth Institutional Review Board and in accor-

dance with the Declaration of Helsinki. Written informed consent was obtained from all participants.

Image Acquisition and Assessment

Triton DRI OCT Plus (Topcon Medical Systems, Oakland, NJ, USA) was used to obtain both fundus photos and SS-OCT images. Fundus photographs were obtained after pupillary dilation. Two fields of each eye were photographed, with one centered at the optic disc and another centered at the fovea. For SS-OCT, images of the fovea, optic disc, vitreous, and sclera were obtained. Scans performed included fovea-centered 3D raster (12×9 mm), 3D disc (6×6 mm), and fovea-centered radial (diameter 12 mm) scans. Ocular ultrasound images were acquired on a Quantel Aviso with a 10 MHz probe (Quantel Medical, Rockwall, TX, USA). The ultrasound transducer was gently placed against the closed eyelids. An anterior-posterior scan was initially obtained with the optic nerve within the scan, then the eye was swept horizontally (fovea to nasal until the extraocular muscle insertion was visualized; then fovea to temporal) and vertically (fovea to superior; then fovea to inferior).

To determine the presence of MMD, fundus photographs were reviewed by two retinal specialists (C.W.W. and Q.V.H.), who graded the fundus photographs using the international META-PM classifications and were masked to participant characteristics.⁹ The presence of MMD was defined as META-PM MMD category 2 (diffuse atrophy) or worse, or the presence of plus signs (lacquer cracks, CNV, or Fuchs spots; e.g. Fig. 1). Images of SS-OCT obtained in both 3D raster and radial scans were reviewed on IMAGENet 6 viewing software in the Enhanced Vitreous Visualization mode and graded by a single trained grader (K.Y.T.) for the degree of PVD following the published classifications as detailed in Table 1.²⁵ Briefly, eyes were classified as having either no PVD (grade 0), early PVD (paramacular, grade 1), intermediate PVD (perifoveal, grade 2), incomplete PVD (grade 3 - with vitreofoveal separation, but with persistent attachment at the optic nerve; which would include both persistently incomplete and transiently incomplete PVD), or complete PVD (grade 4). SS-OCT images were graded by two retinal specialists (C.W.W. and Q.V.H.) for the presence of MTM, for which the presence of MTM is defined by the presence of extrafoveal schisis, foveal schisis, or full-thickness macular hole.¹¹ Images from ocular B-scan ultrasound were assessed by a retinal specialist (C.W.W.) and a trained grader (Y.S.D.) for the presence of PS (e.g. Figs. 1B3, 2), based on an abrupt change in radius of curvature of the posterior sclera.²⁶ Ultrasound images were assessed at the time of acquisition and eyes re-imaged if motion artifacts were present.

Outcome Measures and Statistical Analysis

Stata 15 software (StataCorp, College Station, TX, USA) was used for the statistical analysis in this study. Ratios were compared using the χ^2 test. The mean differences in age and AL were analyzed with the independent *t*-test for between-group comparison. These tests were two-sided with statistical significance set at $P < 0.05$.

Univariate probit regressions were performed with the dependent variable set as MMD presence. Independent variables included age, male gender, left eye (versus right), AL (in mm), MTM presence (versus absence), PS presence (versus absence), and PVD status. The association between

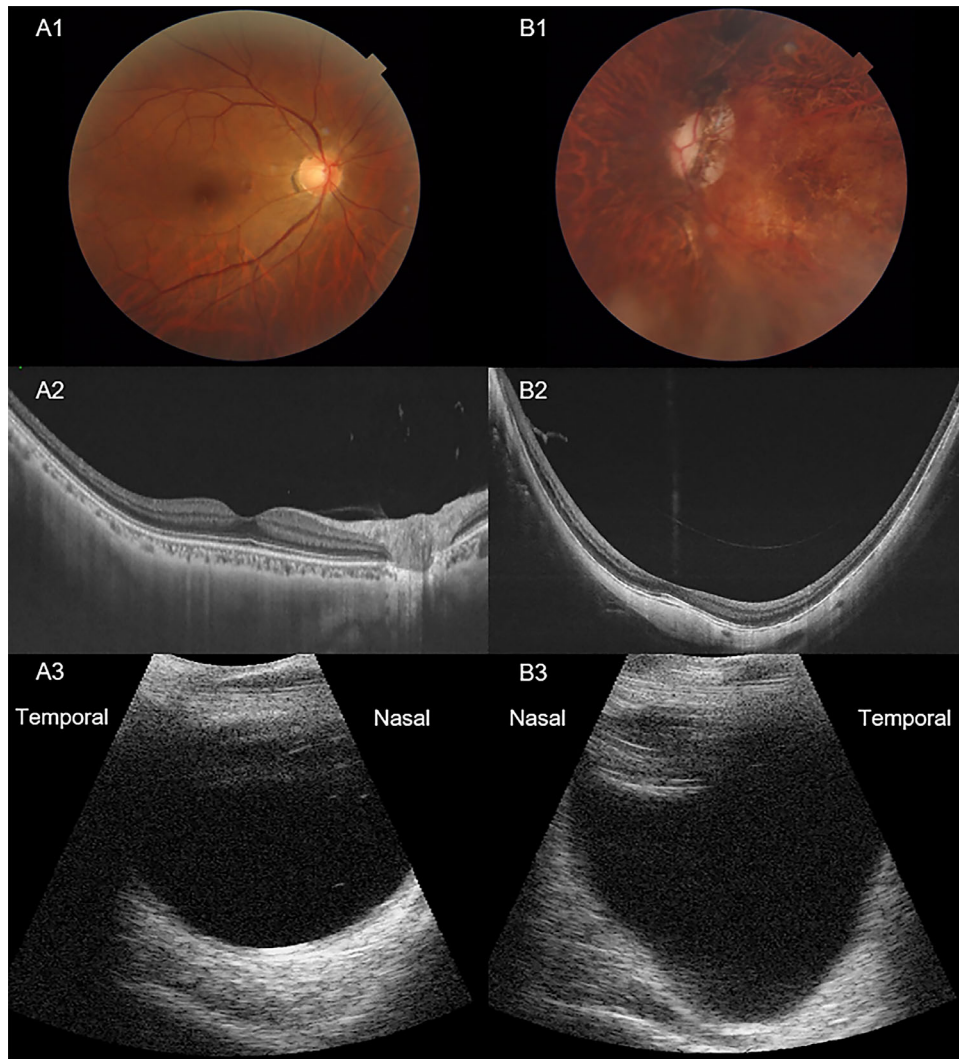


FIGURE 1. Multimodal imaging of highly myopic eyes without (A) and with (B) myopic macular degeneration (MMD) as based on fundus images (Row 1), swept source optical coherence tomography (Row 2) and B-scan ultrasonography (Row 3). The eye in column A shows absence of MMD (META-PM grade 1 – tessellated fundus, A1), early posterior vitreous detachment (paramacular PVD) with no myopic traction maculopathy (MTM, A2) and no posterior staphyloma (PS, A3). In contrast, the eye in column B shows the presence of MMD (META-PM grade 2 – diffuse chorioretinal atrophy, B1), incomplete PVD with vitreofoveal separation but persistent attachment at optic nerve) and MTM (extrafoveal schisis, B2) and PS (B3). META-PM, meta-analysis for pathologic myopia study group.⁹

TABLE 1. Quantitative Grading of Posterior Vitreous Detachment and Distribution

PVD Grade	Description	N (%) (239 Eyes)
0	No PVD	36 (15.1)
1	Early PVD (paramacular)	61 (25.5)
2	Intermediate PVD (perifoveal)	23 (9.6)
3	Incomplete PVD (vitreofoveal separation with persistent optic disc attachment; includes persistently incomplete and transiently incomplete PVD)	23 (9.6)
4	Complete PVD	96 (40.2)

PVD, posterior vitreous detachment.

MMD presence and each independent variable was assessed individually.

For multivariate analysis, a probit regression was performed with the dependent variable set as MMD presence and included independent variables such as age, male

gender, left eye (versus right), AL (in mm), MTM presence (versus absence), PS presence (versus absence), and PVD status. The coefficient estimates are reported as marginal effects that are evaluated for each independent variable with the other predictor variables set at their mean values.

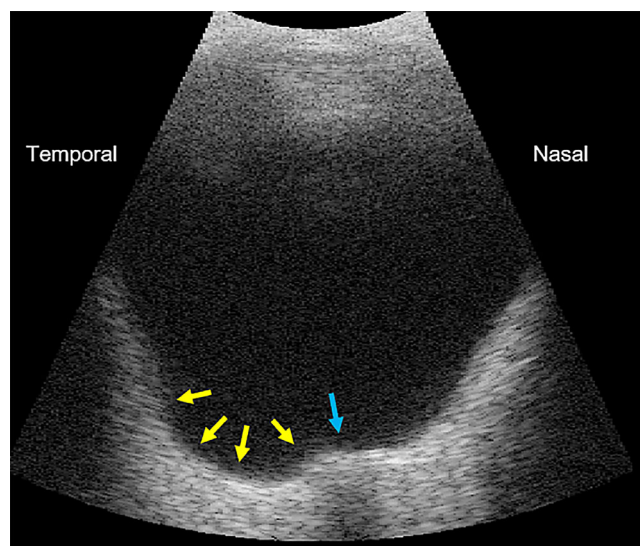


FIGURE 2. Posterior narrow macular (type II) staphyloma (identified by the yellow arrows) located just temporal to the optic nerve head (blue arrow) on a 10 MHz B-scan ultrasound (Aviso, Quantel Medical, Rockwall, TX, USA) obtained in a right eye of a patient with axial length of 32.2 mm.

Standard errors were clustered on the patient level to account for the fact that two measurements (right and left eyes) were taken from the same person, which could create serial correlation in errors across eyes within a person. Statistical significance was set at $P < 0.05$.

RESULTS

Overall, 129 subjects were identified and recruited into the study. Eighty-seven (67.4%) were women, and the mean age was 55.3 ± 11.5 years old (range = 21–70 years old). The overall mean AL was 29.2 ± 2.17 mm (range = 25.0–35.7 mm). Eighteen eyes were excluded from this study as they were not highly myopic. A total of 240 images were obtained, with one image being excluded due to insufficient SS-OCT signal. The breakdown of the PVD grading can be seen in Table 1. Overall, PVD (grades 1 to 4 combined) was found in 203 eyes (84.9%), with incomplete PVD (grade 3) found in 23 eyes (9.6%) based on SS-OCT grading (see Table 1).

There was a total of 27 (75.0%) female eyes in the no-PVD group (grade 0) and 132 (65.0%) female eyes in the PVD group (grades 1 to 4 combined, $P = 0.08$). The mean age of the no-PVD and PVD groups was 52.0 ± 12.6 and 55.6 ± 11.1 years, respectively ($P = 0.02$). On average, eyes in the no-PVD group had shorter AL (28.1 ± 1.6 mm) than eyes in the PVD group (29.5 ± 2.2 mm; $P < 0.001$) as seen in Table 2, top panel.

Clinical characteristics of individual PVD gradings can be seen in Table 2. When comparing specifically the incomplete PVD group (grade 3) versus the early PVD group (grade 1), a total of 18 (78.3%) female eyes were in the incomplete PVD group and 39 (63.9%) in the early PVD group ($P = 0.21$). The mean age of the incomplete PVD and early PVD groups was 56.5 ± 11.6 and 51.6 ± 12.0 years, respectively ($P = 0.09$). On average, eyes in the incomplete PVD group had longer AL (30.3 ± 2.7 mm) than eyes in the early PVD group (29.1 ± 2.2 mm, $P = 0.04$) as seen in Table 2, bottom panel.

Overall, of the 239 eyes assessed for MMD (Fig. 3A), 76 (31.8%) of them were found to have no MMD (grade 0–1 and no plus lesions), 113 (47.3%) with diffuse chorioretinal atrophy (grade 2), 35 (14.6%) with patchy chorioretinal atrophy (grade 3), and 15 (6.3%) had macular atrophy (grade 4). In terms of plus lesions, myopic choroidal neovascularization (mCNV) was present in 10 (4.2%) eyes, lacquer cracks were found in 10 (4.2%) eyes, and Fuchs’ spot was found in 15 (6.3%) eyes

Prevalence of Myopic Macular Degeneration in Eyes With and Without Posterior Staphyloma, Incomplete PVD, and Myopic Traction Maculopathy

A total of 239 ocular B-scan ultrasounds were obtained and assessed for the presence of PS by two independent graders (Y.S.D. and C.W.W.), with an excellent interrater agreement ($\kappa = 0.93$). Overall, of 239 eyes with graded ultrasound images, 163 (68.2%) eyes had MMD on fundus photographs, whereas 76 (31.8%) did not. The prevalence of MMD was significantly higher in eyes with PS (126 out of 145, 86.9%) than eyes without PS (37 out of 94 eyes, 39.4%, $P < 0.001$), as seen in Figure 3A.

The prevalence of MMD was significantly higher in the incomplete PVD (grade 3) group (20 out of 23 eyes, 87.0%) when compared to the combined prevalence in the other PVD grades (143 out of 216 eyes, 66.2%, $P = 0.04$;

TABLE 2. Comparison of Eyes in PVD and No-PVD groups (Top Panel) and Among the PVD Gradings (Bottom Panel)

	PVD (n = 203)	No-PVD (n = 36)	P Value	
Females, n (%)	132 (65.0)	27 (75.0)	0.08	
Mean age, y	55.6 ± 11.1	52.0 ± 12.6	0.02*	
Mean axial length (AL), mm	29.5 ± 2.2	28.1 ± 1.6	< 0.001*	
Myopic macular degeneration (MMD), n (%)	144 (70.9)	19 (52.8)	0.03*	
	Early PVD (n = 61)	Intermediate PVD (n = 23)	Incomplete PVD (n = 23)	Complete PVD (n = 96)
Females, n (%)	39 (63.9)	16 (69.6)	18 (78.3)	59 (61.5)
Mean age, y	51.6 ± 12.0	56 ± 10.9	56.5 ± 11.6	57.8 ± 9.9
Mean AL, mm	29.1 ± 2.2	30.1 ± 2.2	30.3 ± 2.7	29.3 ± 2.0
MMD, n (%)	35 (57.4)	19 (82.6)	20 (87.0)	70 (72.9)

No-PVD implies grade 0 in Table 1. PVD group implies grades 1 to 4 combined. Early PVD, intermediate PVD, incomplete PVD and complete PVD implies grades 1, 2, 3 and 4 in Table 1, respectively. Bold font and asterisk denote statistical significance at $P < 0.05$. mm, millimeters; PVD, posterior vitreous detachment.

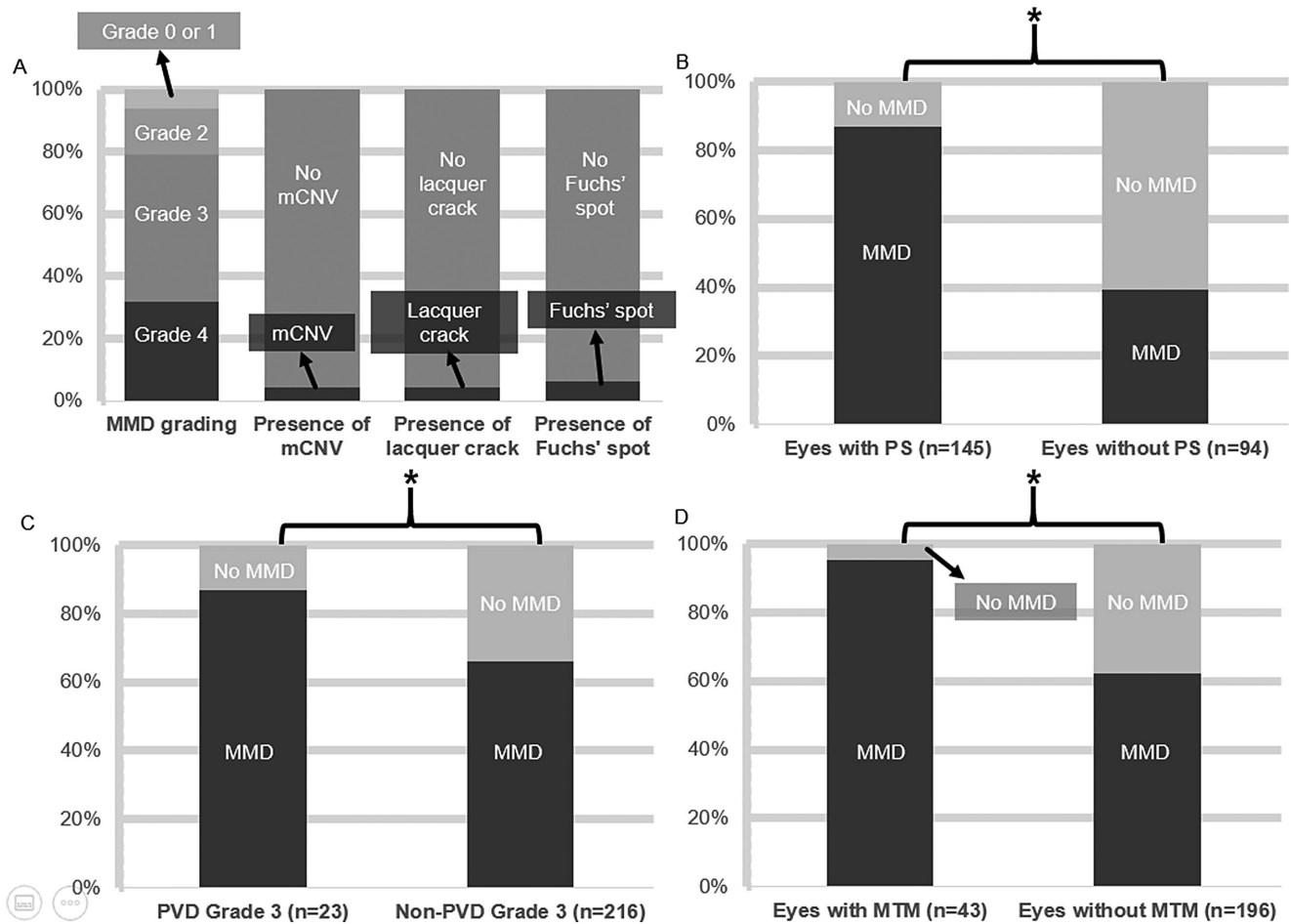


FIGURE 3. Breakdown of META-PM MMD gradings and plus signs amongst highly myopic eyes (A), and prevalence of MMD in eyes with and without (B) PS, (C) incomplete PVD (Grade 3) and (D) MTM, by percentage. mCNV, myopic choroidal neovascularization; MMD, myopic macular degeneration; PVD, posterior vitreous detachment; PS, posterior staphyloma; MTM, myopic traction maculopathy. Asterisk denotes statistical significance at $P < 0.05$.

see Fig. 3B). The prevalence of MMD in eyes with MTM (41 out of 43 eyes, 95.3%) was significantly higher than eyes without MTM (122 out of 196 eyes, 62.2%, $P < 0.001$; see Fig. 3C).

Prevalence of Tractional Elements in Highly Myopic Eyes

Overall, 161 (67.4%) of the HM eyes demonstrated at least one form of tractional elements (incomplete PVD, MTM, or PS), 42 (17.6%) demonstrated at least 2 forms of tractional elements, and 8 (3.3%) of the eyes demonstrated all 3 forms. Thirty-five (14.6%) of the HM eyes demonstrated co-existing MTM and PS, 8 (3.3%) HM eyes demonstrated co-existing MTM and incomplete PVD, and 15 (6.3%) HM eyes demonstrated coexisting incomplete PVD and PS.

Relationship of Posterior Vitreous Detachment, Posterior Staphyloma, Myopic Traction Maculopathy, and Myopic Macular Degeneration

In the univariate analysis (Table 3), the likelihood of an eye having MMD increases by 1.19 percentage points

per 1-year increase in age and 14.37 percentage points per 1 mm increase in AL ($P = 0.001$ and $P < 0.001$, respectively). The likelihood of an eye having MMD is 17.47 percentage points lower in men than women ($P = 0.03$) and does not differ between left and right eyes ($P = 0.12$). The likelihood of an eye having MMD is 46.70 percentage points higher in eyes with MTM than in eyes without, 47.07 percentage points higher in eyes with PS than eyes without, and 33.94 percentage points higher in eyes with PVD grade 3 than in eyes with PVD grade 1 ($P < 0.001$, $P < 0.001$, and $P = 0.01$, respectively).

In terms of multivariate analysis (Table 4), age, gender, and laterality were found to have no significant effect on the presence of MMD ($P = 0.15$, $P = 0.15$, and $P = 0.78$, respectively), whereas the likelihood of an eye having MMD increases by 10.61 percentage points per 1 mm increase in AL ($P < 0.001$). Controlling for potential confounders (e.g. age, AL, gender, and laterality), eyes with MTM have a 29.92 percentage point higher likelihood of having MMD than eyes without ($P = 0.003$), and eyes with PS have a 25.72 percentage point higher likelihood of having MMD than eyes without ($P = 0.002$). When including data from all five grades of PVD, after controlling for potential confounders, the grade of PVD was not predictive of the presence of MMD. These

TABLE 3. Association Between Possible Confounders and the Presence of Myopic Macular Degeneration (Univariate Analysis)

Variable	dy/dx	95% CI	P Value
Age	1.19	0.48 to 1.91	0.001*
Male gender	-17.47	-33.51 to -1.43	0.033*
Left eye	-5.29	-11.87 to 1.29	0.115
Axial length, mm	14.37	10.20 to 18.53	<0.001*
MTM presence	46.70	24.93 to 68.47	<0.001*
PS presence	47.07	32.92 to 61.23	<0.001*
PVD, 5 gradings	5.26	1.10 to 9.43	0.013*
PVD grade 3 vs. 1	33.94	7.32 to 60.55	0.012*
PVD grade 4 vs. 0, 1, 2, 3	7.98	-4.45 to 20.41	0.208
PVD grade 1, 2, 3 vs. 0, 4	1.74	-10.81 to 14.29	0.786

A series of univariate probit regressions were performed with the dependent variable set as MMD presence. Independent variables included: age, male gender, left eye (versus right), axial length (in mm), MTM presence (versus absence), staphyloma presence (versus absence) and PVD status (either as an ordinal variable with 5 levels or as a binary variable comparing grade 3 (persistently incomplete PVD) to grade 1 (early PVD), grade 4 (complete PVD) with grades 0 to 3 combined, or tractional PVD (grades 1 to 3 combined) with non-tractional PVD grades 0 and 4 combined). The association between MMD presence and each independent variable was assessed individually. The coefficient estimates are reported as marginal effects. Bold font and asterisk denote statistical significance at $P < 0.05$. CI, confidence interval; dy/dx, change in likelihood of MMD presence per unit change in predictor variable (in percentage points); mm, millimeters; MMD, myopic macular degeneration; MTM, myopic traction maculopathy; PS, posterior staphyloma; PVD, posterior vitreous detachment.

TABLE 4. Adjusted Association between Possible Confounders and the Presence of Myopic Macular Degeneration (Multivariate Regression Analysis)

Variable	dy/dx	95% CI	P Value
Age	0.56	-0.20 to 1.32	0.146
Male gender	-11.59	-27.49 to 4.32	0.153
Left eye	1.03	-6.29 to 8.35	0.782
Axial length, mm	10.61	7.00 to 14.23	<0.001*
MTM presence	29.92	10.45 to 49.39	0.003*
PS presence	25.72	9.82 to 41.61	0.002*
PVD, 5 gradings	0.87	-2.91 to 4.64	0.653

A multivariate probit regression was performed with myopic macular degeneration as the outcome variable (either as a binary outcome- top panel (no = MMD category 0 or 1 vs. yes = MMD category 2 or above). The coefficient estimates are reported as marginal effects that are evaluated for each independent variable with the other predictor variables set at their means values. Bold font and asterisks denote statistical significance at $P < 0.05$. CI, confidence interval; dy/dx, change in likelihood of MMD presence per unit change in predictor variable (in percentage points); mm, millimeters; MMD, myopic macular degeneration; MTM, myopic traction maculopathy; PS, posterior staphyloma; PVD, posterior vitreous detachment.

effects were evaluated with the other predictor variables at their mean values.

For our multivariate subgroup analysis on the relationship between PVD and MMD (Table 5), after controlling for confounders (e.g. AL, MTM presence, PS presence, age, gender, and laterality), eyes with incomplete PVD (grade 3) have a 22.54 percentage point higher likelihood of having MMD than eyes with early PVD (grade 1, $P = 0.04$). This effect was evaluated with the other predictor variables at their mean values. We chose to focus on the incomplete PVD group (grade 3, vitreofoveal PVD with persistent optic nerve attachment), as this would include many cases of aberrant,

TABLE 5. Adjusted Association Between Possible Confounders and the Presence of Myopic Macular Degeneration in Subanalysis Comparing Eyes With Incomplete PVD Versus Early PVD (Multivariate Regression Analysis)

Variable	dy/dx	95% CI	P Value
Age	-0.34	-1.14 to 0.46	0.407
Male gender	3.47	-15.94 to 22.89	0.726
Left eye	9.82	-7.29 to 26.93	0.261
Axial length, mm	13.91	7.28 to 20.55	<0.001*
MTM presence	22.44	-6.90 to 51.78	0.134
PS presence	24.05	0.57 to 47.54	0.045*
PVD grade 3 vs. 1	22.54	0.66 to 44.41	0.044*

A subanalysis was performed, comparing only eyes with PVD grade 3 (persistently incomplete PVD with vitreofoveal separation) and PVD grade 1 (early paramacular PVD). A multivariate probit regression was performed with myopic macular degeneration as the outcome variable (either as a binary outcome - top panel (no = MMD category 0 or 1 vs. yes = MMD category 2 or above). The coefficient estimates are reported as marginal effects that are evaluated for each independent variable with the other predictor variables set at their means values. Bold font and asterisks denote statistical significance at $P < 0.05$. CI, confidence interval; dy/dx, change in likelihood of MMD presence per unit change in predictor variable (in percentage points); mm, millimeters; MMD, myopic macular degeneration; MTM, myopic traction maculopathy; PS, posterior staphyloma; PVD, posterior vitreous detachment.

arrested, or failed PVD (“persistently incomplete PVD”) in addition to cases successfully transitioning toward complete PVD (“transiently incomplete PVD”). The rationale behind using early PVD (grade 1) as the comparator group is based on the fact that early PVD (grade 1) eyes would have definitively started the PVD process, but were still in its early stage versus the no-PVD group eyes, which could include eyes on the brink of progressing to grade 1 and stable eyes that are many years from progression.

DISCUSSION

In this study, we have attempted to investigate the relationship between the two broad clinical manifestations of PM: the tractional elements (MTM, PS, and persistently incomplete PVD) and the degenerative element (MMD). We observed a relationship between anterior-posterior traction and the presence of MMD. Overall, the prevalence of PVD (grades 1 to 4 combined) in highly myopic eyes is 84.9%, which is comparable to other studies.^{20,21,27} We noted that highly myopic eyes with incomplete PVD (grade 3) were more likely to have MMD. Similarly, MMD was significantly more prevalent in eyes with PS and MTM. Multivariate analysis has shown that eyes with either MTM or PS have a higher likelihood of having MMD independently. Interestingly, in our subanalysis, when comparing PVD grades 3 and 1, it was found that eyes with PVD grade 3 are more likely to have MMD independently.

Posterior Vitreous Detachment and Degenerative Changes

Our primary goal of the study is to assess whether the tractional elements of PM were associated with the degenerative changes in PM, in the hopes of elucidating the pathogenesis of the degenerative changes in PM. Specifically, we hypothesized that abnormal vitreous degeneration could expose highly myopic eyes to asymmetrical distending forces result-

ing in axial lengthening, scleral thinning, and degenerative PM changes. This theory is based on an understanding of two distinct differences between non-myopic and myopic eyes. Firstly, normal age-related changes of the vitreous (liquefaction) and at the vitreoretinal interface (weakening of vitreoretinal adhesion) occur concurrently in nonmyopic eyes. However, these normal processes do not typically occur in tandem in myopic eyes because liquefaction is accelerated and the vitreous destabilizes before vitreous adhesion to the retina is weakened, thus exposing the vitreoretinal interface to geographically differential distension and tractional forces.²⁸ Second, the posterior sclera is known to be less rigid in high myopes and is more susceptible to elongation with deforming forces.²⁹ Further evidence that points to the role of the vitreous in axial elongation can be gleaned from studies that show significantly greater AL change in myopes compared to non-myopes after vitrectomy.^{30,31}

Advancement in imaging technology allows better visualization of PVD, better understanding of how PVD in high myopes differs from non-high myopes, and better understanding of the potential relationship between aberrant PVD and the manifestations of PM.^{21,32,33} When compared to eyes without PVD, we found that eyes with PVD had longer AL, and a higher prevalence of MMD. The overall status of the posterior vitreous itself was not related to the presence of MMD after adjusting for AL and age. However, our subanalysis comparing presumed persistently incomplete PVD (in which the PVD process was arrested at a stage in the presence of vitreofoveal PVD, without separation of the posterior hyaloid from the optic nerve) versus early (paramacular) PVD after accounting for potential confounders (e.g. age, gender, laterality, AL, PS presence, and MTM presence), found that eyes with the presumed persistently incomplete PVD had a higher likelihood of having MMD. Spaide has suggested that the vitreous helps to buffer the tensile and shearing forces generated from ocular movements, which normally aids in reducing the impact on critical structures, including the macula and peripheral retina.³⁴ Anomalous degeneration of the vitreous buffer in high myopes could, therefore, lead to greater mechanical stress on the posterior pole and the sclera, leading to the development of MMD. Incomplete PVD has been noted to exert an anterior-posterior traction on the macula.³⁵ Although the incomplete PVD group of eyes may have included eyes that would eventually succeed in transitioning to complete PVD (transiently incomplete PVD), it likely contained a large number of eyes arrested at this stage of aberrant, incomplete PVD (persistently incomplete PVD). If the eyes in the incomplete PVD group truly represent eyes arrested at this stage long term, this would support the theory that aberrant PVD results in sustained traction at the vitreoretinal interface, which could potentially accelerate the degenerative process we observed in the eyes, leading to a higher prevalence of MMD.

Posterior Staphyloma, Tractional, and Degenerative Changes

Numerous studies have reported the prevalence of PS in highly myopic eyes,^{2,36-43} but there is a relative paucity of research on the prevalence of PS in eyes with MMD. Our study has found that MMD was more commonly seen in eyes with PS compared to eyes without PS. Furthermore, in addition to well-established risk factors of MMD (e.g. age and AL),^{16,44,45} we found that eyes with PS have a 25.72 percent

age point higher likelihood of having MMD than eyes without, after accounting for confounders, such as age and AL. We infer from these findings that age and AL alone are not the sole contributors to the risk or severity of MMD. Both Hsiang et al. and Saka et al. have observed that the presence of PS exposes the thin and fragile posterior scleral wall to mechanical factors (e.g. intraocular pressure), which may lead to degenerative retinal changes.^{40,46} Posterior hyaloid changes might play a role in the pathologic changes of PM as the posterior tensile strength and support of the sclera could be weakened, causing the retinal and choroidal layers to be more susceptible to anterior sources of mechanical stress, and leading to the development and acceleration of the degenerative changes seen in MMD. Future longitudinal studies are needed to elucidate the role of posterior hyaloid changes and their impact on the pathogenesis of MMD.

We identified MTM as a possible independent risk factor for the presence of MMD. This is coherent with the findings of Panozzo et al. who have drawn a possible link between MMD and MTM, with 46.4% of eyes in which degenerative changes were observed, found to also have concurrent MTM on OCT.¹⁰ These findings were corroborated by Xia et al. who observed that eyes with MTM were more likely to have severe MMD.⁴⁷ Multiple studies have noted the association of anterior-posterior traction with the presence of MTM.⁴⁸⁻⁵⁰ We therefore postulate that the presence of MTM exerts mechanical stretch on the retinal layers, which, over time, may ultimately lead to the degenerative changes seen in MMD. It would be interesting to determine which specific category of MMD is driving the association of tractional elements with presence of MMD (categories 2, 3, and 4, or plus lesions), through larger scale studies in the future.

Piecing the three factors (persistently incomplete PVD, PS, and MTM) together, the development and progression of MMD may not only be influenced by age and AL but could also be related to anterior-posterior traction and/or the abnormal degeneration of the vitreous, particularly in cases where these expose the vitreoretinal interface to geographically differential distension. These findings may have implications on potential new therapies for MMD. At the moment, there have been several interventions proposed for MMD (e.g. retina prostheses, intraocular telescopes, and stem cell therapy), however, definitive treatments remain elusive.²⁴ Although existing strategies primarily revolve around preventing or retarding the onset and progression of myopia, there are also effective interventions for PS (macular buckling) and MTM (pars plana vitrectomy).^{24,51,52} Treatment for PS and MTM are generally reserved for later stages where there is a foveal detachment or full-thickness macular hole necessitating urgent intervention to avoid permanent vision loss.^{53,54} By establishing a possible association between PS/MTM and MMD, this may imply that early detection and early treatment of PS/MTM, prior to the current late-stage indications, may potentially prevent MMD development or progression. Although uncomplicated PVD by itself does not warrant treatment, the presence of a chronic persistently incomplete PVD could indicate the presence of an aberrant PVD. Aberrant PVD may prove to be a readily assessable imaging biomarker for future MMD progression and warrant closer follow-up. If this potential biomarker and its association with MMD progression is substantiated with larger and longer-term studies, this may necessitate interventions to proactively treat aberrant PVD (either enzymatically

or surgically), after taking into consideration the risk and benefits of such interventions.

There are several limitations to this study. First, this is a cross-sectional study, as such, our study can only assess for associations, but cannot attribute causality. Second, participants in our study are highly myopic patients recruited from a tertiary referral center. The results, therefore, may not be generalizable to the entire population of highly myopic individuals. Third, the number of eyes with MMD is comparatively smaller than the number of eyes without MMD. A greater number of eyes with MMD is therefore required to allow us to have greater statistical power to detect difference between both groups more accurately. However, the sample sizes used in the present work was sufficient to find significant differences for many of the variables in our regression analyses. Last, we cannot confirm if the PVD grade 3 group in the present study was composed predominantly of persistently incomplete PVD versus transiently incomplete PVD, which can only be determined with longitudinal follow-up.

In conclusion, our study demonstrated a close interconnection between the tractional elements of PM (MTM, PS, and persistently incomplete PVD) and the degenerative elements of PM (MMD). These data provide further insights into the pathogenesis of PM, MTM, and MMD in highly myopic eyes.

Acknowledgments

Supported in part by the SingHealth-Duke-NUS Eye Academic Clinical Programme Nurturing Clinician Scientist Scheme (NCSS/R1364/50/2016, CWW, Singapore), National Eye Institute/NIH K08 Grant (K08 EY023595, QVH, USA) and the National Medical Research Council (grant CSA/MOH-000151/2019, QVH, Singapore). The funding organizations had no role in the design or conduct of this research.

Disclosure: **K.Y. Tey**, None; **Q.Y. Wong**, None; **Y.S. Dan**, None; **A.S.H. Tsai**, None; **D.S.W. Ting**, None; **M. Ang**, None; **G.C.M. Cheung**, None; **S.Y. Lee**, None; **T.Y. Wong**, None; **Q.V. Hoang**, None; **C.W. Wong**, None

References

- Wong TY, Ferreira A, Hughes R, Carter G, Mitchell P. Epidemiology and disease burden of pathologic myopia and myopic choroidal neovascularization: an evidence-based systematic review. *Am J Ophthalmol*. 2014;157(1):9–25.e12.
- Hayashi K, Ohno-Matsui K, Shimada N, et al. Long-term pattern of progression of myopic maculopathy: a natural history study. *Ophthalmology*. 2010;117(8):1595–1611.e1594.
- Liu HH, Xu L, Wang YX, Wang S, You QS, Jonas JB. Prevalence and progression of myopic retinopathy in Chinese adults: the Beijing Eye Study. *Ophthalmology*. 2010;117(9):1763–1768.
- Samarawickrama C, Mitchell P, Tong L, et al. Myopia-related optic disc and retinal changes in adolescent children from Singapore. *Ophthalmology*. 2011;118(10):2050–2057.
- Dolgin E. The myopia boom: short-sightedness is reaching epidemic proportions. some scientists think they have found a reason why. *Nature*. 2015;519:276–278.
- Holden BA, Fricke TR, Wilson DA, et al. Global prevalence of myopia and high myopia and temporal trends from 2000 through 2050. *Ophthalmology*. 2016;123(5):1036–1042.
- Chang L, Pan CW, Ohno-Matsui K, et al. Myopia-related fundus changes in Singapore adults with high myopia. *Am J Ophthalmol*. 2013;155(6):991–999.e991.
- Shimada N, Tanaka Y, Tokoro T, Ohno-Matsui K. Natural course of myopic traction maculopathy and factors associated with progression or resolution. *Am J Ophthalmol*. 2013;156(5):948–957.e941.
- Ohno-Matsui K, Kawasaki R, Jonas JB, et al. International photographic classification and grading system for myopic maculopathy. *Am J Ophthalmol*. 2015;159(5):877–883.e877.
- Panozzo G, Mercanti A. Optical coherence tomography findings in myopic traction maculopathy. *Arch Ophthalmol*. 2004;122(10):1455–1460.
- Shimada N, Ohno-Matsui K, Baba T, Futagami S, Tokoro T, Mochizuki M. Natural course of macular retinoschisis in highly myopic eyes without macular hole or retinal detachment. *Am J Ophthalmol*. 2006;142(3):497–500.
- Sepúlveda G, Chang S, Freund KB, Park S, Hoang QV. Late recurrence of myopic foveoschisis after successful repair with primary vitrectomy and incomplete membrane peeling. *Retina*. 2014;34(9):1841–1847.
- Hoang QV, Chen CL, Garcia-Arumi J, Sherwood PR, Chang S. Radius of curvature changes in spontaneous improvement of foveoschisis in highly myopic eyes. *Br J Ophthalmol*. 2016;100(2):222–226.
- Matsumura S, Sabanayagam C, Wong CW, et al. Characteristics of myopic traction maculopathy in myopic Singaporean adults [published online ahead of print May 23, 2020]. *Br J Ophthalmol*, <https://doi.org/bjophthalmol-2020-316182>.
- Zheng F, Wong C-W, Sabanayagam C, et al. Prevalence, risk factors and impact of posterior staphyloma diagnosed from wide-field optical coherence tomography in Singapore adults with high myopia [published online ahead of print June 29, 2020]. *Acta Ophthalmol*, <https://doi.org/10.1111/aos.14527>.
- Wong YL, Sabanayagam C, Ding Y, et al. Prevalence, risk factors, and impact of myopic macular degeneration on visual impairment and functioning among adults in Singapore. *Invest Ophthalmol Vis Sci*. 2018;59(11):4603–4613.
- Wong Y-L, Sabanayagam C, Wong C-W, et al. Six-year changes in myopic macular degeneration in adults of the Singapore Epidemiology of Eye Diseases Study. *Invest Ophthalmol Vis Sci*. 2020;61(4):14.
- Sebag J. *The vitreous: structure, function, and pathobiology*. New York, NY: Springer Science & Business Media; 2012.
- Sanna G, Nervi I. [Statistical research on vitreal changes in relation to age and refraction defects]. *Ann Ottalmol Clin Ocul*. 1965;91(5):322–335.
- Akiba J. Prevalence of posterior vitreous detachment in high myopia. *Ophthalmology*. 1993;100(9):1384–1388.
- Itakura H, Kishi S, Li D, Nitta K, Akiyama H. Vitreous changes in high myopia observed by swept-source optical coherence tomography. *Invest Ophthalmol Vis Sci*. 2014;55(3):1447–1452.
- Uchino E, Uemura A, Ohba N. Initial stages of posterior vitreous detachment in healthy eyes of older persons evaluated by optical coherence tomography. *Arch Ophthalmol*. 2001;119(10):1475–1479.
- Carrero JL. Incomplete posterior vitreous detachment: prevalence and clinical relevance. *Am J Ophthalmol*. 2012;153(3):497–503.
- Saw SM, Matsumura S, Hoang QV. Prevention and management of myopia and myopic pathology. *Invest Ophthalmol Vis Sci*. 2019;60(2):488–499.
- Hayashi K, Sato T, Manabe SI, Hirata A. Sex-related differences in the progression of posterior vitreous detachment with age. *Ophthalmol Retina*. 2019;3(3):237–243.
- Spaide RF. Staphyloma: Part 1. In: Spaide RF, Ohno-Matsui K, Yannuzzi LA, eds. *Pathologic Myopia*. New York, NY: Springer; 2014:167–176.

27. Morita H, Funata M, Tokoro T. A clinical study of the development of posterior vitreous detachment in high myopia. *Retina*. 1995;15(2):117–124.
28. Semeraro F, Morescalchi F, Russo A, Romano MR, Costagliola C. Tamponade or filling effect: changes of forces in myopic eyes. *Biomed Res Int*. 2014;2014:618382.
29. Sergienko NM, Shargorogska I. The scleral rigidity of eyes with different refractions. *Graefes Arch Clin Exp Ophthalmol*. 2012;250(7):1009–1012.
30. Jee D, Park Y-R, Jung KI, Kim E, La TY. Refractive errors in high myopic eyes after phacovitrectomy for macular hole. *Int J Ophthalmol*. 2015;8(2):369–373.
31. Hamoudi H, La Cour M. Refractive changes after vitrectomy and phacovitrectomy for macular hole and epiretinal membrane. *J Cataract Refract Surg*. 2013;39(6):942–947.
32. Ang M, Wong CW, Hoang QV, et al. Imaging in myopia: potential biomarkers, current challenges and future developments. *Br J Ophthalmol*. 2019;103(6):855–862.
33. Hwang ES, Kraker JA, Griffin KJ, Sebag J, Weinberg DV, Kim JE. Accuracy of spectral-domain OCT of the macula for detection of complete posterior vitreous detachment. *Ophthalmol Retina*. 2020;4(2):148–153.
34. Spaide RF. Visualization of the posterior vitreous with dynamic focusing and windowed averaging swept source optical coherence tomography. *Am J Ophthalmol*. 2014;158(6):1267–1274.
35. Weinand F, Jung A, Becker R, Pavlovic S. [Spontaneous resolution of vitreomacular traction syndrome]. *Ophthalmologe*. 2009;106(1):44–46.
36. Koh V, Tan C, Tan PT, et al. Myopic maculopathy and optic disc changes in highly myopic young Asian eyes and impact on visual acuity. *Am J Ophthalmol*. 2016;164:69–79.
37. Henaine-Berra A, Zand-Hadas IM, Fromow-Guerra J, García-Aguirre G. Prevalence of macular anatomic abnormalities in high myopia. *Ophthalmic Surg Lasers Imaging Retina*. 2013;44(2):140–144.
38. Grossniklaus HE, Green WR. Pathologic findings in pathologic myopia. *Retina*. 1992;12(2):127–133.
39. Ohno-Matsui K. Proposed classification of posterior staphylomas based on analyses of eye shape by three-dimensional magnetic resonance imaging and wide-field fundus imaging. *Ophthalmology*. 2014;121(9):1798–1809.
40. Hsiang HW, Ohno-Matsui K, Shimada N, et al. Clinical characteristics of posterior staphyloma in eyes with pathologic myopia. *Am J Ophthalmol*. 2008;146(1):102–110.
41. Moriyama M, Ohno-Matsui K, Futagami S, et al. Morphology and long-term changes of choroidal vascular structure in highly myopic eyes with and without posterior staphyloma. *Ophthalmology*. 2007;114(9):1755–1762.
42. Baba T, Ohno-Matsui K, Futagami S, et al. Prevalence and characteristics of foveal retinal detachment without macular hole in high myopia. *Am J Ophthalmol*. 2003;135(3):338–342.
43. Numa S, Yamashiro K, Wakazono T, et al. Prevalence of posterior staphyloma and factors associated with its shape in the Japanese population. *Scientific Reports*. 2018;8(1):4594.
44. Williams K, Hammond C. High myopia and its risks. *Community Eye Health*. 2019;32(105):5–6.
45. Hashimoto S, Yasuda M, Fujiwara K, et al. Association between axial length and myopic maculopathy: the Hisayama Study. *Ophthalmol Retina*. 2019;3(10):867–873.
46. Saka N, Ohno-Matsui K, Shimada N, et al. Long-term changes in axial length in adult eyes with pathologic myopia. *Am J Ophthalmol*. 2010;150(4):562–568.e561.
47. Xia H-J, Wang W-J, Chen FE, et al. Long-term follow-up of the fellow eye in patients undergoing surgery on one eye for treating myopic traction maculopathy. *J Ophthalmol*. 2016;2016:2989086.
48. Alkabes M, Padilla L, Salinas C, et al. Assessment of OCT measurements as prognostic factors in myopic macular hole surgery without foveoschisis. *Graefes Arch Clin Exp Ophthalmol*. 2013;251(11):2521–2527.
49. Gaucher D, Haouchine B, Tadayoni R, et al. Long-term follow-up of high myopic foveoschisis: natural course and surgical outcome. *Am J Ophthalmol*. 2007;143(3):455–462.
50. Sun CB, Liu Z, Xue AQ, Yao K. Natural evolution from macular retinoschisis to full-thickness macular hole in highly myopic eyes. *Eye (Lond)*. 2010;24(12):1787–1791.
51. Li X-J, Yang X-P, Li Q-M, et al. Posterior scleral reinforcement for the treatment of pathological myopia. *Int J Ophthalmol*. 2016;9(4):580–584.
52. Huang W, Duan A, Qi Y. Posterior scleral reinforcement to prevent progression of high myopia. *Asia Pac J Ophthalmol (Phila)*. 2019;8(5):366–370.
53. Gómez-Resca M, Burés-Jelstrup A, Mateo C. Myopic traction maculopathy. *Dev Ophthalmol*. 2014;54:204–212.
54. Gohil R, Sivaprasad S, Han LT, Mathew R, Kioussis G, Yang Y. Myopic foveoschisis: a clinical review. *Eye (Lond)*. 2015;29(5):593–601.