

The Association Between Acquired Color Deficiency and PET Imaging of Neurodegeneration in Mild Cognitive Impairment and Alzheimer Disease

Kallene Summer Moreira Vidal,^{1,2,9} Diego Decleva,¹ Mirella Telles Salgueiro Barboni,^{1,3} Balázs Vince Nagy,⁴ Paulo Augusto Hidalgo de Menezes,² Avinash Aher,⁵ Artur Martins Coutinho,^{6,7} Paula Squarzoni,^{6,8} Daniele de Paula Faria,⁷ Fabio Luis de Souza Duran,^{6,8} Carlos Alberto Buchpiguel,⁷ Jan Kremers,⁵ Geraldo Busatto Filho,^{6,8} and Dora Fix Ventura^{1,8}

¹Laboratory of Vision, Institute of Psychology, University of São Paulo, São Paulo, Brazil

²Prevent Senior Private Health Operator, São Paulo, Brazil

³Department of Ophthalmology, Semmelweis University, Budapest, Hungary

⁴Department of Mechatronics, Optics and Mechanical Engineering Informatics, University of Technology and Economics, Budapest, Hungary

⁵Section for Retinal Physiology, University Hospital Erlangen, Erlangen, Germany

⁶Laboratory of Psychiatric Neuroimaging (LIM 21), Department of Psychiatry, Medical School (FMUSP), University of São Paulo, São Paulo, Brazil

⁷Laboratory of Nuclear Medicine (LIM-43), Department of Radiology and Oncology, Medical School (FMUSP), University of São Paulo, São Paulo, Brazil

⁸Núcleo de Apoio à Pesquisa em Neurociência Aplicada (NAPNA), Universidade de São Paulo, São Paulo, Brazil

⁹Young medical Leadership Program of National Academy of Medicine in Brazil, Rio de Janeiro, Rio de Janeiro, Brazil

Correspondence: Kallene Summer Moreira Vidal, University of São Paulo, Av Prof Mello Moraes, 1721, São Paulo, Brazil 05508-030, Brazil; kallenesummer@gmail.com.

Received: November 21, 2021

Accepted: April 13, 2022

Published: May 17, 2022

Citation: Vidal KSM, Decleva D, Barboni MTS, et al. The association between acquired color deficiency and PET imaging of neurodegeneration in mild cognitive impairment and Alzheimer disease. *Invest Ophthalmol Vis Sci.* 2022;63(5):20. <https://doi.org/10.1167/iovs.63.5.20>

PURPOSE. To evaluate color vision changes and retinal processing of chromatic and luminance pathways in subjects with Alzheimer disease (AD) and mild cognitive impairment (MCI) compared with a matched control group and whether such changes are associated with impaired brain glucose metabolism and β -amyloid deposition in the brain.

METHODS. We evaluated 13 patients with AD (72.4 ± 7.7 years), 23 patients with MCI (72.5 ± 5.5 years), and 18 controls of comparable age ($P = 0.44$) using Cambridge color test and the heterochromatic flicker ERG (HF-ERG). The Cambridge color test was performed using the trivector protocol to estimate the protan, deutan and tritan color confusion axes. HF-ERG responses were measured at a frequency of 12 Hz, which ERGs reflect chromatic activity, and at 36 Hz, reflecting luminance pathway. A study subsample was performed using neuropsychological assessments and positron emission tomography.

RESULTS. Patients with AD presented higher mean values indicating poorer color discrimination for protan ($P = 0.04$) and deutan ($P = 0.001$) axes compared with the controls. Along the tritan axis, both patients with AD and patients with MCI showed decreased color vision ($P = 0.001$ and $P = 0.001$) compared with controls. The analyses from the HF-ERG protocol revealed no differences between the groups ($P = 0.31$ and $P = 0.41$). Diffuse color vision loss was found in individuals with signs of neurodegeneration (protan $P = 0.002$, deutan $P = 0.003$ and tritan $P = 0.01$), but not in individuals with signs of β -amyloid deposition only (protan $P = 0.39$, deutan $P = 0.48$, tritan $P = 0.63$), regardless of their clinical classification.

CONCLUSIONS. Here, patients with AD and patients with MCI present acquired color vision deficiency that may be linked with impaired brain metabolism.

Keywords: Alzheimer disease, mild cognitive impairment, color vision, electroretinogram, positron emission tomography

Alzheimer disease (AD) is the most common cause of dementia.¹ Diagnosing the disease early could improve standards of care and decrease the overall burden of disease.¹ Therefore, identifying reliable and sensitive biomarkers is particularly important, because neurodegen-

erative processes begin years before the onset of symptoms.² Nonetheless, current biological markers mostly involve brain imaging and neuropsychological evaluations that are either expensive or not readily available in public health system in low- and middle-income countries, impacting the

early diagnosis particularly those at risk for developing dementia.³⁻⁵

Therefore, alternative screening tools should be explored further. In this context, visual deficits are previously reported in AD and, correspondingly, several visual function changes have been described in such patients, including visual field loss in the inferior hemifield, decreased visual contrast sensitivity, impaired pupillary light reflexes, and ocular motor dysfunction.² Furthermore, retinal fiber layer alterations^{6,7} and ERG changes have also been observed.⁸⁻¹⁰ Psychophysical methods to measure specific visual functions, such as color vision, are also useful for visual screening. Color vision changes have been reported in patients with AD²; most of the studies used arrangement tests, which may be time consuming and less sensitive than threshold tests.¹¹

In the ERGs studies, changes such as amplitude reductions and delays of the P50 component of the pattern ERG have been reported in patients with AD.^{2,12,13} These physiological changes are in accordance with of retinal ganglion cells losses, particularly large retinal ganglion cells, putatively belonging to magnocellular retinogeniculate pathway, observed in post-mortem studies.^{14,15} However, pattern ERGs have limitations because they rely on good ocular fixation and good optical quality of the eye media.¹⁶ Therefore, it is crucial to develop alternative ERG protocols that are more robust.² A possible alternative may be heterochromatic flicker ERGs (HF-ERG) because it is designed to emphasize the activity of the chromatic or the luminance pathways, expanding the scope of the technique to processing in retinogeniculate pathways.^{17,18}

A more rigorous psychophysical test used to evaluate color vision is the Cambridge color test (CCT),¹⁹ which is a computerized psychophysical test in the isoluminant u'v' space, which allows quantitative estimates of color thresholds. It is based on the same principle as the Ishihara plates, using a mosaic of circles of different diameters and luminances as background and a set of this mosaic as the target, with a different chromaticity. The idea behind this design is to eliminate luminance and contour or border cues that might affect the discrimination, the same principle used in the traditional Ishihara plates.^{19,20} It has been found that color vision defects may be detected with the CCT in association with several pathologic conditions: mercury intoxication,^{21,22} diabetes,^{23,24} Duchenne muscular dystrophy,²⁵ Leber's hereditary optic neuropathy,²⁶ multiple sclerosis,²⁷ autism spectrum disorders,²⁸ and glaucoma.^{29,30} Other computerized color vision tests are also available, such as the CAD test from the City University London which has been extensively used and is approved for testing^{19,31} of aviation pilots and other tests as ColorDx CCT HD³² and Rabin cone contrast test.³³

Although the CCT and the HF-ERG have shown promising results in assessing visual deficits, they have not yet been reported in patients with neurodegenerative disorders such as AD or mild cognitive impairment (MCI). Moreover, few studies on color vision changes in AD have been correlated with standard biological markers of neurodegeneration, such as impaired neuropsychological tests and alterations in positron emission tomography (PET) images.³⁴

Thus, the primary aim of the present study was to evaluate color vision using the CCT and HF-ERG in patients with early AD and MCI, compared with age-matched control subjects. As a secondary aim, we evaluated whether the outcomes of these visual tests were associated with cognitive

performance measured by neuropsychological tests. Finally, we investigated whether CCT and HF-ERG changes were observed according to the results of PET scans using Pittsburgh compound-B (¹¹C]PiB-PET) to detect cortical A β -deposition and [¹⁸F] fluorodeoxyglucose (¹⁸F]FDG-PET) to assess brain glucose metabolism (and used as a sensitive probe for neurodegeneration), following the biomarker-based definition of AD.³⁵

METHODS

Study Design

This study used an observational, case control design.

Subjects

All subjects who participated in the study gave their informed consent after an explanation of the nature and possible consequences of the study. The study adhered to the tenets of the Declaration of Helsinki and was approved by the Institutional Review Board of the Clinics Hospital (CAAE:10338213.4.1001.0068) and Psychology Institute (CAAE:2.065.527) at the University of São Paulo.

The patients and part of the control subjects were referred from the Hospital das Clínicas, Faculdade de Medicina, Universidade de São Paulo (HC-FMUSP). The controls were also referred from the Ophthalmology Clinic of Prevent Senior Private Health Operator, in São Paulo, Brazil.

All patients underwent complete clinical and neuropsychological assessments by trained, board-certified psychiatrists and neuropsychologists. Early AD and MCI were diagnosed according to the criteria described by McKhann et al. (2011).³⁶ Briefly, patients with AD had to present symptoms compatible with dementia, with an onset of gradual cognitive decline, which may include language, visuospatial, and executive deficits, and memory decline in the amnesic form. In addition, they neither presented clinical criteria of dementia with Lewy body or frontotemporal lobar degeneration, nor significant concomitant cerebrovascular diseases, aphasia, or other neurological diseases. They were not using any medication that could affect cognition. Also, systemic diseases that affect the retina, such as diabetes, were excluded.

The diagnosis of amnesic MCI was based on a worsening of recent cognitive performance, as informed by the patient, a relative, or a clinician; deficits in one or more cognitive domains (with a performance worse than expected for age and education); a decrease in independence for performing daily activities; and the absence of dementia and of vascular, traumatic, or medical conditions.

For the control group referred from the HC-FMUSP, six age-matched elderly subjects without a history of cognitive deficits, and neurological, psychiatric, or other medical conditions that could interfere with the study results were selected. Twelve control subjects referred from the Prevent Senior Institute were selected using the same criteria, but did not perform neuroimaging and neuropsychological tests.

All subjects underwent a complete ophthalmological examination, including measurements of refraction, best-corrected visual acuity, slit-lamp biomicroscopy, IOP measurements, gonioscopy, and dilated funduscopic examination. Exclusion criteria were a best-corrected visual acuity of less than 20/30, a spherical refractive error of more than 5 diopters (D) and/or a cylindrical error of more than 3 D,

lens opacity of greater than 0.5 according to the Lens Opacity Classification System III groups,³⁷ previous ophthalmological surgery including cataract surgery, and the presence of ophthalmological diseases. Also, individuals with congenital color vision deficiencies were excluded. The visual evaluations including psychophysical tests and ERGs measurements were performed at the Vision Laboratory, Institute of Psychology (USP). Because some subjects were not able or willing to complete all experiments, the test order was randomized. If both eyes met the inclusion criteria, the eye with the best-corrected visual acuity was selected as the study eye.

Visual Evaluation Procedures

Psychophysical Test (CCT). Color vision was evaluated using the CCT. Stimuli were presented on a Viewsonic G90fB 190 CRT monitor controlled by a Visual Stimulus Generator 2/5 (Cambridge Research Systems, Rochester, UK). The test used stimuli in which the background was presented at a given chromaticity (CIE 1976 chromaticity diagram $u'v'$: 0.1977; 0.4689), and the target, a “Landolt C”, was presented with a different chromaticity. Both background and target were composed of circular patches that varied in size (between 5.7 and 22.8 arcmin) and luminance (between 7 and 15 cd/m²). The target was presented in one of four orientations with the Landolt C gap at the right, left, up, or down. The subject’s task was to report the position of the gap verbally to the experimenter (four-alternative forced choice). Only one eye was tested; the other eye was covered by an eyepatch.

The subjects were seated in a dark room 3 m from the monitor. The outer and inner diameters of the Landolt C subtended 4.4° and 2.3° of visual angle, respectively, and the gap subtended 0.8° of visual angle, (corresponding to the detail subtended by a 20/960 letter size; logMAR = 1.7).

The chromaticity of the stimuli was varied along the protan and deutan and tritan color confusion axes in color space (trivector test) in random order. After each correct response, the stimulus chromaticity was altered in the direction of the background and after each incorrect response, it was changed away from the background chromaticity in color space. The thresholds for each axis were calculated by averaging the values at six response reversals from correct to incorrect and vice versa.¹⁹

The test allowed a 10-second interval for the subject’s response, moving on to the next presentation in the absence of a response and recording a wrong response in that case. This time was longer than the usual response time of the test (5 seconds). All subjects were given a demonstration trial (the first 2 minutes of the trivector test) to check if the instructions were understood. We only performed the entire trivector test for subjects who could complete the trial demonstration. The subject’s task in the CCT is a simple task that involves reporting the detection of the target orientation. Subjects who failed to perform the demonstration test were excluded from the sample.

HF-ERGs. HF-ERGs were recorded from the same eye tested for color vision. The other eye was occluded with an eyepatch during the recordings. The pupil was dilated with a drop of 0.5% tropicamide (Pharma Stulln GmbH, Stulln, Germany) prior to recording. A DTL fiber electrode was placed over the lower conjunctiva and served as the active electrode. Two gold cup electrodes filled with electrode paste (Weaver and Company, Aurora, CO), one placed

at the forehead and one at the ipsilateral temple, served as ground and reference electrodes, respectively. The forehead and ipsilateral temple were cleaned using NuPrep Gel abrasive gel before placing the electrode. The impedance of the active and reference electrode was less than 5 k Ω .

The signals were amplified 100,000 times, band-pass filtered between 1 and 300 Hz, and sampled at 1024 Hz. The ERG responses were averages from 24 (36 Hz stimuli) or 48 sweeps (12 Hz stimuli), each lasting 1 second. The first 2 seconds of recording time after the stimulus started were disregarded to avoid onset artifacts.

The heterochromatic stimuli were generated in a Ganzfeld bowl (Q450SC, Roland Consult, Brandenburg, Germany) controlled by the RETIport system (Roland Consult) by modulating the outputs of red (with contrast R) and green (with contrast G) light-emitting diodes sinusoidally in counterphase around a mean luminance of 100 cd/m² each. The different stimulus conditions were generated by varying R while keeping the total contrast (R + G) constant at 100%. The stimulus conditions were quantified by the red contrast fraction (FR = R/[R + G]). At a temporal frequency of 12 Hz the stimuli elicit ERGs whose fundamental components reflect the activity of the parvocellular L-M cone opponent channel, whereas at 36 Hz the ERGs reflect activity of the magnocellular luminance channel.^{17,18}

ERG responses were measured to three different stimuli with FR 0, 0.5 and 1. At an FR of 0, the G was 100% contrast and R was 0% (i.e., the output of the red diode was not modulated). At an FR of 0.5, R and G were both 50% Michelson contrast. At an FR of 1, the G was 0% whereas the R was 100%. This is a short protocol version from those in previous studies.¹⁸ The short version was applied in a previous disease-related study from our group with patients with glaucoma.³⁸

The HF-ERG responses were Fourier analyzed using a self-written MATLAB program (MATLAB, The Math Works, Natick, MA). The ERG amplitudes and phases of the first harmonic (fundamental) components were extracted from the responses to the 12-Hz and 36-Hz stimuli. From the responses to 12-Hz stimuli, the second harmonic components (i.e., at 24 Hz) were also obtained.

Neuropsychological and Neuroimaging Assessment

All patients and controls referred from HC-FMUSP were submitted to neuropsychological tests and neuroimaging evaluation at Laboratory of Psychiatric Neuroimaging (LIM21-IPq USP).

Neuropsychological Tests

Two cognitive performance measures were used: the Rey Auditory-Verbal Learning Test (RAVLT)^{39,40} and the Mini-Mental State Examination (MMSE).⁴¹ For more details about these tests, see previous studies cited by Squarzoni et al.⁴²

Neuroimaging

Most of the patients with MCI (21 of 23) and patients with AD (11 of 12) and 6 of 18 controls underwent neuroimaging tests using ¹¹C-Pittsburgh Compound-B (PiB) and [¹⁸F]FDG PET with computed tomography. These assessments were used to classify the individuals with a modified “AT(N)”

staging based on the 2019 NIA-AA Research Framework,³⁵ aiming to detect the presence of β -amyloid plaques (used as a proxy for A+/A- staging), and to evaluate the reduction of regional brain glucose metabolism indicating neurodegeneration (a proxy for N+/N- staging). A complementary analysis combining amyloid PET and [¹⁸F]FDG-PET to generate an "A(N)" staging was also performed and is disclosed as supplementary material. Details regarding radiochemical production, data acquisition, and the PET-based "A(N)" classification were described previously.⁴³⁻⁴⁶ Our group previously described the whole rationale of this staging in a larger subset of individuals.⁴⁴ It is important to note that this biomarker-based classification does not consider the individuals' clinical status, thus grouping them according to indirect signs of brain pathology, regardless of their clinical status (e.g., cognitively healthy, MCI, or dementia).

Statistical Analysis

We used SPSS v. 20.0 (SPSS Inc., Armonk, NY) and Stata v. 12.0 (StataCorp, College Station, TX) for the statistical analyses. A Kolmogorov-Smirnov test was used to evaluate the distribution of the dependent variables. Mean and standard deviation were used to describe normally distributed variables and median and percentiles for non-normally distributed variables. For descriptive data, clinical and demographic variables were compared across groups using one-way ANOVA, χ^2 tests, or Fisher's exact tests, as appropriate.

For the primary outcome, the significance level adopted was $P < 0.05$. As the data from the CCT and ERG recordings tests were normally distributed; we used one-way ANOVA with subsequent multiple comparisons using Tukey post hoc corrections.

For our secondary outcome, we reclassified the groups according to their PiB-PET (A+ or A-) and [¹⁸F]FDG-PET (N+ or N-) results. For [¹⁸F]FDG-PET, the data from protan and deutan were not normally distributed; therefore, we used a nonparametric Mann-Whitney test. Because the tritan had a normal distribution, a *t*-test was used for this analysis. For PiB-PET, we used ANOVA followed by the Tukey post hoc test, because the data were normally distributed. Multivariate linear regression models were conducted to further examine associations between primary outcomes

and scores from the MMSE and the RAVLT, adjusting for possible confounding factors, including age and education.

RESULTS

Of the 89 subjects evaluated, 53 (18 controls, 23 MCI, and 12 AD) were included in the final sample study (Table). We excluded 36 subjects owing to glaucoma, eye surgery, AMD, and diabetic retinopathy.

Primary Outcomes

CCT. There were significant differences in CCT scores of AD and patients with MCI compared with normal subjects for protan, $F = 3.42$, $P = 0.40$; deutan, $F = 8.63$, $P = 0.001$; and tritan, $F = 10.87$, $P < 0.001$.

Patients with AD ($n = 12$) showed worse color vision, expressed by longer vector length between the threshold and the background chromaticities in the protan ($83.25 \pm 19.53 \text{ u}^\circ\text{v}^\circ \times 10^{-4}$; $P = 0.04$) and deutan ($106.42 \pm 54.21 \text{ u}^\circ\text{v}^\circ \times 10^{-4}$; $P = 0.001$) axes compared with the control group; $59.88 \pm 8.48 \text{ u}^\circ\text{v}^\circ \times 10^{-4}$ and $60.33 \pm 9.25 \text{ u}^\circ\text{v}^\circ \times 10^{-4}$, respectively ($n = 18$). Along the tritan axis, both AD and MCI ($n = 23$) patients showed reduced color vision (respectively, $170.08 \pm 55.22 \text{ u}^\circ\text{v}^\circ \times 10^{-4}$; $P = 0.001$ and $155.30 \pm 56.88 \text{ u}^\circ\text{v}^\circ \times 10^{-4}$; $P = 0.001$) compared with controls ($93.33 \pm 38.81 \text{ u}^\circ\text{v}^\circ \times 10^{-4}$) (Fig. 1).

HF-ERG. Figure 2 shows the results for the HF-ERG recordings from controls ($n = 13$), patients with MCI ($n = 16$), and patients with AD ($n = 10$) for the first and second harmonics at 12 Hz (upper and middle rows) and for the first harmonic at 36 Hz (lower row). No amplitude or phase differences were found for either harmonic at 12 Hz. At 36 Hz, we found amplitude differences in the FR = 1 condition, between patients with MCI (7.65 ± 1.45) and patients with AD (4.91 ± 2.84 ; $P = 0.03$). However, the differences were not statistically different from the control group (6.27 ± 3.20 ; $P = 0.31$ and $P = 0.41$, respectively).

Secondary Outcomes

CCT. In multivariate linear regressions, after adjustment for age and education, thresholds along the deutan axis were

TABLE. Demographic and Clinical Data for Control, MCI, and AD Groups

	Control	MCI	AD	P Value
Total subjects enrolled	18	23	12	
Age (years)*	70.2 \pm 5.6	72.5 \pm 5.5	72.4 \pm 7.7	0.44
Sex female [†]	8 (44)	5 (22)	5 (22)	0.18
Visual acuity [†]				
20/20	7 (39)	12 (52)	5 (38)	0.20
20/25	7 (39)	4 (17)	1 (8)	
20/30	4 (22)	7 (30)	7 (54)	
Subjects with neuropsychological and neuroimaging evaluation	6	21	11	
MMSE*	29.0 \pm 1.3	26.6 \pm 2.3	21.9 \pm 3.5	<0.001
RAVLT total*	10.7 \pm 2.9	7.4 \pm 2.8	1.6 \pm 1.8	<0.001
PiB-PET SUVr*	0.99 \pm 0.56	1.23 \pm 0.23	1.38 \pm 0.40	0.11
A+ [†]	1 (16)	8 (38)	5 (45)	0.51
N+ [†]	0 (0)	3 (14)	6 (54)	0.01
Education (years)*	15.5 \pm 4.4	10.2 \pm 4.7	6.9 \pm 4.5	0.003

SUVr, standardized uptake value ratio of the PiB-PET examinations, using the cerebellum as the reference region.

Values are mean \pm standard deviation or number (%).

Significance levels are based on * One-way ANOVA and [†] χ^2 .

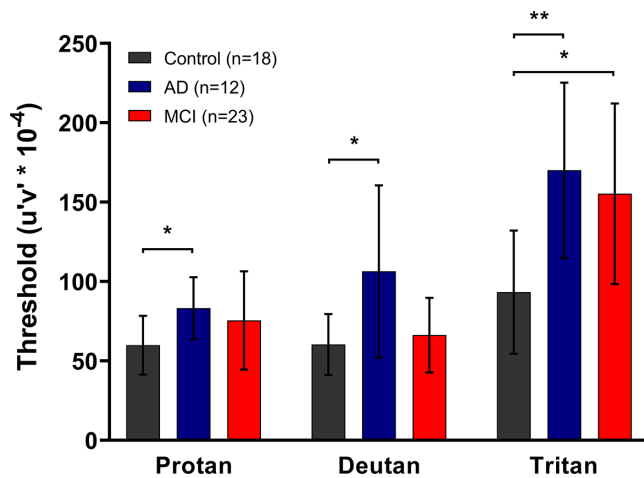


FIGURE 1. CCT results. Means and standard deviations of vector lengths corresponding to protan, deutan and tritan thresholds from controls (black), AD (blue), and MCI (red) groups. Statistically significant comparisons are marked with asterisks. One-way ANOVA $*P < 0.05$, $**P = 0.001$.

associated with neurophysiological tests: RAVLT (slope $[\beta]$ -3.33 ; 95% CI, -5.7 to -0.97 ; $P = 0.007$) and MMSE ($\beta = -3.70$; 95% CI, -6.60 to -6.59 ; $P = 0.01$). The tritan axis thresholds were associated only to RAVLT ($\beta = -6.30$; 95% CI, -11.39 to -1.21 ; $P = 0.01$). For each unit in RAVLT and MMSE scores, there was a loss of $3.33 u'v' \times 10^{-4}$ and $3.70 u'v' \times 10^{-4}$, respectively, along the deutan axis threshold. The discrimination loss along the tritan axis corresponded with $6.30 u'v' \times 10^{-4}$ for each RAVLT unit score.

When groups were divided according to their PiB-PET status (A+ or A-), there was no difference between the A+ ($n = 14$) and A- groups ($n = 25$) for the protan ($F = 0.74$; $P = 0.39$), deutan ($F = 0.49$; $P = 0.48$), or tritan ($F = 0.22$; $P = 0.63$) axes discrimination thresholds (Fig. 3, bottom left). When the groups were reclassified according $[^{18}\text{F}]\text{FDG}$ -PET status (N+ or N-), a significant difference was observed: The N+ group ($n = 9$) had elevated color discrimination thresholds along the protan ($Z = -2.98$; $P = 0.003$), deutan ($Z = -3.03$; $P = 0.002$), and tritan ($F = 7.45$; $P = 0.01$) axes, compared with the N- group ($n = 30$) (Fig. 3, right plot). Negative results are described in Table in the Supplementary Material.

A further analysis using a rationale of the “AT(N)” staging suggested by the 2018 NIA-AA Research Framework (NIA-AA RF) classification was performed. This analysis showed that the neurodegeneration (N- and N+) was a better predictor of worse color discrimination than cortical deposition of β -amyloid plaques (A+ or A-). Neurodegeneration (N+) indicated worse color discrimination for the protan and deutan axes thresholds, but not for tritan. However, when the P value is adjusted for multiple comparisons, only the comparisons between A-N+ and A+N- remain significant for the deutan axis (Tables S2 and S3 in the Supplementary Material).

HF-ERG. No significant associations were found between HF-ERG parameters and neuropsychological tests. There was also no difference between groups according to PiB and $[^{18}\text{F}]\text{FDG}$ -PET scans.

DISCUSSION

The present study investigated color vision and retinal processing alterations using, respectively, psychophysical and ERG methods in AD and patients with MCI, compared with controls. The primary finding was a diffuse color sensitivity loss affecting the protan, deutan, and tritan color confusion axes in patients with AD and a color vision loss along the tritan axis in patients with MCI relative to age-matched control subjects. The ERG showed reduced responses for the AD group compared with the MCI group in the luminance response. Interestingly, no differences between patients and controls were observed. The alterations in the tritan thresholds were related to worse scores in the MMSE test, whereas the worse scores in the RAVLT test were related to deutan and tritan deficiencies. Diffuse color vision loss, that is, impairment along all three-color confusion axes, was also found in individuals with signs of neurodegeneration (N+), irrespective of their clinical classification (MCI or AD), but not in individuals with signs of amyloid deposition (A+) only, also regardless of their clinical classification.

Prior findings on color vision in patients with AD have been inconsistent. Some studies reported an impairment along the tritan axis,^{47,48} whereas others showed a diffusely affected color vision^{34,49} or absence of impairment.^{50–52} Recently, Polo et al.⁵³ showed a protanomaly defect in patients with AD. A possible explanation for these inconsistent results could be methodological differences between the studies. No previous studies examined AD in the light of their neuroimaging biomarker status. They used clinical classification based on cognitive stages to identify patients with AD, which can increase the selection bias, including patients with non-AD, especially in the early stages. Moreover, some studies have reported that color vision impairment is more prevalent in dementia with Lewy body than AD⁵⁴ and can help in the differential diagnosis between dementia with Lewy body and AD.⁵⁵ Thus, the present work emphasizes the application of a sensitive and reliable color vision test, such as the CCT, to compare the results from different studies.²¹

Previous studies reporting color vision impairment in patients with AD showed no correlations between color vision changes and cognitive performance, suggesting that color vision losses in AD are not fully related to global cognitive decline.^{48,49} However, Salamone et al.³⁴ (2009) showed that the color vision performance in patients with AD, assessed with the Farnsworth–Munsell 100 hue test, was inversely correlated with MMSE scores. We found similar results with multivariate linear regression adjusted for age and education. RAVLT scores were inversely related to red–green and blue–yellow thresholds, whereas the MMSE was related only to blue–yellow thresholds. Although an explanation for this finding could be related to patient difficulties in performing or understanding the tests, we believe that this has not occurred in our study, because the CCT requires the understanding of a simple task and the protocol was adapted to the elderly population by allowing a longer response time, as described in the Methods. In addition, we evaluated patients with MCI and mild AD; therefore, patients with higher cognitive declines were excluded.

In the MCI group, only the thresholds along the tritan axis were affected. MCI is associated with a 5% to 10% increased risk per year of developing dementia and AD.⁵⁶ Thus, the fact that a milder color vision loss was found in the MCI compared with the AD group agrees with the morphologi-

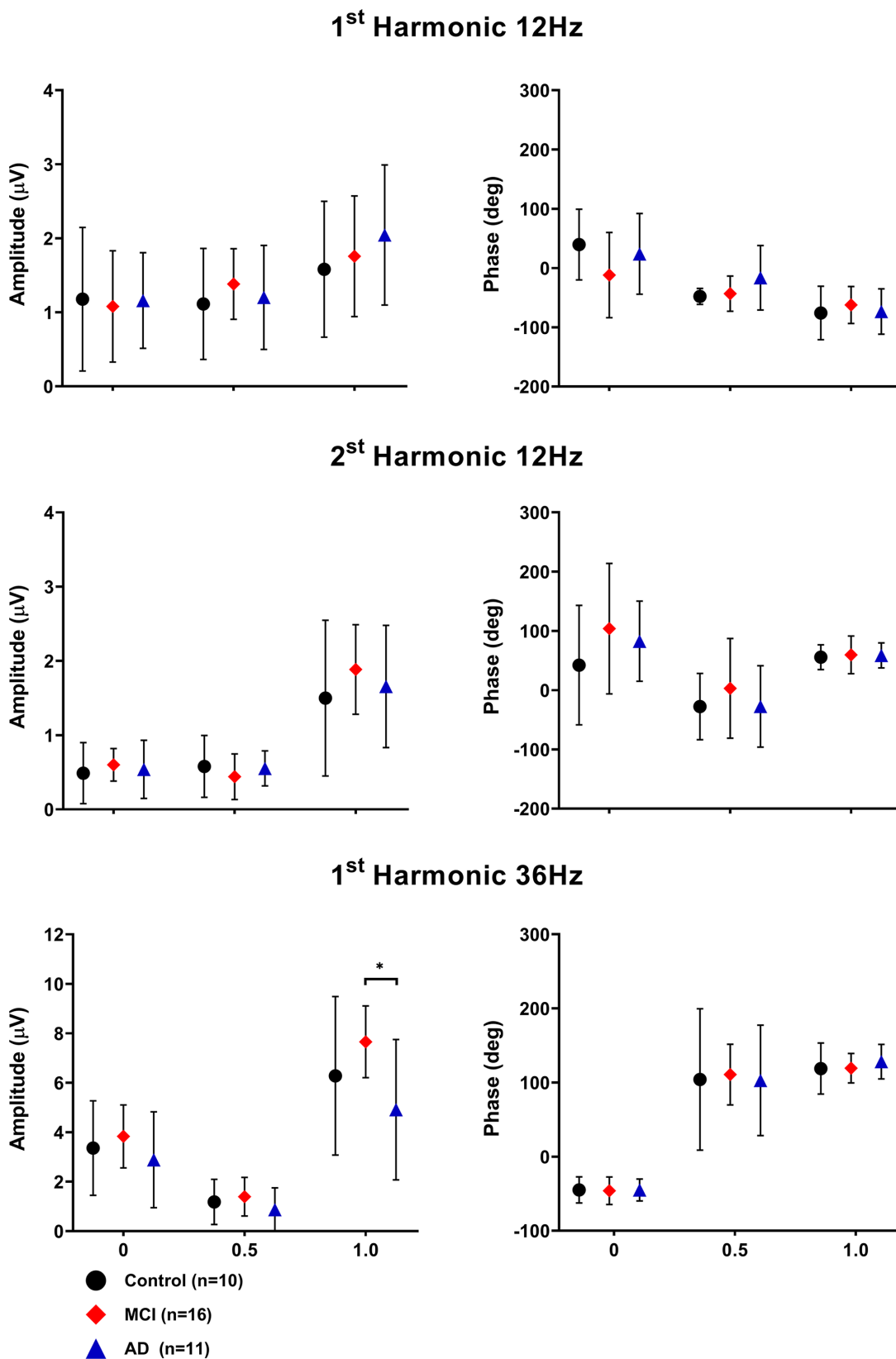


FIGURE 2. HF-ERG results. Group averages \pm standard deviations from 12 Hz first and (*top*), 12 Hz second harmonics (*middle*) and 36 Hz first harmonic (*bottom*) amplitudes (*right*) and phases (*left*). The only statistically significant difference was between the MCI and AD at FR = 1 (marked with an asterisk), however neither patient group differed from control. One-way ANOVA $*P < 0.05$.

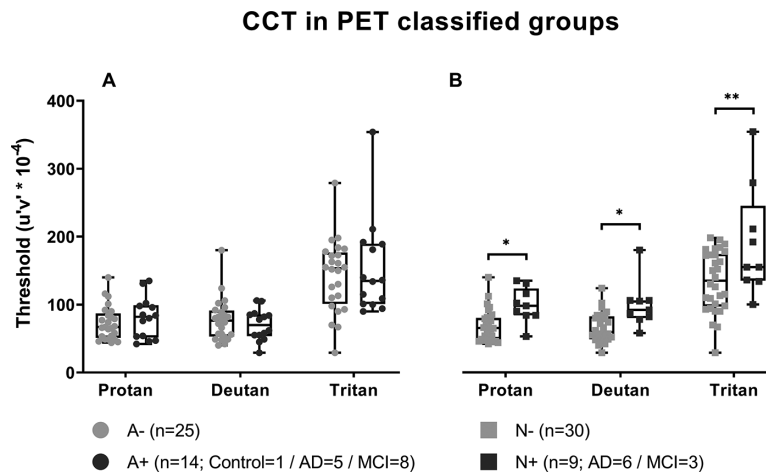


FIGURE 3. CCT results × PET. Box plots for the protan, deutan, and tritan mean thresholds. No statically significant differences were found for PiB-PET groups (A). Significant differences were found for $[^{18}\text{F}]\text{FDG}$ groups. The $[^{18}\text{F}]\text{FDG}$ -positive group had worse color discrimination along the three-color confusion axes (B). The number of subjects statistically significant comparisons are marked with asterisks ($P < 0.05$ Mann-Whitney* t -test**). A+ or –, positivity or not for the presence of β -amyloid plaques in the cerebral cortex detected with PiB PET; N+ or –, presence or not of neurodegeneration detected with an $[^{18}\text{F}]\text{PET}$ scan.

cal observation that the RNFL thicknesses in patients with MCI is intermediate between those of normal subjects and patients with AD.^{57,58} This finding can be explained by the intrinsically heterogeneous nature of MCI, including individuals with variable proportions of amyloid deposition and signs of neurodegeneration (Table). In addition to neural factors, tritan defects may be caused by optical changes, owing to aging of increasing lens density and lens yellowing.^{59,60} However, to avoid lens yellowing as a confounding factor, the groups were age matched and the Lens Opacity Classification System II was used to classify lens opacity.³⁷

One major finding in this study was that global worsening of the color vision was observed for N+ patients, but not for the A+ group. Previous studies used a clinical classification based on cognitive stages to identify patients with AD and patients with MCI. The typical neuroimaging findings indicative of AD include the presence of β -amyloid and tau pathology as assessed with PET, which occur earlier over the course of the disease.³² Later on, there is decreased regional brain glucose metabolism in the posterior cingulate and temporoparietal cortices as assessed by $[^{18}\text{F}]\text{FDG}$ -PET as an indication of neurodegenerative changes.^{35,43,61} The decrease in glucose metabolism is associated with a poorer AD course.^{62–64} Our results show a possible link between color vision loss and brain neurodegeneration, but not with brain amyloid deposition alone. In the other words, the color vision impairment may be associated with non-AD neurodegeneration. According to the previously cited 2019 NIA-AA Research Framework “AT(N)” classification,³⁵ amyloid positivity (A+) is biological necessary to include an individual in the AD continuum. Further stages of the disease are AD pathologic changes without signs of neurodegeneration (A+T+[N–]) or with signs of neurodegeneration (A+T+[N+]). In our study, individuals classified as A–N+ had color vision impairment at a higher rate than A+N– (Supplementary Material). So, probably individuals out of the AD continuum with non-AD-related neurodegeneration are at a higher risk for color vision impairment than individuals in the AD continuum in earlier stages of the disease, thus without overt neurodegeneration (A+N–).³⁵ This find-

ing also suggests that the results of the present study may be at least driven by individuals with non-AD pathology.

The HF-ERG protocol was insensitive to detect color vision alterations in AD and MCI as the psychophysical test. A possible but nonsignificant alteration in the luminance reflecting ERGs could be detected in the AD group. We have argued previously that the HF-ERGs probably originate in the outer retina.^{18,65} The present data, therefore, provide evidence that the outer retina is not involved in AD and MCI. This finding in agreement with the notion that AD-related color vision impairments occur mainly at the cortical level.^{34,47–49,66} Future clinical protocols using VEP recordings combined with HF stimuli,⁶⁷ visual tests, and PET with computed tomography scans that evaluate the visual pathways in the same subjects at retinal and visual cortex levels could give more detail about the involvement of visual pathways in AD and MCI.

The main limitation of our study is the high variability in the control group, probably owing to differences from populations that came from different referral sites. One recruitment site was based in an ophthalmology clinic and the other was based in the Institute of Psychiatry. Even though all participants met the eligibility criteria for participating in the study, this issue might have increased the variability of the data, thus decreasing the power to identify differences between the AD and control groups. It should also be noted that the proportion of dementia patients classified as A+ was lower than the rates reported in the literature and in our previous investigation on a larger sample of elderly subjects.⁴⁴ This finding may be partially explained because we used a conservative A+ threshold, decreasing the proportion of dementia cases.^{44,46} Moreover, the selection of dementia subjects based solely on clinical criteria is known to lead to the inclusion of a non-negligible minority of individuals who have no signs of amyloid deposition.⁴⁴

One of the strengths in our study was the use of the CCT to evaluate the color vision in AD and patients with MCI, since its results are not biased by learning or fatigue effects,⁶⁸ and its fast protocol, the trivector protocol, can be easily and rapidly performed by patients with dementia.

Also, we increase the response time from 5 to 10 seconds and we adopted verbal response instead the input device normally used to indicate the Landolt C gap position. A second strength was the use of amyloid and neurodegeneration biomarkers measured with PET.

Finally, prospective studies following patients with MCI with blue–yellow alterations and A+N+ individuals classified with PiB and [¹⁸F]FDG-PET scans are warranted to explore whether these alterations could be a tool to identify susceptibility for AD development.

CONCLUSIONS

In our study, we observed that patients clinically classified as have elevated color sensitivity thresholds along the protan, deutan, and tritan axes, whereas patients with MCI displayed larger thresholds along the tritan axis. The three-color confusion axes are affected in groups with signs of neurodegeneration (N+), but not with cortical amyloid deposition alone. Also, alterations along the deutan and tritan axes were associated with worse performance in neuropsychological tests. HF-ERG, which mainly evaluates responses from outer and middle retina (cones and cone bipolar cells), was preserved in patients with AD and patients with MCI for both the luminance and the cone-opponent channels. The CCT is a noninvasive tool that may be considered for progression monitoring of AD and MCI. The color vision changes are associated with neurodegeneration despite the clinical classification in MCI and AD.

Acknowledgments

The authors thank Ricardo Nitrini, Sonia Brucki, and Orestes V. Forlenza for referring patients with AD and patients with MCI from HC-FMUSP to be included in the study, and Fabio Luiz de Souza Duran for his assistance in the preprocessing of PET data.

Disclosure: **K.S.M. Vidal**, None; **D. Decleva**, None; **M.T.S. Barboni**, None; **B.V. Nagy**, None; **P.A.H. de Menezes**, None; **A. Aher**, None; **A.M. Coutinho**, None; **P. Squarzoni**, None; **D. de Paula Faria**, None; **F.L. de Souza Duran**, None; **C.A. Buchpiguel**, None; **J. Kremers**, None; **G.B. Filho**, None; **D.F. Ventura**, None

References

- Price JL, Morris JC. Tangles and plaques in nondemented aging and “preclinical” Alzheimer’s disease. *Ann Neurol*. 1999;45(3):358–368, doi:10.1002/1531-8249(199903)45:3(358::AID-ANA12)3.0.CO;2-X.
- Tzekov R, Mullan M. Vision function abnormalities in Alzheimer disease. *Surv Ophthalmol*. 2014;59(4):414–433, doi:10.1016/j.survophthal.2013.10.002.
- Parra MA, Baez S, Allegrì R, et al. Dementia in Latin America. *Neurology*. 2018;90(5):222–231, doi:10.1212/WNL.0000000000004897.
- Ferretti C, Sarti FM, Nitrini R, Ferreira FF, Brucki SMD. An assessment of direct and indirect costs of dementia in Brazil. *PLoS One*. 2018;13(3):e0193209, doi:10.1371/journal.pone.0193209.
- Lorena Chaves M, Luiza Camozzato A, Godinho C, Piazenski I, Kaye J. Incidence of mild cognitive impairment and Alzheimer disease in southern Brazil. *J Geriatr Psychiatry Neurol*. 2009;22(3):181–187, doi:10.1177/0891988709332942.
- Thomson KL, Yeo JM, Waddell B, Cameron JR, Pal S. A systematic review and meta-analysis of retinal nerve fiber layer change in dementia, using optical coherence tomography. *Alzheimer’s Dement Diagn Assess Dis Monit*. 2015;1(2):136–143, doi:10.1016/j.dadm.2015.03.001.
- Moschos M, Markopoulos I, Chatziralli I, et al. Structural and functional impairment of the retina and optic nerve in Alzheimer’s disease. *Curr Alzheimer Res*. 2012;9(7):782–788, doi:10.2174/156720512802455340.
- Javaid FZ, Brenton J, Guo L, Cordeiro MF. Visual and ocular manifestations of Alzheimer’s disease and their use as biomarkers for diagnosis and progression. *Front Neurol*. 2016;7:55, doi:10.3389/fneur.2016.00055.
- Lim JKH, Li Q-X, He Z, et al. The eye as a biomarker for Alzheimer’s disease. *Front Neurosci*. 2016;10:536, doi:10.3389/fnins.2016.00536.
- La Morgia C, Ross-Cisneros FN, Sadun AA, Carelli V. Retinal ganglion cells and circadian rhythms in Alzheimer’s disease, Parkinson’s disease, and beyond. *Front Neurol*. 2017;8:162, doi:10.3389/fneur.2017.00162.
- Bento-Torres NVO, Rodrigues AR, Côrtes MIT, Bonci DM de O, Ventura DF, Silveira LC de L. Psychophysical evaluation of congenital colour vision deficiency: discrimination between protans and deutans using Mollon-Reffin’s ellipses and the Farnsworth-Munsell 100-hue test. *PLoS One*. 2016;11(4):e0152214, doi:10.1371/journal.pone.0152214.
- Parisi V, Restuccia R, Fattapposta F, Mina C, Bucci MG, Pierelli F. Morphological and functional retinal impairment in Alzheimer’s disease patients. *Clin Neurophysiol*. 2001;112(10):1860–1867, doi:10.1016/S1388-2457(01)00620-4.
- Berisha F, Fekete GT, Trempe CL, McMeel JW, Schepens CL. Retinal abnormalities in early Alzheimer’s disease. *Investig Ophthalmol Vis Sci*. 2007;48(5):2285, doi:10.1167/iovs.06-1029.
- Hinton DR, Sadun AA, Blanks JC, Miller CA. Optic nerve degeneration in Alzheimer’s disease. *N Engl J Med*. 1986;315(8):485–487, doi:10.1056/NEJM198608213150804.
- Sadun AA, Bassi CJ. Optic nerve damage in Alzheimer’s disease. *Ophthalmology*. 1990;97(1):9–17, doi:10.1016/S0161-6420(90)32621-0.
- Prager TC, Schweitzer FC, Peacock LW, Garcia CA. The effect of optical defocus on the pattern electroretinogram in normal subjects and patients with Alzheimer’s disease. *Am J Ophthalmol*. 1993;116(3):363–369, doi:10.1016/S0002-9394(14)71355-8.
- Parry NRA, Murray IJ, Panorgias A, McKeefry DJ, Lee BB, Kremers J. Simultaneous chromatic and luminance human electroretinogram responses. *J Physiol*. 2012;590(13):3141–3154, doi:10.1113/jphysiol.2011.226951.
- Kremers J, Rodrigues AR, de Lima Silveira LC, da Silva Filho M. Flicker ERGs representing chromaticity and luminance signals. *Investig Ophthalmol Vis Sci*. 2010;51(1):577, doi:10.1167/iovs.09-3899.
- Regan BC, Reffin JP, Mollon JD. Luminance noise and the rapid determination of discrimination ellipses in colour deficiency. *Vision Res*. 1994;34(10):1279–1299, doi:10.1016/0042-6989(94)90203-8.
- Mollon JD, Reffin JP. A computer-controlled color-vision test that combines the principles of Chibret and of Stilling. *J Physiol*. 1989;414:P5.
- Ventura DF, Simões AL, Tomaz S, et al. Colour vision and contrast sensitivity losses of mercury intoxicated industry workers in Brazil. *Environ Toxicol Pharmacol*. 2005;19(3):523–529, doi:10.1016/j.etap.2004.12.016.
- Feitosa-Santana C, Barboni MTS, Oiwa NN, et al. Irreversible color vision losses in patients with chronic mercury vapor intoxication. *Vis Neurosci*. 2008;25(3):487–491, doi:10.1017/S0952523808080590.
- Ventura DF, Costa MF, Gualtieri M, Nishi M, Bernick M, Bonci D, De Souza JM. Early vision loss in diabetic patients

- assessed by the Cambridge Colour Test. In: *Normal and Defective Colour Vision*. Oxford University Press; 2003:395–403, doi:10.1093/acprof:oso/9780198525301.003.0042.
24. Feitosa-Santana C, Paramei G V, Nishi M, Gualtieri M, Costa MF, Ventura DF. Color vision impairment in type 2 diabetes assessed by the D-15d test and the Cambridge colour test. *Ophthalmic Physiol Opt*. 2010;30(5):717–723, doi:10.1111/j.1475-1313.2010.00776.x.
 25. Costa MF, Oliveira AGF, Feitosa-Santana C, Zatz M, Ventura DF. Red-green color vision impairment in Duchenne muscular dystrophy. *Am J Hum Genet*. 2007;80(6):1064–1075, doi:10.1086/518127.
 26. Ventura DF, Gualtieri M, Oliveira AGF, et al. Male prevalence of acquired color vision defects in asymptomatic carriers of Leber's hereditary optic neuropathy. *Investig Ophthalmol Vis Sci*. 2007;48(5):2362, doi:10.1167/iovs.06-0331.
 27. Moura AL de A, Teixeira RAA, Oiwa NN, et al. Chromatic discrimination losses in multiple sclerosis patients with and without optic neuritis using the Cambridge colour test. *Vis Neurosci*. 2008;25(3):463–468, doi:10.1017/S0952523808080437.
 28. Zachí EC, Costa TL, Barboni MTS, Costa MF, Bonci DMO, Ventura DF. Color vision losses in autism spectrum disorders. *Front Psychol*. 2017;8(JUN):1127, doi:10.3389/fpsyg.2017.01127.
 29. Castelo-Branco M, Faria P, Forjaz V, Kozak LR, Azevedo H. Simultaneous comparison of relative damage to chromatic pathways in ocular hypertension and glaucoma: correlation with clinical measures. *Investig Ophthalmol Vis Sci*. 2004;45(2):499, doi:10.1167/iovs.03-0815.
 30. Duque-Chica GL, Gracitelli CPB, Moura ALA, et al. Inner and outer retinal contributions to pupillary light response: correlation to functional and morphologic parameters in glaucoma. *J Glaucoma*. 2018;27(8):723–732, doi:10.1097/IJG.0000000000001003.
 31. Barbur JL, Harlow AJ, Plant GT. Insights into the different exploits of colour in the visual cortex. *Proc R Soc London Ser B Biol Sci*. 1994;258(1353):327–334, doi:10.1098/rspb.1994.0181.
 32. Gaska J, Winterbottom M, van Atta A. *Operational Based Vision Assessment Cone Contrast Test: Description and Operation*. 2016, doi:10.21236/ADA635957.
 33. Matsumoto R, Saishin Y, Ohji M. Evaluation of acquired color vision deficiency in retinal vein occlusion using the Rabin cone contrast test. *Graefes Arch Clin Exp Ophthalmol*. 2021;259(10):2961–2966, doi:10.1007/s00417-021-05171-7.
 34. Salamone G, Di Lorenzo C, Mosti S, et al. Color discrimination performance in patients with Alzheimer's disease. *Dement Geriatr Cogn Disord*. 2009;27(6):501–507, doi:10.1159/000218366.
 35. Jack CR, Bennett DA, Blennow K, et al. NIA-AA research framework: toward a biological definition of Alzheimer's disease. *Alzheimer's Dement*. 2018;14(4):535–562, doi:10.1016/j.jalz.2018.02.018.
 36. McKhann GM, Knopman DS, Chertkow H, et al. The diagnosis of dementia due to Alzheimer's disease: recommendations from the National Institute on Aging-Alzheimer's Association workgroups on diagnostic guidelines for Alzheimer's disease. *Alzheimer's Dement*. 2011;7(3):263–269, doi:10.1016/j.jalz.2011.03.005.
 37. Chylack LT, Wolfe JK, Singer DM, et al. The Lens Opacities Classification System III. *Arch Ophthalmol*. 1993;111(6):831, doi:10.1001/archophth.1993.01090060119035.
 38. Barboni MTS, Pangen G, Ventura DF, Horn F, Kremers J. Heterochromatic flicker electroretinograms reflecting luminance and cone opponent activity in glaucoma patients. *Investig Ophthalmol Vis Sci*. 2011;52(9):6757, doi:10.1167/iovs.11-7538.
 39. Malloy-Diniz LF, Lasmar VAP, Gazinelli LDSR, Fuentes D, Salgado JV. The Rey Auditory-Verbal Learning Test: applicability for the Brazilian elderly population. *Rev Bras Psiquiatr*. 2007;29(4):324–329, doi:10.1590/S1516-44462006005000053.
 40. Ivnik RJ, Malec JF, Tangalos EG, Petersen RC, et al. The Auditory-Verbal Learning Test (AVLT): norms for ages 55 years and older. *Psychol Assess*. 1990;2(3):304–312, doi:10.1037/1040-3590.2.3.304.
 41. Folstein MF, Folstein SE, McHugh PR. "Mini-mental state": a practical method for grading the cognitive state of patients for the clinician. *J Psychiatr Res*. 1975;12(3):189–198, doi:10.1016/0022-3956(75)90026-6.
 42. Squarzone P, Faria DDP, Yassuda MS, et al. Relationship between PET-assessed amyloid burden and visual and verbal episodic memory performance in elderly subjects. *J Alzheimer's Dis*. 2020;78(1):229–244, doi:10.3233/JAD-200758.
 43. Klunk WE, Koeppe RA, Price JC, et al. The Centiloid Project: standardizing quantitative amyloid plaque estimation by PET. *Alzheimer's Dement*. 2015;11(1):1–15.e4, doi:10.1016/j.jalz.2014.07.003.
 44. Coutinho AM, Busatto GF, de Gobbi Porto FH, et al. Brain PET amyloid and neurodegeneration biomarkers in the context of the 2018 NIA-AA research framework: an individual approach exploring clinical-biomarker mismatches and sociodemographic parameters. *Eur J Nucl Med Mol Imaging*. 2020;47(11):2666–2680, doi:10.1007/s00259-020-04714-0.
 45. Faria D de P, Duran FL, Squarzone P, et al. Topography of 11C-Pittsburgh compound B uptake in Alzheimer's disease: a voxel-based investigation of cortical and white matter regions. *Brazilian J Psychiatry*. 2019;41(2):101–111, doi:10.1590/1516-4446-2017-0002.
 46. Busatto Filho G, Duran FL de S, Squarzone P, et al. Hippocampal subregional volume changes in elders classified using positron emission tomography-based Alzheimer's biomarkers of β -amyloid deposition and neurodegeneration. *J Neurosci Res*. 2021;99(2):481–501, doi:10.1002/jnr.24739.
 47. Rizzo M. Vision and cognition in Alzheimer's disease. *Neuropsychologia*. 2000;38(8):1157–1169, doi:10.1016/S0028-3932(00)00023-3.
 48. Cronin-Golomb A, Sugiura R, Corkin S, Growdon JH. Incomplete achromatopsia in Alzheimer's disease. *Neurobiol Aging*. 1993;14(5):471–477, doi:10.1016/0197-4580(93)90105-K.
 49. Pache M, Smeets CHW, Gasio PF, et al. Colour vision deficiencies in Alzheimer's disease. *Age Ageing*. 2003;32(4):422–426. Accessed October 23, 2017. <http://www.ncbi.nlm.nih.gov/pubmed/12851187>.
 50. Bassi CJ, Solomon K, Young D. Vision in aging and dementia. *Optom Vis Sci*. 1993;70(10):809–813. Accessed October 23, 2017. <http://www.ncbi.nlm.nih.gov/pubmed/8247482>.
 51. Massoud F, Chertkow H, Whitehead V, Overbury O, Bergman H. Word-reading thresholds in Alzheimer disease and mild memory loss: a pilot study. *Alzheimer Dis Assoc Disord*. 2002;16(1):31–39. Accessed October 23, 2017. <http://www.ncbi.nlm.nih.gov/pubmed/11882747>.
 52. Wijk H, Berg S, Bergman B, Hanson AB, Sivik L, Steen B. Colour perception among the very elderly related to visual and cognitive function. *Scand J Caring Sci*. 2002;16(1):91–102, doi:10.1046/j.1471-6712.2002.00063.x.
 53. Polo V, Rodrigo MJ, Garcia-Martin E, et al. Visual dysfunction and its correlation with retinal changes in patients with Alzheimer's disease. *Eye*. 2017;31(7):1034–1041, doi:10.1038/eye.2017.23.
 54. Unger RH, Flanagan PM, Khosravi M, Leverenz JB, Tousei B. Clinical and imaging characteristics associated with color

- vision impairment in Lewy body disease. *J Alzheimer's Dis*. 2019;72(4):1233–1240, doi:[10.3233/JAD-190727](https://doi.org/10.3233/JAD-190727).
55. Flanigan PM, Khosravi MA, Leverenz JB, Tousi B. Color vision impairment differentiates Alzheimer dementia from dementia with Lewy bodies. *J Geriatr Psychiatry Neurol*. 2018;31(2):97–102, doi:[10.1177/0891988718767579](https://doi.org/10.1177/0891988718767579).
 56. Mitchell AJ, Shiri-Feshki M. Rate of progression of mild cognitive impairment to dementia - meta-analysis of 41 robust inception cohort studies. *Acta Psychiatr Scand*. 2009;119(4):252–265, doi:[10.1111/j.1600-0447.2008.01326.x](https://doi.org/10.1111/j.1600-0447.2008.01326.x).
 57. Lewis DA, Campbell MJ, Terry RD, Morrison JH. Laminar and regional distributions of neurofibrillary tangles and neuritic plaques in Alzheimer's disease: a quantitative study of visual and auditory cortices. *J Neurosci*. 1987;7(6):1799–1808. Accessed October 28, 2017. <http://www.ncbi.nlm.nih.gov/pubmed/2439665>.
 58. Black SE. Focal cortical atrophy syndromes. *Brain Cogn*. 1996;31(2):188–229, doi:[10.1006/brcg.1996.0042](https://doi.org/10.1006/brcg.1996.0042).
 59. Pacheco-Cutillas M, Edgar DF, Sahraie A. Acquired colour vision defects in glaucoma—their detection and clinical significance. *Br J Ophthalmol*. 1999;83(12):1396–1402, doi:[10.1136/bjo.83.12.1396](https://doi.org/10.1136/bjo.83.12.1396).
 60. Verriest G. Further studies on acquired deficiency of color discrimination*. *J Opt Soc Am*. 1963;53(1):185, doi:[10.1364/JOSA.53.000185](https://doi.org/10.1364/JOSA.53.000185).
 61. Klunk WE, Engler H, Nordberg A, et al. Imaging brain amyloid in Alzheimer's disease with Pittsburgh Compound-B. *Ann Neurol*. 2004;55(3):306–319. doi:[10.1002/ana.20009](https://doi.org/10.1002/ana.20009).
 62. Varrone A, Asenbaum S, Vander Borgh T, et al. EANM procedure guidelines for PET brain imaging using [18F]FDG, version 2. *Eur J Nucl Med Mol Imaging*. 2009;36(12):2103–2110, doi:[10.1007/s00259-009-1264-0](https://doi.org/10.1007/s00259-009-1264-0).
 63. Fripp J, Bourgeat P, Acosta O, et al. Appearance modeling of 11C PiB PET images: characterizing amyloid deposition in Alzheimer's disease, mild cognitive impairment and healthy aging. *Neuroimage*. 2008;43(3):430–439, doi:[10.1016/j.neuroimage.2008.07.053](https://doi.org/10.1016/j.neuroimage.2008.07.053).
 64. Claassen DRW. Imaging brain metabolism and pathology in Alzheimer's disease with positron emission tomography. *J Alzheimer's Dis Park*. 2014;04(2):143, doi:[10.4172/2161-0460.1000143](https://doi.org/10.4172/2161-0460.1000143).
 65. Kremers J, Link B. Electroretinographic responses that may reflect activity of parvo- and magnocellular post-receptoral visual pathways. *J Vis*. 2008;8(15):11–11, doi:[10.1167/8.15.11](https://doi.org/10.1167/8.15.11).
 66. Brewer AA, Barton B. Visual cortex in aging and Alzheimer's disease: changes in visual field maps and population receptive fields. *Front Psychol*. 2014;5(FEB):74, doi:[10.3389/fpsyg.2014.00074](https://doi.org/10.3389/fpsyg.2014.00074).
 67. Rabin JC, Kryder AC, Lam D. Diagnosis of normal and abnormal color vision with cone-specific VEPs. *Transl Vis Sci Technol*. 2016;5(3):8, doi:[10.1167/tvst.5.3.8](https://doi.org/10.1167/tvst.5.3.8).
 68. Costa MF, Ventura DF, Perazzolo F, Murakoshi M, Silveira LCDL. Absence of binocular summation, eye dominance, and learning effects in color discrimination. *Vis Neurosci*. 2006;23(3-4):461–469, doi:[10.1017/S095252380623311X](https://doi.org/10.1017/S095252380623311X).