

Dental treatment of a Seven-Year-Old Child with Mastocytosis

Filomeni Anagnostou*/Zoi Daskalaki**/Athina Chatzigianni***Konstantinos N Arapostathis****

Aim: Mastocytosis is a rare disorder characterized by pathologic mast cell degranulation. This paper aims to present the dental management of a seven-year-old girl diagnosed with mastocytosis, in a hospital setting, yet without general anesthesia. **Case Report:** A seven-year-old girl, diagnosed with urticaria pigmentosa, was referred to a dental practice. Her parents' main concern was a possible allergic reaction to local anesthetics and antibiotics. It was decided to perform treatment in the operating theatre of a clinic without general anesthesia. Eight primary teeth were restored. The patient was monitored, and no complications occurred throughout the procedure. Follow-ups performed every three months for two years after treatment. Patient's oral hygiene was improved significantly. **Conclusion:** Collaboration between medical experts, patient's family and the pediatric dentist was crucial. The dentist must be aware of the medical history and potential triggering factors. Due to high probability for life-threatening emergencies, dental treatment in a hospital setting is recommended.

Keywords: Mastocytosis; Urticaria pigmentosa; Pediatric dental treatment

INTRODUCTION

Mast cells, also known as mastocytes, are immune cells triggered during allergy attacks. Mastocytosis is a heterogeneous group of clinical disorders that is characterized by a pathologic proliferation and accumulation of mast cells in a variety of tissues, most often the skin¹. The disease presents in two primary age-related patterns as follows: pediatric-onset mastocytosis and adult-onset mastocytosis, which may differ in their clinical manifestations and disease course. Pediatric-onset mastocytosis is commonly diagnosed prior to two years of age and usually consists of cutaneous disease, with urticaria pigmentosa (UP) the most common pattern, representing 70-90% of the cases². The term "urticaria pigmentosa" was introduced by Sangster in 1878³ because of the gross appearance of the lesions.

There is an equal gender distribution, and it seems that no race is predominant. Mastocytosis is considered to be an orphan disease and its cause is still unknown. There are no epidemiologic studies to define the precise incidence, point prevalence, or cumulative prevalence of mastocytosis in the general population. At the consensus meeting of mastocytosis experts in Boston 2010, a general cumulative prevalence of approximately one in 10,000 persons was estimated⁴. Because of the differences in diagnostic criteria and experience between departments, in many countries there is an attempt to create centers of excellence for the disease.

In regards to the onset age of mastocytosis, 60-80% of the patients have their onset during infancy and in some cases lesions, as well as mastocytomas, can be present at birth². The lesions in UP can be red, brown or yellow, oval or round, multiple in the form of nodules or single and their diameter can expand from a few millimeters to one or two centimeters. They usually affect the trunk and extremities, but they may be present in any skin or mucosal

*Filomeni Anagnostou, DDS, MSc, Pediatric Dentist, Thessaloniki, Greece.

**Zoi Daskalaki, DDS, Postgraduate Student, Department of Pediatric Dentistry, School of Dentistry, School of Health Sciences, Aristotle University of Thessaloniki, Greece

***Athina Chatzigianni, Assistant Professor, Department of Orthodontics, School of Dentistry, School of Health Sciences, Aristotle University of Thessaloniki, Greece

****Konstantinos Nikolaos Arapostathis, Associate Professor, Department of Pediatric Dentistry, School of Dentistry, School of Health Sciences, Aristotle University of Thessaloniki, Greece

Corresponding author

Filomeni Anagnostou

Dionysiou Solomou 7, Thessaloniki Greece (ZIP:55134)

Phone: (+30) 6936232479

Fax: (+30) 2310999582

E-mail: filia-a@hotmail.com

area. Patients have mast cell mediator-related symptoms such as erythema, swelling and blister formation spontaneously or after exposure to different stimuli. The Darier sign is associated with the disease due to the release of histamine, prostaglandins and leukotrienes from dermal mast cells, but is not present in all patients. In children, lesions tend to resolve by the age of ten years and if they appear after this age, they tend to persist⁵. It has been stated that total to partial resolution of pediatric-onset mastocytosis would happen in more than 50% of patients⁶. Diffuse cutaneous mastocytosis is more aggressive and the symptoms-usually systemic- can be more severe and persistent. Therapy is primarily symptomatic since no medication is curative.

Acute episodes of cyanosis and respiratory arrest are uncommon but can arise with acute mast cell activation events. Physical stimuli such as exercise, spicy food, exposure to high/low temperature, sunlight; chemical stimuli such as aspirin, radiographic dyes, non-steroidal anti-inflammatory agents and narcotics and also emotional factors such as anxiety and stress can be triggering factors, resulting even in life-threatening anaphylactic reactions⁷.

It is clear that in the dental environment fear and anxiety are usually present, especially in children. Invasive intervention in patients with mastocytosis should be avoided and when needed the dentist should always be aware of the medical history, take specific precautions to prevent mast cell activation and be ready to use resuscitative drugs in case of anaphylactic reaction. Fluids, epinephrine, antihistamines, and pressor agents are often required. Patients with mastocytosis are advised to wear medical alert bracelets and carry epinephrine-filled syringes with them.

Case Report

A seven-year-old girl was referred to a private pediatric dental practice in Thessaloniki. The girl was accompanied by her parents. Their main concern was that the girl may have an allergy to local anesthetics as well as antibiotics and according to her dentist's diagnosis she needed dental treatment. Thus, prior to proceeding to any dental procedure, it was reassured that the parents had brought an adrenaline shot with them. Furthermore, injectable epinephrine was also available in the dental office for the management of a potential anaphylactic shock⁸. There was not history of pain or swelling. The clinical and radiographic examination revealed poor oral hygiene and a total of 12 primary teeth (#51,52,54,55,61,62,64,65,74,75,84,85) affected by dental caries. Two bitewing radiographs were taken, revealing the proximity of caries to the pulp on the left mandibular first primary molar (Figure 1). She had a complete primary dentition and the first permanent upper and lower molars. The upper front teeth had mobility, but the girl had obviously delayed tooth eruption⁹. The mother reported that she brushes her daughter's teeth once a day with fluoridated toothpaste, but the child's diet included many intakes of sugar daily. The patient's level of cooperation was good enough, Frankl Scale: 3 (positive)¹⁰. The child didn't have any oral habits. A prophylaxis and fluoride treatment were accomplished in a second visit.

Medical History

The girl had a normal delivery at birth. Generalized skin lesions were observed by the family and the diagnosis of urticaria pigmentosa was made at the age of six months old by an allergist,

Figure 1: Intraoral radiographs.

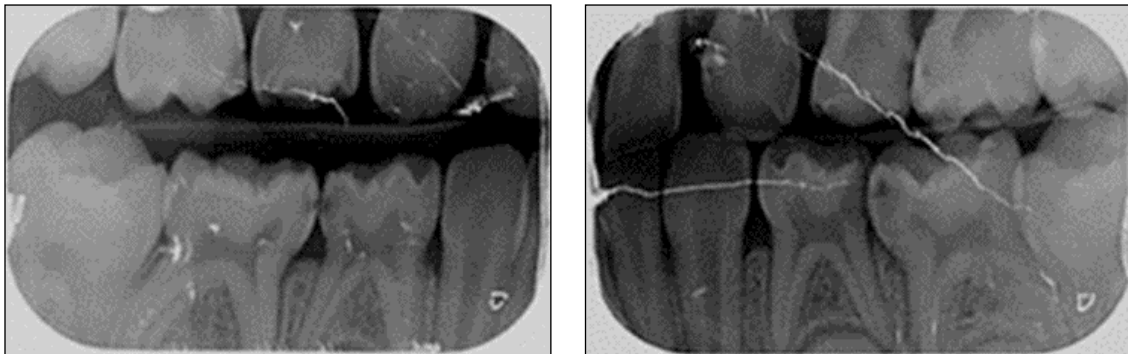
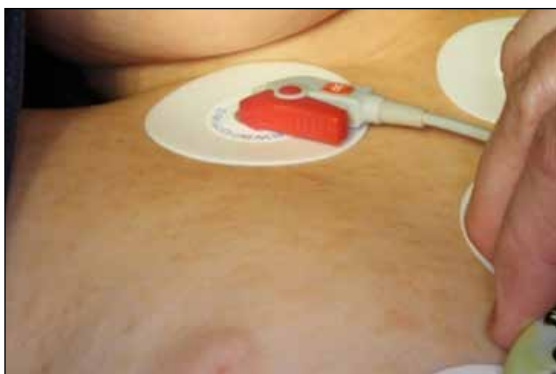

Figure 2: Extended maculopapular lesions -characteristic of mastocytosis- over the girl's trunk and neck.



based also on positive Darier's sign. The patient's daily medication included 5ml of an antihistamine syrup (rupatadine) and application of a hydrocortisone cream. There were multiple, sized from one to five millimeters maculopapular lesions concentrated mainly over her trunk and her neck (Figure 2). The lesions were yellowish-pale red in color. There was a positive history of allergies to aspirin, amoxicillin, foods, and high temperature. The patient's weight was 26kg. She was hospitalized in the past for flu complications, but she had never been treated with general anesthesia. The child was followed closely by a pediatrician and an allergist. At school and outdoor activities, she was supervised by a nurse, who always had an adrenaline shot with her in case of emergency.

Dental Treatment

In order to improve the patient's oral hygiene level, instructions were given to brush twice a day (day and night) with a 1450 ppm F fluoridated toothpaste. Brushing as well as flossing was demonstrated to the mother. The necessity for regular recall examinations and professional application of fluoride varnish every three months was underpinned. Additionally, dietary consultation was provided so the patient with the help of her parents could build healthy eating habits. The restorative treatment plan included fissure sealants on the first permanent molars (ClinproSealant, 3M ESPE); pulpotomy with ferric sulfate on #74 and aesthetic restorations with resin modified glass-ionomer cement (Vitremmer, 3M ESPE) on #54,55,64,65,84,85,74 and 75.

Due to the numerous anaphylactic triggers, the treatment in the private dental practice would be too risky. Also, the parents weren't willing to have their child treated under general anesthesia (GA). After consultation with a pediatric anesthesiologist and the girl's allergist and taking into consideration the girl's cooperation, it was suggested that the treatment would be completed in the operating theatre of a hospital without GA, but under close monitoring during the whole procedure. According to her allergist, the child was pre-medicated with hydroxyzine (25 mg Atarax 1-2mg/kg for children <12 years old) and prednisolone (12mg Prezolon for children <12 years old), which have antihistamine and sedative effects; Montelukast (5mg Singulair for children six to sixteen years old), ranitidine (20mg Zantac for children <12 years old) followed by the administration of 200mg paracetamol.

Peripheral venous access was obtained for administration of drugs if requisite. The dental treatment was planned per quadrant, and it was done using rubber dam isolation. The maxillary teeth were finally treated with local anesthesia using infiltration with 4% articaine and adrenaline 1:200.000 (Ubistesin, 3M ESPE). For the mandibular teeth, inferior alveolar nerve block was administered using the same anesthetic agent. Approximately 3,4 ml were administered totally. No other sedative was used. The restorations were completed in a single session lasting about 2,5 hours.

The patient was quite cooperative but because of the extent of the restorations she finally got tired. The pediatric dentist as well as the assistants used basic behavior management techniques such as tell-show-do, positive reinforcement and distraction with the use of imagination¹¹.

After supervision in the recovery room, the child remained in the hospital postoperatively for eight hours. She was then discharged to the care of her parents.

The patient was seen every three months for dental prophylaxis and professional fluoride application for two and half years after treatment. Clinical evaluation revealed an improved oral hygiene level and no dental pathologies. Panoramic radiograph last year revealed no other pathologies except ectopic eruption and tooth size discrepancy of tooth #22.

DISCUSSION

Mastocytosis is usually diagnosed by hematologists or dermatologists. Children with mastocytosis should be monitored regularly by an allergist and their parents should be trained in how to manage attacks. Given their high propensity anaphylaxis, patients with mastocytosis should be tested for allergies prior to any dental treatment¹². However, data may be difficult to interpret, and tests may be invaluable. A retrospective review of 64 patients with mastocytosis (31 children and 33 adults) correlated a severity scoring system with tryptase levels¹³. Serum tryptase levels are a reflection of mast cell burden and can serve as a reference point really valuable in the diagnosis of the disease and of possible anesthesia-associated adverse events¹⁴. Levels of tryptase higher than the normal range (11–15 ng/mL) may indicate an increased mast cell burden and/or extensive level of degranulation².

Patients with urticaria pigmentosa may be susceptible to cardiovascular collapse due to excessive histamine release from mast cells, even during their stay at the dental office. Dental anxiety and emotional stress are probably the most concerning triggers, as they may cause severe reactions¹⁵. Symptoms are quite variable, ranging from mild pruritus to abdominal pain, or even anaphylaxis.

Several allergens have been identified on the dental office. Latex, zinc oxide, eugenol, nickel, chromium and even titanium have been related to allergic reactions on patients^{16,17}. In order to avoid a delayed allergic reaction to nickel or chromium, we preferred restoration with resin modified glass-ionomer cement on #74 instead of a stainless-steel crown as indicated. Also, drugs commonly used and prescribed like local anesthetics, non-steroidal anti-inflammatory drugs and antibiotics have been reported as triggers for mast cell activation^{12,17}. Thus, the main goal in treating a child with mastocytosis is avoiding triggers that cause acute mediator release.

Although there are in the published literature cases where patients are treated under GA without any complication^{15,18,19}, previous reports had presented a number of side effects including anaphylaxis, cardiovascular collapse, bleeding and even death^{20,21}. Because mast cells are implicated in the pathophysiology of anaphylaxis and patients with mastocytosis have an increased mast cell burden, drugs used in anesthesia degranulate mast cells and raise justified concerns about potential adverse reactions¹⁴. The incidence of anaphylaxis is much higher on patients with mastocytosis²². Thus, treating them in a non-hospital environment can be perilous. In this case, GA was not preferred as too risky. Instead, we decided to provide dental treatment in the operating theatre of a private hospital clinic in order to allow both meticulous monitoring and systematic desensitization of the dental procedures. Of course, to take such a decision, consultation with the medical team and written consent of the parents are necessary.

Patients submitted to high-risk procedures should be premedicated with H1 and H2 blockers at maximum dose and if necessary, diazepam derivatives, as they can be useful in order to prevent

stress-induced mast cell mediator release^{12,23}. It is also recommended to have adrenaline ready to use in case of emergency. H1 antihistamines, such as hydroxyzine, inhibit the effects of histamine on capillary permeability and they also possess local anesthetic activity. The side effect with the highest incidence of all H1 blockers is sedation¹⁵. H2 antihistamines, for instance ranitidine, are indicated for amelioration of gastrointestinal symptoms including bleeding and peptic ulcer. Those symptoms are derived from the increased secretion of gastric acid secondary to increased histamine levels.

In local anesthesia we used the minimum required dose of articaine per quadrant. If local anesthesia is needed amide-type anesthetic agents are recommended and not ester-linked. There is no reason to avoid local anesthetic nerve block, while the vasoconstrictor (like adrenaline or epinephrine), is useful in case histamine release occurs. Medically indicated drugs should not be eliminated from therapeutic consideration unless there is a clear prior history of sensitivity².

Patients suffering from mast cell disease may be more prone to particular oral pathologies, such as periodontal disease, jaw osteoporosis. Medications can make them more susceptible to dental caries and mucosal lesions¹². Antihistamines have been shown to greatly affect salivary glands in result of the diminishing of histaminic effects on salivary secretion²⁴. Xerostomia may increase susceptibility to dental caries, candidiasis and other infections, and mucosal inflammation²⁵. These patients should be submitted to regular dental examinations. Our patient's parents were given meticulous oral hygiene instructions, including the need to use a fluoridated dentifrice and to brush twice daily in order to prevent caries and gingivitis.

CONCLUSION

In children with mastocytosis, mast cells are triggered much more easily and that causes allergy-like symptoms. The dentist should be aware of the medical history especially the duration and the factors provoking mediator release. The fear of reactions to drugs and materials used in procedures for the benefit of the patient must be evaluated, placed in perspective, and not be allowed to interfere with optimal patient care. Team approach is recommended in treating patients with mastocytosis, ideally in a hospital setting, with or without general anesthesia. H1 and H2 blockers can restrict mast cell degranulation, however dental staff and family should always be prepared to face an anaphylaxis reaction.

REFERENCES

1. Longley J, Duffy TP, Kohn S. The mast cell and mast cell disease. *J Am Acad Dermatol*, 1988; 32:545-561.
2. Castells M, Metcalfe DD, Escribano L. Diagnosis and treatment of cutaneous mastocytosis in children-Practical Recommendations. *Am J Clin Dermatol*, 2011; 12(4):259-270.
3. Sangster A. An anomalous mottled rash, accompanied by pruritus, factitious and pigmentation, 'urticaria pigmentosa'. *Trans Clin Soc Lond*, 1878; 11:161-163.
4. Brockow K. Epidemiology, Prognosis, and Risk Factors in Mastocytosis. *Immunol Allergy Clin N Am*, 2014; 34:283-295.
5. Soter NA. The skin in mastocytosis. *J Invest Dermatol*, 1991; 96(3):32S-38S.
6. Uzzaman A, Maric I, Noel P, et al. Pediatric-onset mastocytosis: a long term clinical follow-up and correlation with bone marrow histopathology. *Pediatr Blood Cancer*, 2009; 53(4):629-634.
7. Pauls JD, Brems J, Pockros PJ, Saven A, Wagner RL, Weber R, et al. Mastocytosis diverse presentations and outcomes. *Arch Intern Med*, 1999; 159:401-405.
8. American Academy of Pediatric Dentistry (AAPD). Management of medical emergencies. The Reference Manual of Pediatric Dentistry. Ed. American Academy of Pediatric Dentistry, Chicago, 2020; 600-601.
9. Suri L, Gagari E, Vastardis E. Delayed tooth eruption: Pathogenesis, diagnosis, and treatment. A literature review. *Am J Orthod Dentofacial Orthop*, 2004; 126(4):432-445.
10. Klingberg G. Dental anxiety and behaviour management problems in paediatric dentistry: a review of background factors and diagnostics. *Eur Arch Paediatr Dent*, 2007; 8(4):11-15.
11. American Academy of Pediatric Dentistry (AAPD). Behavior guidance for the pediatric dental patient. The Reference Manual of Pediatric Dentistry. Ed. American Academy of Pediatric Dentistry, Chicago, 2020; 292-310.
12. Rama TA, Corle-Real I, Gomes PS, Escribano L, Fernandes MH. Mastocytosis: oral implications of a rare disease. *J Oral Pathol Med*, 2011; 40:441-450.
13. Heide R, van Doorn K, Mulder PG, et al. Serum tryptase and SCORMA (SCORingMAstocytosis) Index as disease severity parameters in childhood and adult cutaneous mastocytosis. *Clin Exp Dermatol*, 2009; 34(4):462-468.
14. Carter MC, Uzzaman A, Scott LM, Metcalfe DD, Quezado Z. Pediatric Mastocytosis: Routine anesthetic management for a complex disease. *Anesth Analg*, 2008; 107(2):422-427.
15. Nelson LP, Savelli-Castillo I. Dental management of a pediatric patient with mastocytosis: a case report. *Pediatr Dent*, 2002; 24:343-346.
16. Munksgaard EC. Toxicology versus allergy in restorative dentistry. *Adv Dent Res*, 1992; 6:17-21.
17. Ring J, Franz R, Brockow K. Anaphylactic reactions to local anesthetics. *Chem Immunol Allergy*, 2010; 95:190-200.
18. Coleman MA, Libberthson RR, Crone RK, Levine FH. General anesthesia in a child with urticaria pigmentosa. *Anesth Analg*, 1980; 59(9):704-706.
19. Davidovich E, Ronin L, Ram D. Mastocytosis-oral and dental manifestations and medical considerations for dental treatment: a case report. *J Disabil Oral Health*, 2007; 8(3):124-128.
20. Auvray L, Letourneau B, Freysz M. Mastocytosis: general anesthesia with remifentanyl and sevoflurane. *Ann Fr Anesth Reanim*, 2001; 20:635-638.
21. Borgeat A, Ruetsch YA. Anesthesia in a patient with malignant systemic mastocytosis using a total intravenous anesthetic technique. *Anesth Analg*, 1998; 86:442-444.
22. Brockow K, Jofer C, Behrendt H, Ring J. Anaphylaxis in patients with mastocytosis: a study on history, clinical features and risk factors in 120 patients. *Allergy*, 2008; 63:226-232.
23. Heide R, Beishuizen A, De Groot H, et al. Mastocytosis in children: A protocol for management. *Pediatr Dermatol*, 2008; 25(4):493-500.
24. Kim JH, Park SH, Moon YW, et al. Histamine H1receptor induces cytosolic calcium increase and aquaporin translocation in human salivary gland cells. *J Pharmacol Exp Ther*, 2009; 330:403-412.
25. Jorgensen GH, Arnlaugsson S, Theodors A, Ludviksson BR. Immunoglobulin A deficiency and oral health status: a case-control study. *J Clin Periodontol*, 2010; 37:1-8.