

Lung Transplantation for Pulmonary Veno-Occlusive Disease Without Hemodynamic Changes: A Case of Radiographic Findings Preceding Vascular Changes

Martin Y. Rofael

Department of Medicine, University of California Irvine, Irvine, CA

Travis Henry

Department of Radiology and Biomedical Imaging, Duke University, Durham, NC

Alyssa A. Perez

Department of Medicine, University of California San Francisco, San Francisco, CA

Lorriana E. Leard

Department of Medicine, University of California San Francisco, San Francisco, CA

Jasleen Kukreja

Department of Surgery, University of California San Francisco, San Francisco, CA

Kirk D. Jones

Department of Pathology and Laboratory Medicine, University of California San Francisco, San Francisco, CA

Teresa De Marco

Department of Medicine, University of California San Francisco, San Francisco, CA

Nicholas A. Kolaitis

Department of Medicine, University of California San Francisco, San Francisco, CA

We present a case of pulmonary veno-occlusive disease, with classic findings on cross-sectional imaging, but the absence of any hemodynamic changes. Given the high clinical suspicion for pulmonary veno-occlusive disease, this patient was referred for lung transplantation despite the absence of hypoxemia, and despite the normal pulmonary vascular resistance. His clinical picture progressed rapidly without the development of significant hemodynamic abnormalities. Fortunately, he was transplanted before fulminant respiratory failure, with the explant confirming granulomatous pulmonary veno-occlusive disease as the diagnosis. Early referral for transplantation is needed when pulmonary veno-occlusive disease is suspected, even in the absence of hemodynamic changes.

CASE PRESENTATION

A 52-year-old male nonsmoker presented with progressive dyspnea, cough, and wheezing over the preceding 7 months. He reported no fevers, chills, night sweats, weight loss, joint stiffness, or rashes. History was notable for

biopsy-proven neurosarcoidosis, diagnosed 9 years prior, for which he was in remission and off immunosuppression. Aside from the history of sarcoidosis, there were no risk factors for cardiac disease or diastolic dysfunction. Physical examination was remarkable only for minimal bilateral lower extremity edema. He had no hypoxemia. Spirometry and diffusing capacity for carbon monoxide ($D_{L,CO}$) were normal. He walked 400 m without desaturations on his 6-minute walk test.

Laboratory investigation was notable for an elevated erythrocyte sedimentation rate of 52 mm/h (normal 0-10 mm/h) and a C-reactive protein of 11.6 mg/L (normal <5.1 mg/L). His B-type natriuretic peptide (BNP) was normal at 6 pg/mL. Vitamin D, 25-hydroxy; Vitamin D, 1,25-dihydroxy; and both serum and cerebral spinal angiotensin converting enzyme were normal. Infectious workup was unrevealing.

Chest computed tomography (CT) scan revealed interlobular septal thickening, ground glass opacities (GGOs), lymphadenopathy, peri-bronchial

cuffing, and pleural effusions, highly suggestive of pulmonary veno-occlusive disease (PVOD) (Figure 1A). Thoracic echo (TTE) revealed mild left ventricular hypertrophy, and normal left ventricular function with an ejection fraction of 60% to 65%. There was no diastolic dysfunction. Right ventricular systolic function was also normal, with an estimated pulmonary artery systolic pressure of 36 mm Hg. Positron emission tomography CT showed no active sarcoidosis. Multiple large bilateral mismatched defects were noted on ventilation-perfusion scan (Figure 1B).

Given concern for PVOD, the patient underwent right heart catheterization (RHC), which showed mean pulmonary artery pressure of 28 mm Hg, pulmonary capillary wedge pressure (PCWP) of 15 mm Hg, pulmonary vascular resistance (PVR) of 1.69 Wood units, and cardiac output (CO) of 7.67 L/min, measured by averaging 3 separate thermodilution values. When measured by indirect Fick, the CO was 6.60 L/min, yielding a PVR of 1.97. There was no significant change after vasodilator therapy. The PCWP measurement was confirmed by measurement of a PCWP saturation, which showed a jump in saturation

Key Words—lung transplantation, pulmonary veno-occlusive disease
Correspondence: nicholas.kolaitis@ucsf.edu

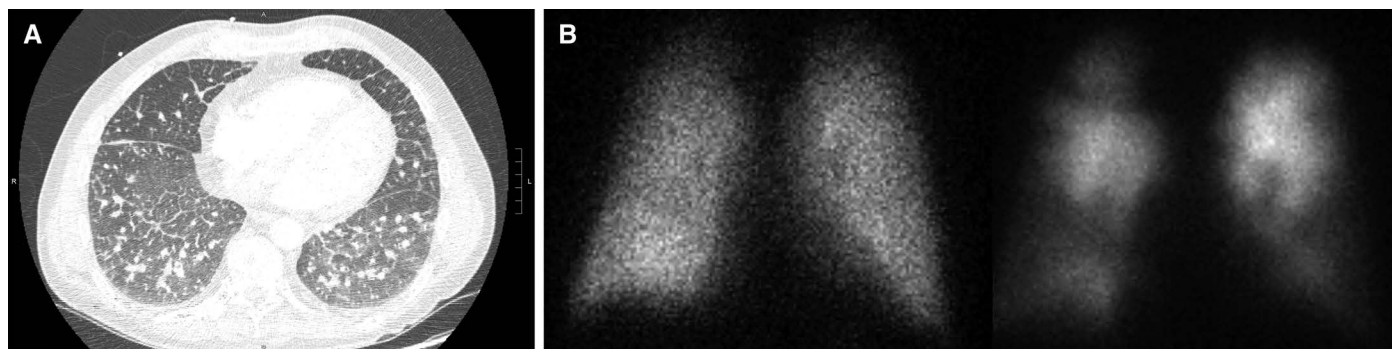


Figure 1: (A) Chest computed tomography with centrilobular ground glass nodules and interlobular septal thickening. (B) Ventilation (left)–perfusion (right) scan with multiple large bilateral mismatched defects.

from 74.8% in the pulmonary artery to 96.2% in the pulmonary capillary wedge position. Pulmonary angiography demonstrated no filling defects. The patient underwent endobronchial ultrasound-guided transbronchial needle aspiration of a station VII lymph node, without evidence of infection, malignancy, or granulomas. While the RHC was not consistent with an elevated PVR, the clinical picture was felt to represent PVOD, with imaging findings preceding hemodynamic changes. Therefore, the patient was referred simultaneously for surgical lung biopsy and lung transplant evaluation.

His symptoms rapidly progressed, and evaluation 6 weeks from initial presentation revealed worsening hypoxemia requiring 4 L/min at rest and 15 L/min with exertion. A TTE at the time showed right ventricular enlargement, and a pulmonary artery systolic pressure > 60 mm Hg. Given the rapidity of progression, he was hospitalized for expedited lung transplant evaluation. Repeat RHC showed a showed mean

pulmonary artery pressure of 35 mm Hg, PCWP of 12 mm Hg, PVR of 2.8 Wood units, and CO of 7 L/min by thermodilution and 6.7 L/min by indirect Fick. His BNP increased 12-fold to 74 pg/mL. After completion of his workup, he was rapidly listed for transplant without tissue confirmation of PVOD, and underwent bilateral lung transplant 2 weeks later. Pathologic examination of the explanted lung showed diffuse obliteration of pulmonary veins within interlobular septa, nonnecrotizing granulomas, and perivascular fibrosis (Figure 2).

DISCUSSION

We present this case of a patient with a history of neurosarcoidosis in remission, who presented with progressive dyspnea, and a chest CT suggestive of PVOD. Notably, the imaging findings of PVOD preceded any hemodynamic manifestations, which has only been described once before.¹ Unlike the previously reported case, this patient developed rapidly progressive hypoxemia

and required emergent lung transplant. Explanted lung pathology confirmed granulomatous PVOD.

Sarcoidosis is a granulomatous disorder of unknown etiology that can involve any organ. Sarcoidosis can lead to pulmonary hypertension (PH), most often as pulmonary arterial hypertension secondary to advanced pulmonary fibrosis, and rarely as PVOD.²⁻⁴ PVOD is a subset of PH characterized typically by intimal proliferation, thrombosis, and obliteration of the intralobular veins.⁵ PVOD has multiple etiologies including autoimmune disorders, chemotherapy, and as an inherited condition.⁴ Symptoms of PVOD are nonspecific. Radiographic findings include GGOs, interlobular septal thickening, lymphadenopathy, and less likely pericardial and pleural effusions.⁶ Ventilation-perfusion scans may show mismatches, which are not seen with pulmonary angiograms.⁷ Pulmonary function tests often show a severely reduced $D_{L,CO}$.² The presence of postcapillary blockage can lead to alveolar hemorrhage in

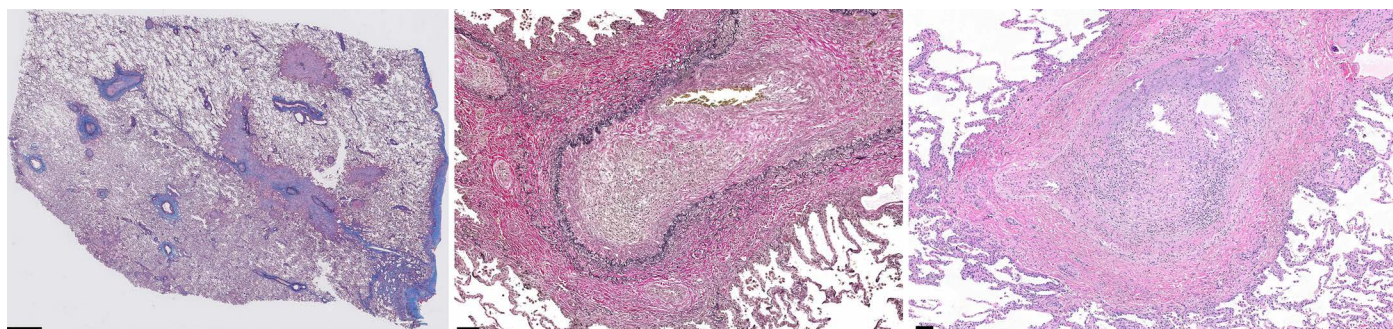


Figure 2: Low-power view (left) shows complete obliteration of interlobular pulmonary veins by non-necrotizing granulomas and fibrosis (Elasticchrome, scale bar = 2 mm). The pulmonary veins show filling and obliteration of lumens by nonnecrotizing granulomas (middle: Verhoeff-Van Gieson, scale bar = 100 microns, and right: hematoxylin and eosin, scale bar = 100 microns).

PVOD, so transbronchial lung biopsies are not recommended.⁸ Mainstay pulmonary arterial hypertension therapies, such as vasodilators, may conversely lead to increased capillary congestion leading to life-threatening pulmonary edema.^{8,9} PVOD has a poor prognosis and lung transplant is the best available treatment.¹⁰

Sarcoidosis-associated PVOD is characterized by noncaseating granulomas involving intralobular veins and fibrointimal changes of small venules causing luminal obliteration.^{4,11-13} In a postmortem study of 40 patients with sarcoidosis, 65% had granulomatous invasion of pulmonary venules.¹⁴ Despite this, the frequency of clinically significant pulmonary arterial hypertension and PVOD is low. Studies suggested that PH from sarcoidosis can be from pulmonary fibrosis, or in the absence of it, as is the case with granulomatous infiltration of the pulmonary vascular system.⁴

The decision to treat sarcoid-related PVOD with steroids is controversial. Reports suggest that pulse steroids may not change progression of disease.¹³ Others suggest that steroids may stabilize symptoms, though recurrence may occur with tapering.^{4,11,12} One study noted that response to steroids, disease burden, and normalized pulmonary pressures on RHC occurred only in patients without fibrotic changes, suggesting that the nonfibrotic phenotype may respond to steroids.⁴ Before we listed this patient for transplantation we had a multidisciplinary conversation with our internal sarcoidosis expert, as well as 2 sarcoidosis experts at other academic centers. All 3 sarcoidosis experts independently agreed that steroids would not have been helpful. As such, the patient was not given a trial of steroids given the concern that it would delay transplantation, would likely not change the clinical course, and would pose increased risks of infection posttransplantation. Although steroids may be reasonable to consider in other less advanced patients without sig-

nificant pulmonary fibrosis, our patient's explant demonstrated severe intimal fibrosis in the postcapillary venules, confirming that steroids would have had little benefit even if they had been given.

In prior reports of sarcoidosis-associated PVOD, pulmonary hypertension was noted on TTE or RHC and correlated with symptoms well before diagnosis of PVOD. In our case, chest CT scan strongly suggested PVOD, despite an initially normal BNP, $D_{L,CO}$, TTE, and PVR on RHC. Guidelines recommend chest CT scan as part of the PH workup, and the combination of GGOs, interlobular septal thickening, and mediastinal lymphadenopathy is 95% sensitive and 89% specific for PVOD.¹⁵ Random zonal predominance and preferential centrilobular distribution of GGOs are more specific, while pericardial and pleural effusions are less specific.⁶ Our patient's symptoms, and PVOD imaging findings, preceded objective changes in pulmonary vascular pressures. Evidence of PH on his TTE and RHC were very late findings, after significant and rapid clinical worsening. Our high clinical index of suspicion for PVOD led to early referral for transplant evaluation, and without this early referral the patient would likely have died before completing his transplant evaluation.

This case highlights that sarcoidosis-related PVOD may occur even in the absence of markers of active sarcoidosis and should always be considered in any patient with a history of sarcoidosis, no matter how remote. It also highlights the need for early referral for lung transplantation in patients with suspected PVOD, even when hemodynamic changes are not present.

References

1. Beshay S, Humbert M, Barrios R, Sahay S. Progression of pulmonary veno-occlusive disease without pulmonary hypertension. *Pulm Circ.* 2022;12(1):e12046.
2. Rapti A, Kouranos V, Gialafos E, et al. Elevated pulmonary arterial systolic pressure

- in patients with sarcoidosis: prevalence and risk factors. *Lung.* 2013;191(1):61-67.
3. Huitema MP, Bakker ALM, Mager JJ, et al. Prevalence of pulmonary hypertension in pulmonary sarcoidosis: the first large European prospective study. *Eur Respir J.* 2019;54(4).
4. Nunes H, Humbert M, Capron F, et al. Pulmonary hypertension associated with sarcoidosis: mechanisms, haemodynamics and prognosis. *Thorax.* 2006;61(1):68-74.
5. Burke AP, Farb A, Virmani R. The pathology of primary pulmonary hypertension. *Mod Pathol.* 1991;4(2):269-282.
6. Resten A, Maitre S, Humbert M, et al. Pulmonary hypertension: CT of the chest in pulmonary venoocclusive disease. *AJR Am J Roentgenol.* 2004;183(1):65-70.
7. Bailey CL, Channick RN, Auger WR, et al. "High probability" perfusion lung scans in pulmonary venoocclusive disease. *Am J Respir Crit Care Med.* 2000;162(5):1974-1978.
8. Palmer SM, Robinson LJ, Wang A, Gossage JR, Bashore T, Tapson VF. Massive pulmonary edema and death after prostacyclin infusion in a patient with pulmonary veno-occlusive disease. *Chest.* 1998;113(1):237-240.
9. Montani D, Achouh L, Dorfmueller P, et al. Pulmonary veno-occlusive disease: clinical, functional, radiologic, and hemodynamic characteristics and outcome of 24 cases confirmed by histology. *Medicine (Baltimore).* 2008;87(4):220-233.
10. Huertas A, Girerd B, Dorfmueller P, O'Callaghan D, Humbert M, Montani D. Pulmonary veno-occlusive disease: advances in clinical management and treatments. *Expert Rev Respir Med.* 2011;5(2):217-229; quiz 230-211.
11. Crissman JD, Koss M, Carson RP. Pulmonary veno-occlusive disease secondary to granulomatous venulitis. *Am J Surg Pathol.* 1980;4(1):93-99.
12. Dwyer N, Smith R, Challis D, Reid D, Kilpatrick D. Granulomatous angiitis leading to a pulmonary veno-occlusive disease-like picture. *Eur Respir J.* 2009;33(3):666-669.
13. Portier F, Lerebours-Pigeonniere G, Thiberville L, et al. Sarcoidosis simulating a pulmonary veno-occlusive disease [in French]. *Rev Mal Respir.* 1991;8(1):101-102.
14. Takemura T, Matsui Y, Saiki S, Mikami R. Pulmonary vascular involvement in sarcoidosis: a report of 40 autopsy cases. *Hum Pathol.* 1992;23(11):1216-1223.
15. Mineo G, Attina D, Mughetti M, et al. Pulmonary veno-occlusive disease: the role of CT. *Radiol Med.* 2014;119(9):667-673.