

Suspected True Hermaphroditism in a Free-ranging Gray Wolf (*Canis lupus*) in Interior Alaska, USA

Bridget L. Borg,^{1,3} Kaija J. Klauder,¹ and Kimberlee B. Beckmen² ¹Denali National Park and Preserve, PO Box 9, Denali Park, Alaska 99755, USA; ²Alaska Department of Fish and Game, Division of Wildlife Conservation, 1300 College Road, Fairbanks, Alaska 99701, USA; ³Corresponding author (email: bridget_borg@nps.gov)

ABSTRACT: Hermaphroditism or intersexuality occurs endogenously in most mammal species. We document the behavior and physical and anatomic appearance of a suspected true hermaphroditic free-ranging wild gray wolf (*Canis lupus*) in Denali National Park and Preserve, Alaska, USA.

Hermaphroditism or intersexuality occurs when internal or external genitalia do not match the gonads and sex chromosome complement. True hermaphrodites have both ovarian and testicular tissue; male pseudohermaphrodites have testes and female external genitalia; and female pseudohermaphrodites have ovaries and male external genitalia (Mickelsen and Memon 1995; Kustritz 2003).

True hermaphroditism has been documented in humans (Krob et al. 1994), domestic animals (Lee et al. 2013; Costa et al. 2017), and occasionally in wild animals (De Guise et al. 1994; Pajares et al. 2009). There is one documented case in a cloned gray wolf (*Canis lupus*; Kang et al. 2012). We describe a free-ranging wild gray wolf with characteristics of true hermaphroditism in Denali National Park and Preserve, Alaska, US.

Gray wolves have been monitored and researched in Denali since the 1930s, with long-term, continuous monitoring since 1986 (Murie 1944; Mech et al. 1998; Meier et al. 2009). Denali National Park biologists maintain radio collars (Telonics, Inc., Mesa, Arizona, USA) on one or more wolves in each pack in the Denali study area by conducting annual or biannual capture operations. On 4 March 2013, a wolf from the McKinley Slough pack, Denali, was anesthetized by aerial darting and radio-collared following protocols in Meier et al. (2009) under NPS IACUC (National Park Service IACUC : <https://www.nps.gov/orgs/1103/iacuc.htm>) approval (AKR_YUCH and DENA_Burch_Wolves_2013)

and given the identifier wolf 1306. Wolf 1306 was considered in excellent body condition, weighing 52.6 kg (within approximately the top 15% of weights of wolves captured in Denali from 1986 to 2022). Based on tooth wear (Gipson et al. 2000), we estimated wolf 1306's date of birth to be May 2009 (i.e., approximately 3 yr and 10 mo old when collared). Based on physical size and behavior leading the other pack members, we suspected wolf 1306 was the breeding male of the McKinley Slough pack. Wolf 1306 appeared masculine in body size and physical characteristics (Mech 2006, Supplementary Material Table 1), but without a scrotum or external testes. The prepuce did not cover the apparent penis, which was small and mishappen (Fig. 1A). Wolf 1306 was assigned a male gender for our records at the time.

The McKinley Slough pack consisted of five wolves in spring 2013 and four wolves in fall 2013. In spring 2014, wolf 1306 (identity confirmed by GPS collar locations and collar visible in photos) was documented by a motion-activated trail camera (Reconyx PC900 HyperFire Professional IR) mounting another wolf multiple times but not achieving a copulatory tie (Fig. 2). By late March 2014, the McKinley Slough pack consisted only of wolf 1306 and newly collared female wolf 1402, presumed to be the wolf observed in the photos earlier that spring. The pair remained together for almost 3 yr but without producing any pups or showing denning behavior. In January 2017, wolf 1402 joined the neighboring Grant Creek pack; wolf 1306 was alone from January to February 2017. On 5 February 2017, wolf 1306 was seen via aerial tracking feeding on old kill. Two members of the resident Riley Creek West pack were initially resting 400 yards away on a ridge, then chased wolf 1306 off the kill, returned, and fed. Based on GPS collar data, wolf 1306 died on 16 February 2017, at an

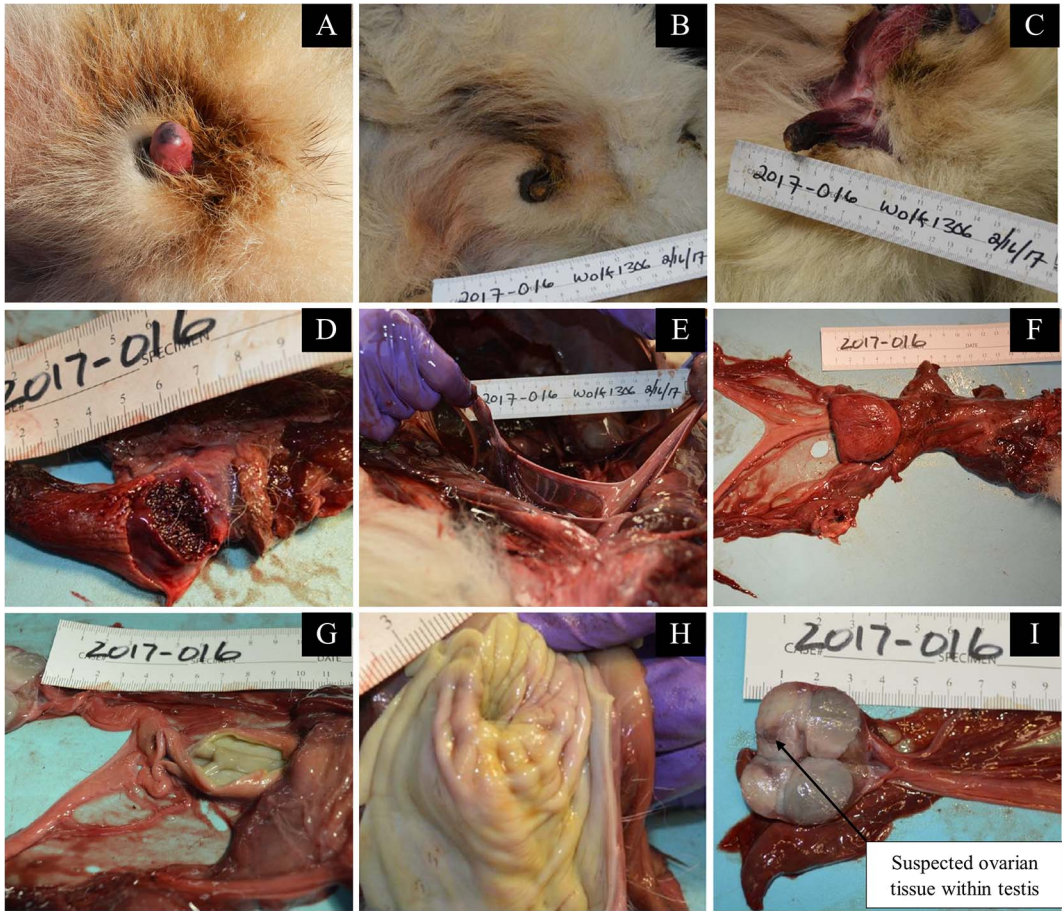


FIGURE 1. External and gross necropsy images of genitalia from gray wolf (*Canis lupus*) 1306. Wolf 1306 was a free-ranging wild wolf and a suspected true hermaphrodite from Denali National Park and Preserve, Alaska, USA. (A) External genitalia of wolf 1306 at time of capture, 4 March 2013. (B) External genitalia of wolf 1306 during gross necropsy. (C) External genitalia of wolf 1306 with sheath or vulva opened. (D) Cut section of the external genitalia grossly consistent with a corpus cavernosum 1306. (E) Uterus of wolf 1306 in situ. (F) Reproductive tract with urinary bladder of wolf 1306, excised. (G) Body of uterus of wolf 1306. (H) Cervix and vagina mucosa of wolf 1306. (I) Left reproductive organ (suspected ovotestis) incised, with arrow indicating suspected ovarian tissue within outer testicular tissue.

estimated age of 7 yr 9 mo. The carcass was frozen in situ and recovered 24 March 2017.

Wolf 1306 was brought to the Alaska Department of Fish and Game Division of Wildlife Conservation, Fairbanks, Alaska, US, on 30 March 2017 for necropsy. Tissue samples were fixed in 10% neutral buffered formalin, sectioned to 6 μ m, and stained with H&E.

Cause of death was determined to be starvation and peritonitis secondary to a penetrating wound to the jejunum, probably caused by other wolves during an altercation; there was no evidence of a penetrating foreign body or

human involvement. Grossly, the reproductive organs suggested a true hermaphrodite or female pseudohermaphrodite. What was originally identified at capture as a misshapen external os penis appeared consistent with an os clitoris at necropsy. It was 70 mm long and L shaped. The tip of the organ was frostbitten, dark and desiccated, and the urethral opening could not be located (Fig. 1B–D). The tip of the organ was ventral to the abdominal midline, neither directed cranially as typical of a penis nor completely in the caudoventral position of a normal clitoris in the vulva. The sheath was vulva-like,



FIGURE 2. Suspected true hermaphroditic gray wolf (*Canis lupus*) 1306 mounting another wolf on 2 March 2014 in Denali National Park and Preserve, Alaska, USA.

incompletely extending over this organ. There was no evidence of a scrotum. Internally, there was a bicornate uterus with an enlarged uterine body (Fig. 1E, F), lacking a true cervix, instead widening into a vagina ending blindly past the base of the urinary bladder and not appearing to connect with the vulva (Fig. 1G, H). The urethra extended into the external genitalia. A small bulge corresponded to the typical location of a prostate in the pelvic inlet.

The internal reproductive organs appeared to be ovotestes. Both appeared bilobed, with the left organ three times as large as the right organ. On cut section, normal testes have a creamy, light tan color with radiating septa forming lobules, whereas an ovary is grayish in color, has a dense texture medulla and a cortex with multiple small follicles, corpora albicans and at times corpora lutea. The suspected ovotestes of wolf 1306 had characteristics of a testis interspersed with a distinct darker area having the appearance

of denser ovarian tissue (Fig. 1I). On microscopic examination they were too autolyzed to confirm cellular characteristics. Serum was not available for hormone analysis.

Wolf 1306 had ambiguous male external morphology (Supplemental Materials Table S1), the presence of a Y chromosome on genotyping (A. Cerreta, pers. comm.), and male breeding behavior (Fig. 2), yet female internal reproductive organs. Despite not producing pups, wolves 1306 and 1402 maintained a territory together for 3 yr (average pair tenure in Denali 1986–2022 = 1.9 yr, 95% confidence interval 1.7–2.3 yr). Additionally, this wolf was comparatively long lived at >7 yr at time of death, versus mean 5.5 yr for collared wolves 1986–2022. The lack of reproduction, with associated energetic demands of raising young, may have contributed to this individual's relatively long life span, indicative of the life history trade-off between the cost of reproduction and survival (Williams 1966).

Although the ovotestes could not be confirmed histologically, we suspect this is a case of endogenously occurring true hermaphroditism. Some cases of pseudohermaphroditism in free-living wildlife have been suspected to be of exogenous origin (exposure of the dam to teratogens, which include infectious or physical agents; Cattet 1988); we have no evidence for that in this case, nor evidence of any cluster of hermaphroditism occurring in this area. We suspect that some level of intersex development occurs naturally in wild canid populations, as in other mammals (Krob et al. 1994; Kustritz 2003). Wildlife researchers should be aware that, although infrequent, endogenously occurring free-ranging intersex mammals may occur. Without concerted monitoring, cryptic anomalies such as hermaphroditism may go undetected in a population yet cause individual heterogeneity in reproduction or survival, with potential for unexpected population, management, or conservation effects.

SUPPLEMENTARY MATERIAL

Supplementary material for this article is online at <http://dx.doi.org/10.7589/JWD-D-23-00038>.

LITERATURE CITED

- Cattet M. 1988. Abnormal sexual differentiation in black bears (*Ursus americanus*) and brown bears (*Ursus arctos*). *J Mammal* 69:849–852.
- Costa PPC, Braga Filho CT, de Freitas LA, dos Santos MH, Cabral LAR, de Moraes Silveira JA, de Araújo AA. 2017. True hermaphroditism in a dog. *Acta Sci Vet* 45(Suppl 1):199.
- De Guise S, Lagacé A, Béland P. 1994. True hermaphroditism in a St. Lawrence beluga whale (*Delphinapterus leucas*). *J Wildl Dis* 30:287–290.
- Gipson PS, Ballard WB, Nowak RM, Mech LD. 2000. Accuracy and precision of estimating age of gray wolves by tooth wear. *J Wildl Manage* 64:752–758.
- Kang JT, Kim HJ, Oh HJ, Hong SG, Park JE, Kim MJ, Kim MK, Jang G, Kim DY, Lee BC. 2012. SRY-positive 78, XY ovotesticular disorder of sex development in a wolf cloned by nuclear transfer. *J Vet Sci* 13:211–213.
- Krob G, Braun A, Kuhnle U. 1994. True hermaphroditism: Geographical distribution, clinical findings, chromosomes and gonadal histology. *Eur J Pediatr* 153:2–10.
- Kustritz MVR, editor. 2003. *Small animal theriogenology*. Elsevier Science, St. Louis, Missouri, 638 pp.
- Lee DS, Lee JH, Park JY, Lee SJ, Kim KJ, Kim EY, Son HY, Sohn SH, Woo JS, Kim MK. 2013. Histological and genetic characterization of true hermaphroditism in Korean pigs. *J Vet Med Sci* 75:203–206.
- Mech LD. 2006. Age-related body mass and reproductive measurements of gray wolves in Minnesota. *J Mammal* 87:80–84.
- Mech LD, Adams LG, Meier TJ, Burch JW, Dale BW. 1998. *The wolves of Denali*. University of Minnesota Press, Minneapolis, Minnesota.
- Meier TJ, Burch JW, Wilder D, Cook M. 2009. Wolf monitoring protocol for Denali National Park and Preserve, Yukon-Charley Rivers National Preserve and Wrangell–St. Elias National Park and Preserve, Alaska. National Park Service, Fort Collins, Colorado, 79 pp.
- Mickelsen W, Memon MA. 1995. Inherited and congenital disorders of the male and female reproductive system. In: *Textbook of veterinary internal medicine*, Ettinger SJ, Feldman EC, editors. W. B. Saunders, Philadelphia, Pennsylvania, pp. 1636–1690.
- Murie A. 1944. *The wolves of Mount McKinley*. US Government Printing Office, Washington, DC, 238 pp.
- Pajares G, Balseiro A, Pérez-Pardal L, Gamarra JA, Monteagudo LV, Goyache F, Royo LJ. 2009. Sry-negative XX true hermaphroditism in a roe deer. *Anim Reprod Sci* 112:190–197.
- Williams GC. 1966. Natural selections, the costs of reproduction, and a refinement of Lack's principle. *Am Nat* 100:687–690.

Submitted for publication 2 March 2023.

Accepted 24 October 2023.