

Letters From Our Readers

To: Editor, *The Angle Orthodontist*

Re: A comparison of treatment results of adult deep-bite cases treated with lingual and labial fixed appliances. Hande Pamukçu, Ömür Polat Özsoy, *Angle Orthod.* 2021;91:590–596.

Thank you for publishing this paper on the comparison of treatment results of lingual and labial fixed appliances during the treatment of deep-bite. We appreciate the authors for doing a clinical study that proves the time-tested biomechanical advantage of lingual appliances in limiting the proclination of incisors while correcting the deep-bite.

However, we wish to seek clarification on Figure 2 of the paper, which explains the effects of lingual and labial forces on the lower incisors and molars.

The illustration of the labial appliance in Figure 2 of the paper, shows counter-clockwise rotation of molars. Whether the appliance is labial or lingual the molars

would always experience a tip-back moment, a clockwise moment in this case, while correcting the deep-bite.

Additionally, if the force of intrusion is labial to the center of resistance, as shown in the illustration of the lingual appliance in Figure 2 of the paper, incisors would still procline due to the counter-clockwise moment generated (Figure 1). The incisors would undergo retroclination, only if the intrusion force is lingual to the center of resistance, which occurs in those few cases where the incisors are upright or retroclined at the beginning of the treatment.

Thank you for providing clarifications regarding the figures in your paper.

Sarah Anvery, Pramod Philip

Department of Orthodontics, University at Buffalo
School of Dental Medicine, Buffalo, New York

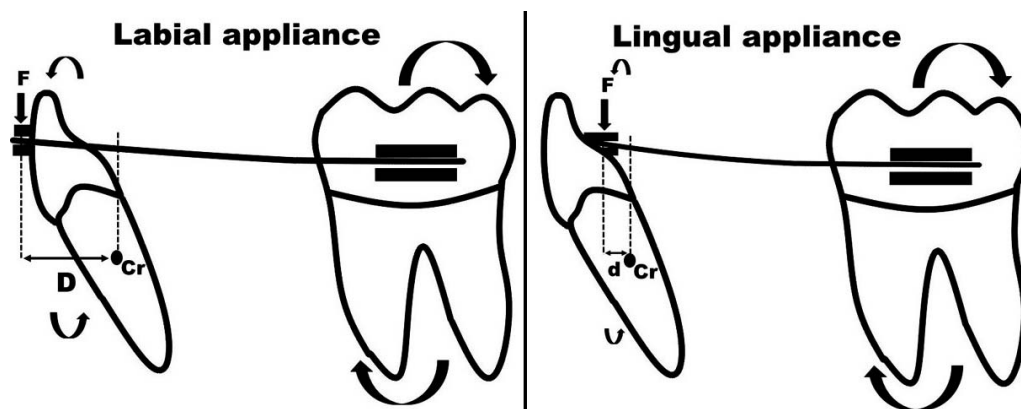


Figure 1. Distance 'D' in the labial appliance is more than the distance 'd' in the lingual appliance resulting in larger moment and hence more tipping in the labial appliance. In both appliance systems, the molars experience a 'tip-back' moment.