

## Relative anchorage loss under reciprocal anchorage in mandibular premolar extraction cases treated with clear aligners

Zhenxing Tang<sup>a</sup>; Weichang Chen<sup>b</sup>; Li Mei<sup>c</sup>; Ehab A. Abdulghani<sup>d</sup>; Zhihe Zhao<sup>e</sup>; Yu Li<sup>e</sup>

### ABSTRACT

**Objectives:** To compare mandibular relative anchorage loss (RAL) under reciprocal anchorage between first and second premolar extraction cases in bimaxillary protrusion mild crowding cases treated using clear aligner therapy (CAT).

**Materials and Methods:** Adult patients who met the following criteria were included: treated using CAT with bilateral mandibular premolar extractions and space closure using intra-arch reciprocal anchorage. RAL was defined as the percent molar mesial movement relative to the sum of molar mesial plus canine distal movement. Movements of the mandibular central incisor (L1), canine (L3), and first molar (L6) were measured based on superimposition of the pre- and post-treatment dentition and jaw models.

**Results:** Among the 60 mandibular extraction quadrants, 38 had lower first premolar (L4) and 22 had lower second premolar (L5) extracted. L6 mesial movement was  $2.01 \pm 1.11$  mm with RAL of 25% in the L4 extraction group vs  $3.25 \pm 1.19$  mm with RAL of 40% in the L5 extraction group ( $P < .001$ ). Tooth movement efficacy was 43% for L1 occlusogingival movement, 75% for L1 buccolingual inclination, 60% for L3 occlusogingival movement, and 53% for L3 mesiodistal angulation. L1 had unwanted extrusion and lingual crown torquing whereas L3 had unwanted extrusion and distal crown tipping, on which the power ridges or attachments had little preventive effect.

**Conclusions:** The average mandibular reciprocal RAL is 25% or 40% for extraction of L4 or L5, respectively, in CAT cases. A RAL-based treatment planning workflow is proposed for CAT extraction cases. (*Angle Orthod.* 2023;93:375–381.)

**KEY WORDS:** Clear aligner; Invisalign; Anchorage; Extraction treatment; Tooth movement efficacy

### INTRODUCTION

Clear aligner therapy (CAT) has become increasingly popular due to its advantages over conventional fixed orthodontics, such as a more comfortable treat-

ment experience, reduced number of appointments, and less negative impact on oral hygiene.<sup>1,2</sup> CAT was initially indicated for nonextraction cases due to its limitation in controlling root movement.<sup>3,4</sup> More recently, it has also been used with extraction cases, thanks to

<sup>a</sup> Postgraduate Student, State Key Laboratory of Oral Diseases, National Clinical Research Center for Oral Diseases, Department of Orthodontics, West China Hospital of Stomatology, Sichuan University, Chengdu, China.

<sup>b</sup> Undergraduate Student, State Key Laboratory of Oral Diseases, National Clinical Research Center for Oral Diseases, West China Hospital of Stomatology, Sichuan University, Chengdu, China.

<sup>c</sup> Associate Professor, Discipline of Orthodontics, Department of Oral Sciences, Faculty of Dentistry, University of Otago, Dunedin, New Zealand.

<sup>d</sup> Researcher, Department of Orthodontics and Dentofacial Orthopedics, College of Dentistry, Thamar University, Dhamar, Yemen; and Postgraduate Student, State Key Laboratory of Oral Diseases, National Clinical Research Center for Oral Diseases, Department of Orthodontics, West China Hospital of Stomatology, Sichuan University, Chengdu, China.

<sup>e</sup> Professor, State Key Laboratory of Oral Diseases, National Clinical Research Center for Oral Diseases, Department of Orthodontics, West China Hospital of Stomatology, Sichuan University, Chengdu, China.

Corresponding author: Dr Yu Li, State Key Laboratory of Oral Diseases, National Clinical Research Center for Oral Diseases, Department of Orthodontics, West China Hospital of Stomatology, Sichuan University, Chengdu, 610041, China (e-mail: yuli@scu.edu.cn)

Accepted: February 2023. Submitted: October 2022.

Published Online: March 29, 2023

© 2023 by The EH Angle Education and Research Foundation, Inc.

development of new aligner materials, attachment designs, and staging of tooth movement.<sup>5-7</sup>

Anchorage is important for extraction cases and it can be classified according to the manner of force application, jaws involved, site of anchorage, number of anchorage units, or anchorage demands.<sup>8</sup> Among them, reciprocal anchorage refers to the desired movement of two segments with equal and opposite forces.<sup>8</sup> In premolar extraction cases, when retraction of the anterior segment and mesial movement of the posterior segment are desired, the two segments move in opposite directions, taking the form of reciprocal anchorage. For a specific case with reciprocal anchorage, extraction of the second premolar may result in greater mesial movement of the molar than would be expected with extraction of the first premolar, as the ratio of the posterior vs anterior units is smaller when the second premolar is extracted. Therefore, knowledge of the difference in posterior anchorage loss under reciprocal anchorage after extraction of the first or second premolar can help clinicians choose the optimal extraction plan.

Posterior anchorage loss is usually measured as amount of first molar mesial movement. With conventional fixed orthodontic appliances, average mesial movement of the mandibular molars ranged from 2.14 to 4.16 mm in first premolar extraction cases,<sup>9-15</sup> and from 3.30 to 4.93 mm in second premolar extraction cases.<sup>14-18</sup> In CAT, after first premolar extraction, the mandibular first molar moved forward by an average of 1.66 mm.<sup>7</sup> Though evaluating anchorage loss with molar mesial movement is straightforward, it does not take into account the total space involved. Therefore, in the present study, relative anchorage loss (RAL) was used as another indicator to describe anchorage capacity, meaning the percentage of molar mesial movement relative to the sum of molar mesial movement plus canine distal movement during extraction space closure. The RAL under intra-arch reciprocal anchorage may also be referred to as “reciprocal RAL.”

Studies on tooth movement efficacy of CAT, representing the capacity to achieve the predicted clinical outcome, are of great significance. Most such studies included nonextraction cases only,<sup>19-25</sup> but the conclusions drawn from nonextraction cases should not be extrapolated to extraction cases. A few studies<sup>4,6,7,19</sup> compared the discrepancy between the actual and virtual outcomes in CAT extraction cases; however, none of them reported the efficacy of tooth movement. Therefore, the primary aim of this study was to investigate reciprocal RAL in mandibular premolar extraction cases treated with CAT, and the secondary aim was to analyze the efficacy of tooth movement.

## MATERIALS AND METHODS

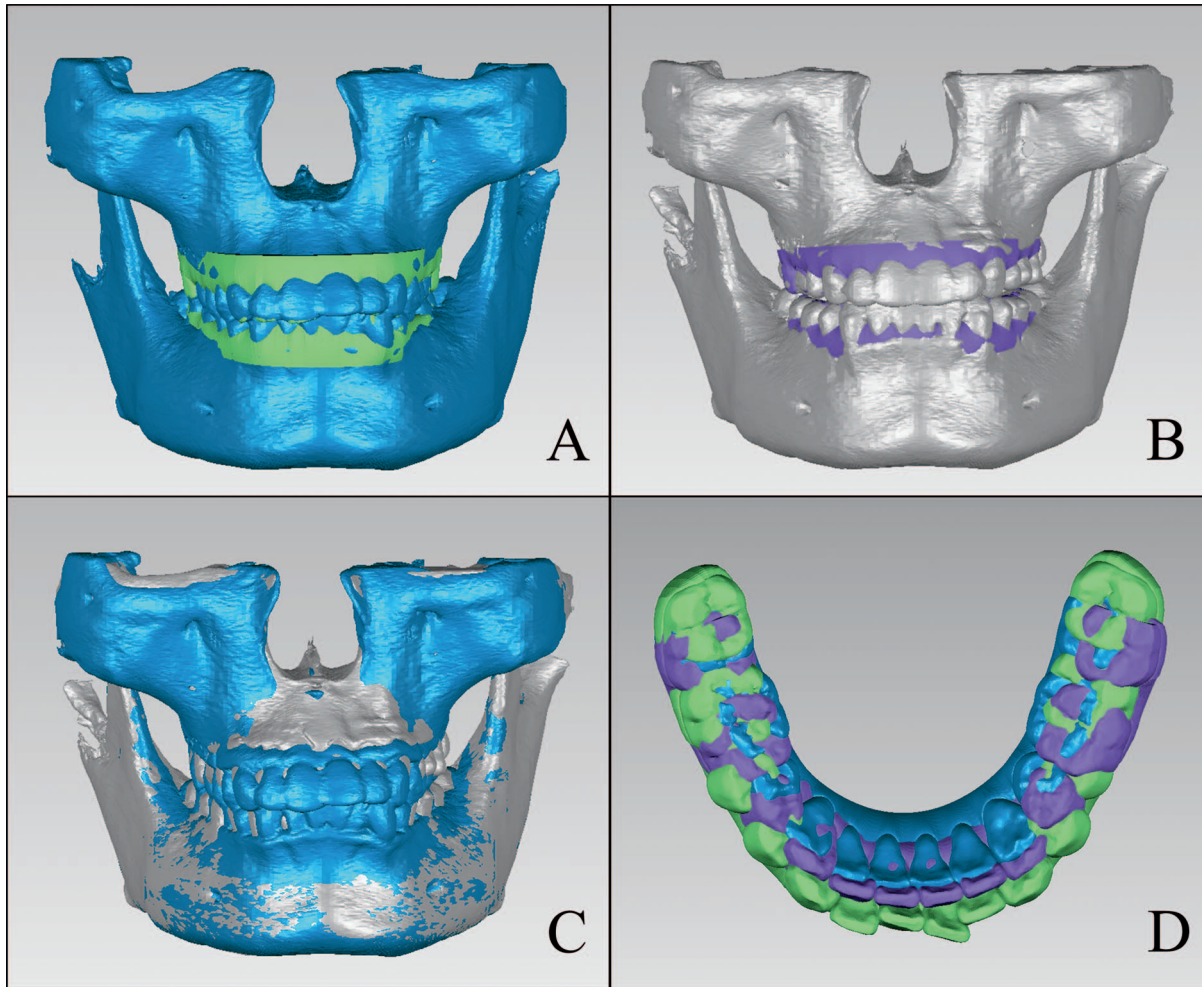
### Samples

The determination of sample size was based on a previous study,<sup>15</sup> which investigated the molar mesial movement in mandibular premolar extraction cases. A sample size of 10 per group was needed with type I error at 0.05 and type II error at 0.20 (80% power) based on one-sided two-sample *t*-test. A total of 342 patients who began CAT during the years 2016–2020, by the same orthodontist, were screened for eligibility. After applying the inclusion and exclusion criteria, 30 patients were included in the study, comprising seven males and 23 females, with an average age of  $27.2 \pm 6.4$  (range: 20–45 years). Permission to perform this study was approved by the Ethics Committee of the West China Hospital of Stomatology, Sichuan University (WCHSIRB-CT-2022-160).

The inclusion criteria were: (1) adult patients with a clinical diagnosis of bimaxillary dentoalveolar protrusion who underwent CAT (Invisalign, Align Technology, San Jose, CA), (2) the mandibular arch involved 14 teeth (37–47) with the third molars missing or extracted before treatment, (3) less than 2 mm crowding in each mandibular quadrant, (4) treatment involving extraction of one mandibular premolar on each side, (5) the mandibular extraction space was closed with only intra-arch reciprocal anchorage and no other form of anchorage (inter-arch elastics or temporary anchorage devices [TADs]), (6) completion of the first series of clear aligners without midcourse correction, and (7) full records available for pre- and post-treatment (when the first series of aligners were finished); records included the cone-beam computed tomography (CBCT) images and intra-oral scans. The exclusion criteria were: (1) treatment combined with fixed appliances, (2) treatment combined with orthognathic surgery, and (3) severe alveolar bone atrophy or root resorption. The reason for including mild rather than moderate or severe crowding cases was so that the cases would thus have maximum residual extraction spaces after resolving crowding, which could best represent reciprocal anchorage during space closure.<sup>26</sup> The diagnosis of bimaxillary dentoalveolar protrusion was made based on photographic and cephalometric assessment, including incisor protrusion and increased lip procumbence.<sup>27</sup> All patients changed aligners every 10 days. The average treatment time of the first series of aligners was  $20.2 \pm 6.5$  months. After collection of the records needed for the present study, all the included patients continued their treatment with at least one refinement.

### 3D Model Measurements

The 3D dental models included the intra-oral pre- and post-treatment scans, and the predicted post-

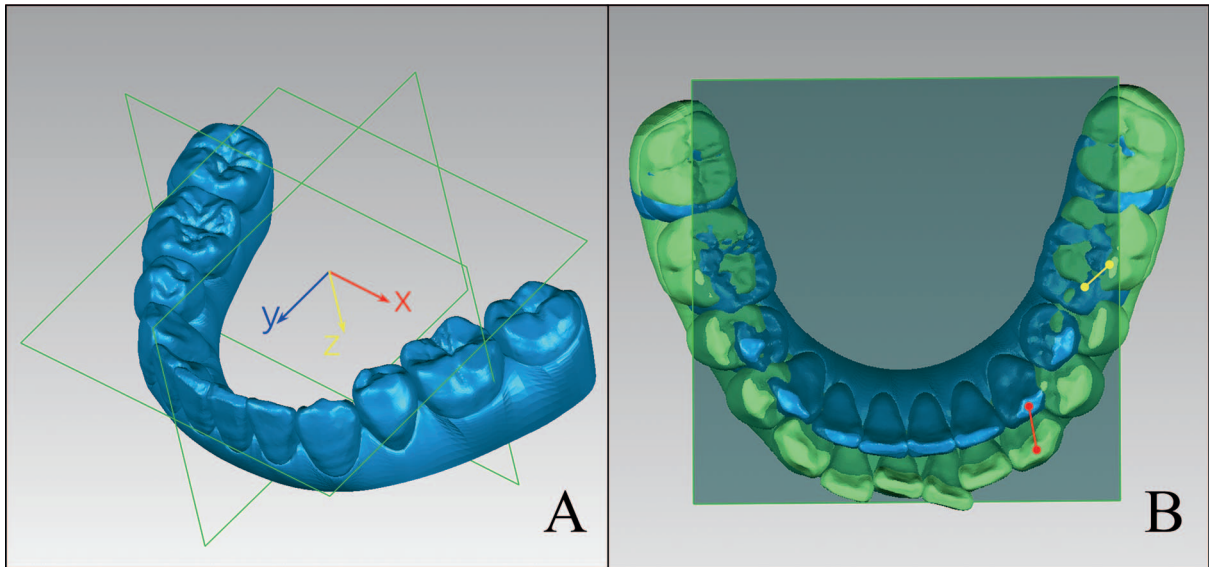


**Figure 1.** Superimposition of the digital dentition models derived from ClinCheck software and the jaw models reconstructed from CBCT data. (A) Superimposition of the pre-treatment dentition model and jaw model based on crown surfaces of all teeth; (B) Superimposition of the achieved post-treatment dentition model and jaw model based on crown surfaces of all teeth; (C) Superimposition of the pre-treatment and post-treatment jaw models based on the mandibular basal bone; (D) Final superimposition of the pre-treatment (green), predicted post-treatment (blue) and achieved post-treatment (purple) mandibular dentition models.

treatment dentition models in the ClinCheck software (Align Technology, San Jose, CA). The 3D jaw models were derived from the CBCT reconstruction using Mimics software (version 21.0; Materialise, Leuven, Belgium). Superimposition of the 3D models (Figure 1) was performed with Geomagic Studio (version 12.0, Geomagic, Rock Hill, SC) as described by Dai et al.<sup>7</sup> A 3D coordinate system (Figure 2A) was established for tooth movement measurement. The mesial buccal cusps of bilateral first molars and the proximal contact point of bilateral central incisors on the predicted post-treatment dentition model were used to fit the transverse plane (xy plane); the coronal plane (xz plane) was the plane perpendicular to the transverse plane, passing through mesial buccal cusps of bilateral first molars; the midsagittal plane (yz plane) was the plane perpendicular to the transverse and coronal

planes, passing through the proximal contact point of the central incisors.

Tooth movements, including anteroposterior movement, occlusogingival movement, mesiodistal angulation, buccolingual inclination, and rotation, were measured for every lower central incisor (L1), canine (L3), and first molar (L6). The L6 mesial movement was measured as the length between the projected points of the pre- and post-treatment first molar mesial buccal cusp tips on the transverse plane. The L3 distal movement was quantified similarly (Figure 2B). The relative anchorage loss (RAL) was defined as the percentage of L6 mesial movement to the total extraction space closed (the sum of L6 mesialization and L3 distalization). All other tooth movement measurements were conducted in the same manner as described in the literature,<sup>6,7</sup> and repeated by the same operator after a 1-week interval.



**Figure 2.** The measurement of anteroposterior tooth movement. (A) Establishment of the three-dimensional coordinate system based on anatomical landmarks on the predicted post-treatment dentition model. (B) Measurement of mandibular first molar mesial movement (yellow) and canine distal movement (red) in the xy plane.

**Statistical Analysis**

All statistical analyses were performed with Stata software (version 15.0; Stata Corporation, College Station, TX). Pearson correlation coefficients and Bland-Altman analyses were used to evaluate intra-operator agreement. Independent *t*-tests were used to compare anteroposterior movement and RAL between the lower first premolar (L4) extraction quadrants and the lower second premolar (L5) extraction quadrants. Paired *t*-test was used to compare the achieved and predicted tooth movements. For those variables with statistically significant differences (except anteroposterior movement), stepwise regression analysis was used to explore the influence of predicted tooth movement, power ridges, and attachment types on achieved tooth movement. Tooth movement efficacy was calculated as the coefficient of corresponding predicted tooth movement of the regression models. Statistical significance was set at *P* < .05.

**Table 1.** Pearson’s Correlation Coefficients (*r*) and Results of Bland-Altman Analyses for Intra-Operator Agreement\*

Measurement	<i>r</i>	Difference	95% Limits of Agreement
APM	0.997	-0.016 ± 0.170	-0.349-0.316
OGM	0.993	0.006 ± 0.157	-0.302-0.315
MDA	0.998	0.048 ± 0.574	-1.077-1.173
BLI	0.997	0.207 ± 0.707	-1.179-1.594
Rotation	0.998	0.002 ± 0.834	-1.633-1.636

\* APM indicates anteroposterior movement; BLI, buccolingual inclination; MDA, mesiodistal angulation; OGM, occlusogingival movement.

**RESULTS**

For repeated measurements, the Pearson correlation coefficients and the Bland-Altman analysis showed excellent intra-operator agreement (Table 1). Among the 60 mandibular extraction quadrants, 38 quadrants had L4 extraction, and 22 quadrants had L5 extraction. The characteristics of attachments and power ridges used on mandibular teeth are summarized in Table 2.

Table 3 compares the achieved anteroposterior movement and RAL between the L4 and L5 extraction groups. The amount of L1 retraction and L3 distalization in the L4 extraction group was greater than that in the L5 extraction group (*P* < .05); the amount of L6 mesial movement in the L4 extraction group (2.01 ± 1.11 mm) was significantly less than that in the L5 extraction group (3.25 ± 1.19 mm); and the RAL was 25 ± 13% in the L4 extraction group vs 40 ± 15% in the L5 extraction group (*P* < .001).

Table 4 shows the comparison between the predicted and achieved tooth movements. Compared with predicted, the L1 had 2.36 ± 1.19 mm more occlusal movement and 12.30 ± 5.20° more lingual crown

**Table 2.** Power Ridges and Attachments Used on Different Mandibular Teeth

Teeth	Attachment/Power Ridge		
L1	Power ridge	None	Total 60
	11	49	
L3	Rectangular attachment	Optimized attachment	Total 60
	22	38	
L6	Rectangular attachment	Optimized attachment	Total 60
	43	17	

**Table 3.** Achieved Anteroposterior Movement and Relative Anchorage Loss in Different Groups<sup>a</sup>

Measurement	L4 Extraction	L5 Extraction	Difference	P*
L1_APM	5.02 ± 1.36	4.11 ± 1.58	-0.91	.028
L3_APM	5.86 ± 1.32	4.97 ± 1.41	-0.90	.017
L6_APM	2.01 ± 1.11	3.25 ± 1.19	1.23	<.001
RAL	0.25 ± 0.13	0.40 ± 0.15	0.14	<.001

<sup>a</sup> APM indicates anteroposterior movement; +, retraction of central incisors, distalization of canines, and mesialization of first molars; -, protrusion of central incisors, mesialization of canines, and distalization of first molars. RAL indicates relative anchorage loss.  
\* Independent t-test, significant at P < .05.

torquing, whereas the L3 had 1.04 ± 1.11 mm more occlusal movement and 10.33 ± 8.13° more distal crown tipping. In addition, the achieved L6 mesialization was 0.90 ± 1.38 mm larger than the amount predicted (P < .001).

Stepwise regression analysis (Table 5) showed that the efficacy of different tooth movements varied: 42.8% for the L1 occlusogingival movement, 74.8% for the L1 buccolingual inclination, 60.1% for the L3 occlusogingival movement, and 52.8% for the L3 mesiodistal angulation. As shown in the regression model, the power ridges had no significant effect on the L1 buccolingual inclination, and the use of optimized or rectangular attachments had no significant effect on the L3 mesiodistal angulation.

**DISCUSSION**

It is controversial in the literature whether mandibular anchorage loss varies between different premolar extraction patterns in fixed orthodontics. Some studies found significantly greater molar mesial movement in L5 than L4 extraction patients,<sup>14,15,28</sup> whereas others found no significant difference.<sup>16,29</sup> It should be noted that most of these studies involved intermaxillary elastics rather than intra-arch reciprocal anchorage exclusively, except for one study conducted by Kim et al.,<sup>15</sup> which found that the L6 moved mesially by 2.14 mm in the L4 extraction cases and by 3.62 mm in the L5 extraction cases. The present study is the first to compare anchorage loss between L4 and L5 extraction patterns in CAT. Based on the sample observed in the present study, L6 mesial movement was 2.01 ± 1.11 mm with RAL of 25% in the L4 extraction group, significantly less than the 3.25 ± 1.19 mm with RAL of 40% in the L5 extraction group (Table 3). It also seemed that the mandibular posterior anchorage loss in CAT was smaller than that in fixed appliances, though the sample in the present study might not be completely comparable to the sample evaluated by Kim et al.<sup>15</sup>

A RAL based workflow is recommended to determine the optimal extraction site and the need for

**Table 4.** Predicted and Achieved Tooth Movement<sup>a</sup>

Measurement	Predicted	Achieved	Difference	P*
<b>APM</b>				
L1	5.16 ± 1.73	4.70 ± 1.49	0.45 ± 1.51	.023
L3	5.69 ± 1.53	5.55 ± 1.41	0.14 ± 2.01	.585
L6	1.55 ± 1.16	2.45 ± 1.27	-0.90 ± 1.38	<.001
<b>OGM</b>				
L1	-1.73 ± 1.13	0.64 ± 1.11	2.36 ± 1.19	<.001
L3	-0.82 ± 1.12	0.22 ± 1.21	1.04 ± 1.11	<.001
L6	-0.19 ± 1.31	-0.27 ± 0.55	0.08 ± 1.43	.657
<b>MDA</b>				
L1	-0.74 ± 5.41	-0.69 ± 4.54	0.05 ± 3.14	.900
L3	1.00 ± 10.76	11.33 ± 8.52	10.33 ± 8.13	<.001
L6	3.02 ± 8.38	2.23 ± 9.16	-0.79 ± 8.46	.473
<b>BLI</b>				
L1	2.46 ± 6.29	14.76 ± 7.21	12.30 ± 5.20	<.001
L3	1.59 ± 8.00	1.42 ± 12.67	-0.17 ± 10.03	.897
L6	-1.59 ± 4.89	0.09 ± 6.02	1.67 ± 7.39	.085
<b>Rotation</b>				
L1	5.70 ± 13.90	4.74 ± 12.44	-0.97 ± 8.18	.365
L3	-0.84 ± 16.17	-0.82 ± 16.47	0.01 ± 7.69	.988
L6	-2.00 ± 4.54	-2.70 ± 5.34	-0.70 ± 3.74	.150

<sup>a</sup> APM indicates anteroposterior movement; +, retraction of central incisors, distalization of canines, and mesialization of first molars; -, protrusion of central incisors, mesialization of canines, and distalization of first molars. BLI indicates buccolingual inclination; +, lingual crown torque; -, labial/buccal crown torque. +, retraction of central incisors, distalization of canines, and mesialization of first molars; -, protrusion of central incisors, mesialization of canines, and distalization of first molars. MDA indicates mesiodistal angulation; +, distal crown tipping; -, mesial crown tipping. OGM indicates occlusogingival movement; +, extrusion; -, intrusion. Rotation: +, distal-lingual rotation; -, mesial-lingual rotation.

\* Paired t-test, significant at P < .05.

additional anchorage (Figure 3). First, the orthodontist sets the incisor position objective (IPO) and develops a tentative extraction plan, based upon which a tentative dental setup is made in the digital orthodontic software, such as ClinCheck. Then, the orthodontist measures the predicted RAL and compares it with the average reciprocal RAL value. If the predicted RAL is close to the reciprocal RAL, the tentative extraction plan is justified; otherwise, it should be modified, either by supplementing additional posterior or anterior anchorage, or by changing to a new extraction plan that better matches the predicted RAL with the reciprocal RAL.

Previous studies superimposed the pre- and post-treatment dentition models using regional superimposition on molars<sup>21</sup> or global dentition alignment,<sup>23</sup> which were not applicable in the present study because the arch length and form were changed in the extraction cases. Due to the stability of mandibular basal bone in adults, registration of the pre- and post-treatment CBCT jaw models was used to measure mandibular tooth movement in the present study. Such an approach for registration has been previously validated,<sup>7</sup> with the caution in mind that multiple superimposition operations might result in accumulation of measurement errors.

**Table 5.** Results of Stepwise Regression Analysis<sup>a</sup>

DV	IV	Coef.	Std. Err.	t	P >  t *	95% CI	R <sup>2</sup>
L1_OGM <sup>b</sup>	L1_OGM <sup>c</sup>	0.428	0.116	3.68	.001	0.195–0.660	0.190
	_cons	1.376	0.239	5.76	<.001	0.897–1.854	
L1_BLI <sup>b</sup>	L1_APM <sup>c</sup>	1.244	0.359	3.47	.001	0.525–1.964	0.620
	L1_BLI <sup>c</sup>	0.748	0.099	7.55	<.001	0.550–0.946	
	_cons	6.502	1.917	3.39	.001	2.663–10.342	
L3_OGM <sup>b</sup>	L1-BLI <sup>c</sup>	0.057	0.020	2.85	.006	0.017–0.097	0.387
	L3-OGM <sup>c</sup>	0.601	0.112	5.36	<.001	0.247–0.894	
	_cons	0.571	0.162	3.53	<.001	0.247–0.894	
L3_MDA <sup>b</sup>	L3_MDA <sup>c</sup>	0.528	0.077	6.82	<.001	0.373–0.683	0.445
	_cons	10.802	0.830	13.02	<.001	9.141–12.463	

<sup>a</sup> APM indicates anteroposterior movement; BLI, buccolingual inclination; coef, coefficient; DV, dependent variable; IV, independent variable; MDA, mesiodistal angulation; OGM, occlusogingival movement; Std. Err., standard error.

<sup>b</sup> Achieved tooth movement.

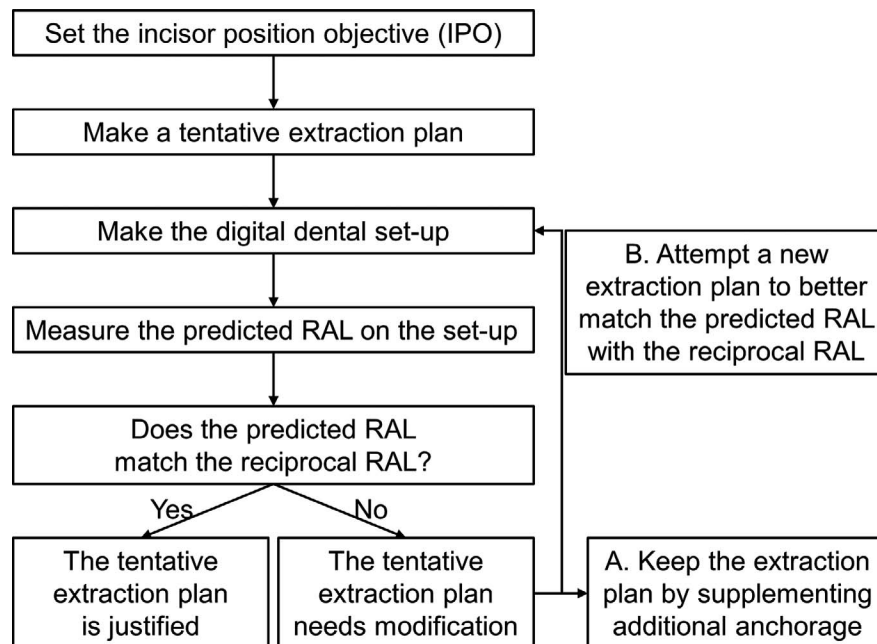
<sup>c</sup> Predicted tooth movement.

\* Stepwise regression analysis; significant at  $P < .05$ .

In the present study, the efficacy of occlusogingival movement of the L1 and L3 was 43% and 60%, respectively (Table 5). The L1 and L3 extruded though they were designed to intrude (Table 4). Relative extrusion caused by poor control and tipping of teeth into the extraction site during anterior retraction may account for these results.<sup>30</sup> The L1 had an average of  $12.30 \pm 5.20^\circ$  more lingual crown torquing and the L3 had  $10.33 \pm 8.13^\circ$  more distal crown tipping (Table 4), which is consistent with a previous study.<sup>7</sup> The power ridge is claimed to facilitate incisor torque control and optimized attachments are supposed to improve control of canine tipping. Nevertheless, according to the stepwise regression model, the power ridge had no significant effect on the L1 buccolingual inclination, nor

did any type of attachment on the L3 mesiodistal angulation (Table 5). Thus, clear aligners seem to lack sufficient control for maintaining incisor torque and canine angulation during anterior retraction, even with power ridges or attachments.

This study had some limitations. First, although strict inclusion criteria were set in the present study, there still might be some confounding factors, such as vertical skeletal pattern variations. Second, when applying the RAL value in a specific case, anatomical features should also be considered, especially alveolar bone width. Additionally, only Invisalign cases were included to reduce bias, and future studies on the same topic may involve other brands of clear aligners.



**Figure 3.** Flow chart for the RAL-based extraction treatment planning scheme in digital orthodontics.

## CONCLUSIONS

- The average mandibular reciprocal RAL is 25% for L4 extraction and 40% for L5 extraction in CAT. Based on the RAL, clinicians can determine the appropriate extraction treatment plan with improved precision.
- The L1 had unwanted extrusion and lingual crown torquing, whereas the L3 had unwanted extrusion and distal crown tipping during anterior retraction; power ridges or attachments had little effect on preventing this from occurring.

## REFERENCES

1. Fujiyama K, Honjo T, Suzuki M, Matsuoka S, Deguchi T. Analysis of pain level in cases treated with Invisalign aligner: comparison with fixed edgewise appliance therapy. *Prog Orthod*. 2014;15(1):64.
2. Miller KB, McGorray SP, Womack R, et al. A comparison of treatment impacts between Invisalign aligner and fixed appliance therapy during the first week of treatment. *Am J Orthod Dentofacial Orthop*. 2007;131(3):302.e1–9.
3. Gomez JP, Peña FM, Martínez V, Giraldo DC, Cardona CI. Initial force systems during bodily tooth movement with plastic aligners and composite attachments: a three-dimensional finite element analysis. *Angle Orthod*. 2015;85(3):454–460.
4. Baldwin DK, King G, Ramsay DS, Huang G, Bollen AM. Activation time and material stiffness of sequential removable orthodontic appliances. Part 3: premolar extraction patients. *Am J Orthod Dentofacial Orthop*. 2008;133(6):837–845.
5. Choi NC, Park YC, Jo YM, Lee KJ. Combined use of miniscrews and clear appliances for the treatment of bialveolar protrusion without conventional brackets. *Am J Orthod Dentofacial Orthop*. 2009;135(5):671–681.
6. Dai FF, Xu TM, Shu G. Comparison of achieved and predicted tooth movement of maxillary first molars and central incisors: first premolar extraction treatment with Invisalign. *Angle Orthod*. 2019;89(5):679–687.
7. Dai FF, Xu TM, Shu G. Comparison of achieved and predicted crown movement in adults after 4 first premolar extraction treatment with Invisalign. *Am J Orthod Dentofacial Orthop*. 2021;160(6):805–813.
8. Nahidh M, Azzawi A, Al-Badri S. Understanding anchorage in orthodontics—a review article. *Ann Clin Med Case Rep*. 2019;2(3):1–6.
9. Staggers JA. A comparison of results of second molar and first premolar extraction treatment. *Am J Orthod Dentofacial Orthop*. 1990;98(5):430–436.
10. Paquette DE, Beattie JR, Johnston LE Jr. A long-term comparison of nonextraction and premolar extraction edgewise therapy in “borderline” Class II patients. *Am J Orthod Dentofacial Orthop*. 1992;102(1):1–14.
11. Zablocki HL, McNamara JA, Jr., Franchi L, Baccetti T. Effect of the transpalatal arch during extraction treatment. *Am J Orthod Dentofacial Orthop*. 2008;133(6):852–860.
12. Hedayati Z, Hashemi SM, Zamiri B, Fattahi HR. Anchorage value of surgical titanium screws in orthodontic tooth movement. *Int J Oral Maxillofac Surg*. 2007;36(7):588–592.
13. Upadhyay M, Yadav S, Nagaraj K, Patil S. Treatment effects of mini-implants for en-masse retraction of anterior teeth in bialveolar dental protrusion patients: a randomized controlled trial. *Am J Orthod Dentofacial Orthop*. 2008;134(1):18–29.e1.
14. George SM, Campbell PM, Tadlock LP, Schneiderman E, Buschang PH. Keys to Class II correction: a comparison of 2 extraction protocols. *Am J Orthod Dentofacial Orthop*. 2021;159(3):333–342.
15. Kim TK, Kim JT, Mah J, Yang WS, Baek SH. First or second premolar extraction effects on facial vertical dimension. *Angle Orthod*. 2005;75(2):177–182.
16. Wang Y, Yu H, Jiang C, et al. Vertical changes in Class I malocclusion between 2 different extraction patterns. *Saudi Med J*. 2013;34(3):302–306.
17. Jung MH. A comparison of second premolar extraction and mini-implant total arch distalization with interproximal stripping. *Angle Orthod*. 2013;83(4):680–685.
18. Urias D, Mustafa FI. Anchorage control in bioprogressive vs straight-wire treatment. *Angle Orthod*. 2005;75(6):987–992.
19. Papadimitriou A, Mousoulea S, Gkantidis N, Kloukos D. Clinical effectiveness of Invisalign® orthodontic treatment: a systematic review. *Prog Orthod*. 2018;19(1):37.
20. Robertson L, Kaur H, Fagundes NCF, Romanyk D, Major P, Flores Mir C. Effectiveness of clear aligner therapy for orthodontic treatment: a systematic review. *Orthod Craniofac Res*. 2020;23(2):133–142.
21. Charalampakis O, Iliadi A, Ueno H, Oliver DR, Kim KB. Accuracy of clear aligners: a retrospective study of patients who needed refinement. *Am J Orthod Dentofacial Orthop*. 2018;154(1):47–54.
22. Jiang T, Jiang YN, Chu FT, Lu PJ, Tang GH. A cone-beam computed tomographic study evaluating the efficacy of incisor movement with clear aligners: assessment of incisor pure tipping, controlled tipping, translation, and torque. *Am J Orthod Dentofacial Orthop*. 2021;159(5):635–643.
23. Haouili N, Kravitz ND, Vaid NR, Ferguson DJ, Makki L. Has Invisalign improved? A prospective follow-up study on the efficacy of tooth movement with Invisalign. *Am J Orthod Dentofacial Orthop*. 2020;158(3):420–425.
24. Grünheid T, Loh C, Larson BE. How accurate is Invisalign in nonextraction cases? Are predicted tooth positions achieved? *Angle Orthod*. 2017;87(6):809–815.
25. Solano-Mendoza B, Sonnemberg B, Solano-Reina E, Iglesias-Linares A. How effective is the Invisalign® system in expansion movement with Ex30' aligners? *Clin Oral Investig*. 2017;21(5):1475–1484.
26. Li Y. [Extraction and non-extraction cases treated with clear aligners]. *Zhonghua Kou Qiang Yi Xue Za Zhi*. 2020;55(8):536–540.
27. Bills DA, Handelman CS, BeGole EA. Bimaxillary dentoalveolar protrusion: traits and orthodontic correction. *Angle Orthod*. 2005;75(3):333–339.
28. Al-Nimri KS. Changes in mandibular incisor position in Class II Division 1 malocclusion treated with premolar extractions. *Am J Orthod Dentofacial Orthop*. 2003;124(6):708–713.
29. Shearn BN, Woods MG. An occlusal and cephalometric analysis of lower first and second premolar extraction effects. *Am J Orthod Dentofacial Orthop*. 2000;117(3):351–361.
30. Upadhyay M, Arqub SA. Biomechanics of clear aligners: hidden truths & first principles. *J World Fed Orthod*. 2022;11(1):12–21.