

# A comparison of maxillary canine retraction into healed and recent extraction sites using cone beam computed tomography: a randomized clinical trial

Salam Ghazwan Almaasarani<sup>a</sup>; Nada Rajeh<sup>b</sup>

## ABSTRACT

**Objectives:** To compare maxillary canine retraction between healed and recent extraction sites by assessing movement rate, canine dentoalveolar changes, molar rotation, and anchorage loss using cone-beam computed tomography (CBCT).

**Materials and Methods:** Twenty-eight patients (16–26 years old) who had bimaxillary protrusion and orthodontic treatment planned with extraction of first premolars were randomly distributed into two groups and treated using a straight wire appliance. In the recent group (RG), the upper first premolars were extracted 2 weeks before the initiation of canine retraction (after tooth alignment). In the healed group (HG), the upper first premolars were extracted before tooth alignment. Movement rate, canine dentoalveolar changes, molar rotation, and anchorage loss were assessed using CBCT.

**Results:** Movement rate, canine alveolar bone dimensions, canine rotation, and rotation and mesial movement of the first molar were not significantly different between groups ( $P > .05$ ). Canine tipping was greater in RG ( $P = .001$ ).

**Conclusions:** Retracting canines into recent extraction sites compared with healed sites showed greater distal tipping of the canine with no differences in movement rate, canine alveolar bone dimensions, canine rotation, molar rotation, and anchorage loss. (*Angle Orthod.* 2023;93:382–389.)

**KEY WORDS:** Canine retraction; Healed extraction sites; Recent extraction sites; Extraction time; Alveolar bone thickness; Alveolar bone height; CBCT; Anchorage loss

## INTRODUCTION

Premolar extraction is well accepted in the treatment of many malocclusions.<sup>1</sup> After tooth extraction, many changes can develop in the alveolar process, and the structure of the bone into which the canine is moved can be affected by the orthodontist. The tooth can be moved into an extraction site in which sufficient time was allowed for healing to take place, or tooth movement can start immediately after extraction, and

the canine can be moved into new or forming bone.<sup>2</sup> In addition, many methods of tooth movement acceleration recently garnering attention from the orthodontic community depend on the regional acceleratory phenomenon (RAP), which typically occurs in the healing process of an alveolar socket after tooth extraction.

The period between extraction and initiation of canine retraction and the impact on rate of tooth movement was previously addressed by only a few clinical studies. Abu Alhaija et al.<sup>3</sup> and Zubair et al.<sup>4</sup> demonstrated faster movement in recent extraction sites during the first month. The trial of Abu Alhaija et al.<sup>3</sup> was performed in the mandibular arch, while the other study<sup>4</sup> was conducted in the maxillary arch, with a follow-up period of just 1 month. Hasler et al.,<sup>2</sup> in a pilot study, reported overall faster movement of maxillary canines in recent extraction sites. Conversely, according to Reichert et al.,<sup>5</sup> a mixed sample of upper and lower extraction sites showed slower movement in recent extraction sites, whereas Bertl et al.<sup>6</sup> found an insignificant difference in rate.

<sup>a</sup> Graduate Student, Department of Orthodontics, School of Dentistry, University of Damascus, Damascus, Syria.

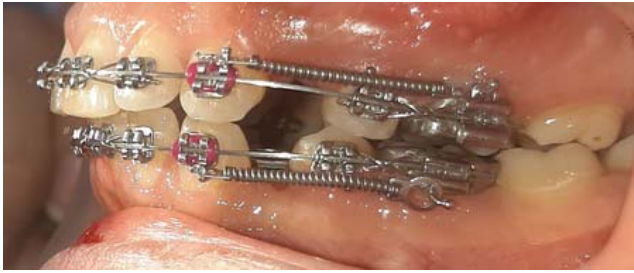<sup>b</sup> Lecturer, Department of Orthodontics, School of Dentistry, University of Damascus, Damascus, Syria.

Corresponding author: Salam Ghazwan Almaasarani, Department of Orthodontics, School of Dentistry, University of Damascus, Damascus, Syria  
(e-mail: salammass@hotmail.com)

Accepted: February 2023. Submitted: November 2022.

Published Online: April 5, 2023

© 2023 by The EH Angle Education and Research Foundation, Inc.



**Figure 1.** Canine retraction using an NiTi closed coil.

The loss of canine-supporting bone has been studied only in the mandible by a vertical measure on a panoramic X-ray in a retrospective study by Spruyt and Cleaton-Jones.<sup>7</sup> They found no significant differences between recent and delayed retraction.

Tipping and rotation of the retracted canine was assessed by Hasler et al.,<sup>2</sup> who reported no significant differences in rotation; however, the canine tipped significantly more in the recent extraction site. In contrast, Abu Alhaija et al.<sup>3</sup> indicated similar tipping in both groups. There have been no published studies comparing rotation and mesial movement of the first molar during canine retraction into healed and recent extraction sites.

Due to the contradicting results regarding the rate of tooth movement and the lack of studies assessing canine dentoalveolar changes and molar anchorage loss, this randomized clinical trial aimed to compare maxillary canine retraction in healed and recent extraction sites by assessing movement rate, canine dentoalveolar changes, molar rotation, and anchorage loss using cone-beam computed tomography (CBCT).

## MATERIALS AND METHODS

### Registration and Ethics

The local ethics committee of the Dental School at the University of Damascus in Syria approved the protocol of the current trial (UDDS-649-18062019/SRG-3875). This trial was registered at the German Clinical Trials Register (DRKS) with the identifier number DRK-S00029321.

### Sample Size Calculation

Sample size was estimated using G\*power 3.1.9 software with an alpha level of .05, a power of 95%, and assuming an effect size of 1 based on movement rate data reported by Hasler et al.<sup>2</sup> A total sample size of 27 canines was required; therefore, a minimum of 14 patients per group was needed. Fifteen patients in each group were recruited to compensate for any possible dropouts.

### Trial Design, Randomization, and Blinding

The study was designed as a prospective parallel-group randomized clinical trial with a 1:1 allocation ratio. Randomization was done using online software ([www.randomizer.org](http://www.randomizer.org)).

Blinding was only applied for the outcome assessor, as blinding of the principal researcher and the patients was not possible due to the nature of the intervention. Patient names were concealed and replaced with numbers by a person not involved in the study. All subjects in this trial were treated by one orthodontist (Dr Almaasarani).

### Participants and Eligibility Criteria

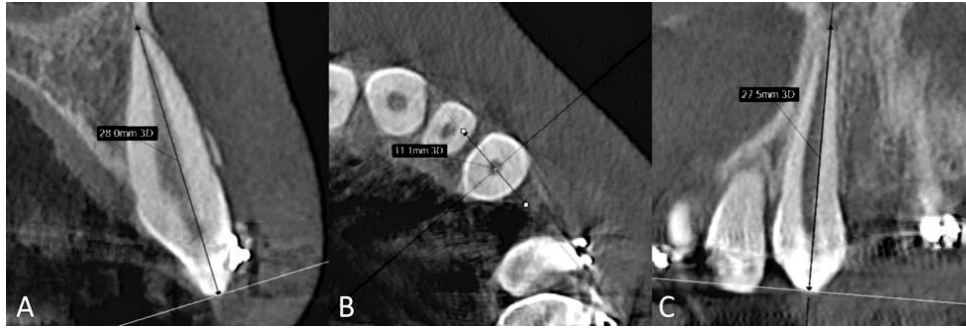
The inclusion criteria were age 16–26 years, Class I occlusion with bimaxillary protrusion (treatment plan included first premolar extractions) and all permanent teeth erupted (except for third molars), vertical or normal growth pattern, and skeletal pattern Class I or mild Class II. The exclusion criteria were moderate or severe crowding in the upper arch, presence of any systemic disease that could affect tooth movement, and patient history of previous orthodontic treatment. Written informed consent was obtained from all patients who agreed to participate in the study.

### Interventions

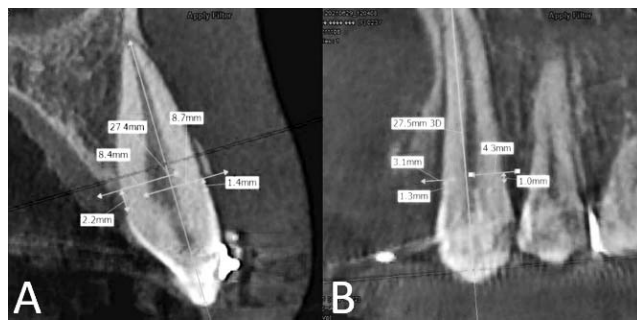Thirty patients (22 females, 8 males) were enrolled in the trial and were equally and randomly divided into two groups. A straight wire appliance was used.

- In the recent group (RG), the upper first premolars were extracted 2 weeks before the initiation of canine retraction (after tooth alignment).
- In the healed group (HG), the upper first premolars were extracted at the beginning of treatment (before tooth alignment).

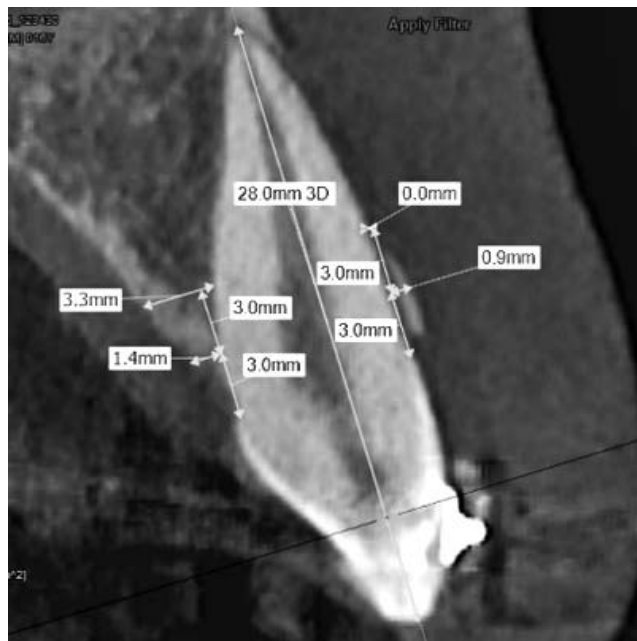
The upper and lower teeth were leveled and aligned using MBT prescription brackets with 0.022-inch slots. The archwire sequence was 0.014-inch NiTi, 0.016-inch NiTi, 0.016 × 0.022-inch NiTi, 0.017 × 0.025-inch NiTi (3 weeks for each wire) and, finally, 0.019 × 0.025-inch stainless steel (SS). Transpalatal and lingual arches were used for anchorage. After the completion of leveling and alignment, and before canine retraction, the first CBCT for the maxilla was taken (T<sub>0</sub>). Then, canine retraction was initiated on 0.019 × 0.025-inch stainless steel (SS) wire using NiTi closed-coil springs, applying a force of 150 g (Figure 1).<sup>8</sup> A force gauge was used to check the generated force. Reactivation was performed every 4 weeks and continued until enough space for retracting the anterior segment was achieved. At this point, the canine was tied to the first



**Figure 2.** Orientation of the CBCT image according to the canine axes and drawing them. (A) Coronal view: the sagittal axis was set with the canine longitudinal axis. (B) Axial view: the coronal axis was set with canine greatest buccolingual width and the canine transverse axis was drawn perpendicular to the greatest buccolingual width. (C) Sagittal view: the coronal axis was set with the canine longitudinal axis.



**Figure 3.** (A) Measuring buccal and palatal bone height in the coronal view. (B) Measuring mesial and distal bone height in the sagittal view.



**Figure 4.** Measuring buccal and palatal bone thickness at 3 and 6 mm from the CEJ in the coronal view, perpendicular to the canine longitudinal axis.

molar and second premolar using ligature, and the second CBCT for the maxilla was taken (T1). If the canine on one side was retracted before the other, it was tied passively until the other canine was retracted; then, the second CBCT was taken.

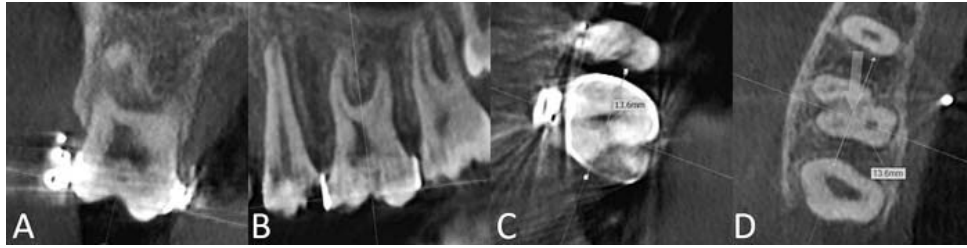
All CBCT images were obtained using the same scanner, PaX-i3D Green (Vatech, Hwaseong-si, Gyeonggi-do, South Korea), with a 12 × 9-cm field of view and 0.2-mm voxel size. The device settings were 98 kV and 11.2 mA.

**CBCT Measurements**

First, images were oriented according to the canine longitudinal and transverse axes, which were drawn<sup>9</sup> (Figure 2). In the coronal view, buccal and palatal bone heights (defined as the distance from the cemento-enamel junction [CEJ] to the alveolar crest parallel to the canine longitudinal axis) were measured.<sup>10</sup> Mesial and distal bone heights were measured similarly in the sagittal view (Figure 3). Buccal and palatal bone thicknesses were assessed at 3 and 6 mm from the CEJ in the coronal view<sup>11</sup> (Figure 4). Then, the image was oriented according to the first molar axes, and the molar center of resistance (CR) was marked at the trifurcation.<sup>9</sup> The transverse axis was drawn perpendicularly to a line passing through the buccal and lingual groove in the axial view (Figure 5).

Finally, the orientation was done according to the skeletal reference lines as follows. The axial axis with the orbital line in the three-dimensional (3D) view, the axial axis with ANS-PNS in the sagittal view (which was drawn and named as the x-axis), and the sagittal axis with the ANS-PNS line in the axial view. A line perpendicular to ANS-PNS, passing through PNS in the axial view, was drawn and named as the y-axis<sup>9</sup> (Figure 6).

In the axial view, the following variables were measured: rotation of canine (Rot3) and first molar (Rot6), distance between canine crown tip and y-axis (Dis3), and the distance between molar CR and y-axis



**Figure 5.** Orientation of the CBCT image according to the first molar axes: (A) Coronal view, (B) Sagittal view. (C) Drawing the transverse axis of the first molar in the axial view. (D) Drawing an arrow at the trifurcation in the axial view.

(Dis6). The canine tipping angle (Tip3) was measured in the sagittal view. The definitions of the variables and their abbreviations are displayed in Table 1.

Differences between preretraction and postretraction measurements were calculated. The rate of canine movement was determined by dividing the difference between pre- and postretraction Dis3 by the retraction duration.

**Statistical Analysis**

All statistical analyses were performed using IBM SPSS version 26. *P* values equal to or less than .05 were considered statistically significant.

To assess the measurement error, 12 CBCT images were randomly chosen and remeasured 4 weeks after the first measurement. The intraclass correlation coefficient (ICC) of reliability was used to determine the reliability of CBCT measurements. Paired sample *t*-test was applied to detect any systematic error.

The normal distribution of variables was assessed by Shapiro-Wilk test. If a normally distributed, paired sample *t*-test was used to detect intragroup differences and independent sample *t*-test was used to detect significant differences between the two groups; otherwise, Wilcoxon and Mann-Whitney *U*-tests were used.

**RESULTS**

Patients were recruited between September 2019 and June 2021 and the follow-up period ended in

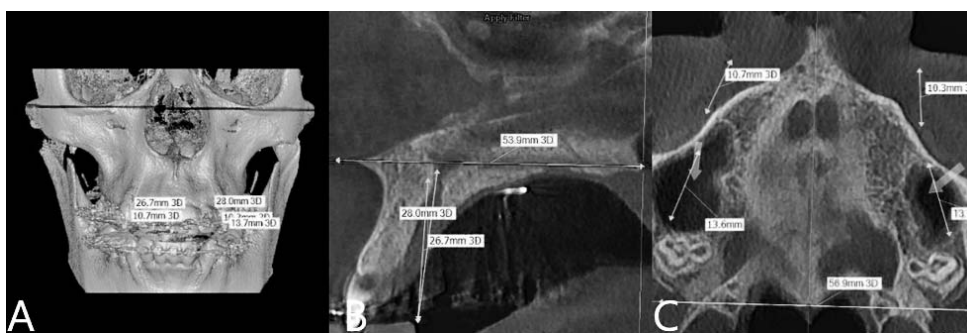February 2022. Two patients did not complete the follow-up. Twenty-eight patients (6 males, 22 females; mean age: 19.4 years, 14 patients in each group) were included in data analysis. Patient allocation and follow-up are shown in Figure 7. Descriptive statistics for the sample are shown in Table 2.

ICCs demonstrated strong intraexaminer reliability and ranged from 0.934 to 0.999. Paired sample *t*-tests indicated that there were no significant differences between the first and second measures (*P* > .05), which reflected nonsignificant systematic errors. The results of ICC and paired sample *t*-test are presented in Table 3.

The period between extraction and the initiation of canine retraction was 17.0 ± 4 days in RG and 121.6 ± 22 days in HG.

Between T0 and T1 for each group, significant distal movement of the canine crown tip, distal tipping, and distopalatal rotation of the canine as well as mesial movement of the first molar were observed. There was nonsignificant mesiopalatal rotation of the first molar in both groups. In terms of canine supporting bone, the significant changes were small apical migration of distal and mesial bone and an increase in P-Th6 (0.5, 0.5, 0.4 mm, respectively) in RG. In HG, There was significant apical migration of the mesial bone in addition to a reduction in B-TH3 (0.7, 0.2 respectively).

There was no significant difference in rate of canine movement between the groups (1.37 and 1.15 mm/mo in RG and HG, respectively; *P* = .087). There were no



**Figure 6.** Orientation of the image according to the skeletal reference lines: (A) 3D view: the axial axis was set with the orbital line; (B) Sagittal view: the axial axis was set with ANS-PNS. (C) Axial view: the sagittal axis was set with ANS-PNS.

**Table 1.** Definitions of Variables and Their Abbreviations<sup>a</sup>

Variable	Abbreviation	Definition
Canine's buccal bone height	BH	Distance from the CEJ to the buccal alveolar crest parallel to the canine's longitudinal axis in the coronal view
Canine's palatal bone height	PH	Distance from the CEJ to the palatal alveolar crest parallel to canine's longitudinal axis in the coronal view.
Canine's mesial bone height	MH	The distance from CEJ to the mesial alveolar crest parallel to the canine's longitudinal axis in the sagittal view
Canine's distal bone height	DH	Distance from the CEJ to the distal alveolar crest parallel to the canine's longitudinal axis in the sagittal view
Canine's buccal bone thickness at 3 mo	B-Th3	Buccal bone thickness measured between the buccal surface of the root to the buccal surface of the alveolar bone perpendicular to the canine's longitudinal axis, at 3 mm from the CEJ in the coronal view
Canine's buccal bone thickness at 6 mo	B-Th6	Buccal bone thickness measured between the buccal surface of the root to the buccal surface of the alveolar bone perpendicular to the canine's longitudinal axis, at 6 mm from the CEJ in the coronal view
Canine's palatal bone thickness at 3 mo	P-Th3	Palatal bone thickness measured between the palatal surface of the root to the palatal surface of the alveolar bone perpendicular to the canine's longitudinal axis, at 3 mm from the CEJ in the coronal view
Canine's palatal bone thickness at 6 mo	P-Th6	Palatal bone thickness measured between the palatal surface of the root to the palatal surface of the alveolar bone perpendicular to the canine's longitudinal axis, at 6 mm from the CEJ in the coronal view
Canine tipping angle	Tip3	Angle between the canine's longitudinal axis and x-axis in the sagittal view
Canine rotation angle	Rot3	The angle between canine's transverse axis and Y axis in the axial view.
Molar rotation angle	Rot6	Angle between the first molar's transverse axis and y-axis in the axial view
Distance between the canine's crown tip and y-axis	Dis3	Sagittal distance between the canine's crown tip and y-axis measured in the axial view
Distance between the molar's center of resistance and y-axis	Dis6	Sagittal distance between the first molar's CR and y-axis measured in the axial view

<sup>a</sup> CEJ indicates cemento-enamel junction; x-axis, ANS-PNS line in the sagittal view; y-axis, line perpendicular to ANS-PNS line passing through PNS in the axial view; CR, center of resistance.

significant differences between the groups in alveolar bone dimension changes, canine rotation, molar rotation, and anchorage loss. However, the change in Tip3 was significantly greater in RG ( $x = 3.48$ ,  $P = .001$ ). These results are shown in Table 4.

## DISCUSSION

The present randomized clinical trial evaluated canine retraction into healed and recent extraction sites and compared movement rate, canine dentoalveolar changes, molar rotation, and anchorage loss using CBCT. The sample consisted of patients with Class I malocclusion with bimaxillary protrusion. The overjet and overbite were not considered in the inclusion criteria because they did not affect the canine retraction phase. Retraction was performed using an NiTi closed coil because it was considered an optimal method to apply light continuous forces for orthodontic tooth movement.<sup>12</sup> CBCT was chosen to assess variables due to several advantages: high diagnostic value at a relatively low radiation dose,<sup>13</sup> 3D display, lower cost than CT, and accurate linear and angular measurements.<sup>14</sup> To reduce the radiation dose, the field of view was reduced by taking the CBCT for the maxilla only. In addition, a scanner with a small exposure time of 5.9 seconds was used.

Canines were retracted at a rate of 1.37 and 1.15 mm/mo in RG and HG, respectively. This movement occurred with significant distal tipping and rotation of the canine in both groups, which was related to the force application point, which did not pass through the canine CR. There was, in addition, significant mesial movement of the first molar of 1.03 and 0.97 mm in RG and HG, respectively. That was due to expected loss of anchorage. However, molar rotation was not significant because a TPA was present.

Although the movement rate was greater in RG, the difference was not statistically significant, in agreement with Bertl et al.<sup>6</sup> While two recent studies by Abu Alhaja et al.<sup>3</sup> and Zubair et al.<sup>4</sup> reported faster movement into recent extraction sites during the first month, the time of initiation of retraction after extraction may have played a role (immediately and after 1 week, respectively). In the current study, retraction began 2 weeks after extraction in RG. In addition, there was no monthly assessment in the current study to investigate differences during the first month, and the final assessment was after canine retraction was complete. On the other hand, Häsler et al.<sup>2</sup> found overall faster movement at recent extraction sites. The younger average age (13.6 years), difference in retraction mechanics (Gjessing spring), amount of force applied (100 g), and wide variance in retraction initiation time

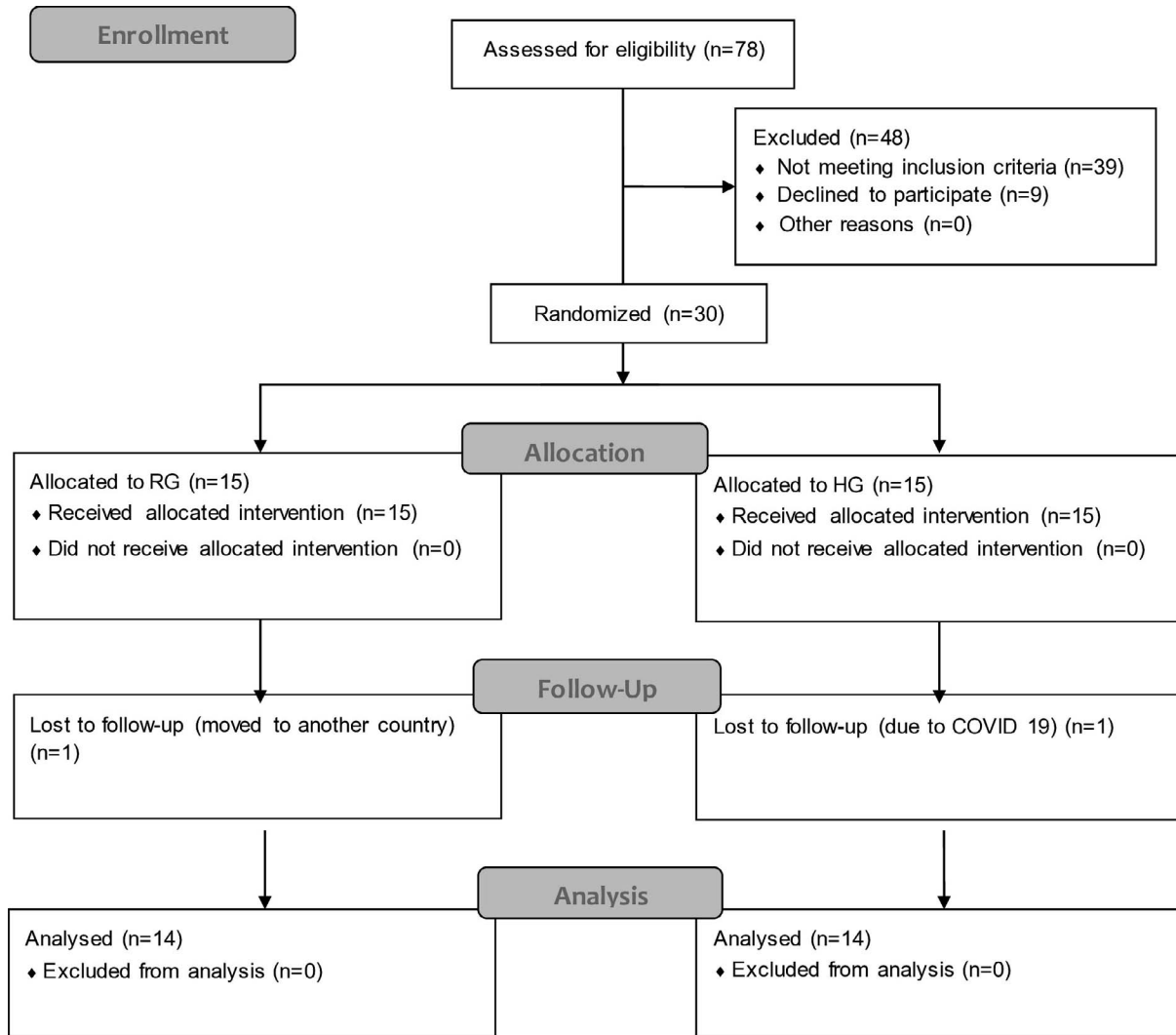


Figure 7. CONSORT (Consolidated Standards of Reporting Trials) flow diagram.

after extraction (0–21 and 52–151 days in the RG and HG, respectively) may explain the contrasting results. In contrast, Reichert et al.<sup>5</sup> reported slower movement in recent extraction sites. The difference between their findings and the current findings can be attributed to their sample, which was mixed maxillary and mandibular extraction sites, in addition to the younger average age (14.8 years); additionally, the initiation time point of

retraction in the recent group was between 2 and 4 weeks after extraction.

In agreement with Häslér et al.<sup>2</sup> there was no significant difference between RG and HG in canine rotation occurring during retraction, whereas distal tipping of the canine was significantly greater in RG ( $P = .001$ ). That may have been due to the longer canine root compared with the root of the extracted first

Table 2. Descriptive Statistics for the Sample<sup>a</sup>

Group	Sex	Age, Mean (SD), y	Maximum Age, y	Minimum Age, y	ANB, Mean (SD), °	MM, Mean (SD), °
RG	Males: 1 Females: 13	19.22 (2.26)	22	16.5	5.7 (1.9)	26.8 (4.6)
HG	Males: 5 Females: 9	19.72 (3.03)	25.5	16	5.2 (1.7)	26.8 (5.2)
Total	Males: 6 Females: 22	19.47 (2.73)	25.5	16	5.5 (1.8)	26.8 (4.7)

<sup>a</sup> RG indicates recent group; HG: healed group; SD, standard deviation; MM, max/mand plane angle.

**Table 3.** Systematic and Random Error in the Measurements

Variable	First Measurement Means	Second Measurement Means	Mean Difference	P Value <sup>a</sup>	ICC <sup>b</sup>
BH	7.36	8.44	1.07	.197	.950
PH	4.07	4.09	0.02	.598	.997
MH	1.56	1.57	0.01	.969	.934
DH	2.93	2.98	0.05	.060	.999
B-Th3	0.45	0.41	0.03	.070	.991
B-Th6	0.33	0.33	0.00	.718	.976
P-Th3	0.21	0.21	0.00	.864	.974
P-Th6	1.27	1.20	0.07	.056	.985
Tip3	95.30	95.60	0.30	.245	.995
Rot3	63.55	62.94	0.61	.119	.996
Rot6	74.79	74.12	0.67	.226	.955
Dis3	41.59	41.68	0.09	.142	.998
Dis6	22.42	22.50	0.08	.116	.985

<sup>a</sup> Applying paired *t*-tests.<sup>b</sup> Intraclass correlation coefficients.

premolar, thus resulting in varying bone density between the apical and cervical areas (the center of resistance of the canine might be located more apically). In turn, more tipping may have resulted when retraction was initiated before bone healing. This was in disagreement with Abu Alhajja et al.,<sup>3</sup> who found that

the greater tipping on the recent side was not significant. That may have been due to their measurement method based on the difference between coronal and gingival extraction space. In addition, their retraction method was an elastomeric power chain from the second molar to the second molar.

In the current study, there were no significant differences in rotation and mesial movement of the first molar between the groups. These changes were not assessed by any previous study.

The current results showed significant apical migration of mesial bone by 0.50 and 0.71 mm in RG and HG, respectively. This may have been due to distal tipping of the canine causing occlusal movement of the mesial CEJ relative to the mesial bone crest. Also, there was significant apical migration of distal bone (0.46 mm) and an increase in P-Th6 (0.42 mm) in RG and a reduction in B-Th3 (0.23 mm) in HG. The decrease in bone height or thickness of approximately 0.5 mm or less, even though statistically significant, may be considered of little clinical importance.

There were no significant differences in mesial and distal alveolar bone height changes between RG and

**Table 4.** Comparison of Changes in Measures Between the Two Groups<sup>a</sup>

Variable	Group	Mean at T0 (SD)	Mean at T1 (SD)	P Value <sup>b</sup>	Difference T0-T1 (SD)	P Value <sup>c</sup>
BH, mm	RG	3.39 (4.52) AL	7.44 (6.64) AL	.066	-4.05 (6.81) AL	.589
	HG	4.66 (5.61) AL	6.00 (5.42) AL	.090	-1.34 (4.16) AL	
PH, mm	RG	2.80 (1.54) NL	3.28 (1.38) NL	.116	-0.47 (1.53) NL	.887
	HG	2.72 (1.55) AL	3.26 (1.71) NL	.178	-0.55 (2.33) NL	
MH, mm	RG	1.26 (1.09) AL	1.77 (1.23) NL	<b>.034</b>	-0.50 (1.19) NL	.539
	HG	1.31 (1.03) NL	2.03 (1.08) AL	<b>.010</b>	-0.71 (1.56) AL	
DH, mm	RG	2.64 (2.60) AL	2.17 (2.48) AL	<b>.041</b>	0.46 (2.85) AL	.422
	HG	2.50 (2.47) AL	2.43 (3.09) AL	.400	0.07 (3.64) AL	
B-Th3, mm	RG	0.65 (0.48) AL	0.50 (0.58) AL	.190	-0.15 (0.67) NL	.567
	HG	0.59 (0.47) AL	0.36 (0.48) AL	<b>.005</b>	-0.23 (0.38) NL	
B-Th6, mm	RG	0.44 (0.49) AL	0.37 (0.52) AL	.348	-0.07 (0.47) AL	.236
	HG	0.19 (0.30) AL	0.20 (0.32) AL	.834	0.01 (0.40) AL	
P-Th3, mm	RG	0.67 (0.64) AL	0.49 (0.88) AL	.088	-0.17 (0.51) AL	.941
	HG	0.60 (0.59) AL	0.45 (0.53) AL	.330	-0.15 (0.74) NL	
P-Th6, mm	RG	1.86 (1.00) NL	2.28 (1.34) AL	<b>.040</b>	0.42 (0.96) NL	.246
	HG	1.80 (0.93) NL	1.87 (0.97) NL	.761	0.07 (1.23) NL	
Tip3, °	RG	104.09 (3.63) NL	89.31 (4.45) NL	<b>.000</b>	14.78 (3.63) NL	.001
	HG	102.64 (3.86) AL	91.34 (5.29) NL	<b>.000</b>	11.30 (3.78) NL	
Rot3, °	RG	51.16 (5.76) NL	77.50 (8.30) NL	<b>.000</b>	26.34 (8.11) NL	.064
	HG	52.68 (5.85) NL	74.27 (9.93) NL	<b>.000</b>	21.59 (10.52) NL	
Rot6, °	RG	76.31 (5.08) NL	74.98 (6.22) NL	.140	1.33 (4.62) NL	.753
	HG	74.25 (5.73) NL	72.48 (6.62) NL	.120	1.78 (5.85) NL	
Dis3, mm	RG	45.98 (2.98) NL	40.34 (3.03) NL	<b>.000</b>	5.51 (0.88) NL	.000
	HG	44.34 (2.56) NL	39.99 (2.63) NL	<b>.000</b>	4.37 (1.28) NL	
Dis6, mm	RG	22.65 (2.54) NL	23.69 (2.51) NL	<b>.000</b>	1.03 (0.51) NL	.698
	HG	22.58 (2.06) NL	23.55 (2.29) NL	<b>.000</b>	0.97 (0.65) NL	
Retraction duration, mo	RG	—	—	—	4.55 (1.37) NL	.123
	HG	—	—	—	4.09 (1.39) AL	
Canine velocity, mm/mo	RG	—	—	—	1.37 (0.51) NL	.087
	HG	—	—	—	1.15 (0.43) NL	

<sup>a</sup> Bold text: *P* value  $\leq .05$ . NL indicates normal data distribution; AL, abnormal data distribution.<sup>b</sup> *P* values from paired-sample *t*-test or Wilcoxon test.<sup>c</sup> *P* values from independent-sample *t*-test or Mann-Whitney test.

HG. This was consistent with the findings of a previous retrospective study by Spruyt and Cleaton-Jones,<sup>7</sup> in which bone height was measured using panoramic X-rays. Similarly, there were no significant differences in buccal and palatal alveolar bone heights and thicknesses at 3 and 6 mm from the CEJ, but there was no previous study that also assessed these variables. The similar changes in the dimensions of the alveolar bone may be attributed to the duration of canine retraction (4.55 and 4.09 months in RG and HG, respectively), which was sufficient for bone remodeling even when the extraction was delayed in RG.

### Limitations

The current study had some limitations that should be mentioned. There was an unequal distribution of gender in the sample, with a high female-to-male ratio. Another limitation was that there was no monthly assessment, which might have helped with better understanding of the results.

### CONCLUSIONS

Retracting canines into recent extraction sites compared to healed extraction sites showed the following:

- No significant difference in the rate of canine movement
- Greater distal tipping of the canine with no differences in canine rotation and alveolar bone dimension changes
- No significant difference in anchorage loss and first molar rotation

### REFERENCES

1. de Araújo TM, Caldas LD. Tooth extractions in orthodontics: first or second premolars? *Dental Press J Orthod.* 2019;24:88–98.
2. Häsler R, Schmid G, Ingervall B, Gebauer U. A clinical comparison of the rate of maxillary canine retraction into healed and recent extraction sites—a pilot study. *Eur J Orthod.* 1997;19:711–719.
3. Abu Alhaja ES, Al Shayeb RA, Al-Khateeb S, Daher HO, Daher SO. A comparative assessment of the amount and rate of orthodontic space closure toward a healed vs recent lower premolar extraction site: a split-mouth randomized clinical trial. *Angle Orthod.* 2022;92:463–470.
4. Zubair NR, Ehsan AA, Sakrani H, Zubair NR, Ehsan AA, Sakrani H. Comparison of mean canine retraction between healed and recently extracted site: a single center, randomized control trial. *APOS Trends Orthod.* 2021;11:132–139.
5. Reichert C, Kutschera E, Plötz C, et al. Incidence and severity of gingival invaginations associated with early versus late initiation of orthodontic space closure after tooth extraction. *J Orofac Orthop.* 2017;78:415–425.
6. Bertl K, Neuner H, Meran A, et al. Does the time-point of orthodontic space closure initiation after tooth extraction affect the incidence of gingival cleft development? A randomized controlled clinical trial. *J Periodontol.* 2020;91:572–581.
7. Spruyt J, Cleaton-Jones P. An investigation into the relationship of alveolar bone height and timing of canine retraction following premolar extraction. *J DASA.* 1983;38:285–289.
8. Samuels RHA, Orth M, Rudge SJ, Mair LH. A comparison of the rate of space closure using a nickel-titanium spring and an elastic module: a clinical study. *Am J Orthod Dentofac Orthop.* 1993;103:464–467.
9. Masaes MM, Burhan AS, Youssef M, Nawaya FR. T-loop spring vs ricketts maxillary canine retractor in canine retraction efficacy and anchorage loss control: a cone-beam computed tomography study. *AJO-DO Clin Companion.* 2022;2:26–40.
10. Morais JF, Melsen B, De Freitas KMS, Branco NC, Garib DG, Cattaneo PM. Evaluation of maxillary buccal alveolar bone before and after orthodontic alignment without extractions: a cone beam computed tomographic study. *Angle Orthod.* 2018;88:748–756.
11. Zeitounlouian TS, Zeno KG, Brad BA, Haddad RA. Three-dimensional evaluation of the effects of injectable platelet rich fibrin (i-PRF) on alveolar bone and root length during orthodontic treatment: a randomized split mouth trial. *BMC Oral Health.* 2021;21:1–10.
12. Von Fraunhofer JA, Bonds PW, Johnson BE. Force generation by orthodontic coil springs. *Angle Orthod.* 1993;63:145–148.
13. Molen AD. Considerations in the use of cone-beam computed tomography for buccal bone measurements. *Am J Orthod Dentofac Orthop.* 2010;137:S130–S135.
14. Coşkun İ, Kaya B. Cone Beam Computed Tomography in Orthodontics. *Turkish J Orthod.* 2018;31:55–61.