

# A Cross-Sectional Study of Sub-Basal Corneal Nerve Reduction Following Neurotoxic Chemotherapy

Jeremy Chung Bo Chiang<sup>1</sup>, David Goldstein<sup>2</sup>, Terry Trinh<sup>2</sup>, Kimberley Au<sup>2</sup>, David Mizrahi<sup>2</sup>, Mark Muhlmann<sup>2</sup>, Philip Crowe<sup>2</sup>, Siobhan O'Neill<sup>3</sup>, Katie Edwards<sup>4</sup>, Susanna B. Park<sup>5</sup>, Arun V. Krishnan<sup>2</sup>, and Maria Markoulli<sup>1</sup>

<sup>1</sup> School of Optometry & Vision Science, University of New South Wales, Sydney, Australia

<sup>2</sup> Prince of Wales Clinical School, University of New South Wales, Sydney, Australia

<sup>3</sup> Department of Medical Oncology, Prince of Wales Hospital, Sydney, Australia

<sup>4</sup> Institute of Health and Biomedical Innovation, Queensland University of Technology, Brisbane, Australia

<sup>5</sup> Brain and Mind Centre, Faculty of Medicine and Health, University of Sydney, Sydney, Australia

**Correspondence:** Jeremy Chung Bo, Chiang, School of Optometry & Vision Science, University of New South Wales, Sydney, Australia. e-mail: [jeremychungbo.chiang@unsw.edu.au](mailto:jeremychungbo.chiang@unsw.edu.au)

**Received:** November 12, 2020

**Accepted:** December 18, 2020

**Published:** January 12, 2021

**Keywords:** chemotherapy-induced peripheral neuropathy; corneal nerves; inferior whorl; in-vivo corneal confocal microscopy; neurotoxic chemotherapy

**Citation:** Chiang JCB, Goldstein D, Trinh T, Au K, Mizrahi D, Muhlmann M, Crowe P, O'Neill S, Edwards K, Park SB, Krishnan AV, Markoulli M. A cross-sectional study of sub-basal corneal nerve reduction following neurotoxic chemotherapy. *Trans Vis Sci Tech.* 2021;10(1):24. <https://doi.org/10.1167/tvst.10.1.24>

**Purpose:** Sub-basal corneal nerves have been shown to change during neurotoxic chemotherapy treatment. This cross-sectional study investigated corneal nerve morphology in patients who have completed neurotoxic chemotherapy well after treatment cessation and its association with peripheral nerve function.

**Methods:** Central corneal nerve fiber length (CNFL) and inferior whorl length (IWL), average nerve fiber length (ANFL), corneal nerve fiber density (CNFD) and corneal nerve branch density (CNBD), and nerve fiber area (CNFA) were examined using in vivo corneal confocal microscopy in patients with cancer who had completed treatment with either paclitaxel or oxaliplatin between 3 and 24 months prior to assessment in comparison with 2 separate groups of healthy controls. Neurological assessments were conducted including clinician- and patient-reported outcomes, and neurological grading scales.

**Results:** Both paclitaxel- ( $n = 40$ ) and oxaliplatin-treated ( $n = 30$ ) groups had reduced IWL and ANFL compared to the respective healthy control groups ( $n = 15$  in each group) (paclitaxel: IWL =  $P = 0.02$ , ANFL =  $P = 0.009$ ; and oxaliplatin: IWL =  $P = 0.008$ , ANFL =  $P = 0.02$ ). CNFL and CNFD reduction were observed only in the paclitaxel-treated group compared with healthy controls ( $P = 0.008$  and  $P = 0.02$ , respectively), whereas CNFA was reduced in the oxaliplatin-treated group ( $P = 0.04$ ). IWL reduction correlated with worse fine hand dexterity in chemotherapy-treated patients ( $r = -0.33$ ,  $P = 0.007$ ).

**Conclusions:** There is evidence of corneal nerve loss in patients with cancer who have been treated with paclitaxel and oxaliplatin well after treatment cessation associated with worse upper limb function.

**Translational Relevance:** Sub-basal corneal nerve reduction is evident even after cessation of neurotoxic treatment. In vivo corneal confocal microscopy may be useful in the monitoring of nerve function in patients receiving chemotherapy.

## Introduction

Chemotherapy-induced peripheral neuropathy (CIPN) is a distal, predominantly sensory neuropathy, which can affect both large and small nerve fiber function.<sup>1,2</sup> With increasing survival rates due to improved diagnosis and chemotherapeutic treatment of cancer, the side effect burden of CIPN has also

increased.<sup>3</sup> Notably, it is one of the most common dose-limiting factors, with debilitating neuropathic symptoms, such as pain and numbness necessitating treatment discontinuation.<sup>3</sup> It also has the potential to cause long-term sensory and functional impairments, which can negatively affect quality of life.<sup>4</sup>

The two drugs that are most commonly associated with the development of peripheral neuropathy are oxaliplatin, widely used in upper gastrointestinal

and colorectal cancers, and paclitaxel, used for the treatment of breast, gynecological, and lung cancers. Chronic neuropathy has been reported to be present in up to 84% of oxaliplatin-treated patients at 24 months follow-up.<sup>5</sup> Paclitaxel-induced peripheral neuropathy is also common with 71% of treated patients reporting neuropathic symptoms.<sup>6</sup> These symptoms can persist well after treatment, with 54% of patients reporting persistent neuropathy at 18 months post-treatment cessation.<sup>7</sup>

Despite developments in the use of validated clinician- and patient-reported outcome measures, there is no test available that provides early detection of neuropathy onset in patients receiving chemotherapy. Nerve conduction studies remain the gold standard for neuropathy diagnosis but are slow to demonstrate changes in nerve function and often correlate poorly with clinical features.<sup>8</sup> In vivo corneal confocal microscopy has been proposed as an instrument for detecting peripheral neuropathy due to its noninvasive nature and rapid method of imaging small nerves particularly in patients with diabetes.<sup>9-12</sup> Most research involving corneal assessment in CIPN were longitudinal studies during treatment without long-term follow-up to assess any persistent loss of peripheral and corneal nerves.<sup>9,13</sup> As investigations into corneal nerve morphology in patients with cancer treated with neurotoxic chemotherapy with high prevalence of persistent peripheral neuropathy well after treatment cessation is limited,<sup>14</sup> the current study aimed to observe corneal nerve morphology in patients with cancer who have received and completed treatment with paclitaxel or oxaliplatin.

## Methods

### Study Design

This cross-sectional study was approved by the South Eastern Sydney Area Health Service Human Research Ethics Committee. All methods were conducted in accordance with relevant guidelines and regulations. Participants provided written informed consent after explanation of the nature and possible consequences of the study in accordance with the tenets of the Declaration of Helsinki.

### Patient Selection

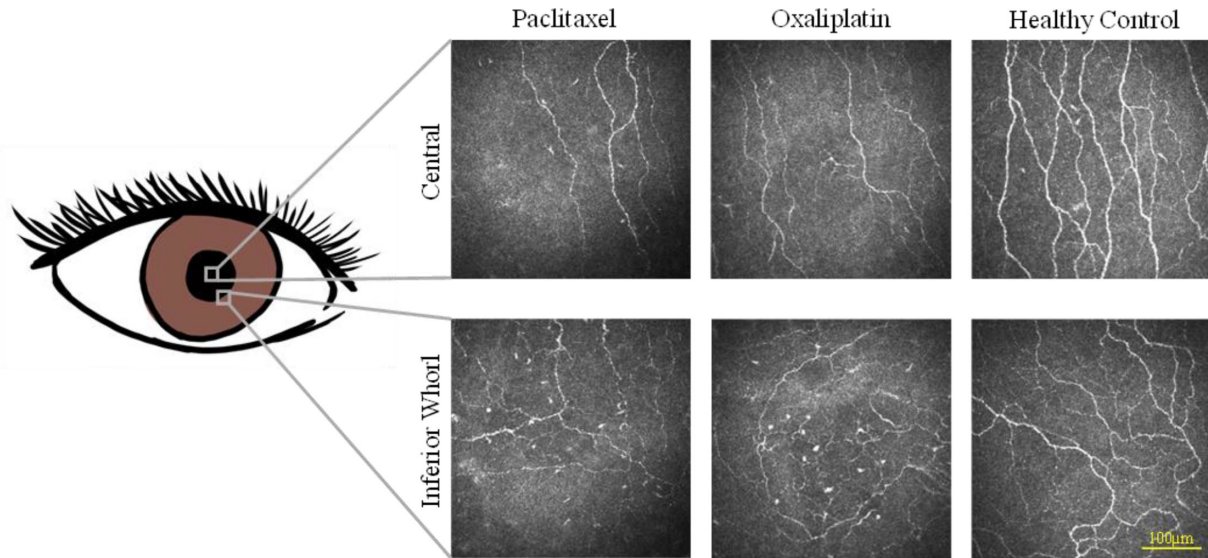
Seventy patients with cancer who had completed treatment with chemotherapy between 3 to 24 months prior to assessment ( $n = 40$  treated with paclitaxel: 36 breast and 4 gynecological cancers;  $n = 30$  treated

with oxaliplatin: 25 colorectal and 5 upper intestinal tract cancers) were recruited by convenience sampling from the Department of Medical Oncology, Prince of Wales Hospital (Sydney, Australia). Sample size calculation using G\*Power 3.1.9.4 (Heinrich Heine University, Dusseldorf, Germany) was based on the difference between the mean values for corneal nerve fiber length (CNFL) of patients with cancer completing chemotherapy ( $18.08 \pm 3.62$  mm/mm<sup>2</sup>) compared with controls ( $26.82 \pm 4.27$  mm/mm<sup>2</sup>),<sup>9</sup> and showed that 12 participants would be the minimum sample size required to show a significant difference with 90% power and alpha of 0.05. Two separate groups of age-, sex-, and body mass index (BMI)-matched healthy controls, each compared with paclitaxel- or oxaliplatin-treated groups, were recruited through contact in the local health district.

Participants were excluded if they had a history of any other medical disorders known to cause neuropathy, including impaired glucose tolerance, diabetes, and chronic kidney disease, as well as those who were pregnant or lactating, had a history of ocular trauma, ocular surgery, or refractive surgery, had any active ocular disease, such as significant corneal epitheliopathy from dry eye disease (grade >2 fluorescein staining on the Efron scale),<sup>15</sup> iritis, corneal edema, herpetic ulcers, corneal dystrophies, or glaucoma requiring treatment with intraocular pressure lowering eye drop medication, soft and rigid contact lens wear, or had known allergies to anesthetic eyedrops. Slit lamp biomicroscopy was performed to exclude clinical manifestations of these conditions.

### Assessment of Neurotoxicity

Clinical assessment was conducted using the clinician-reported outcome, National Cancer Institute Common Toxicity Criteria for Adverse Events (NCI-CTCAE) version 3 sensory subscale for peripheral neuropathy with the following grading system: grade 1, asymptomatic loss of tendon reflex or paresthesia (including tingling) but not interfering with function; grade 2, sensory alterations or paresthesia interfering with function but not interfering with activities of daily living; grade 3, sensory alterations or paresthesia interfering with activities of daily living; and grade 4, disabling.<sup>16</sup> The European Organization for Research and Treatment of Cancer (EORTC) Quality of Life – Chemotherapy-induced Peripheral Neuropathy questionnaire (QLQ-CIPN20) was incorporated as a patient-reported outcome, which assesses sensory, motor, and autonomic symptoms, in addition to functional activities of daily living.<sup>17</sup> The Total Neuropathy Scale (TNS - Johns Hopkins



**Figure 1.** In vivo corneal confocal microscopy images of the corneal sub-basal nerve plexus. The approximate anatomical locations of the central region and the inferior whorl on the illustration of an eye are shown, with representative corneal nerve images of age-matched participants treated with paclitaxel (age = 58 years) or with oxaliplatin (age = 56 years), and a healthy control (age = 54 years). Sparser nerves are evident in the paclitaxel and oxaliplatin groups compared to the healthy controls.

University) is a composite scale developed to grade neuropathy according to symptoms, signs, and nerve conduction studies.<sup>18,19</sup> The reduced TNS (TNSr) was used to grade symptomatology, clinical, and neurophysiological measures across eight domains (sensory symptoms, weakness symptoms, pin prick sensibility, vibration threshold, strength, deep tendon reflexes, sensory nerve, and motor nerve conduction studies), with grades ranging from 0 to 4, where 0 signifies no deficit and 4 represents more severe changes.<sup>18</sup> The total score ranges from 0 to 32. Nerve conduction studies were undertaken in the sural sensory and tibial motor nerves, as per standard protocols.<sup>20</sup> Functional assessment of upper limb dexterity and hand-eye coordination was conducted via timed completion of a grooved pegboard test using identical keyhole-shaped pegs with their dominant hand.<sup>21</sup> The task was completed twice, and the average time of completion was reported.

### In Vivo Corneal Confocal Microscopy

In vivo corneal confocal microscopy using a laser scanning confocal microscope (Heidelberg Retinal Tomograph III with Rostock Corneal module; Heidelberg Engineering GmbH, Heidelberg Germany) was performed on participants after the cornea has been anesthetized with sterile 0.4% benoxinate hydrochloride (oxybuprocaine hydrochloride). A sterile probe was then placed onto the cornea to capture images.

Only the right eye was imaged for all the participants, given the symmetry between the two eyes in previous studies.<sup>22,23</sup> The central cornea and inferior whorl region were scanned. Eight images best representing the central cornea with <20% overlap between images<sup>24</sup> and 3 to 5 images from the inferior whorl region were identified for analysis as previously described (Fig. 1).<sup>25</sup> Data were averaged across the eight central images and three to five inferior whorl images. The inferior whorl is the most distal portion of corneal nerves located about 2 mm inferonasal from the central cornea (see Fig. 1) and is known to be a sensitive parameter for detecting peripheral neuropathy.<sup>26</sup> Corneal nerve parameters were measured with an established automated image analysis software<sup>27,28</sup> (ACCMetrics, The University of Manchester Intellectual Property UMIP, Manchester, UK): CNFL (mm/mm<sup>2</sup>), the total length of all nerve fibers (main trunks and branches) at the central cornea, and inferior whorl length (IWL; mm/mm<sup>2</sup>), the total length of all nerve fibers and branches in the inferior whorl region given the diagnostic value of CNFL as shown in diabetic peripheral neuropathy.<sup>29</sup> The IWL is also thought to represent the most distal regions of the corneal nerve and shown to be a sensitive measure in length-dependent peripheral neuropathy in diabetes.<sup>26</sup> Additional pertinent corneal nerve parameters, including corneal nerve fiber density (CNFD; no/mm<sup>2</sup>), corneal nerve branch density (CNBD; no/mm<sup>2</sup>), corneal nerve fiber area (CNFA; mm<sup>2</sup>/mm<sup>2</sup>), and

average nerve fiber length ( $ANFL = \frac{CNFL + IWL}{2}$ , mm/mm<sup>2</sup>) have also been included given their potential diagnostic utility reflected in diabetic peripheral neuropathy.<sup>30–34</sup>

## Statistical Analysis

Statistical analysis was conducted using SPSS Statistics 26 (IBM Corp., Armonk, NY). Significance was defined as  $P \leq 0.05$ , unless stated otherwise. Normality was considered when  $P > 0.05$  in the Shapiro-Wilk test. Neurophysiological, functional, and corneal measures were compared between the paclitaxel and oxaliplatin groups with the respective healthy control groups (healthy controls group 1 with paclitaxel, and healthy controls group 2 with oxaliplatin). Chi squared test of independence was used to compare gender proportions between the groups. Normally distributed data were compared using independent samples  $t$ -test, whereas nonparametric data were compared using the Mann-Whitney  $U$  test. The two largest patient groups for each treatment type (breast cancer for paclitaxel and colorectal cancer for oxaliplatin) were also compared in terms of corneal nerve parameters.

A subanalysis of patients with neuropathy (TNSr grade  $\geq 1$ ) versus no neuropathy (TNSr grade 0) as assessed with TNSr was performed within each chemotherapeutic treatment group. Chi squared test of independence was used to compare gender proportions between the two groups. Normally distributed data were compared using independent samples  $t$ -test, whereas nonparametric data were compared using the Mann-Whitney  $U$  test. Comparisons with the respective healthy control groups matched in the primary analysis using the Kruskal Wallis test with Bonferroni adjustment were also conducted, with an adjusted  $P$  value of  $\frac{0.05}{3}$  used to assess for significance.

Partial correlation analysis was used to assess the association between corneal nerve parameters with five main measures of sensory neuropathy severity and nerve function, including grooved pegboard test, NCI-CTCAE, EORTC QLQ-CIPN20, TNSr scores, and sural nerve amplitude in chemotherapy-treated patients (both paclitaxel and oxaliplatin) after adjusting for age. The associations among stage of cancer prior to treatment, number of treatment cycles, mean cumulative dose, period post-treatment, and relative dose intensity by the two chemotherapy types with corneal nerve parameters were also assessed with correlation analysis while adjusting for age. Additionally, correlation between cancer and chemotherapy data with the measures of sensory neuropathy severity and nerve function was conducted. An adjusted  $P$  value of

$\frac{0.05}{5}$  was used to assess for significance in each correlation analysis to control for type 1 errors.

## Results

The clinical, demographic, and neurological data are presented in Table 1. Representative figures of the corneal nerve images for the paclitaxel, oxaliplatin, and healthy control groups are shown in Figure 1.

Both paclitaxel- and oxaliplatin-treated patients had severe reduction in length of the inferior whorl corneal nerves compared with their respective healthy control groups (Table 2). Only the paclitaxel-treated patients had significantly reduced CNFL in the central cornea compared with healthy controls (Table 2). ANFL and CNFD were also reduced in paclitaxel-treated patients, whereas reductions in ANFL and CNFA were noted in oxaliplatin-treated patients when compared with healthy controls (Table 2). Comparisons of the corneal nerve parameters of the two largest cancer groups showed no significant differences between patients with breast cancer who received paclitaxel treatment and patients with colorectal cancer who received oxaliplatin treatment (CNFL:  $13.5 \pm 3.7$  mm/mm<sup>2</sup> vs.  $14.2 \pm 2.4$  mm/mm<sup>2</sup>,  $P = 0.41$ ; IWL:  $13.7 \pm 4.0$  mm/mm<sup>2</sup> vs.  $12.5 \pm 3.3$  mm/mm<sup>2</sup>,  $P = 0.21$ ; ANFL:  $13.6 \pm 3.6$  mm/mm<sup>2</sup> vs.  $13.3 \pm 2.7$  mm/mm<sup>2</sup>,  $P = 0.72$ ; CNFD:  $22.7 \pm 7.6$  no/mm<sup>2</sup> vs.  $24.25 \pm 6.0$  no/mm<sup>2</sup>,  $P = 0.39$ ; CNBD:  $31.3 \pm 15.8$  no/mm<sup>2</sup> vs.  $27.6 \pm 11.6$  no/mm<sup>2</sup>,  $P = 0.47$ ; CNFA:  $0.0050 \pm 0.0014$  mm<sup>2</sup>/mm<sup>2</sup> vs.  $0.0053 \pm 0.0012$  mm<sup>2</sup>/mm<sup>2</sup>,  $P = 0.49$ ).

A subanalysis was performed on the treatment groups to explore differences in corneal nerve parameters of those with neuropathy (TNSr grade  $\geq 1$ ), those without neuropathy (TNSr grade 0), and healthy controls. Only the paclitaxel group was considered in this analysis as the oxaliplatin group had a limited number of patients without neuropathy for comparison ( $n = 1$ ). Paclitaxel-treated patients with neuropathy were older ( $P = 0.002$ ) and had worse fine hand dexterity ( $P = 0.005$ ) compared with paclitaxel-treated patients without neuropathy (Supplementary Table S1). CNFL, IWL, ANFL, and CNFD were significantly reduced in those with paclitaxel-induced neuropathy ( $n = 27$ ) compared with healthy controls ( $P = 0.001$ ,  $P = 0.004$ ,  $P = 0.001$ , and  $P = 0.002$ , respectively; Fig. 2). There was also significant CNFL, IWL, ANFL, and CNFD loss in the paclitaxel-treated group with neuropathy compared with those without neuropathy ( $n = 13$ ;  $P = 0.004$ ,  $P = 0.009$ ,  $P = 0.005$ , and  $P = 0.004$ , respectively).

**Table 1.** Clinical Characteristics, Neurophysiological, and Functional Measures of Study Participants

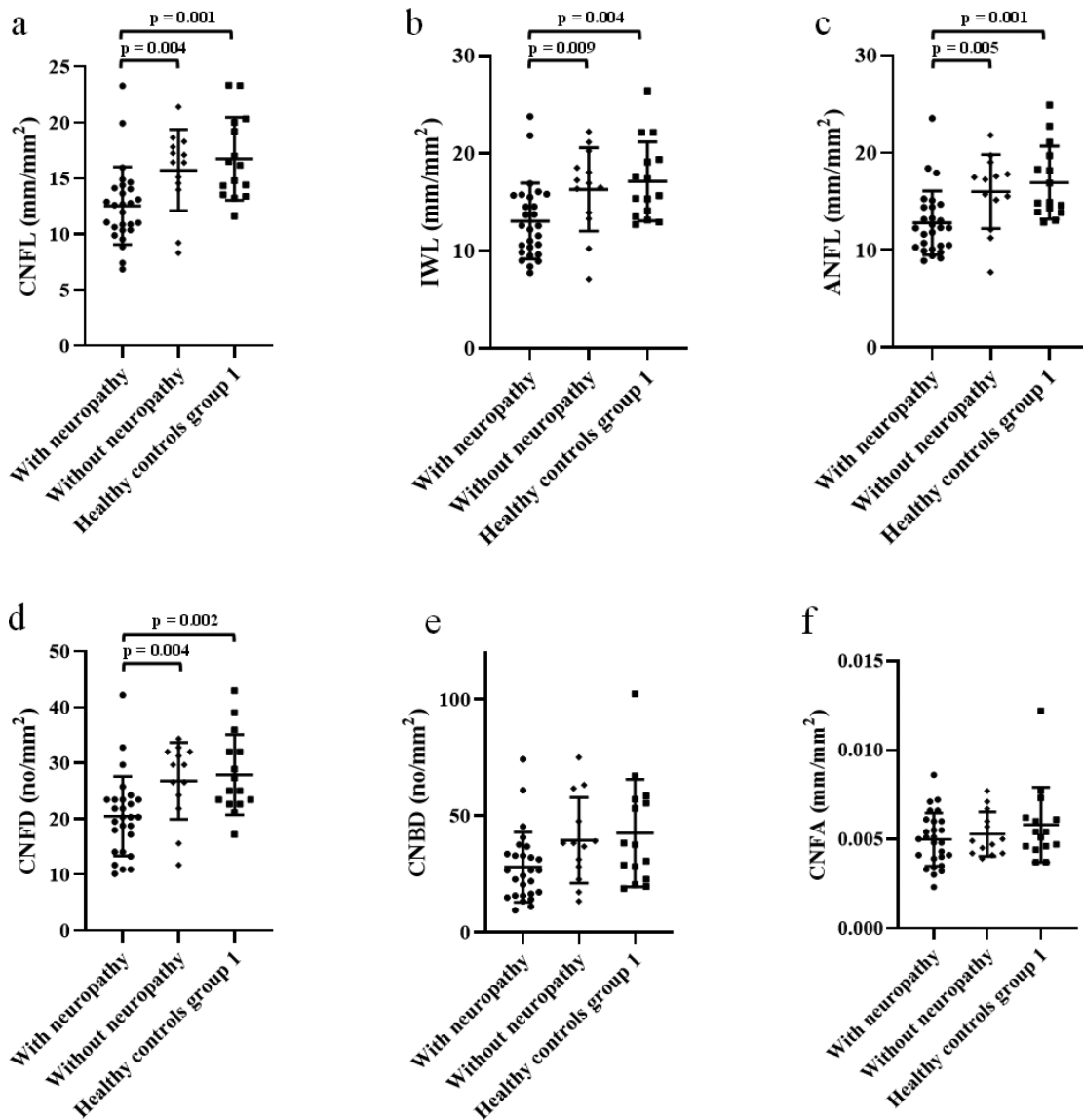
Clinical Characteristics	Participants					
	Paclitaxel (n = 40)	Healthy Control Group 1 (n = 15)	P Value	Oxaliplatin (n = 30)	Healthy Control Group 2 (n = 15)	P Value
Age, y	56.4 ± 12.5	52.1 ± 13.5	0.33	59.8 ± 8.8	58.8 ± 11.5	0.95
Gender, female, n	38 (95%)	14 (93%)	1.00	13 (45%)	6 (43%)	1.00
BMI, kg/m <sup>2</sup>	27.9 ± 5.8	26.2 ± 5.1	0.31	27.1 ± 5.0	24.5 ± 4.7	0.09
Stage of cancer prior to treatment	2 [2-3](none with metastasis)	N/A	N/A	3 [3-4](n = 8 with liver metastasis)	N/A	N/A
Number of treatment cycles	10.5 [7–12]	N/A	N/A	9 [5.8–12]	N/A	N/A
Mean cumulative dose, mg	1463.85 ± 364.45	N/A	N/A	1244.19 ± 450.82	N/A	N/A
Relative dose intensity, %	92.2 ± 13.5	N/A	N/A	92.7 ± 11.2	N/A	N/A
Period post-treatment, mo	14.3 ± 7.4	N/A	N/A	10.5 ± 7.9	N/A	N/A
NCI-CTCAE (0–4)	1 [0–2]	0 [0–0]	<b>&lt;0.001</b>	1 [1–2]	0 [0–0]	<b>&lt;0.001</b>
EORTC QLQ-CIPN20 (0–100)	15.8 [5.7–29.8]	0 [0–0]	<b>&lt;0.001</b>	19.7 [9.7–33.3]	0 [0–1.8]	<b>&lt;0.001</b>
TNSr score (0–32)	3 [1–6]	1 [0–3]	<b>0.006</b>	5 [3–8]	0 [0–1]	<b>&lt;0.001</b>
Sural nerve amplitude, μV	13.1 [9.2–18.1]	20.1 [12.2–33.7]	<b>0.02</b>	6.9 [3.5–11.3]	12.4 [9.4–26.4]	<b>0.002</b>
Tibial nerve amplitude, mV	12.6 [6.9–17.0]	12.9 [9.5–19.4]	0.32	9.3 [4.1–13.3]	10.8 [7.1–13.2]	0.28
Grooved pegboard test, s	70.7 ± 15.0	61.1 ± 8.3	0.07	85.1 ± 24.7	65.2 ± 8.6	<b>0.02</b>

Relative dose intensity (actual dose received/actual dose prescribed) is expressed as a percentage. Data is reported as mean ± SD, or median [interquartile range, quartile 1 to quartile 3]. Abbreviations: BMI, body mass index; NCI-CTCAE, National Cancer Institute Common Toxicity Criteria for Adverse Events; EORTC QLQ-CIPN20, the European Organization for Research and Treatment of Cancer Quality of Life – Chemotherapy-induced Peripheral Neuropathy questionnaire; TNSr, reduced version of Total Neuropathy Scale.

**Table 2.** In Vivo Corneal Confocal Microscopy Parameters of Study Participants

Sub-Basal Corneal Nerve Parameters	Participants					
	Paclitaxel (n = 40)	Healthy Controls Group 1 (n = 15)	P Value	Oxaliplatin (n = 30)	Healthy Controls Group 2 (n = 15)	P Value
CNFL, mm/mm <sup>2</sup>	13.6 ± 3.8	16.8 ± 3.7	<b>0.008</b>	13.9 ± 2.5	16.3 ± 4.7	0.09
IWL, mm/mm <sup>2</sup>	14.1 ± 4.3	17.1 ± 4.1	<b>0.02</b>	12.5 ± 3.3	17.4 ± 5.9	<b>0.008</b>
ANFL, mm/mm <sup>2</sup>	13.8 ± 3.7	16.9 ± 3.7	<b>0.009</b>	13.2 ± 2.6	16.8 ± 4.9	<b>0.02</b>
CNFD, no/mm <sup>2</sup>	22.5 ± 7.6	27.9 ± 7.2	<b>0.02</b>	23.6 ± 6.0	26.8 ± 9.5	0.18
CNBD, no/mm <sup>2</sup>	31.7 ± 16.9	42.5 ± 23.1	0.11	26.1 ± 11.2	36.1 ± 22.3	0.13
CNFA, mm <sup>2</sup> /mm <sup>2</sup>	0.0051 ± 0.0014	0.0058 ± 0.0021	0.28	0.0052 ± 0.0012	0.0067 ± 0.0031	<b>0.04</b>

All data is reported as mean ± SD. Abbreviations: CNFL, corneal nerve fiber length; IWL, inferior whorl length; ANFL, average nerve fiber length; CNFD, corneal nerve fiber density; CNBD, corneal nerve branch density; CNFA, corneal nerve fiber area.



**Figure 2.** Scatterplots of (a) corneal nerve fiber length (CNFL), (b) inferior whorl length (IWL), (c) average nerve fiber length (ANFL), (d) corneal nerve fiber density (CNFD), (e) corneal nerve branch density (CNBD), and (f) corneal nerve fiber area (CNFA) in patients treated with paclitaxel who have established peripheral neuropathy and those without neuropathy compared with healthy controls. Healthy controls group 1 represent the group of age-, sex-, and body mass index-matched healthy controls for the paclitaxel group. Scatterplots show the mean and standard deviation bars with significant differences highlighted.

CNBD and CNFA were not considered significantly different between those with neuropathy compared with those without neuropathy ( $P = 0.034$  and  $P = 0.53$ , respectively) or healthy controls ( $P = 0.027$  and  $P = 0.25$ , respectively). There were no significant differences in CNFL, IWL, ANFL, CNFD, CNBD, and CNFA between the patients without neuropathy and healthy controls ( $P = 0.75$ ,  $P = 0.90$ ,  $P = 0.75$ ,  $P = 0.99$ ,  $P = 0.99$ , and  $P = 0.56$ , respectively; Supplementary Table S2).

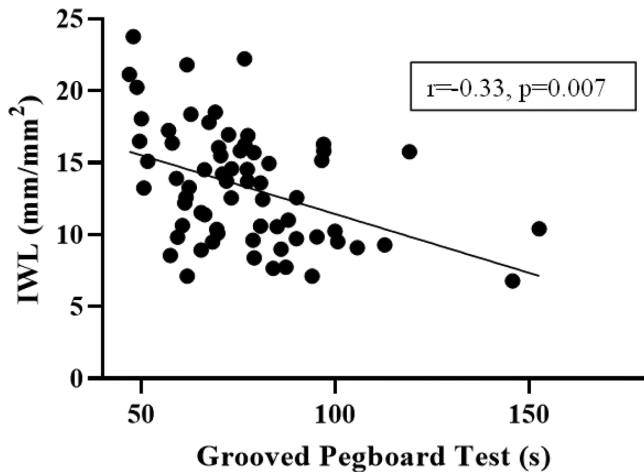
The relationship between corneal nerve parameters and peripheral nerve measures were also analyzed. IWL

reduction correlated with worse functional outcomes in terms of fine dexterity of the upper extremities in chemotherapy-treated patients (Table 3, Fig. 3). When analyzed by chemotherapy type, corneal nerve parameters did not correlate with stage of cancer prior to treatment, number of treatment cycles, mean cumulative dose, relative dose intensity, or period post-treatment for either the paclitaxel- or oxaliplatin-treated group (Supplementary Tables S3, S4). In investigating the association between chemotherapy dosage and neurophysiological measures, the number of treatment cycles for oxaliplatin correlated significantly with

**Table 3.** Correlation Matrix Summarizing Associations Between Corneal Measures, and Neurophysiological and Functional Measures After Adjusting for Age in Chemotherapy-Treated Patients

	NCI-CTCAE	EORTC QLQ-CIPN20	TNSr Score	Grooved Pegboard Test	Sural Nerve Amplitude
<b>CNFL</b>	-0.19 ( <i>P</i> = 0.12)	-0.10 ( <i>P</i> = 0.44)	-0.002 ( <i>P</i> = 0.99)	-0.07 ( <i>P</i> = 0.56)	0.15 ( <i>P</i> = 0.24)
<b>IWL</b>	-0.24 ( <i>P</i> = 0.04)	-0.17 ( <i>P</i> = 0.16)	-0.22 ( <i>P</i> = 0.07)	<b>-0.33 (<i>P</i> = 0.007)</b>	0.23 ( <i>P</i> = 0.08)
<b>ANFL</b>	-0.25 ( <i>P</i> = 0.04)	-0.15 ( <i>P</i> = 0.21)	-0.14 ( <i>P</i> = 0.27)	-0.24 ( <i>P</i> = 0.051)	0.22 ( <i>P</i> = 0.08)
<b>CNFD</b>	-0.15 ( <i>P</i> = 0.22)	-0.01 ( <i>P</i> = 0.92)	0.009 ( <i>P</i> = 0.94)	-0.13 ( <i>P</i> = 0.31)	0.19 ( <i>P</i> = 0.14)
<b>CNBD</b>	-0.19 ( <i>P</i> = 0.11)	-0.05 ( <i>P</i> = 0.67)	-0.05 ( <i>P</i> = 0.67)	-0.12 ( <i>P</i> = 0.36)	0.14 ( <i>P</i> = 0.27)
<b>CNFA</b>	0.01 ( <i>P</i> = 0.93)	-0.04 ( <i>P</i> = 0.74)	0.17 ( <i>P</i> = 0.16)	0.06 ( <i>P</i> = 0.62)	-0.10 ( <i>P</i> = 0.43)

Data are reported as *r* (*P* value), with statistically significant correlations highlighted in bold. Abbreviations: CNFL, corneal nerve fiber length; IWL, inferior whorl length; ANFL, average nerve fiber length; CNFD, corneal nerve fiber density; CNBD, corneal nerve branch density; CNFA, corneal nerve fiber area; NCI-CTCAE, National Cancer Institute Common Toxicity Criteria for Adverse Events; EORTC QLQ-CIPN20, the European Organization for Research and Treatment of Cancer Quality of Life – Chemotherapy-induced Peripheral Neuropathy Questionnaire; TNSr, reduced version of Total Neuropathy Scale.



**Figure 3.** Scatterplot showing association between corneal nerve inferior whorl lengths (IWL) and increased grooved pegboard test completion times after accounting for age in partial correlation analysis in chemotherapy-treated patients.

TNSr scores (Supplementary Table S5). No significant associations were noted between chemotherapy dosage and cancer staging with neurophysiological measures in paclitaxel-treated patients (Supplementary Table S6).

## Discussion

The present study explored the differences in corneal nerve parameters in patients with cancer who have completed treatment with two commonly used neurotoxic chemotherapies. A significant reduction in the corneal nerve fiber length particularly at the inferior whorl regions reflected a loss of nerves in patients who

completed treatment with paclitaxel and oxaliplatin treatments. Interestingly, corneal nerve loss particularly in the inferior whorl regions, the most distal portion of the corneal nerves, was associated with functional loss in terms of fine dexterity in the upper extremities, suggesting an association between corneal measures and peripheral functional outcomes. Similar central and inferior whorl corneal nerve changes have been found in diabetic peripheral neuropathy.<sup>35,36</sup> Although previous research has shown evidence of corneal nerve dysfunction in patients receiving neurotoxic chemotherapy,<sup>9,37</sup> the current study involved a more comprehensive assessment of CIPN, including clinical, symptomatology, and functional tests. The large sample size enabled us to detect a significant difference in the corneal nerve measures with greater power.

The current novel findings suggest that in vivo corneal confocal microscopy, a noninvasive and rapid test, combined with a validated automated software<sup>27,28</sup> is able to analyze and detect corneal nerve length reduction in chemotherapy-treated patients, particularly those with peripheral neuropathy after treatment. Similar findings have already been demonstrated in patients with diabetes and early corneal changes have been shown to be predictive of neuropathy in prediabetic and diabetic cohorts.<sup>10,11,29</sup> Although evidence of an association between corneal nerve reduction and local clinical corneal measures, such as corneal sensitivity or ocular surface discomfort remains equivocal,<sup>38,39</sup> this study shows evidence of corneal nerve loss in a neurotoxic systemic condition. The current study cannot exclude an even greater effect of corneal nerve fiber loss during or immediately after cessation of chemotherapy treatment, however,

even at a delayed time point, a significant loss in corneal nerve fiber lengths was evident. Whereas the CNFL values of healthy controls in the current study seem to be lower than a few studies,<sup>40,41</sup> the values are comparable to others using similar methodologies.<sup>42–45</sup> This may also be due to the more advanced ages of healthy controls that were involved in the current study for age-matching with the patients with cancer.<sup>25,46</sup> A limitation of this study is not stratifying patients according to dry eye severity, which may impact on nerve morphology.<sup>44</sup> Future studies will investigate the association between ocular surface discomfort symptomatology with corneal and peripheral nerve involvement. Another limitation is that only one eye was examined, however, previous studies have shown symmetry in healthy corneal nerve fiber parameters and pattern of loss in the context of peripheral neuropathy.<sup>22,23,47</sup> Additionally, testing one eye reduced the test burden on patients who have a recent history of cancer and chemotherapy treatment, and enabled shortening of the protocol to assist with flow of assessments.

A longitudinal study by Ferdousi and colleagues showed that patients with gastrointestinal cancer had reduced CNFL prior to oxaliplatin or cisplatin treatment, whereas CNFL increased from baseline while undergoing treatment.<sup>9</sup> The baseline reduction of CNFL may be attributed to existing subclinical peripheral neuropathy, which may be associated with gastrointestinal cancers.<sup>48</sup> The current study is limited by its cross-sectional design to investigate this association, as it assessed the effects of peripheral neuropathy persisting after treatment on limb function and corneal nerve morphology. However, a remote effect of cancer is unlikely as paraneoplastic effects typically predate cancer diagnosis by months to years.<sup>49</sup> Moreover, paraneoplastic syndromes generally improve with treatment of the underlying tumor. The current study demonstrated corneal nerve changes following treatment cessation, which would be more consistent with a treatment effect rather than a remote effect of cancer. The increase in CNFL observed by Ferdousi and colleagues may be an acute aberrant regenerative response of the corneal nerves to the initial chemotherapy insult. Corneal tortuosity or microneuromas would be insightful measures to be included in future studies to investigate putative aberrant regeneration of corneal nerves.

Significant corneal nerve reduction at both the central cornea and inferior whorl in paclitaxel-treated patients as compared to mainly inferior whorl length reduction in oxaliplatin-treated patients versus healthy controls may indicate that paclitaxel potentially affects small nerve fibers of the cornea more

extensively, despite paclitaxel having a lower proportion of patients with peripheral neuropathy manifesting clinically compared to oxaliplatin-treated patients. This may suggest differences in pathophysiological mechanisms and clinical expression of neurotoxicity between the two chemotherapies. Prior research has shown that oxaliplatin affects large nerve fiber function as indicated by reduced sensory nerve amplitudes and elevated vibration thresholds, whereas small fiber morphology represented by intra-epidermal nerve fiber density involved in pain and temperature signaling seem to be less affected.<sup>50,51</sup> In contrary, corneal nerve fiber involvement has been shown to be reduced in mice treated with oxaliplatin.<sup>52</sup> However, the evidence for small fiber involvement with paclitaxel treatment is more convincing, as shown by reduction in both intraepidermal and corneal nerve fiber densities.<sup>53,54</sup> Motor nerves are usually only minimally involved in CIPN as found by Bennedsgaard and colleagues,<sup>14</sup> which is also reflected in the current study. Large sensory nerve fiber function in nerve conduction studies have been shown to be reduced with CIPN.<sup>14</sup> However, a cutoff value for sensory nerve conduction amplitudes for diagnosing CIPN is currently absent, with clinicians and researchers instead proposing a multimodal approach incorporating symptomatology as well as large and small nerve fiber assessments.<sup>8,14</sup> Future investigation of the ability of sensory nerve conduction studies and in vivo corneal confocal microscopy in differentiating patients with and without peripheral neuropathy during development and progression of the condition in longitudinal studies is warranted.

Of clinical significance, the paclitaxel group with established neuropathy also showed significantly reduced corneal nerve parameters compared with healthy controls, whereas those without neuropathy had similar levels of corneal nerve fiber lengths to healthy controls. This implies that corneal nerve dysfunction is more evident in patients with CIPN, and raises the possibility of using this technique to monitor nerve function in patients receiving paclitaxel. Although the age of paclitaxel-treated patients with neuropathy is higher than those without neuropathy, it is unlikely that the difference in corneal nerve parameters is due to an age effect as the discrepancy observed exceeds physiological decrease due to normal aging seen in previous studies ( $-0.06$  mm/mm<sup>2</sup> per year in CNFL,<sup>46</sup>  $-0.171$  no/mm<sup>2</sup> per year in CNFD<sup>25</sup>). Whereas the current study did not find an association between cumulative dose of chemotherapy with corneal nerve loss, the relationship and impact of dosing on corneal nerve fibers may be more appreciated when patients are undergoing treatment. Hence,



longitudinal studies that involve prospective monitoring of patients with cancer receiving neurotoxic chemotherapy treatment from baseline are needed to provide a more insightful understanding of the potential effect of treatment on corneal nerve parameters in parallel with neurophysiological measures associated with the development of neuropathy. This will provide a more definitive answer regarding the association between neurotoxic chemotherapy and corneal nerve changes. Future studies should also explore the corneal effects of other neurotoxic chemotherapy drugs, including vinca alkaloids, epothilones, immunomodulatory therapies, and proteasome inhibitors.

The current study presents evidence of corneal nerve loss in patients who have completed paclitaxel and oxaliplatin. Patients treated with either paclitaxel or oxaliplatin with more severe reduction in corneal nerve parameters was associated with reduced fine dexterity of the hands. Larger studies involving a longitudinal design will be of value in the future to investigate the potential of in vivo corneal confocal microscopy in identifying corneal nerve changes during treatment.

## Acknowledgments

The authors acknowledge the help with patient recruitment provided by the surgical and medical oncology staff from the Prince of Wales Hospital. The Total Neuropathy Scale was provided to Professor Arun Krishnan, MBBS, FRACP, PhD (Prince of Wales Clinical School, University of New South Wales) by Professor David Cornblath, MD (Johns Hopkins University). The illustrative artwork of the eye (Fig. 1) was provided by Mr. Bertin Huynh (University of Technology Sydney).

Supported by an Australian Government Research Training Program (RTP) Scholarship awarded by UNSW Sydney to JCB Chiang. This study was supported by a Cancer Institute NSW Program Grant (14/TPG/1-05) and a National Health and Medical Research Council of Australia (NHMRC) Project Grant (1080521). S.B. Park is supported by an NHMRC Career Development Fellowship (1148595).

Disclosure: **J.C.B. Chiang**, None; **D. Goldstein**, None; **T. Trinh**, None; **K. Au**, None; **D. Mizrahi**, None; **M. Muhlmann**, None; **P. Crowe**, None; **S. O'Neill**, None; **K. Edwards**, None; **S.B. Park**, None; **A.V. Krishnan**, None; **M. Markoulli**, None

## References

- Argyriou AA, Park SB, Islam B, et al. Neurophysiological, nerve imaging and other techniques to assess chemotherapy-induced peripheral neurotoxicity in the clinical and research settings. *J Neurol Neurosurg Psychiatry*. 2019;90:1361–1369.
- Timmins HC, Li T, Kiernan MC, Horvath LG, Goldstein D, Park SB. Quantification of small fiber neuropathy in chemotherapy treated patients. *J Pain*. 2019;21(1–2):44–58.
- Shah A, Hoffman EM, Mauermann ML, et al. Incidence and disease burden of chemotherapy-induced peripheral neuropathy in a population-based cohort. *J Neurol Neurosurg Psychiatry*. 2018;89:636–641.
- Li T, Timmins H, Harrison M, et al. Long term improvements in chemotherapy induced peripheral neuropathy-objective improvement or patient adaptation? *Support Care Cancer*. 2018;26 (2 suppl 1):S160–S161.
- Briani C, Argyriou AA, Izquierdo C, et al. Long-term course of oxaliplatin-induced polyneuropathy: a prospective 2-year follow-up study. *J Peripher Nerv Syst*. 2014;19:299–306.
- Park SB, Lin CS, Krishnan AV, Friedlander ML, Lewis CR, Kiernan MC. Early, progressive, and sustained dysfunction of sensory axons underlies paclitaxel-induced neuropathy. *Muscle Nerve*. 2011;43:367–374.
- Park SB, Kwok JB, Friedlander M, et al. Clinical and genetic predictors of paclitaxel neurotoxicity based on patient- versus clinician-reported incidence and severity of neurotoxicity in the ICON7 trial. *Ann Oncol*. 2017;28:2733–2740.
- McCrary JM, Goldstein D, Boyle F, et al. Optimal clinical assessment strategies for chemotherapy-induced peripheral neuropathy (CIPN): a systematic review and Delphi survey. *Support Care Cancer*. 2017;25:3485–3493.
- Ferdousi M, Azmi S, Petropoulos IN, et al. Corneal confocal microscopy detects small fibre neuropathy in patients with upper gastrointestinal cancer and nerve regeneration in chemotherapy induced peripheral neuropathy. *PLoS One*. 2015;10:e0139394–e0139394.
- Ziegler D, Papanas N, Zhivov A, et al. Early detection of nerve fiber loss by corneal confocal microscopy and skin biopsy in recently diagnosed type 2 diabetes. *Diabetes*. 2014;63:2454–2463.
- Azmi S, Ferdousi M, Petropoulos IN, et al. Corneal confocal microscopy identifies small-fiber neuropathy in subjects with impaired glucose

- tolerance who develop type 2 diabetes. *Diabetes Care*. 2015;38:1502–1508.
12. Azmi S, Ferdousi M, Alam U, et al. Small-fibre neuropathy in men with type 1 diabetes and erectile dysfunction: A cross-sectional study. *Diabetologia*. 2017;60:1094–1101.
  13. Campagnolo M, Lazzarini D, Fregona I, et al. Corneal confocal microscopy in patients with oxaliplatin-induced peripheral neuropathy. *J Peripher Nerv Syst*. 2013;18:269–271.
  14. Bennedsgaard K, Ventzel L, Andersen NT, et al. Oxaliplatin- and docetaxel-induced polyneuropathy: Clinical and neurophysiological characteristics. *J Peripher Nerv Syst*. 2020;25(4):377–387.
  15. Efron N, Morgan PB, Katsara SS. Validation of grading scales for contact lens complications. *Ophthalmic Physiol Opt*. 2001;21:17–29.
  16. Trotti A, Colevas AD, Setser A, et al. CTCv3.0: development of a comprehensive grading system for the adverse effects of cancer treatment. *Semin Radiat Oncol*. 2003;13:176–181.
  17. Postma TJ, Aaronson NK, Heimans JJ, et al. The development of an EORTC quality of life questionnaire to assess chemotherapy-induced peripheral neuropathy: The QLQ-CIPN20. *Eur J Cancer*. 2005;41:1135–1139.
  18. Cavaletti G, Bogliun G, Marzorati L, et al. Grading of chemotherapy-induced peripheral neurotoxicity using the Total Neuropathy Scale. *Neurology*. 2003;61:1297–1300.
  19. Cornblath DR, Chaudhry V, Carter K, et al. Total neuropathy score: Validation and reliability study. *Neurology*. 1999;53:1660–1664.
  20. Liveson J, Ma J. *Laboratory Reference for Clinical Neurophysiology*. Oxford, UK: Oxford University Press; 1992.
  21. Ruff RM, Parker SB. Gender- and age-specific changes in motor speed and eye-hand coordination in adults: normative values for the Finger Tapping and Grooved Pegboard Tests. *Percept Mot Skills*. 1993;76:1219–1230.
  22. Misra S, Craig JP, McGhee CN, Patel DV. Interocular comparison by in vivo confocal microscopy of the 2-dimensional architecture of the normal human corneal subbasal nerve plexus. *Cornea*. 2012;31:1376–1380.
  23. Parissi M, Karanis G, Randjelovic S, et al. Standardized baseline human corneal subbasal nerve density for clinical investigations with laser-scanning in vivo confocal microscopy. *Invest Ophthalmol Vis Sci*. 2013;54:7091–7102.
  24. Vagenas D, Pritchard N, Edwards K, et al. Optimal image sample size for corneal nerve morphometry. *Optom Vis Sci*. 2012;89:812–817.
  25. Tummanapalli SS, Willcox MDP, Issar T, et al. The effect of age, gender and body mass index on tear film neuromediators and corneal nerves. *Curr Eye Res*. 2020;45:411–418.
  26. Kalteniece A, Ferdousi M, Petropoulos I, et al. Greater corneal nerve loss at the inferior whorl is related to the presence of diabetic neuropathy and painful diabetic neuropathy. *Sci Rep*. 2018;8:3283.
  27. Dabbah MA, Graham J, Petropoulos IN, Tavakoli M, Malik RA. Automatic analysis of diabetic peripheral neuropathy using multi-scale quantitative morphology of nerve fibres in corneal confocal microscopy imaging. *Med Image Anal*. 2011;15:738–747.
  28. Chen X, Graham J, Dabbah MA, Petropoulos IN, Tavakoli M, Malik RA. An automatic tool for quantification of nerve fibers in corneal confocal microscopy images. *IEEE Trans Biomed Eng*. 2017;64:786–794.
  29. Perkins BA, Lovblom LE, Bril V, et al. Corneal confocal microscopy for identification of diabetic sensorimotor polyneuropathy: A pooled multinational consortium study. *Diabetologia*. 2018;61:1856–1861.
  30. Chen X, Graham J, Dabbah MA, et al. Small nerve fiber quantification in the diagnosis of diabetic sensorimotor polyneuropathy: Comparing corneal confocal microscopy with intraepidermal nerve fiber density. *Diabetes Care*. 2015;38:1138–1144.
  31. Brines M, Culver DA, Ferdousi M, et al. Corneal nerve fiber size adds utility to the diagnosis and assessment of therapeutic response in patients with small fiber neuropathy. *Sci Rep*. 2018;8:4734.
  32. Alam U, Jeziorska M, Petropoulos IN, et al. Diagnostic utility of corneal confocal microscopy and intra-epidermal nerve fibre density in diabetic neuropathy. *PLoS One*. 2017;12:e0180175.
  33. Ferdousi M, Kalteniece A, Petropoulos I, et al. Diabetic neuropathy is characterized by progressive corneal nerve fiber loss in the central and inferior whorl regions. *Invest Ophthalmol Vis Sci*. 2020;61:48.
  34. Ferdousi M, Kalteniece A, Azmi S, et al. Diagnosis of neuropathy and risk factors for corneal nerve loss in type 1 and type 2 diabetes: A corneal confocal microscopy study. *Diabetes Care*, <https://doi.org/10.2337/dc20-1482>. [Online ahead of print.]
  35. Zhao K, Yu H, Zheng X, et al. Use of the inferior whorl to detecting age-related changes in human corneal subbasal nerve plexus with laser-scanning confocal microscopy. *Ophthalmic Res*, <https://doi.org/10.1159/000506952>. [Online ahead of print.]
  36. Tummanapalli SS, Issar T, Kwai N, et al. A comparative study on the diagnostic utility of corneal

- confocal microscopy and tear neuromediator levels in diabetic peripheral neuropathy. *Curr Eye Res.* 2020;45:921–930.
37. Venkitaraman R, Sharma S, Soomal R, Scrase CD, Rayman G. Chemotherapy-induced peripheral neuropathy: A prospective study using methods of small fibre function and structure. *J Clin Oncol.* 2015;33:e20723–e20723.
  38. Zhang J, Zhao Z, Shao C, et al. Degeneration of corneal sensation and innervation in patients with facial paralysis: A cross-sectional study using in vivo confocal microscopy. *Curr Eye Res.* 2019;44:1209–1215.
  39. Belmonte C, Nichols JJ, Cox SM, et al. TFOS DEWS II Pain and Sensation Report. *Ocul Surf.* 2017;15:404–437.
  40. Azmi S, Jeziorska M, Ferdousi M, et al. Early nerve fibre regeneration in individuals with type 1 diabetes after simultaneous pancreas and kidney transplantation. *Diabetologia.* 2019;62:1478–1487.
  41. Brines M, Culver DA, Ferdousi M, et al. Corneal nerve fiber size adds utility to the diagnosis and assessment of therapeutic response in patients with small fiber neuropathy. *Sci Rep.* 2018;8:4734.
  42. Yan A, Issar T, Tummanapalli SS, et al. Relationship between corneal confocal microscopy and markers of peripheral nerve structure and function in type 2 diabetes. *Diabet Med.* 2020;37:326–334.
  43. Klitsch A, Evdokimov D, Frank J, et al. Reduced association between dendritic cells and corneal sub-basal nerve fibers in patients with fibromyalgia syndrome. *J Peripher Nerv Syst.* 2019;25(1):9–18.
  44. Giannaccare G, Pellegrini M, Sebastiani S, Moscardelli F, Versura P, Campos EC. In vivo confocal microscopy morphometric analysis of corneal subbasal nerve plexus in dry eye disease using newly developed fully automated system. *Graefes Arch Clin Exp Ophthalmol.* 2019;257:583–589.
  45. Ferdousi M, Romanchuk K, Mah JK, et al. Early corneal nerve fibre damage and increased Langerhans cell density in children with type 1 diabetes mellitus. *Sci Rep.* 2019;9:8758.
  46. Tavakoli M, Ferdousi M, Petropoulos IN, et al. Normative values for corneal nerve morphology assessed using corneal confocal microscopy: A multinational normative data set. *Diabetes Care.* 2015;38:838–843.
  47. Petropoulos IN, Alam U, Fadavi H, et al. Corneal nerve loss detected with corneal confocal microscopy is symmetrical and related to the severity of diabetic polyneuropathy. *Diabetes Care.* 2013;36:3646–3651.
  48. Reddy SM, Vergo MT, Paice JA, et al. Quantitative sensory testing at baseline and during cycle 1 oxaliplatin infusion detects subclinical peripheral neuropathy and predicts clinically overt chronic neuropathy in gastrointestinal malignancies. *Clin Colorectal Cancer.* 2016;15:37–46.
  49. Höftberger R, Rosenfeld MR, Dalmau J. Update on neurological paraneoplastic syndromes. *Curr Opin Oncol.* 2015;27:489–495.
  50. Kroigard T, Svendsen TK, Wirenfeldt M, et al. Early changes in tests of peripheral nerve function during oxaliplatin treatment and their correlation with chemotherapy-induced polyneuropathy symptoms and signs. *Eur J Neurol.* 2020;27:68–76.
  51. de Carvalho Barbosa M, Kosturakis AK, Eng C, et al. A quantitative sensory analysis of peripheral neuropathy in colorectal cancer and its exacerbation by oxaliplatin chemotherapy. *Cancer Res.* 2014;74:5955–5962.
  52. Tyler EF, Misra SL, McGhee CNJ, Zhang J. Corneal nerve plexus changes induced by oxaliplatin chemotherapy and ergothioneine antioxidant supplementation. *Clin Exp Ophthalmol.* 2020;48:264–266.
  53. Ferrari G, Nalassamy N, Downs H, Dana R, Oaklander AL. Corneal innervation as a window to peripheral neuropathies. *Exp Eye Res.* 2013;113:148–150.
  54. Ko MH, Hu ME, Hsieh YL, Lan CT, Tseng TJ. Peptidergic intraepidermal nerve fibers in the skin contribute to the neuropathic pain in paclitaxel-induced peripheral neuropathy. *Neuropeptides.* 2014;48:109–117.