

Comparison of Corneal Irregularity After Recurrent and Primary Pterygium Surgery Using Fourier Harmonic Analysis

Takashi Ono^{1,2}, Yosai Mori¹, Ryohei Nejima¹, Takuya Iwasaki¹, Takashi Miyai², Makoto Aihara², and Kazunori Miyata¹

¹ Miyata Eye Hospital, Miyazaki, Japan

² Department of Ophthalmology, Graduate School of Medicine, The University of Tokyo, Tokyo, Japan

Correspondence: Takashi Ono, Miyata Eye Hospital, 6-3, Kuraharacho, Miyakonojo, Miyazaki 885-0051, Japan.
e-mail: taono-ky@umin.ac.jp

Received: April 6, 2021

Accepted: August 20, 2021

Published: September 13, 2021

Keywords: recurrent pterygium; primary pterygium; Fourier harmonic analysis; corneal topography

Citation: Ono T, Mori Y, Nejima R, Iwasaki T, Miyai T, Aihara M, Miyata K. Comparison of corneal irregularity after recurrent and primary pterygium surgery using fourier harmonic analysis. *Transl Vis Sci Technol.* 2021;10(11):13, <https://doi.org/10.1167/tvst.10.11.13>

Purpose: To the best of our knowledge, few detailed investigation of astigmatism with recurrent pterygium currently exists. We aimed to evaluate corneal irregularity after recurrent pterygium surgery.

Methods: This observational study included consecutive patients who underwent recurrent pterygium surgery and were observed for >12 months postoperatively via corneal examination. Patients who underwent primary pterygium surgery during the same period served as controls. Pterygium size and corneal irregularity evaluated with Fourier harmonic analysis (spherical component, regular astigmatism, asymmetry component, and higher-order irregularity) were compared between groups preoperatively and at 1, 3, 6, and 12 months postoperatively.

Results: Overall, 203 eyes of 203 patients (age, 66.5 ± 9.5 years) were included, of which 44 eyes had recurrent pterygium and 159 had primary pterygium. Regular astigmatism in the recurrent pterygium group was higher than that in the primary pterygium group preoperatively and at 1 and 3 months postoperatively. The asymmetry component and higher-order irregularity in the recurrent pterygium group were higher than those in the primary pterygium group at all observation points.

Conclusions: Fourier harmonic analysis showed that larger corneal irregularity that could not be corrected with spectacles persisted for a long time after recurrent pterygium excision than after primary pterygium excision. Thus, recurrence prevention is critical for primary pterygium surgery.

Translational Relevance: We demonstrated that larger corneal irregularity that could not be corrected with spectacles remained long after excision of recurrent pterygium compared with excision of primary pterygium; thus, the prevention of recurrence is clinically important for primary pterygium surgery in terms of corneal irregularity.

Introduction

Pterygium is a disease in which proliferative tissue invades and covers the cornea.¹ It sometimes impairs visual acuity by directly disturbing the visual axis and indirectly changing the corneal regularity.²⁻⁴ Although numerous reports have shown the effectiveness of various types of surgery, one of the greatest clinical concerns in treating pterygium is the recurrence after excision; for example, the bare

sclera technique is associated with a high recurrence rate (88%).^{1,5,6} Moreover, residual postoperative corneal irregularity is important, as it is highly related to visual acuity.⁷ Furthermore, some patients who undergo pterygium surgery may require cataract surgery,⁸ and instability of corneal astigmatism could lead to an incorrect selection of the intraocular lens.⁹ A previous report stated that corneal irregularity was observed in recurrent pterygium postoperatively, even after 12 months, revealing a large remaining surface regularity index and surface asymmetry

index, despite being similar in terms of horizontal size.¹⁰

Fourier harmonic analysis has been proven to be a valuable tool for detecting corneal topography, and it categorizes the corneal surface into four components: spherical component, regular astigmatism, asymmetry component, and higher-order irregularity.¹¹ Because the use of spectacles can correct the spherical component and regular astigmatism, but not the asymmetry component and higher-order irregularity, this examination is useful for the clinical evaluation of corneal astigmatism. Many patients with pterygium are not office workers but work outside and are exposed to ultraviolet radiation, but many do not wish to use contact lenses postoperatively.¹² It is important to evaluate the severity of astigmatism that cannot be corrected solely using spectacles. Previous reports have shown that corneal irregularity changes after pterygium surgery.^{2,13} However, to the best of our knowledge, there has been no detailed investigation of astigmatism with recurrent pterygium, especially using Fourier harmonic analysis. Therefore, in this study, we conducted a detailed investigation and comparison of corneal astigmatism and irregularity in eyes with recurrent pterygium and those with primary pterygium using Fourier harmonic analysis of corneal topography.

Methods

The current observational study adhered to the tenets of the Declaration of Helsinki. It was approved by the Institutional Review Board of Miyata Eye Hospital (Miyazaki, Japan; identifier CS-318_005), and the requirement for written informed consent was waived; the participants were provided the opportunity to opt out of the study. The study included eyes that underwent excision of recurrent pterygium at Miyata Eye Hospital between 2002 and 2017 and were observed for >12 months postoperatively for corneal irregularity, which was evaluated using Fourier harmonic analysis. We excluded eyes that had undergone previous operations for pterygium more than twice or excision of pterygium of both the nasal and temporal sides and eyes that had undergone ophthalmologic surgical interventions, such as cataract or corneal surgery. Patients who underwent primary pterygium surgery at Miyata Eye Hospital during the same period and were subsequently observed for >12 months for corneal irregularity, evaluated using Fourier harmonic analysis, served as controls. Only one eye from each patient was included for the analysis.

Examinations

An image of the ocular surface was captured preoperatively with a digital camera, and the distance between the pterygium end and the corneal peripheral edge was measured. The pterygium size (%) was calculated as the ratio of the distance between the corneal peripheral edge and the advancing edge position to the corneal diameter, as per a previously established methodology.^{14,15} The examiners were not masked to whether the patients had recurrent or primary pterygium when they acquired the image.

We retrospectively reviewed medical records, including background data, pterygium size, and corneal topography data, evaluated with Fourier harmonic analyses, and compared them between the two groups before surgery and at 1, 3, 6, and 12 months postoperatively. Corneal topography was evaluated using a TMS-4A Corneal Topographer (Tomey, Nagoya, Japan). Fourier harmonic analysis of the corneal topographic data was conducted as reported previously.¹¹ Axial refractive power data on the mire ring were decomposed with a series of trigonometric components. Dioptric powers on mire ring i , $F_i(\sigma)$, were transformed into the trigonometric components of the form with the Fourier series harmonic analysis program included in the TMS software, as follows:

$$F_i(\sigma) = a_0 + c_1 \cos(\sigma - \alpha_1) + c_2 \cos 2(\sigma - \alpha_2) + c_3 \cos 3(\sigma - \alpha_3) + \dots + c_n \cos n(\sigma - \alpha_n)$$

In this equation, a_0 is the spherical component of the ring, $2 \times c_1$ is the asymmetry component (i.e., tilt or decentration), $2 \times c_2$ is regular astigmatism, and the summation of $c_3 \dots c_n$ includes the higher-order irregularity components. They were averaged for each parameter (i.e., spherical component, regular astigmatism, asymmetry component, and higher-order irregularity). We performed 3.0-mm- and 6.0-mm-diameter analyses.

Surgical Technique

Pterygium surgery was performed when patients complained of a sensation of a foreign body in the eye or decreased visual function. Regarding the surgical techniques for recurrent pterygium, transplantation of the preserved limbal allograft and amniotic membrane was performed after excision of the recurrent pterygium, as described in a previous report.¹⁶ All of the patients underwent an identical surgical procedure. Briefly, after topical anesthesia, the recurrent or primary pterygium head with conjunctival and subconjunctival fibrovascular tissues was

resected from the cornea. Sufficient coagulation was performed, and the scarred and the remaining tissue was bluntly cleaned from the cornea. Next, subconjunctival 0.04% mitomycin was administered for 1 minute, after which the area was completely irrigated using 500 mL of saline. The amniotic membrane was sutured on the exposed bare sclera using a 10-0 polyglycolic acid suture (Alcon, Fort Worth, TX). Furthermore, the trimmed corneal limbal allograft was sutured to cover the limbal-deficient area using a 10-0 nylon suture (Alcon). For primary pterygium, the adjacent superior or inferior conjunctiva was moved and sutured on the bare sclera after resection of the pterygium and washing out of mitomycin. Postoperatively, 0.5% levofloxacin (Cravit; Santen, Osaka, Japan) and 0.1% betamethasone sodium phosphate (Rinderon; Shionogi, Osaka, Japan) were topically instilled four times a day for a minimum of 3 months.

Statistical Analysis

All data are expressed as the mean \pm standard deviation unless otherwise indicated. The Mann-Whitney *U* test was used for the comparisons of age and pterygium size. The parameters of Fourier harmonic analysis between the recurrent pterygium and primary pterygium groups were analyzed using a repeated-measures analysis of variance (ANOVA), and the inter-time point difference was evaluated using post hoc Bonferroni analyses with the threshold for statistical significance set at $P < 0.01$, performed in complete-case analysis. The χ^2 test was used for the comparisons of sex and the side of the eye. Fisher's exact test was used for the comparison of pterygium position. In order to examine the effect of pterygium size on the degree of corneal irregularity, Pearson's correlation coefficient was determined from the preoperative pterygium size and each parameter of the Fourier harmonic analysis within each group before the surgery and at 1, 3, 6, and 12 months postoperatively. A two-tailed $P < 0.05$ was considered statistically significant.

Statistical analyses were conducted using Bell Curve for Excel (Social Survey Research Information, Tokyo, Japan).

Results

A total of 203 eyes of 203 patients were included in the study, of which 44 eyes had recurrent pterygium and 159 eyes had primary pterygium. The mean age of the patients was 66.5 ± 9.5 years, and the mean size of the pterygium was $30.6\% \pm 11.2\%$ (Table 1). There was no significant difference in sex, eye side, age, pterygium size, and the side of the pterygium between the primary pterygium and recurrent pterygium groups (Table 1).

In the 3.0-mm-diameter Fourier harmonic analysis, there was no significant difference in time serial change of the spherical component between the two groups (Fig. 1). In contrast, regular astigmatism was significantly different between the recurrent pterygium and primary pterygium groups ($P = 0.0052$, repeated-measures ANOVA). The asymmetry component and higher-order irregularity were also significantly different between the two groups ($P < 0.001$ and $P = 0.010$, respectively; repeated-measures ANOVA).

Longitudinal change in the recurrent pterygium group showed that the spherical component, regular astigmatism, asymmetry components, and higher-order irregularity were all significantly decreased at 1, 3, 6, and 12 months postoperatively compared with their preoperative values (all $P < 0.001$, repeated-measures ANOVA with post hoc analysis). Additionally, asymmetry components significantly decreased at 12 months compared with their values 6 months postoperatively ($P < 0.001$, repeated-measures ANOVA with post hoc analysis). Similar to the findings in the recurrent pterygium group, longitudinal change in the primary pterygium group showed that all four components of the Fourier harmonic analysis decreased at 1, 3, 6, and 12 months postoperatively compared with their preoperative values

Table 1. Demographic Characteristics of the Patients With Recurrent Pterygium and Primary Pterygium

Demographic	Total ($n = 203$)	Recurrent Pterygium ($n = 44$)	Primary Pterygium ($n = 159$)	<i>P</i>
Male; female, <i>n</i>	91; 112	16; 28	75; 84	0.202
Right; left, <i>n</i>	113; 90	26; 18	87; 72	0.605
Age (yr), mean \pm SD	66.5 ± 9.5	68.0 ± 7.9	66.1 ± 9.9	0.175
Pterygium size (%), mean \pm SD	30.6 ± 11.2	31.2 ± 12.4	30.4 ± 10.9	0.663
Position (nasal; temporal), <i>n</i>	198; 5	42; 2	156; 3	0.314

The Mann-Whitney *U* test was used for comparisons for age and pterygium size. The χ^2 test was used for comparisons of sex and side of the eye. Fisher's exact test was used for the comparison of pterygium position.

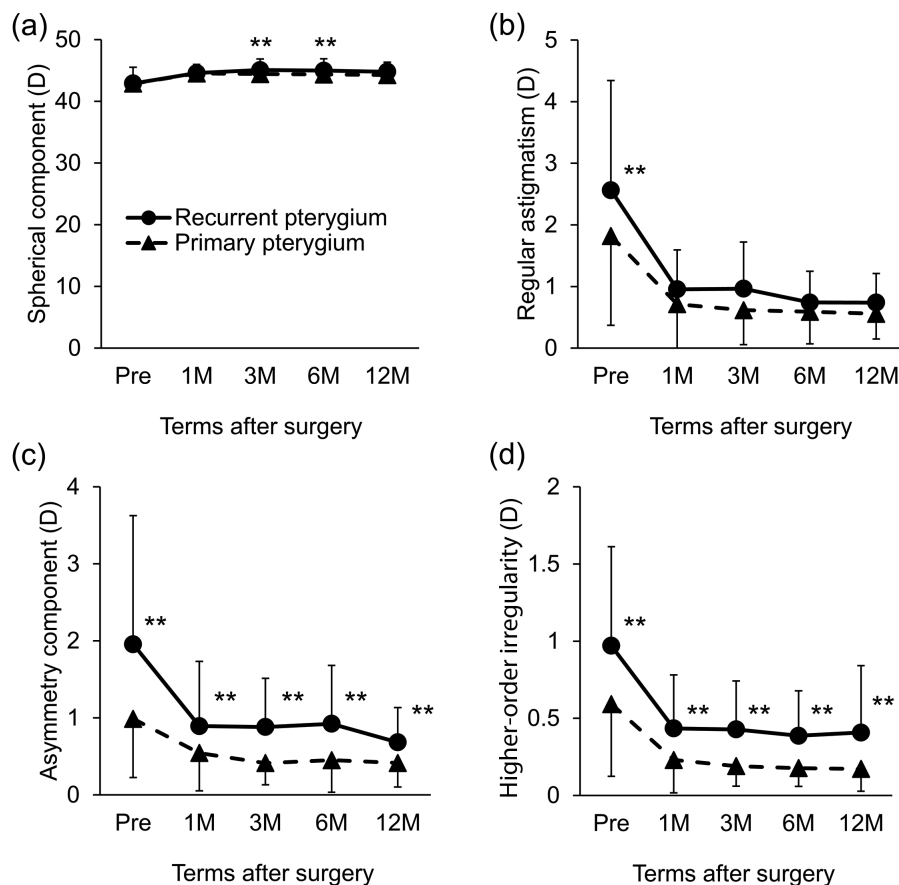


Figure 1. The 3.0-mm-diameter Fourier harmonic analysis of recurrent and primary pterygium. (a) Comparison of the spherical component during a postoperative period of 12 months. There was no significant difference in time serial change between recurrent pterygium and primary pterygium. In both groups, the values at 1, 3, 6, and 12 months were significantly lower than that before surgery (all $P < 0.001$). (b) Comparison of regular astigmatism during a postoperative period of 12 months. Time serial change in regular astigmatism was significantly different between the two groups ($P = 0.0052$). In both groups, the values at 1, 3, 6, and 12 months were significantly lower than that before surgery (all $P < 0.001$). (c) Comparison of the asymmetry component during a postoperative period of 12 months. Time serial change in the asymmetry component was significantly different between the two groups ($P < 0.001$). In both groups, the values at 1, 3, 6, and 12 months were significantly lower than that before surgery (all $P < 0.001$). (d) Comparison of higher-order irregularity during a postoperative period of 12 months. Time serial change in higher-order irregularity was significantly different between the two groups ($P = 0.010$). In both groups, the values at 1, 3, 6, and 12 months were significantly lower than that before surgery (all $P < 0.001$). ** $P < 0.01$, intergroup comparison with repeated-measures ANOVA with post hoc analysis and Bonferroni correction.

(all $P < 0.001$, repeated-measures ANOVA with post hoc analysis).

In the 6.0-mm-diameter analysis, there was no significant difference in the time serial changes in spherical component, regular astigmatism, and higher order irregularity between the two groups (Fig. 2). However, the asymmetry component was significantly different between the recurrent pterygium and primary pterygium groups ($P < 0.001$, repeated-measures ANOVA).

Similarly, longitudinal change in the recurrent pterygium group showed that all four components significantly decreased at 1, 3, 6, and 12 months compared with their preoperative values (all $P < 0.001$, repeated-measures ANOVA with post hoc analysis). Asymmetry components significantly decreased at

12 months compared with 6 months postoperatively ($P < 0.001$, repeated-measures ANOVA with post hoc analysis). Moreover, longitudinal change in the primary pterygium group showed that all four components of the Fourier harmonic analysis decreased at 1, 3, 6, and 12 months postoperatively compared with their preoperative values (all $P < 0.001$, repeated-measures ANOVA with post hoc analysis) similar to the 3.0-mm diameter analysis.

In the recurrent pterygium group, none of the four components in the 3.0-mm diameter Fourier harmonic analysis correlated with pterygium size at any observation point (Table 2). Conversely, in primary pterygium, almost all of the components (spherical components, regular astigmatism, asymmetry components,

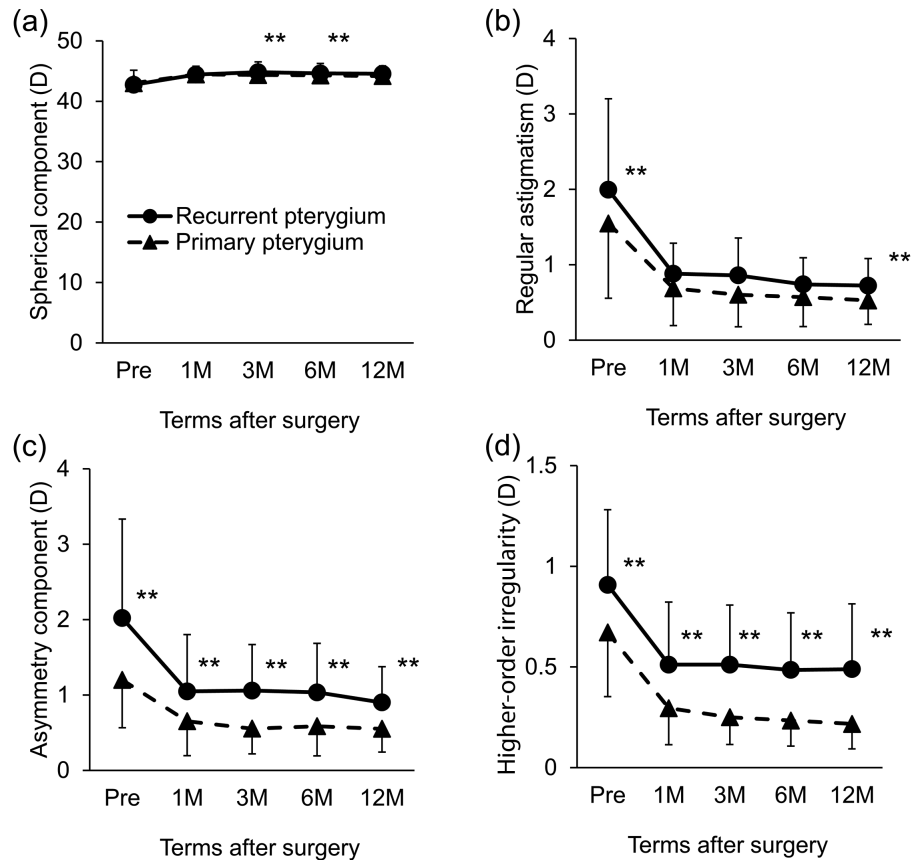


Figure 2. The 6.0-mm-diameter Fourier harmonic analysis of recurrent and primary pterygium. (a) Comparison of the spherical component during a postoperative period of 12 months. There was no significant difference in time serial change between recurrent pterygium and primary pterygium. In both groups, the values at 1, 3, 6, and 12 months were significantly lower than that before surgery (all $P < 0.001$). (b) Comparison of regular astigmatism during a postoperative period of 12 months. There was no significant difference in time serial change between recurrent pterygium and primary pterygium. In both groups, the values at 1, 3, 6, and 12 months were significantly lower than that before surgery (all, $P < 0.001$). (c) Comparison of the asymmetry component during a postoperative period of 12 months. The time serial change in the asymmetry component differed significantly between the two groups ($P < 0.001$). In both groups, the values at 1, 3, 6, and 12 months were significantly lower than that before surgery (all, $P < 0.001$). (d) Comparison of higher-order irregularity during a postoperative period of 12 months. There was no significant difference in time serial change between recurrent pterygium and primary pterygium. In both groups, the values at 1, 3, 6, and 12 months were significantly lower than that before surgery (all $P < 0.001$). ** $P < 0.01$, intergroup comparison with repeated-measures ANOVA with post hoc analysis and Bonferroni correction).

and higher-order irregularity) were significantly correlated with pterygium size at all observation points. The same trend was observed in the 6.0-mm-diameter analysis, except for the spherical component (Table 3).

Discussion

We retrospectively demonstrated using Fourier harmonic analysis that the time serial postoperative change in corneal irregularity differed between the surgeries for recurrent pterygium and primary pterygium. The surface asymmetry index and surface regularity index were higher in recurrent pterygium

than in primary pterygium of the same size, as reported previously.¹⁰ Our results contribute further detailed information on corneal irregularity based on the four components of Fourier harmonic analysis (spherical components, regular astigmatism, asymmetry components, and higher-order irregularity). In accordance with the progression of pterygium, the higher-order irregularity component was reported to increase in primary pterygium.¹³ Conversely, in our data of recurrent pterygium, regular astigmatism, asymmetry components, and higher-order irregularity were high preoperatively, suggesting that recurrent pterygium caused larger corneal irregularity due to the three-dimensional elevation of the proliferative tissue and roughness. The values of these components

Table 2. Pearson Correlation Coefficients for the Components of the 3.0-mm-Diameter Fourier Harmonic Analysis and Pterygium Size

Component		Correlation Coefficient (P)				
		Before	1 mo	3 mo	6 mo	12 mo
Spherical component	Recurrent pterygium	0.025 (0.869)	−0.050 (0.814)	0.070 (0.744)	−0.197 (0.356)	0.093 (0.637)
	Primary pterygium	−0.594 (<0.001)	0.162 (0.041)	0.188 (0.020)	0.129 (0.115)	0.052 (0.514)
Regular astigmatism	Recurrent pterygium	0.085 (0.584)	−0.323 (0.114)	−0.059 (0.785)	−0.309 (0.141)	−0.157 (0.425)
	Primary pterygium	0.670 (<0.001)	0.510 (<0.001)	0.448 (<0.001)	0.372 (<0.001)	0.234 (0.003)
Asymmetry component	Recurrent pterygium	0.119 (0.440)	−0.023 (0.915)	−0.184 (0.388)	−0.030 (0.890)	0.352 (0.065)
	Primary pterygium	0.650 (<0.001)	0.463 (<0.001)	0.391 (<0.001)	0.385 (<0.001)	0.308 (<0.001)
Higher-order irregularity	Recurrent pterygium	0.078 (0.614)	−0.293 (0.153)	−0.075 (0.728)	−0.177 (0.407)	0.072 (0.715)
	Primary pterygium	0.811 (<0.001)	0.569 (<0.001)	0.517 (<0.001)	0.520 (<0.001)	0.337 (<0.001)

Bold typeface indicates a significant association ($P < 0.05$). In the recurrent pterygium group, the numbers of eyes were $n = 44, 25, 24, 24,$ and 28 before and 1, 3, 6, and 12 months after, respectively. In the primary pterygium group, the number of eyes was 159 at all examination points.

Table 3. Pearson Correlation Coefficients for the Components of the 6.0-mm-Diameter Fourier Harmonic Analysis and Pterygium Size

Component		Correlation Coefficient (P)				
		Before	1 mo	3 mo	6 mo	12 mo
Spherical component	Recurrent pterygium	0.113 (0.465)	0.095 (0.652)	0.119 (0.580)	−0.052 (0.808)	0.105 (0.595)
	Primary pterygium	−0.513 (<0.001)	0.117 (0.145)	0.140 (0.084)	0.084 (0.306)	0.036 (0.655)
Regular astigmatism	Recurrent pterygium	0.057 (0.712)	−0.223 (0.282)	−0.119 (0.579)	−0.301 (0.152)	−0.049 (0.804)
	Primary pterygium	0.626 (<0.001)	0.482 (<0.001)	0.386 (<0.001)	0.335 (<0.001)	0.203 (0.010)
Asymmetry component	Recurrent pterygium	0.066 (0.670)	−0.185 (0.376)	−0.157 (0.463)	−0.170 (0.426)	0.312 (0.105)
	Primary pterygium	0.565 (<0.001)	0.475 (<0.001)	0.400 (<0.001)	0.385 (<0.001)	0.285 (<0.001)
Higher-order irregularity	Recurrent pterygium	0.077 (0.619)	−0.213 (0.306)	−0.174 (0.416)	−0.257 (0.224)	0.128 (0.514)
	Primary pterygium	0.782 (<0.001)	0.605 (<0.001)	0.560 (<0.001)	0.497 (<0.001)	0.365 (<0.001)

Bold typeface indicates a significant association ($P < 0.05$). In the recurrent pterygium group, the numbers of eyes were $n = 44, 25, 24, 24,$ and 28 before and 1, 3, 6, and 12 months after, respectively. In the primary pterygium group, the number of eyes was 159 at all examination points.

significantly decreased postoperatively, but each value remained significantly higher than those in the primary pterygium group. Therefore, resection was shown to be effective in reducing corneal irregularity. However, asymmetry components and higher-order irregularity, which were not corrected with spectacles, remained higher than the normal-range values as reported by Tanabe et al.¹⁷ In primary pterygium, pterygium size and all four components of Fourier harmonic analysis were significantly correlated, demonstrating that the greater the primary pterygium size, the larger the postoperative corneal irregularity that persisted even after 12 months. In contrast, in recurrent pterygium, pterygium size and each component of Fourier harmonic analysis were not significantly correlated at 12 months postoperatively, although the value of the corneal irregularity was not small. This result implies that small, recurrent pterygium induces a large postoperative corneal irregularity and also suggests that the effects of primary and recurrent pterygium on the ocular surface are different.

Subsequently, 3-mm- and 6-mm-diameter Fourier harmonic analyses were performed. Nearly identical tendencies were revealed in both analyses for all parameters. Resection of pterygium is clinically considered when it induces visual loss by threatening the visual axis, restricting eye movement, or leading to the occurrence of astigmatism.¹⁸ A previous study reported a tendency for large-diameter analysis to more sensitively detect larger asymmetry and higher-order components in Fourier harmonic analysis even in otherwise indistinguishable patients.¹³ Considering the varying size of the postoperative scar, topographic analysis in multiple diameters would be beneficial to fully characterize the postoperative changes in corneal irregularity.

There was no significant correlation between the size of the recurrent pterygium and each component of the Fourier harmonic analysis, contrary to findings from previous studies investigating primary pterygium. In our study, recurrent pterygium first advanced on the rough cornea, in which some type of irregularity induced by primary pterygium resection remained.

Therefore, the size of the resected primary pterygium possibly affected the degree of corneal irregularity in recurrent pterygium. Ideally, we would have assessed the scar made by primary pterygium resection, but it was impossible because most of these operations were performed in another institution with insufficient topographic data. Fourier harmonic analysis would be beneficial for detecting and evaluating corneal irregularity due to recurrent pterygium because even small recurrent pterygium could result in large corneal irregularity that is not corrected with spectacles. Because Fourier harmonic analysis of the cornea can detect regular astigmatism and irregular astigmatism accurately and quantitatively, it accurately indicates appropriate correction for visual acuity after pterygium surgery, such as contact lens prescription, that can correct irregular astigmatism.

The timing of pterygium resection is sometimes clinically problematic. Our results showed that recurrent pterygium caused large asymmetry components and higher-order irregularity, which could not be corrected with spectacles and significantly decreased with excision. In both primary and recurrent pterygium, a larger size leads to larger corneal irregularity.^{10,14} Therefore, if possible, they should be resected while small. However, the recurrence rate is not negligible.¹⁶ When pterygium recurs, even a small size could result in larger corneal irregularity than that in primary pterygium. Furthermore, recurrent pterygium is more adherent to underlying tissue than primary pterygia and sometimes has a scar around the medial rectus muscle; therefore, a greater surgical technique is required.^{19–21} Hence, the prevention of recurrence is very crucial.

The current study has a few limitations. First, due to the observational nature of the study, some examination data could not be collected from the medical charts, such as the uncorrected visual acuity and best spectacle-corrected visual acuity. Higher-order irregularity and asymmetry were not corrected with spectacles, and the uncorrected visual acuity was an important parameter. Further studies that include observation of these variables for a period of at least 12 months are required. Additionally, blinding at examination would be required in further prospective studies. Second, as mentioned above, preoperative data were not available for the recurrent pterygium group. Most of the patients with recurrent pterygium who were included in the current study had not undergone their first surgery for primary pterygium at our institution, as they were referred to our institution for their second surgery. Therefore, we regarded the recurrent and primary pterygium as different and independent entities in the current study. A

corneal scar remaining after primary pterygium resection could affect corneal irregularity after recurrent pterygium that advances on such a rough cornea. It is difficult to accurately evaluate the corneal irregularity that was made when primary pterygium was resected in the recurrent pterygium group. However, the corneal topographic information obtained after primary pterygium surgery in the recurrent pterygium group might help further research. Third, this study only included amniotic membrane and limbal allograft transplantation for recurrent pterygium. This procedure was reported with a low recurrence rate without serious complications because allografts would serve as a barrier to the invasiveness of recurrent proliferative tissue in addition to the anti-inflammatory effect of the amniotic membrane.¹⁶ The surgical technique of the present study also included mitomycin usage for adjunctive therapy for the suppression of subconjunctival cell proliferation.^{22–24} However, it is possible that the different surgical techniques could result in different patterns of corneal irregularity; therefore, further analysis, including other surgical techniques, especially conjunctival autograft, would be required.

In conclusion, Fourier harmonic analysis data showed that corneal irregularity significantly decreased after recurrent pterygium surgery. Larger corneal irregularity that could be corrected with spectacles remained for a longer time after excision of recurrent pterygium compared with that after excision of primary pterygium. Thus, prevention of recurrence is clinically critical for primary pterygium surgery in terms of corneal irregularity.

Acknowledgments

Disclosure: **T. Ono**, None; **Y. Mori**, None; **R. Nejima**, None; **T. Iwasaki**, None; **T. Miyai**, None; **M. Aihara**, None; **K. Miyata**, None

References

1. Janson BJ, Sikder S. Surgical management of pterygium. *Ocul Surf*. 2014;12(2):112–119.
2. Minami K, Tokunaga T, Okamoto K, Miyata K, Oshika T. Influence of pterygium size on corneal higher-order aberration evaluated using anterior-segment optical coherence tomography. *BMC Ophthalmol*. 2018;18(1):166.
3. Gumus K., Topaktas D, Göktaş A, Karakucuk S, Oner A, Mirza GE. The change in ocular

- higher-order aberrations after pterygium excision with conjunctival autograft: a 1-year prospective clinical trial. *Cornea*. 2012;31(12):1428–1431.
4. Levinger E., Sorkin N, Sella S, Trivizki O, Lapira M, Keren S. Posterior corneal surface changes after pterygium excision surgery. *Cornea*. 2020;39(7):823–826.
 5. Alpay A, Uğurbaş SH, Erdoğan B. Comparing techniques for pterygium surgery. *Clin Ophthalmol*. 2009;3:69–74.
 6. Clearfield E, Muthappan V, Wang X, Kuo IC. Conjunctival autograft for pterygium. *Cochrane Database Syst Rev*. 2016;2:CD011349.
 7. Shiotani Y, Maeda N, Inoue T, et al. Comparison of topographic indices that correlate with visual acuity in videokeratography. *Ophthalmology*. 2000;107(3):559–564.
 8. Lim R, Mitchell P, Cumming RG. Cataract associations with pinguecula and pterygium: the Blue Mountains Eye Study. *Am J Ophthalmol*. 1998;126(5):717–719.
 9. Kamiya K, Shimizu K, Iijima K, Shoji N, Kobashi H. Predictability of intraocular lens power calculation after simultaneous pterygium excision and cataract surgery. *Medicine (Baltimore)*. 2015;94(52):e2232.
 10. Ono T, Mori Y, Nejima R, et al. Long-term changes and effect of pterygium size on corneal topographic irregularity after recurrent pterygium surgery. *Sci Rep*. 2020;10(1):8398.
 11. Oshika T, Tomidokoro A, Maruo K, Tokunaga T, Miyata N. Quantitative evaluation of irregular astigmatism by Fourier series harmonic analysis of videokeratography data. *Invest Ophthalmol Vis Sci*. 1998;39(5):705–709.
 12. Durkin SR, Abhary S, Newland HS, Selva D, Aung T, Casson RJ. The prevalence, severity and risk factors for pterygium in central Myanmar: the Meiktila Eye Study. *Br J Ophthalmol*. 2008;92(1):25–29
 13. Minami K, Miyata K, Otani A, Tokunaga T, Tokuda S, Amano S. Detection of increase in corneal irregularity due to pterygium using Fourier series harmonic analyses with multiple diameters. *Jpn J Ophthalmol*. 2018;62(3):342–348.
 14. Nejima R, Masuda A, Minami K, Mori Y, Hasegawa Y, Miyata K. Topographic changes after excision surgery of primary pterygia and the effect of pterygium size on topographic restoration. *Eye Contact Lens*. 2015;41(1):58–63.
 15. Tomidokoro A, Oshika T, Amano S, Eguchi K, Eguchi S. Quantitative analysis of regular and irregular astigmatism induced by pterygium. *Cornea*. 1999;18(4):412–415.
 16. Ono T, Mori Y, Nejima R, Tokunaga T, Miyata K, Amano S. Long-term follow-up of transplantation of preserved limbal allograft and amniotic membrane for recurrent pterygium. *Graefes Arch Clin Exp Ophthalmol*. 2016;254(12):2425–2430.
 17. Tanabe T, Tomidokoro A, Samejima T, et al. Corneal regular and irregular astigmatism assessed by Fourier analysis of videokeratography data in normal and pathologic eyes. *Ophthalmology*. 2004;111(4):752–757.
 18. Hirst LW. The treatment of pterygium. *Surv Ophthalmol*. 2003;48(2):145–180.
 19. Clearfield E, Hawkins BS, Kuo IC. Conjunctival autograft versus amniotic membrane transplantation for treatment of pterygium: findings from a Cochrane Systematic Review. *Am J Ophthalmol*. 2017;182:8–17.
 20. Hirst LW. Recurrent pterygium surgery using pterygium extended removal followed by extended conjunctival transplant: recurrence rate and cosmesis. *Ophthalmology*. 2009;116(7):1278–1286.
 21. Ma DH, See LC, Hwang YS, Wang SF. Comparison of amniotic membrane graft alone or combined with intraoperative mitomycin C to prevent recurrence after excision of recurrent pterygia. *Cornea*. 2005;24(2):141–150.
 22. Lam DS, Wong AK, Fan DS, Chew S, Kwok PS, Tso MO. Intraoperative mitomycin C to prevent recurrence of pterygium after excision: a 30-month follow-up study. *Ophthalmology*. 1998;105(5):901–904; discussion 904–905.
 23. Walkow T, Daniel J, Meyer CH, Rodrigues EB, Mennel S. Long-term results after bare sclera pterygium resection with excimer smoothing and local application of mitomycin C. *Cornea*. 2005;24(4):378–381.
 24. Segev F, Jaeger-Roshu S, Gefen-Carmi N, Assia EI. Combined mitomycin C application and free flap conjunctival autograft in pterygium surgery. *Cornea*. 2003;22(7):598–603.