

Peripapillary Choroid Thickness as a Predisposing Factor for Nonarteritic Anterior Ischemic Optic Neuropathy: A Semiautomated OCT Study

Yi-Ting Hou¹, Ta-Ching Chen¹, Chao-Yuan Yeh², and Chao-Wen Lin¹

¹ Department of Ophthalmology, National Taiwan University Hospital, Taipei, Taiwan

² AetherAI, Co., Ltd., Taipei, Taiwan

Correspondence: Chao-Wen Lin, Department of Ophthalmology, National Taiwan University Hospital, Taipei, Taiwan; No 7, Chung-Shan S. Rd., Taipei 100, Taiwan. e-mail: b91401108@ntu.edu.tw

Received: July 5, 2021

Accepted: December 1, 2021

Published: December 29, 2021

Keywords: nonarteritic anterior ischemic optic neuropathy; peripapillary choroidal thickness; optical coherence tomography; visual outcome

Citation: Hou YT, Chen TC, Yeh CY, Lin CW. Peripapillary choroid thickness as a predisposing factor for nonarteritic anterior ischemic optic neuropathy: A semiautomated OCT study. *Transl Vis Sci Technol.* 2021;10(14):31, <https://doi.org/10.1167/tvst.10.14.31>

Purpose: The purpose of this study was to investigate the correlations between peripapillary choroidal thickness (PCT) and nonarteritic ischemic optic neuropathy (NAION) by using semiautomated optical coherence tomography (OCT).

Methods: A total of 35 NAION eyes, 29 unaffected fellow eyes, and 40 eyes from an age-matched control group were recruited. Enhanced-depth imaging OCT was performed after the resolution of disc edema. PCT was measured using a customized semiautomated MATLAB program. Regression models adjusted for multiple variables were used to inspect the correlation between mean PCT and NAION.

Results: The mean PCT in NAION eyes, unaffected fellow eyes, and the control group was 197.09 ± 38.09 , 196.52 ± 38.47 , and 153.53 ± 29.92 μm , respectively. The mean PCT was significantly thicker both in NAION-affected eyes and fellow eyes compared with the control group ($P < 0.001$). No significant difference existed between NAION-affected eyes and unaffected fellow eyes. The PCT of the superior quadrant was significantly thicker than that of the inferior quadrant in all three groups. In the multivariate logistic regression, PCT was the only predisposing factor for NAION. However, the value of the PCT was not correlated with final visual outcomes.

Conclusions: With a semiautomated program to alleviate the missing measurements, our study demonstrated significantly thicker PCT in both NAION-affected and unaffected eyes of patients, which indicated that peripapillary pachychoroid is a predisposing factor for NAION but may not be a prognostic factor for visual outcomes.

Translational Relevance: Accurate measurement of PCT by using semiautomated OCT illustrates the correlation between choroidal vasculature and NAION.

Introduction

Nonarteritic anterior ischemic optic neuropathy (NAION) is the most common acute optic neuropathy in aging populations.^{1–3} Patients with NAION present with sudden onset of painless vision loss accompanied by disc edema. Although the exact pathogenesis of NAION remains unclear, a consensus cites the loss of blood flow and vascular insufficiency in the optic nerve head.^{2,3}

The short posterior ciliary arteries provide blood supply to the optic nerve. The short posterior ciliary arteries and their branches also supply the peripapil-

lary choroid. Vascular hypoperfusion is often cited as the pathophysiology of NAION. However, evaluating or quantifying blood perfusion through a traditional technique or examination is difficult. Because of poor signal resolution and the difficulties in evaluating layer separation, measuring choroidal thickness is challenging. The novel advances of optical coherence tomography (OCT) are successful in measuring and quantifying the structures of the optic nerve head and peripapillary choroid.^{4,5} Research has hypothesized that vascular circulation affects choroidal thickness.⁶ Because of the pathophysiology of NAION, the measurement of peripapillary choroidal thickness (PCT) is critical in diagnosis and prognosis prediction of NAION.

As an ischemic disease, NAION has vascular risk factors, such as diabetes mellitus (DM), hypertension, ischemic heart disease, and arrhythmia.^{7,8} However, predisposing factors predicting second-eye involvement in patients with unilateral NAION have not been identified. The Ischemic Optic Neuropathy Decompression Trial reported that the incidence of NAION in the fellow eye was 15% within 5 years after incidence in the first eye.⁷ The trial results concluded that DM and poor visual acuity in the first eye were associated with attack in the fellow eye.⁷ PCT evaluation may be a more successful approach to assessing optic nerve diseases, including NAION, primary open-angle glaucoma, and normal tension glaucoma.^{4,8-10}

Several studies have reported conflicting results on macular choroidal thickness in NAION. Schuster et al.¹¹ and Garcia-Basterra et al.¹² demonstrated thinner subfoveal choroidal thickness in both the affected eyes and unaffected fellow eyes of patients with NAION, whereas Dias-Santos et al.¹³ reported a thicker choroid in patients with chronic NAION compared with the controls. Moreover, the choroid area near the optic nerve head may be more closely related to NAION. As a result, further studies have explored the association of PCT with NAION. To date, three studies conducted by Fard et al.,⁴ Nagia et al.,¹⁴ and Ane Pérez-Sarriegui et al.⁵ reported thicker PCT in the affected eyes and unaffected fellow eyes of patients with NAION. By contrast, a study found that PCT in both eyes of patients with NAION was thinner than that in the control group.¹⁵ Conflicting results may be attributed to different study protocols, measurement methods, and patient populations. In this study, we investigated the association between PCT and NAION by using a customized MATLAB semiautomated measurement program to address the limitations of manual segmentation and missing measurements. We also explored the influences of PCT on final visual outcomes.

Methods

This observational study adhered to the tenets of the Declaration of Helsinki and was approved by the Research Ethics Committee of National Taiwan University Hospital (NTUH-REC No. 201409073RIND) and conducted at National Taiwan University Hospital. From December 2014 to December 2020, 72 participants were recruited, including 32 patients with first-time NAION, and a control group of 40 patients.

Patients with NAION who visited our neuro-ophthalmology clinic were recruited. NAION was

defined as the sudden onset of painless vision loss, visual field defect, disc edema, and delay-disc filling presenting in fluorescein angiography. The inclusion criteria included NAION attack in at least one eye, a follow-up period of more than 3 months, no evidence of arteritic anterior ischemic optic neuropathy, and normal levels of C-reactive proteins and erythrocyte sedimentation rates. The exclusion criteria were the diagnosis of retinal pathology, primary open angle glaucoma, spherical equivalent greater than ± 6.0 diopters, axial length greater than 26 mm, and a previous intraocular operation except cataract surgery. The exclusion criteria were developed to omit conditions that may influence choroidal hemodynamics or choroidal thickness. Healthy controls were recruited from patients who visited the clinic for routine eye examinations without ocular diseases.

For each participant, we performed comprehensive history-taking and ocular examinations, which included best-corrected visual acuity and slit-lamp evaluations and fundoscopies. Detailed information, including age, gender, systemic diseases, such as DM and hypertension, the onset of NAION, and visual acuity, were recorded. Fluorescein angiography was also conducted to confirm NAION diagnoses. Axial length was measured with laser interferometric biometry (Lenstar LS900; HAAG-STREIT AG, Bern, Switzerland). Visual field tests were performed using Humphrey automated perimetry (Humphrey 740i Visual Field Analyzer; Carl Zeiss Meditec, Dublin, CA, USA).

All participants underwent choroidal imaging with spectral-domain OCT (SD-OCT, RTVue RT-100; Optovue Inc., Fremont, CA, USA). Patients with NAION received OCT examinations after disc edema resolution and within 1 year of disease onset. We obtained cross-line images of the peripapillary retina and choroid along an 8-mm line passing through the central area of the disc. Two sets of images for each disc (X–Y axis with 0 degrees and 90 degrees) and oblique axis (45 degrees and 135 degrees) were captured to retrieve the peripapillary cross-sectional structures in eight directions. Images with a signal strength index lower than 50 were excluded from the analysis.

We developed a customized MATLAB script for semiautomated measurement of the PCT by conducting the automated calculation with eight-direction peripapillary cross-line scans. Our previous study detailed the protocols and procedures.¹⁵ First, we retrieved the four raw images (8 directions) from the OCT files (Fig. 1a). All subsequent measurements were completed by one reviewer (authors Y.T. Hou) and rechecked by the second reviewer (author T.C. Chen). The border between the choroid and retinal pigment

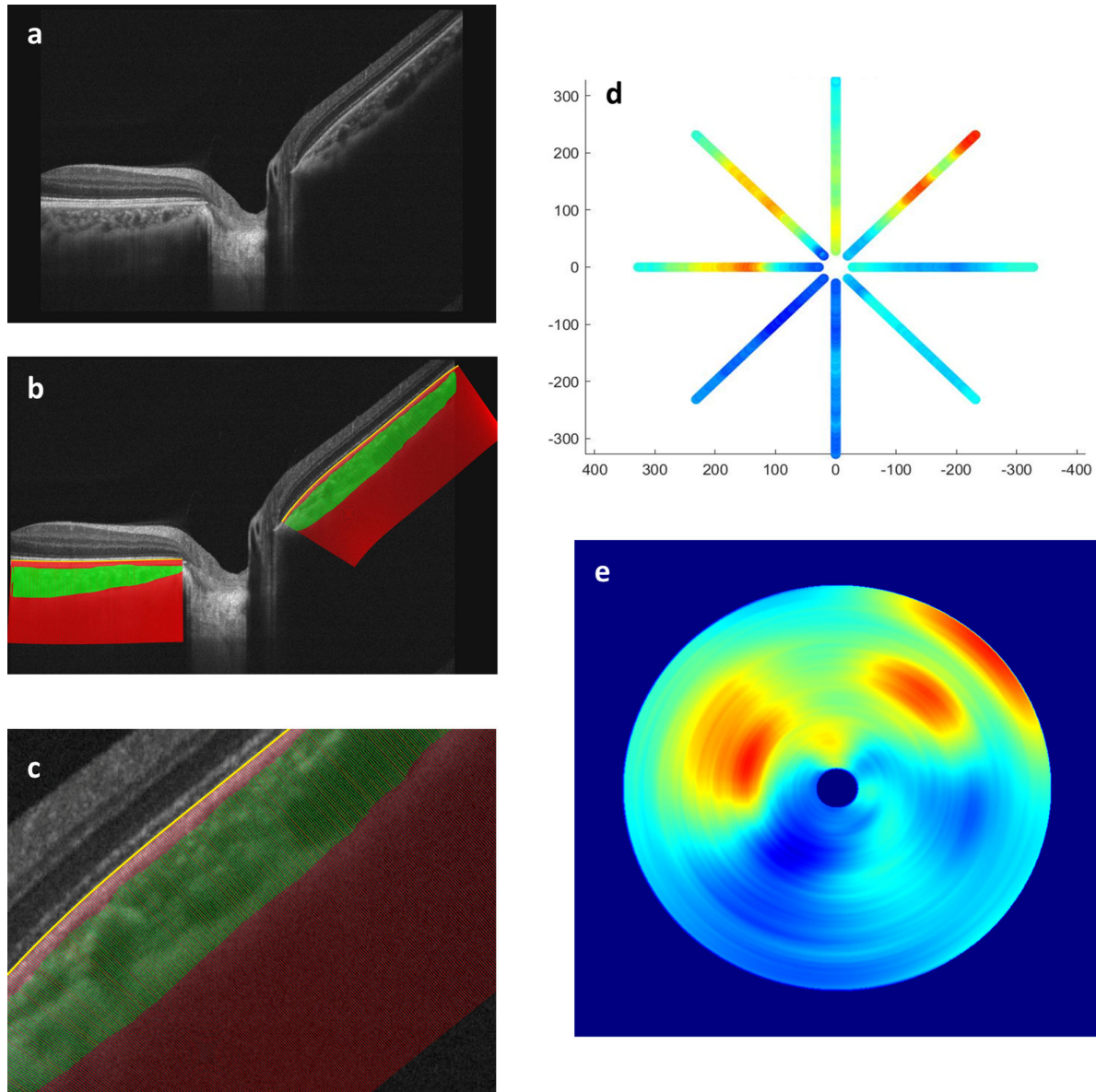


Figure 1. Customized semiautomated MATLAB program assisting the measurement of peripapillary choroidal thickness (PCT). **(A)** High-resolution optic coherence topography (OCT) image of the peripapillary retina with an 8-mm cross section. **(B)** We inscribed the *yellow line* along the retinal pigment epithelium as the reference curve and then drew along the contour of the choroid. The area of the choroid is shown in *green*. *Red lines* were automatically produced at fixed 1- μm intervals and represent the auxiliary lines perpendicular to the *yellow* reference curve. **(C)** Magnified view of **B**. The auxiliary red lines were used for calculating the choroid thickness at high spatial density. **(D)** The calculation of PCT was composed of four cross-line images that cover eight regions of the eye. Warm colors represent a thicker choroid and cool colors represent a thinner choroid. **(E)** A full circle of PCT was estimated with the spline interpolation of the data shown in **D**.

epithelium was lined using a free-hand region of interest tool. In an automated process, the reference curve was marked parallel to Bruch's membrane, which enabled the choroid thickness to be measured vertical to the retina (see Figs. 1b,c). Choroidal thickness was calculated by combining four cross-line images representing eight directions of the eye (0 degrees, 45 degrees, 90 degrees, 135 degrees, 180 degrees, 225 degrees, 270 degrees, and 315 degrees; see Figs. 1d,e).

We divided participants into 3 groups to conduct analysis: (1) affected eyes in patients with NAION, (2) unaffected fellow eyes in patients with NAION, and (3) age-matched normal controls. Continuous variables were analyzed using Student's *t*-test, and categorical variables were examined using a chi-square or Fisher's exact test. Univariate and multivariate logistic regression analyses were performed to investigate the predisposing factors of NAION. Multiple linear regression

was used to estimate the prognostic values of different variables in the visual outcomes of patients with NAION. A P value of < 0.05 indicated statistical significance. Statistical analyses were conducted using SPSS version 25 (IBM SPSS, Armonk, NY, USA).

Results

The study recruited 32 patients for the NAION group, which included 3 patients with bilateral disease. The mean period between disease onset and OCT examination was 142 days (with a range of 34 to 289 days). Patients with insufficient follow-up periods or inadequate OCT imaging quality were excluded from the study. The age-matched control group included 40 participants. The average age of the NAION study group was 59.97 ± 8.27 years. The mean age of participants in the control group was 59.08 ± 14.92 years. The average axial length was 23.8 ± 1.15 mm in the NAION group and 24.1 ± 1.03 mm in the age-matched control group. Table 1 compares the demographic characteristics of the NAION and age-matched control groups. No significant differences existed in age distribution ($P = 0.762$), gender ($P = 0.316$), axial length ($P = 0.28$), and systemic diseases, such as hypertension ($P = 0.638$) or DM ($P = 0.761$).

As indicated in Table 2, the average PCT was 197.09 ± 38.09 μm in the affected eye of the patients with NAION, 196.52 ± 38.47 μm in the fellow eye of the patients with NAION, and 153.53 ± 29.92 μm in the control group. The PCT in the affected or fellow eye of all patients with NAION was significantly thicker

than that in the control group ($P < 0.001$). Conversely, no significant differences in mean PCT existed between the affected and fellow eye in the patients with unilateral NAION ($P = 0.174$).

Furthermore, we investigated the average PCT in the four quadrants (superior, inferior, temporal, and nasal). Our results indicated that the PCT values in all sectors were significantly thicker in both the affected and fellow eye of patients with NAION than those in the control group (all $P < 0.005$). Additionally, no significant differences existed in the PCT values of the four quadrants between the affected eye and fellow eye in the patients with NAION. We also found that the PCT of the superior quadrant was significantly thicker than that of the inferior quadrant in NAION eyes, fellow eyes, and control eyes (Fig. 2).

We conducted a regression to investigate the predisposing factors of NAION (Table 3). In the univariate analysis, a diagnosis of NAION was positively associated with PCT ($P < 0.001$, odds ratio [OR] = 1.417, per 10 μm , 95% confidence interval [CI] = 1.186–1.692), and no significant associations existed with age ($P = 0.759$), gender ($P = 0.317$), axial length ($P = 0.274$), hypertension ($P = 0.638$), or DM ($P = 0.761$). In the multivariate analysis, we adjusted for age, gender, and axial length. However, PCT remained significantly associated with the diagnosis of NAION ($P < 0.001$, OR = 1.426, per 10 μm , 95% CI = 1.187–1.714). Furthermore, we investigated the relationship between mean PCT and final visual outcomes, including visual acuity and visual field (Table 4). After adjustments for other variables, including age, gender, DM, hypertension, and axial length, no significant correlation existed among the mean PCT, final visual acuity ($P = 0.063$), and visual field ($P = 0.804$).

Table 1. Demographic and Clinical Characteristics of the NAION Group and Age-Matched Control Group

Variables	NAION (N = 32)	Control (N = 40)	P Value
Age, years	59.97 ± 8.27	59.08 ± 14.92	0.762
Gender			0.316
Male	19	19	
Female	13	21	
Axial length, mm	23.8 ± 1.15	24.1 ± 1.03	0.28
Hypertension			0.638
Yes	8	12	
No	24	28	
Diabetes mellitus			0.761
Yes	4	6	
No	28	34	

Data presented as mean \pm SD.

$P < 0.05$ was considered statistically significant.

NAION, nonarteritic anterior ischemic optic neuropathy.

Discussion

The choroidal vessel is vital in the nutrition and circulation of the outer retina and optic nerve head.¹⁶ The correlation between choroidal thickness and optic nerve head diseases, such as primary open angle glaucoma and other optic neuropathies and their underlying mechanisms, should be further studied.^{6,10} Research has investigated the relationship between glaucoma and the choroidal thickness and discovered thinner choroids in patients with primary open angle glaucoma and normal tension glaucoma, suggesting that a smaller vessel lumen was a cause of and predisposing factor for glaucoma.¹⁰

By contrast, our study indicated that PCT was significantly thicker in patients with NAION than in

Table 2. PCT in NAION Eyes, Unaffected Fellow Eyes, and Control Eyes

PCT, μm	NAION $N = 35$		Fellow $N = 29$		Control $N = 40$		P Value		
	Mean	SD	Mean	SD	Mean	SD	NAION vs. Fellow	NAION vs. Control	Fellow vs. Control
Mean	197.09	38.09	196.52	38.47	153.53	29.92	0.174	<0.001*	<0.001*
Superior	199.43	36.73	200.03	47.63	167.17	37.03	0.323	<0.001*	0.002*
Inferior	187.73	44.83	179.56	39.32	137.19	33.12	0.291	<0.001*	<0.001*
Nasal	207.83	49.64	199.63	46.30	159.59	37.38	0.719	<0.001*	<0.001*
Temporal	196.90	36.70	196.23	45.33	154.57	38.68	0.813	<0.001*	<0.001*

* $P < 0.05$ was considered statistically significant.

NAION, nonarteritic anterior ischemic optic neuropathy; PCT, peripapillary choroidal thickness.

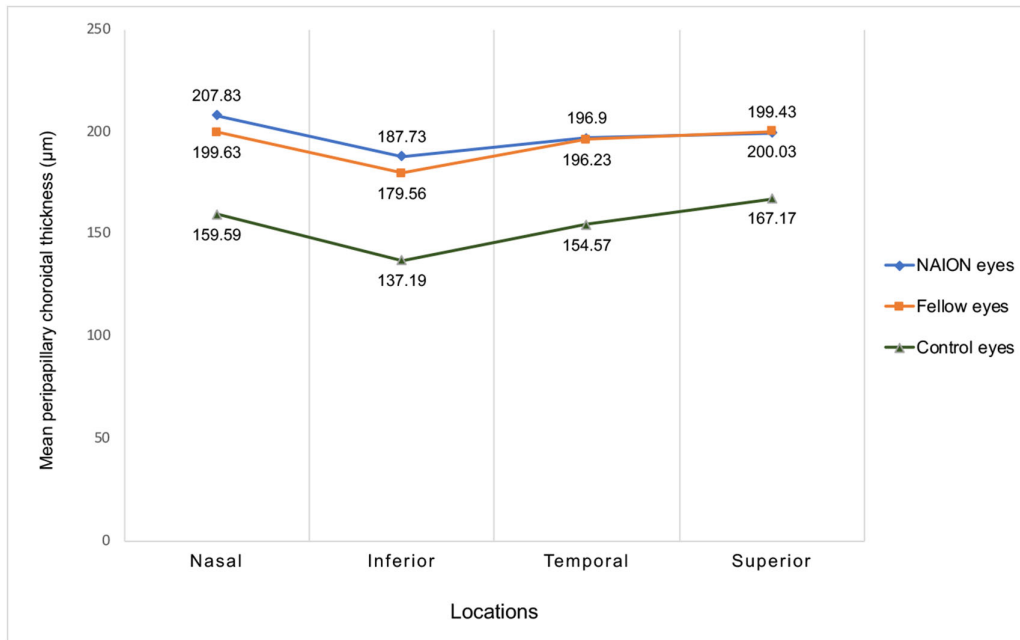


Figure 2. Distribution of mean peripapillary choroidal thickness in four quadrants (nasal, inferior, temporal, and superior) of nonarteritic anterior ischemic optic neuropathy (NAION) eyes, unaffected fellow eyes, and control eyes.

translational vision science & technology

the healthy controls. Additionally, no significant differences existed in PCT between the affected and fellow eyes of patients with NAION. This phenomenon was observed in all four quadrants. These results are consistent with the findings of Fard et al.,⁴ Nagia et al.,¹⁴ and Ane Pérez-Sarriegui et al.,⁵ who indicated that PCT was thicker in both eyes of patients with NAION. Consequently, thicker PCT may be a risk factor for NAION. Additionally, our findings suggest that PCT is a contributing factor for as opposed to a consequence of ischemic events.

Studies have reported smaller disc areas and small cup–disc ratios in the fellow eyes of patients with NAION.^{1,17,18} Our results indicate that thicker PCT was a predisposing factor for NAION. Both small disc and choroidal thickening increase the risk of NAION attack. Thicker choroidal thickness, as well as greater

choroidal volume within the small disc and narrow cup, crowd the peripapillary vessels, which leads to an ischemic event. After ischemia occurs, the swelling of the optic nerve head reduces choroidal circulation. These symptoms worsen continually through the course of NAION.

Furthermore, we found that among the four quadrants, the PCT of the inferior quadrant was the thinnest. This asymmetrical distribution was consistent with past studies.^{4,15,19} The PCT of the superior quadrant in all patients with NAION was thicker than that of the inferior quadrant. Research has concluded that altitudinal visual field defect is a typical feature of NAION and that altitudinal visual field defect is more common than superior defect.^{1,17} These findings indicate relative vascular insufficiency in the superior vascular network. Thicker PCT in the superior

Table 3. Statistical Analysis of Potential Predisposing Factors for NAION

	OR	95% CI	P Value in Simple Regression	Adjusted OR	95% CI	P Value in Multivariate Regression
Age, Years	1.006 (Per Year of Age)	0.968–1.045	0.759	1.022 (Per Year of Age)	0.972–1.074	0.389
Gender						
Male	1 (reference)			1 (reference)		
Female	1.615	0.631–4.134	0.317	0.533	0.177–1.722	0.307
AXL, mm	0.783	0.505–1.214	0.274	0.930	0.546–1.585	0.790
Hypertension						
Yes	1.286	0.451–3.665	0.638			
No	1 (reference)					
DM						
Yes	0.810	0.208–3.155	0.761			
No	1 (reference)					
Mean PCT, 10 μ m	1.417 (per 10 μ m)	1.186–1.692	<0.001*	1.426	1.187–1.714	<0.001*

* $P < 0.05$ was considered statistically significant.

NAION, nonarteritic anterior ischemic optic neuropathy; AXL, axial length; DM, diabetes mellitus; PCT, peripapillary choroidal thickness; OR, odds ratio; CI, confidence interval.

Table 4. Multiple Linear Regression Analysis of Potential Prognostic Factors Associated With Visual Outcomes

	Visual Acuity (LogMAR)			Visual Field, dB		
	Regression Coefficient	Standard Error	P Value	Regression Coefficient	Standard Error	P Value
Age, years	0.012	0.017	0.504	0.021	0.212	0.921
Gender, male/female	-0.403	0.277	0.157	-0.173	3.467	0.961
AXL, mm	-0.004	0.122	0.975	1.772	1.741	0.318
Hypertension	0.337	0.381	0.383	9.362	4.936	0.069
DM	-0.064	0.314	0.839	-4.773	4.061	0.254
Mean PCT, μ m	-0.007	0.003	0.063	0.010	0.041	0.804

LogMAR, logarithm of a minimum angle of resolution; AXL, axial length; DM, diabetes mellitus; PCT, peripapillary choroidal thickness.

quadrant may compress the vessel, increase the risk of compartment syndrome, and render the optic nerve more vulnerable to changes in choroidal blood supply.

Our automated MATLAB program succeeded in calculating the choroidal thickness and investigating the relationship between the vascular perfusion and choroidal thickness proposed in our past research.²⁰ We used the MATLAB program to retrieve the choroidal thickness in eight-directional cross-sectional images. First, we reduced bias through continuous calculation. Second, high-resolution OCT cross-sectional images strengthened the measurement accuracy. Third, we defined the reference lines parallel to Bruch's membrane, which eliminated the errors from the choroid curvature and segmentation. The two-dimensional images along eight directions were turned into three-dimensional topographic images by using the spline interpolation through the MATLAB program. Applying this MATLAB program enabled us to analyze the peripapillary choroid structure accurately.

Research has reported that PCT is influenced by multiple variables, such as age,^{21,22} axial length,^{21–23} and DM.²² Therefore, we included these factors in the multivariate regression model, and only PCT was

associated with the development of NAION (OR = 1.426, per 10 μ m, $P < 0.001$). The difference of mean PCT between patients with NAION and control group was about 40 μ m, which indicated that the OR of NAION could be more than 4 in the group with thicker PCT. We speculated that thicker PCT was an anatomic predisposing factor rather than a post-NAION change. Furthermore, our results support the hypothesis that compartment syndrome is a vital pathophysiological mechanism of NAION.^{24,25} However, no significant correlation existed between mean PCT and final visual outcomes, including visual acuity and visual field, which indicated that PCT is not a parameter in predicting the prognosis of NAION. Therefore, PCT is a contributing factor but not a prognostic factor for NAION.

Several limitations in our study should be noted. First, the sample size in our study was relatively small. Second, choroidal thickness changes between day and night,²¹ and the different OCT scan times in our study may have affected the measurement of choroidal thickness. Third, the interval between NAION attack and OCT examination was inconsistent among the participants. However, we sought to eliminate measurement errors by using an automated MATLAB program and

high-resolution OCT images. As a result, our findings are accurate, valuable, and clinically applicable.

In conclusion, because PCT is thicker not only in the affected eye but also in the unaffected fellow eyes of patients with NAION, thicker choroids may be predisposing factor for NAION. However, PCT cannot be used to predict the visual outcomes of patients with NAION. Our study provided better understanding about the effects of choroid structure on the physiology and circulation around the optic nerve head. Patients with thicker PCT and other well-known risk factors may have a higher risk of NAION attack. Proper risk factor modification and regular follow-up are recommended for patients with unilateral NAION and thicker PCT. Further prospective studies with larger sample sizes and longer follow-up periods are necessary to validate our results and elucidate the underlying pathophysiology of structural changes of the optic nerve head and NAION attack.

Acknowledgments

Disclosure: **Y.-T. Hou**, None; **T.-C. Chen**, None; **C.-Y. Yeh**, None; **C.-W. Lin**, None

References

1. Biouesse V, Newman NJ. Ischemic Optic Neuropathies. *N Engl J Med*. 2015;372(25):2428–2436.
2. Berry S, Lin WV, Sadaka A, Lee AG. Nonarteritic anterior ischemic optic neuropathy: cause, effect, and management. *Eye Brain*. 2017;9:23–28.
3. Miller NR, Arnold AC. Current concepts in the diagnosis, pathogenesis and management of nonarteritic anterior ischaemic optic neuropathy. *Eye (Lond)*. 2015;29(1):65–79.
4. Fard MA, Abdi P, Kasaei A, et al. Peripapillary Choroidal Thickness in Nonarteritic Anterior Ischemic Optic Neuropathy. *Invest Ophthalmol Vis Sci*. 2015;56(5):3027–3033.
5. Pérez-Sarriegui A, Muñoz-Negrete FJ, Noval S, De Juan V, Rebolleda G. Automated Evaluation of Choroidal Thickness and Minimum Rim Width Thickness in Nonarteritic Anterior Ischemic Optic Neuropathy. *J Neuroophthalmol*. 2018;38(1):7–12.
6. Ho J, Branchini L, Regatieri C, et al. Analysis of normal peripapillary choroidal thickness via spectral domain optical coherence tomography. *Ophthalmology*. 2011;118(10):2001–2007.
7. Newman NJ, Scherer R, Langenberg P, et al. The fellow eye in NAION: report from the ischemic optic neuropathy decompression trial follow-up study. *Am J Ophthalmol*. 2002;134(3):317–328.
8. Moghimi S, Mazloumi M, Johari M, et al. Evaluation of Lamina Cribrosa and Choroid in Nonglaucomatous Patients With Pseudoexfoliation Syndrome Using Spectral-Domain Optical Coherence Tomography. *Invest Ophthalmol Vis Sci*. 2016;57(3):1293–1300.
9. Song W, Huang P, Dong X, Li X, Zhang C. Choroidal Thickness Decreased in Acute Primary Angle Closure Attacks with Elevated Intraocular Pressure. *Curr Eye Res*. 2016;41(4):526–531.
10. Park HY, Lee NY, Shin HY, Park CK. Analysis of macular and peripapillary choroidal thickness in glaucoma patients by enhanced depth imaging optical coherence tomography. *J Glaucoma*. 2014;23(4):225–231.
11. Schuster AK, Steinmetz P, Forster TM, et al. Choroidal thickness in nonarteritic anterior ischemic optic neuropathy. *Am J Ophthalmol*. 2014;158(6):1342–1347.e1.
12. García-Basterra I, González Gómez A, García-Ben A, et al. Macular choroidal thickness in nonarteritic ischemic optic neuropathy. *Arch Soc Esp Oftalmol*. 2016;91(5):223–227. Grosor corioideo macular en la neuropatía óptica isquémica anterior no arterítica.
13. Dias-Santos A, Ferreira J, Abegão Pinto L, et al. Choroidal Thickness in Nonarteritic Anterior Ischaemic Optic Neuropathy: A Study with Optical Coherence Tomography. *Neuroophthalmology*. 2014;38(4):173–179.
14. Nagia L, Huisingh C, Johnstone J, et al. Peripapillary Pachychoroid in Nonarteritic Anterior Ischemic Optic Neuropathy. *Invest Ophthalmol Vis Sci*. 2016;57(11):4679–4685.
15. Garcia-Basterra I, Lahrach I, Morillo Sanchez MJ, et al. Analysis of peripapillary choroidal thickness in non-arteritic anterior ischaemic optic neuropathy. *Br J Ophthalmol*. 2016;100(7):891–896.
16. Morrow MJ. Ischemic Optic Neuropathy. *Continuum (Minneapolis)*. 2019;25(5):1215–1235.
17. Hayreh SS. Ischemic optic neuropathy. *Prog Retin Eye Res*. 2009;28(1):34–62.
18. Beck RW, Servais GE, Hayreh SS. Anterior ischemic optic neuropathy. IX. Cup-to-disc ratio and its role in pathogenesis. *Ophthalmology*. 1987;94(11):1503–1508.
19. Gupta P, Jing T, Marziliano P, et al. Peripapillary choroidal thickness assessed using automated choroidal segmentation software in an Asian population. *Br J Ophthalmol*. 2015;99(7):920–926.
20. Chen T-C, Yeh C-Y, Lin C-W, et al. Vascular hypoperfusion in acute optic neuritis is a

- potentially new neurovascular model for demyelinating diseases. *PLoS One*. 2017;12(9):e0184927.
21. Lee SW, Yu S-Y, Seo KH, Kim ES, Kwak HW. Diurnal variation in choroidal thickness in relation to sex, axial length, and baseline choroidal thickness in healthy Korean subjects. *Retina*. 2014;34(2):385–393.
 22. Chang MY, Keltner JL. Risk Factors for Fellow Eye Involvement in Nonarteritic Anterior Ischemic Optic Neuropathy. *J Neuroophthalmol*. 2019;39(2):147–152.
 23. Tan CS, Ouyang Y, Ruiz H, Sadda SR. Diurnal Variation of Choroidal Thickness in Normal, Healthy Subjects Measured by Spectral Domain Optical Coherence Tomography. *Invest Ophthalmol Vis Sci*. 2012;53(1):261–266.
 24. Tesser RA, Niendorf ER, Levin LA. The morphology of an infarct in nonarteritic anterior ischemic optic neuropathy. *Ophthalmology*. 2003;110(10):2031–2035.
 25. Beck RW, Savino PJ, Repka MX, Schatz NJ, Sergott RC. Optic disc structure in anterior ischemic optic neuropathy. *Ophthalmology*. 1984;91(11):1334–1337.