

# Can the Macula be Attached if View Is Obscured by a Bullous Retinal Detachment? A Mathematical Consideration

William E. Smiddy<sup>1</sup>, Lev Kapitanski<sup>2</sup>, and Harry W. Flynn<sup>1</sup>

<sup>1</sup> Department of Ophthalmology, University of Miami Miller School of Medicine, Bascom Palmer Eye Institute, Miami, FL, USA

<sup>2</sup> Department of Mathematics, University of Miami, Miami, FL, USA

**Correspondence:** William E. Smiddy, Department of Ophthalmology, University of Miami Miller School of Medicine, Bascom Palmer Eye Institute, 900 NW 17th Street, Miami, FL 33136, USA. e-mail: [wsmiddy@med.miami.edu](mailto:wsmiddy@med.miami.edu)

**Received:** August 18, 2020  
**Accepted:** January 26, 2021  
**Published:** April 15, 2021

**Keywords:** retinal detachment; mathematical model; macular detachment; myopia

**Citation:** Smiddy WE, Kapitanski L, Flynn HW. Can the macula be attached if view is obscured by a bullous retinal detachment? a mathematical consideration. *Trans Vis Sci Tech.* 2021;10(4):13, <https://doi.org/10.1167/tvst.10.4.13>

**Purpose:** The purpose of this study was to determine if it is possible for the macula to remain attached if a bullous retinal detachment blocks the examiner's view to the macula.

**Methods:** A mathematical analysis compared the arc length of the attached retina versus the length of a detached retina necessary to obscure the macula (hang over the visual axis). The shape (oblate ellipsoid) and dimensions of the retina were based on a published study. The complete path of the hanging retina was calculated as a static catenary so as to depict the lowest possible position ("worst case scenario").

**Results:** The measured and calculated angle between the fovea and ora serrata was 105 degrees. When considering a catenary shape of the hanging retina, the macula could, mathematically, still be attached despite the retina hanging down 1.03 mm below the visual axis for an emmetropic eye. The maximal distance calculated was 1.095 mm for a –12 diopter (D) myopic eye.

**Conclusions:** If the macular center cannot be viewed due to a bullous superior retinal detachment hanging into the examiner's view, it is unlikely but possible that the macula remains attached. If the view is obscured by at least 1 mm below the fovea, it is not mathematically possible for the fovea to be attached.

**Translational Relevance:** The status of the macula being detached is subject to mathematical constraints, which, explored herein, offer a higher certainty of clinical decision making that could inform management for better clinical results.

## Introduction

One of the most well-established truths in vitreoretinal therapeutics is that the anatomic and visual results are superior if repair efforts can be initiated before the macula is involved by an advancing retinal detachment.<sup>1</sup> Thus, the accuracy of discerning the macular status has important implications regarding the visual prognosis and urgency of necessary attempted repair.

Occasionally, a patient will present with a superior, bullous retinal detachment that billows below the visual axis in such a way as to obscure the ophthalmologist's view to the macula. In most clinical instances, of course, ophthalmoscopic examination discloses a shallow "shoulder" – a more posterior lobe – of subreti-

nal fluid extending below the obscuration, which establishes macular involvement.

However, in some instances, a more posterior component is not apparent, so it cannot be determined with certainty that the macula is involved or spared. We have found B-scan ultrasonography to be imprecise in localizing the fovea but imaging can be an invaluable element of the pre-operative evaluation. Optical coherence tomography (OCT) might clarify the status of the macula, but is not always accurate due to fixation challenges or might not be immediately available given after hours of presentation of many acute retinal detachment patients. Hence, determining the prognosis and urgency for surgery are not ascertained as objectively or precisely as ideal. These authors were schooled in the dictum that if the macula could not be seen, then it must be involved. This generally unchallenged

hypothesis is based on the intuition that the nonmacular detached portion of the retina is not long enough to extend so far central as to obscure the visual axis.

The most simplistic model of the eye, the Gullstrand model, postulates a spherical posterior segment appended by the more curved cornea.<sup>2</sup> Although this works well in most instances, especially for optic calculations, it is an oversimplification of the true shape of the retina; this might yield incorrect results when trying to answer mathematically a question as just introduced above.

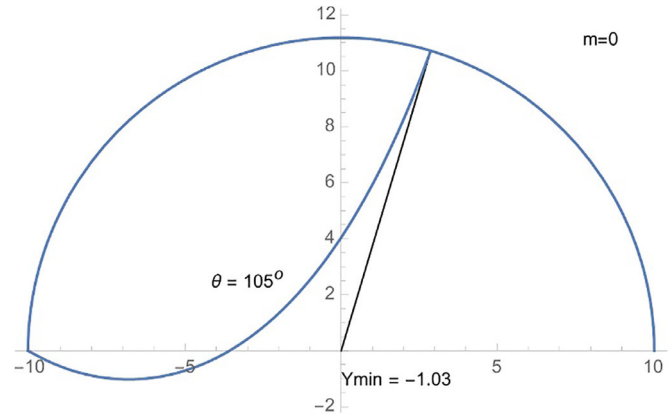
Others have measured the shape of the retina using various forms of imaging, most elegantly using magnetic resonance imaging by Atchison et al.<sup>3</sup> Atchison tabulated many enhanced measurements and concluded that the retina more closely approximates an ellipsoid – more specifically, an oblate ellipsoid where the sagittal and transverse dimensions are similar and slightly longer than the transverse (i.e. optical) axis.

Using the dimensions Atchison deduced, we attempted to determine whether it was mathematically possible for the arc length of a superior, bullous retinal detachment to be sufficiently long to hang down over the visual axis, and, if so, what boundary conditions permit this.

## Methods

This study was conducted in adherence with the Declaration of Helsinki. Institutional review board approval was not required because no patients or privileged health information were involved. The mathematical model included considerations that the retinal shape is not a sphere but rather an ellipsoid (as Atchison et al.<sup>3</sup> deduced), and that the detached retina assumes a catenary shape as for any freely hanging, weighted cable.<sup>4</sup> We assumed a static situation, so that fluid shifts were not a factor. Moreover, we considered an average sized retinal break so that additional extension of the detached retina was not created. We also did not consider the possibility of the retina stretching, because little is known about that possibility or its extent.

A necessary parameter to calculate the arc length from the fovea to the ora serrata (i.e. the available substrate of retina to be detached) is the angle,  $\theta$ , from the fovea to the ora serrata (Fig. 1). This parameter is not clearly established in the literature; rather, anatomic treatises report the chord lengths from the limbus to the muscle insertion (i.e. the superior rectus insertion at 7.7 mm corresponds to the ora serrata) and the cornea dimensions (12 mm limbus to limbus).<sup>5</sup>



**Figure 1.** Model of hanging retina as a catenary in an emmetrope with the angle,  $\theta$ , from the fovea as 105 degrees. The retina hangs 1.03 mm below the visual axis.

Subtracting the angles corresponding to those measurable chord lengths, and subtracting from 180, gives an approximation of  $\theta$ . This yielded about 105 degrees. Applying a protractor to measure published gross pathology section photographs determined that the arc,  $\theta$ , from the ora to the fovea is also about 105 degrees. However, a range from 100 degrees to 120 degrees was evaluated in our analysis.

The Atchison model<sup>3</sup> was simplified to an ellipse taken in the sagittal plane (we will refer to this as the yz-plane) to model the hanging retina (see Fig. 1). They set the fovea as the posterior extent along the z-axis; the current study was based on that same reference point. The radii of the retina in these dimensions for an emmetrope were 11.18 mm vertically (the y-axis, b in the ensuing equations) and 10.04 mm horizontally (the z-axis, the approximate optical axis, a in the ensuing equations). In addition, the Atchison model determined that these dimensions (mm) vary with diopters of myopia (m, up to 12 diopter [D]) as  $z = 10.04 + 0.16 m$ , and  $y = 11.18 + 0.09 m$ .

The arc length of a sphere (circle in sagittal section) can easily be computed. However, computation of the arc length along the ellipse is more complicated. A more detailed description of the mathematical formulas and solutions is provided in the Appendix; only a brief description will be included in this text. The equation of the ellipse in the yz-plane is  $y^2/b^2 + z^2/a^2 = 1$ , where a is the length of the corresponding minor axis in the z direction (optical axis) and b is the corresponding major axis in the y direction (vertical axis). The upper half of the ellipse is the graph of the function  $y = f(z) = b\sqrt{1 - z^2/a^2}$ . Another convenient parametrization is  $z = -a \cos t$  and  $y = b \sin t$ , where t runs from 0 to  $\pi$ . With it, the arc length along the portion of the ellipse from the fovea (z-intercept which is  $[-a, 0]$  where  $\theta = 0$ ) to the prescribed position  $(z_1, y_1)$  on the ellipse

(corresponding to some  $\theta$ ) is expressed by Equation 1:

$$L_e(z_1) = \int_{-a}^{z_1} \sqrt{1 + \left(\frac{df(z)}{dz}\right)^2} dz \Big|_{z=-a \cos t} = b \int_0^{\arccos(-z_1/a)} \sqrt{1 - \left(1 - \frac{a^2}{b^2}\right) \sin^2 t} dt. \quad (1)$$

However, this cannot be expressed with simpler standard integral calculus, as the integral is the elliptic integral of the second kind (see Appendix). Hence, we use Mathematica, to calculate this arc length but other, similar computational tools, such as MatLab or SciPy, could achieve this as well.

A determination of whether the arc length of the retina, when detached, is large enough to extend below the z- (visual) axis requires comparing this to the pathlength of the hanging retina. The current study assumes a “worst case scenario” in which there is no separate, posterior lobe of subretinal fluid, and where the hanging retina assumes the shape that results in the lowest possible extent of its inferior edge.

Thus, we considered the shape of the hanging retina to be a catenary (hyperbolic trigonometrically defined) in the sagittal plane, with the tether points at the ora serrata anteriorly and the posterior extent of the retinal detachment.

Thus, the parameters  $\alpha$ ,  $\lambda$ , and  $s$  of the catenary (Equation 2)

$$y(z) = -\lambda + s \cosh\left(\frac{z + \alpha}{s}\right) \quad (2)$$

were computed from the restrictions that the catenary (detached retina) must hang from the given tether points  $(z_0, y_0)$  and  $(z_1, y_1)$  on the ellipse, and, in addition, the arc length of the portion of the ellipse between those points and the arc length of the catenary must be equal.

The arc length of the hanging catenary is given by Equation 3

$$L_{cat}(z_0, z_1) = s \left[ \sinh\left(\frac{z_1 + \alpha}{s}\right) - \sinh\left(\frac{z_0 + \alpha}{s}\right) \right] \quad (3)$$

whereas the arc length of the ellipse between the same tether points is given by Equation 4:

$$L_e(z_0, z_1) = b \int_{\arccos(-z_0/a)}^{\arccos(-z_1/a)} \sqrt{1 - \left(1 - \frac{a^2}{b^2}\right) \sin^2 t} dt. \quad (4)$$

(see Appendix for details of these calculations). Because of the nonelementary form of the arc length,

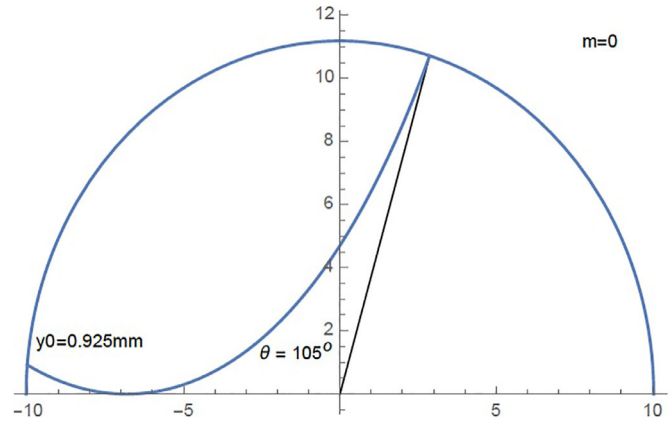


Figure 2. Model of hanging retina as a catenary in an emmetrope with the angle,  $\theta$ , from the fovea as 105 degrees. The maximal distance for the retina to be inserted above the fovea when the hanging retina is tangent to the visual axis is 0.925 mm.

finding numerical values of the parameters of the catenary required Mathematica to calculate.

## Results

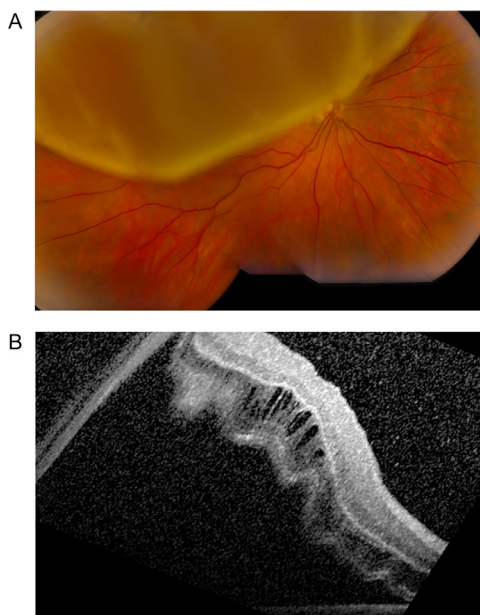
The result was that the retina could hang down below the optical axis throughout a broad range of arc angle (from the z-axis to the ora serrata). For an emmetropic eye, if  $\theta$  was, theoretically, less than 73 degrees, the catenary could not hang below the visual axis, but for larger  $\theta$  it could, and at  $\theta = 105^\circ$  degrees, which most closely depicts the human eye, it will hang 1.03mm below the axis (for an emmetrope, i.e. when  $m = 0$ ; see Fig. 1). This distance increased such that if  $\theta$  was 120 degrees the distance would be 2.41 mm.

We also calculated how far above the fovea the posterior extent of the retinal detachment could be tethered (in an emmetrope) to just barely allow a view to the fovea (i.e. when the hanging retina was tangent to the optical [z-] axis) and found it was 0.925 mm (Fig. 2).

The distance the retina could hang below the optical axis was also calculated for different degrees of myopia (0 to 12 diopters), but there was only a minimal increase, to 1.095 for -12 (assuming  $\theta = 105$  degrees).

## Discussion

The current study involved calculations based on the most comprehensive, empiric model and measurements of the shape of the retina.<sup>3</sup> The principal finding is that it is mathematically possible for the retina to hang below the visual axis sufficiently to obscure the



**Figure 3.** (A) Fundus photograph of bullous superior retinal detachment hanging below the visual axis, obscuring a view to the fovea. (B) OCT demonstrating probable position of the fovea as detached.

view to the fovea without the fovea becoming detached. Hence, if the fovea cannot be seen, it is not necessarily detached. This has implications for prognosis and the urgency of pursuing definitive repair.

An ancillary implication is that if the examiner cannot visualize portions of attached retina within 1.03 mm (approximately  $2/3$  of a disc diameter) below the fovea, then it is not possible for the fovea to be attached in an emmetrope. For more myopic eyes, the distance from the macula that can be obscured without requiring macular involvement was only minimally larger (presuming a similar arc angle from the ora to the fovea, when in fact this might be smaller in a myope because the ora serrata is located proportionately more posteriorly both from the Atchison model and a previous empiric study<sup>6</sup>). Our presumption for this is that the magnitude of the change in the length of the eye (approximating a sphere, and in the extreme case becoming a prolate ellipsoid) simply did not yield enough dimensional change to alter the (relatively imprecise) clinical observational implications meaningfully.

When the fovea cannot be visualized, an OCT (or possibly an ultrasound, perhaps an A scan might be more accurate than a B scan) might allow definitive evaluation of the macular status. Although this study did not evaluate this specifically, we have had some experience with finding foveal detachment (Fig. 3) but have not identified a case in which it was definitely

uninvolved. Even if the current study has grossly erred in determining the arc from the fovea to the ora serrata, the maximum overhang is about 2.4 mm, hence the same inference process as above can be applied, but the variation with increasing myopia was miniscule.

An important consideration in these calculations is that it represents the “worst case scenario,” the mathematical maximum extension of the retina as constrained by the arc length that is detached. That is, it presumes that the retina hangs like a cable and that it does not have another, posterior “lobe” of retinal detachment shape that might involve the macula. The clinician knows from experience that the latter is commonly the case. A classic situation is that a bullous superior retinal detachment is billed as macular sparing, but a more shallow, subtle, macular-involving zone of detachment posterior to the larger, more bullous portion was overlooked, establishing macular detachment.

There are many areas of possible deviations from our idealized mathematical model in the biologic variations in the true state. One set of key assumptions were that the shape of the retina approximates an ellipsoid with the sagittal section describing an ellipse, and that in the static, examining position, the retina hangs completely as a catenary without a more posterior lobe of detachment. This seems intuitively reasonable because the degree of bullous configuration in a retinal detachment does shift (although not as much or in distribution as in the classic exudative case). We adapted Atchison’s empiric model of an ellipsoid, but even that is only an approximation as there were relatively minor deviations.<sup>3</sup> Distantly, a hanging cable was thought to have assumed a shape of parabola. With its axis of symmetry parallel to the y axis, a parabola is defined by three parameters, which can be determined to satisfy the boundary conditions and the path length. However, the computation is more complex than with the catenary and no closed form solutions can be obtained. The parabola is “slimmer” than the catenary and dips deeper. Looking for a triangular shape, one would find even lower minimum point (and no uniqueness). We posit that the catenary is physically the most appropriate shape in our case.

Our model also addresses the static situation as the clinician might encounter it upon examining the eye, choosing not to consider effects on temporal changes in the configuration that might be present with saccades or position.

Another possible shortcoming of this study is that it did not rigorously assess for possible stretching of the retina, which might would overestimate the sagging distance in a macular spared retinal detachment. From



the physical point of view, the catenary shape of a chain may be derived from the balance of forces acting on chain's segments. For a catenary, any force of tension exerted by the chain is parallel to the chain. In a more realistic, three-dimensional picture of the detached retina, there will be lateral forces (in the xy-plane) that would prevent the sagittal cross-section from hanging freely and thus would shorten the vertical reach. The Young's modulus has been calculated ex vivo for the retina and found to be about 1/100 that of standard rubber, meaning retina is very deformable.<sup>7</sup> The elasticity of the retina has been evaluated using acoustic radiation force optical coherence elastography (in ex vivo porcine retina) finding the outer retina layers to be more elastic than the inner layers.<sup>8</sup> Another study used Brillouin microscopy in ex vivo murine retinal, but did not find a difference between the inner and outer retinal layers.<sup>9</sup> The retina is a nonhomogeneous solid, and we are suspicious that in vivo it would likely demonstrate neoHookean characteristics<sup>10</sup> due to its more complex, interlocking, and cellular structure. We hypothesize, however, that the tiny differences in specific gravity of subretinal fluid (minimally different from vitreous fluid in the acute retinal detachment, because the protein concentration, which determines of specific gravity<sup>11</sup> – about 1.02 g/cm<sup>3</sup>)<sup>12</sup> the retina (1.04)<sup>13</sup> and vitreous (1.0053–1.008)<sup>14</sup> would seem to be of minimal gravitational impact to effect stretching. If the retina did stretch, it could hang down even further below the optical axis before peeling off at the fovea.

Other limitations of the elasticity assumptions are that we have ignored any effect that a tear in the retina (which, if large, could be very important) might have on the distensibility of the retina. Conversely, we have ignored the possible restrictions in elasticity that local or regional pathology, such as amputated chorioretinal scars or epiretinal membranes, might induce.

Careful clinical evaluation and examination should continue to inform optimal assessment of macular status, but mathematical modeling lends a modicum of comfort in avoiding mistaking an impending macular involvement for the actuality of macular involvement.

## Acknowledgments

Presented (virtually) at the Retina Society Meeting, 2020.

Disclosure: **W.E. Smiddy**, None; **L. Kapitanski**, None; **H.W. Flynn**, None

## References

1. Burton TC, Lambert RW, Jr. A predictive model for visual recovery following retinal detachment surgery. *Ophthalmology*. 1978;85(6):619–625.
2. Atchison DA. Optical models for human myopic eyes. *Vis Research*. 2006;46:2236–2250.
3. Atchison DA, Pritchard N, Schmid, et al. Shape of the retinal surface in emmetropia and myopia. *Invest Ophthalmol Vis Sci*. 2005;46(8):2698–2707.
4. James Stewart. Essential Calculus. 2nd Edition, Independence, KY: Brooks/Cole, Cengage Learning; 2013, Section 5.7
5. Hogan MJ, Alvarado JA, Weddell. Histology of the human eye; an atlas and textbook. Philadelphia, PA: Saunders; 1971, pp. 1–7.
6. Gallogly P, Smiddy WE, Feuer WJ. The effect of myopia on the position of the ora serrata. *Ophthalmic Surg Lasers Imaging*. 2007; 38(6):518–519.
7. Jones IL, Stevens JD. Mathematical modelling of the elastic properties of retina: a determination of Young's Modulus. *Eye*. 1992;6:556–559.
8. Qu Y, He Y, Zhang Y, et al. Quantified elasticity mapping of retinal layers using synchronized acoustic radiation force optical coherence elastography. *Biomed Optics Express*. 2018;9(9):4054.
9. Ambekar YS, Singh M, Scarcelli G, et al. Characterization of retinal biomechanical properties using Brillouin microscopy. *J Biomed Optics*. 2020;25(9):1–7.
10. Ogden RW. Non-Linear Elastic Deformations. Mineola, NY: Dover Publications, Inc.; 1997.
11. Weech AA, Reeves EB, Goettsch . The relationship between specific gravity and protein content in plasma, serum and transudate from dogs. *J Biol Chem*. 1936;113:167–174.
12. Heath H, Beck TC, Foulds WS. Chemical composition of subretinal fluid. *Brit J Ophthalmol*. 1962;46:385–396.
13. Stefansson E, Wilson CA, Lightman SL, et al. *Invest Ophthalmol Vis Sci*. 1987;28:1281–1289.
14. Donati S, Capani SM, Airaghi G, et al. Vitreous substitutes: The present and the future. *Biomed Res Int*. 2014;2014:article ID 351804.