

Correlation of Complement Activation in Aqueous and Vitreous in Patients With Proliferative Diabetic Retinopathy

Jesse M. Smith¹, Nikhil Mandava¹, Vanessa Tirado-Gonzalez², Rodrigo Garcia-Santisteban², Matthew D. Geiger¹, Jennifer L. Patnaik¹, Ashley Frazer-Abel³, Anne M. Lynch¹, Naresh Mandava¹, V. Michael Holers⁴, Brandie D. Wagner⁵, Idaira Sanchez-Santos², Daniela Meizner², Hugo Quiroz-Mercado², and Alan G. Palestine¹

¹ Department of Ophthalmology, University of Colorado School of Medicine, Aurora, CO, USA

² Asociación Para Evitar La Ceguera, Mexico City, Mexico

³ Exersa BioLabs, University of Colorado School of Medicine, Aurora, CO, USA

⁴ Departments of Immunology and Medicine, University of Colorado School of Medicine, Aurora, CO, USA

⁵ Department of Biostatistics and Informatics, University of Colorado School of Public Health, Aurora, CO, USA

Correspondence: Jesse M. Smith, Department of Ophthalmology, University of Colorado School of Medicine, 1675 Aurora Ct, Mail Stop F731, Aurora, CO 80045, USA. e-mail: jesse.smith@cuanschutz.edu

Received: September 20, 2021

Accepted: March 24, 2022

Published: April 14, 2022

Keywords: complement; aqueous; diabetic retinopathy; vitreous

Citation: Smith JM, Mandava N, Tirado-Gonzalez V, Garcia-Santisteban R, Geiger MD, Patnaik JL, Frazer-Abel A, Lynch AM, Mandava N, Holers VM, Wagner BD, Sanchez-Santos I, Meizner D, Quiroz-Mercado H, Palestine AG. Correlation of complement activation in aqueous and vitreous in patients with proliferative diabetic retinopathy. *Transl Vis Sci Technol.* 2022;11(4):13, <https://doi.org/10.1167/tvst.11.4.13>

Purpose: A growing body of evidence suggests complement dysregulation is present in the vitreous of patients with diabetic eye disease. Further translational study could be simplified if aqueous—as opposed to vitreous—were used to sample the intraocular complement environment. Here, we analyze aqueous samples and assess whether a correlation exists between aqueous and vitreous complement levels.

Methods: We collected aqueous, vitreous, and plasma samples from patients with and without proliferative diabetic retinopathy (PDR) undergoing vitrectomy. We assessed correlation between complement levels in aqueous and vitreous samples after using a normalizing ratio to correct for vascular leakage. Spearman correlation coefficients were used to assess the correlation between complement levels in the aqueous and vitreous.

Results: Aqueous samples were obtained from 17 cases with PDR and 28 controls. In all patients, aqueous Ba, C3a, and albumin levels were strongly correlated with vitreous levels (Spearman correlation coefficient of 0.8 for Ba and C3a and 0.7 for albumin; all P values < 0.0001). In PDR eyes only, aqueous and vitreous C3a levels were significantly correlated (Spearman correlation coefficient 0.7; $P = 0.002$), whereas in control eyes, both Ba and C3a (Spearman correlation coefficients of 0.7; $P < 0.0001$) were significantly correlated.

Conclusions: A strong correlation exists between aqueous and vitreous complement levels in diabetic eye disease.

Translational Relevance: The results establish that accurate sampling of the intraocular complement can be done by analyzing aqueous specimens, allowing for the rapid and safe measurement of experimental complement targets and treatment response.

Introduction

Complement is a key part of the innate immune system and the first line of defense against pathogens. A critical step in complement activity is the formation of

C3 convertase, an enzyme that cleaves C3 into C3a and C3b.¹ This step is the common point of convergence of the three pathways and the initiation of the effector functions of the complement system.² In a previous study, we sampled the vitreous of patients with proliferative diabetic retinopathy (PDR) and found two

complement components in high abundance: C3a and Ba.³ C3a is a unbound peptide mediator of inflammation that is a product of the cleavage of C3. The other product is C3b that, together with factor Bb (a product of the cleavage of factor B), combine to form C3 convertase, thus initiating the terminal function of the system. The presence of C3a and Ba in vitreous suggests that the corresponding split products—C3b and Bb—were active at the time of sampling, but were membrane bound and not free floating in the vitreous, which explains the relative abundance of the soluble “a” products.

Complement in ophthalmic disease is an area of rapidly growing research. Studies have shown its involvement in age-related macular degeneration, uveitis, and glaucoma, among other diseases, and the complement system has been a recent target of drug development.^{4–7} In uveitis, for example, complement-depleted animals show a marked reduction of several cytokine levels in experimental autoimmune uveitis, while injection of anti-C3 receptor antibody had a significant protective effect in progression of experimental uveitis.^{8,9} In age-related macular degeneration, complement dysregulation has been demonstrated at the level of the retinal pigment epithelium, Bruch’s membrane, and the choriocapillaris, and it has become clear that polymorphisms in genes encoding factor H and its receptors, factor I, and factor 3 considerably influence the risk of disease.¹⁰

Although complement dysregulation in eye disease continues to attract interest, relatively few studies exist regarding the role of complement in diabetic retinopathy (DR).^{4,11–13} In our own prior study of vitreous complement, we demonstrated significantly increased complement activity in the vitreous of eyes with DR as compared with eyes without retinopathy.³ As a part of our specimen collection for that study, we sampled aqueous and plasma from the same patient cohort for later analysis. Here, we analyze the aqueous samples.

Our goal in describing the role of complement in DR is to develop targets for diagnostic and therapeutic application. One limitation in the pursuit of that goal is the fact that obtaining vitreous samples is neither easy nor practical in a clinic setting. Aqueous samples, by contrast, are relatively simple to obtain. Accordingly, we wanted to learn whether aqueous samples can be used as a proxy for vitreous complement activity in future studies. Our hypothesis was that, by using paired aqueous, vitreous, and plasma samples, we could demonstrate a correlation between these specimens. If true, it would indicate that aqueous complement measurement could be used in future research for risk stratification and the development of targeted treatments using complement inhibition.

Methods

This case-control study was approved by the Colorado Multiple Institutional Review Board and La Comité de Ética en Investigación de la Asociación para Evitar la Ceguera en Mexico, IAP. All samples were collected at the Asociación para Evitar la Ceguera en Mexico in Mexico City, Mexico. All research adhered to the tenets of the Declaration of Helsinki. Informed consent was obtained from all subjects after an explanation of the nature and possible consequences of the study. Each patient granted written consent for medical chart review and collection vitreous, aqueous, and plasma samples.

Data coordination, management, and statistical analysis was performed in the Division of Ophthalmic Epidemiology, Department of Ophthalmology at the University of Colorado School of Medicine and sample analysis was performed at Exsera BioLabs, Division of Rheumatology at the University of Colorado School of Medicine. Surgeries and sample collection were performed between July 2018 and December 2019.

Cases and Controls

All patients underwent a preoperative dilated fundus examination. Cases were patients with diabetes undergoing pars plana vitrectomy for tractional retinal detachment as a result of PDR. Controls were patients without clinical evidence of DR undergoing pars plana vitrectomy for epiretinal membrane or macular hole.

Exclusion Criteria

Exclusion criteria were as follows: concurrent ocular procedures other than cataract surgery, comorbidities of the retina, nonproliferative DR, vitreous hemorrhage (identified before or during surgery), and treatment with laser or anti-vascular endothelial growth factor injections within the 3 months preceding surgery. Finally, patients from whom aqueous was not collected were excluded.

Collection and Processing of the Ethylenediaminetetra-Acetic Acid (Lasma Sample

Following phlebotomy, the ethylenediaminetetraacetic acid tube was spun at 3000 rpm in a cooled (4°C) centrifuge for 10 minutes to isolate plasma. Aliquots of plasma were stored at –80°C within 30 minutes

of collection. The average time from phlebotomy to spin was 8.2 minutes \pm standard deviation 2.8 minutes (range, 3–21 minutes).

Vitreous Collection

After the eye was prepped and draped in the normal sterile manner, vitrectomy trocars were placed through the pars plana in the standard fashion. The infusion cannula was left clamped to prevent sample dilution. Air was infused into the eye during core vitrectomy to maintain physiologic pressure. During vitrectomy, at least 1 mL of undiluted vitreous was removed using a 3- or 5-mL syringe connected to the aspiration tubing of the vitrectomy probe. All samples were stored at -80°C .

Complement Factor Analysis

The frozen cryovials were transferred from APEC to Exsera BioLabs, a CAP/CLIA-certified laboratory for analysis. Complement factors Ba and C3a were measured, as well as albumin for normalization. Measurement of complement components and activation fragments was performed by two methods. The Ba and C3a levels were measured by enzyme-linked immunosorbent assays (Quidel Corp, San Diego CA). The albumin assay was performed by multiplex Luminex immunoassays (MilliporeSigma, Burlington, MA). For both methods, Exsera had previously optimized the methods to measure a low concentration and were validated to the level required for regulated laboratory analysis. All analyses were performed in duplicate with the resulting mean values used for analyses. For the multiplex Luminex data, the mean fluorescent intensity was the raw value and for the enzyme-linked immunosorbent assay analysis the raw value was optical density. Six nonpoint, standard curves were fit with a four-parameter parametric curve fit were used to calculate the absolute quality in picograms per milliliter, nanograms per milliliter, or micrograms per milliliter, as appropriate. Three quality controls were included in each run, including at least one laboratory developed and characterized quality control. The quality controls were monitored for performance. For sensitivity, all specimens that were below the test sensitivity were reported as less than the lower limit of quantitation. To test specificity, purified complement components were spiked into the analysis and recover of $100\% + 20\%$ was tested. For all testing in the study, the values returned were within required parameter of assay performance.

Statistical Analysis

Descriptive statistics included basic frequencies for categorical variables and means, associated standard deviations, medians and ranges for continuous variables. The *t* test was used to compare age between cases and controls. Because complement factors were not normally distributed, Spearman rank correlation coefficients were used to assess protein-specific correlations between aqueous and vitreous samples, as well as aqueous and plasma samples. Spearman correlation coefficients were used because complement levels were not normally distributed. These correlations were examined across all patients and stratified by case-control status. To adjust for vascular leakage in the eye, the ratio of each complement factor in the aqueous/vitreous and plasma was adjusted for albumin levels in both the aqueous/vitreous and plasma, with the normalized ratios. For vitreous, we used $\frac{\text{Vitreous complement} \div \text{Vitreous albumin}}{\text{Plasma complement} \div \text{Plasma albumin}}$. For aqueous, we used $\frac{\text{Aqueous complement} \div \text{Aqueous albumin}}{\text{Plasma complement} \div \text{Plasma albumin}}$. The signed-rank test was used to compare the aqueous normalized ratio with the vitreous normalized ratio for Ba and C3a. A *P* value of less than 0.05 was considered statistically significant throughout the analysis. SAS software (version 9.4, SAS Institute Inc., Cary, NC) was used for merging laboratory and epidemiologic data and for statistical analyses.

Results

Forty-five patients met the inclusion criteria. Table 1 shows demographic characteristics for the 17 DR cases and 28 controls. All of the cases and eight controls

Table 1. Demographic Characteristics for Patient Cases with DR and Controls

Status	DR Cases # (%)	Controls # (%)
Total	17	28
Gender		
Male	4 (23.5%)	6 (21.4%)
Female	13 (76.5%)	22 (78.6%)
Family history of diabetes		
None	2 (11.8%)	9 (32.1%)
Yes	15 (88.2%)	18 (64.3%)
Unknown	0	1 (3.6%)
Type 2 diabetes		
Yes	17 (100%)	8 (28.6%)
No. of years, median (range)	17.0 (1–30)	7.0 (2–23)
Age, years		
Mean (standard deviation)	52.8 (7.2)	64.3 (5.6)
Median	53	66

Table 2. Correlations Between Complement in Aqueous and Plasma/Vitreous

	No. of Subjects	Mean (Standard Deviation) Median (Range)	Spearman Correlation Coefficient With Aqueous		
			All Patients P Value	Cases Only P Value	Controls Only P value
Ba vitreous	43	81.1 (110) 15.0 (1–400)	0.79<0.0001	0.340.206	0.660.0001
Ba aqueous	45	29.4 (37.3) 12.0 (2–155)			
C3a vitreous	43	15.0 (26.0) 3.3 (0.1–147)	0.82<0.0001	0.720.002	0.68<0.0001
C3a aqueous	45	8.7 (12.2) 3.3 (0.10–53.2)			
Albumin vitreous	42	73.2 (88.8) 26.5 (3.9–336)	0.67<0.0001	0.240.431	0.560.004
Albumin aqueous	41	30.7 (42.3) 17.0 (2.0–228)			
Ba plasma	41	749 (434) 597 (321–2950)	0.220.164	0.190.495	–0.110.604
C3a plasma	44	65.5 (36.8) 53.0 (34.0–251)	–0.040.804	–0.230.386	–0.010.961
Albumin plasma	44	3942 (447) 3965 (2760–4770)	–0.050.766	0.190.522	0.260.204

had a diagnosis of diabetes. Cases and controls had a similar distribution by sex, but cases were younger with mean age of 52.8 ± 7.2 years versus 64.3 ± 5.6 years for controls ($P < 0.0001$). Two cases and no controls had neuropathy and no participants had kidney or vascular disease. Twelve cases and 8 controls were taking oral medication for their diabetes, and 12 cases and 2 controls were on insulin at enrollment.

Sufficient volume for aqueous sampling was available in 45 patients for Ba and C3a and in 41 patients for albumin.

Table 2 shows correlation coefficients between aqueous and vitreous levels and aqueous and plasma level of Ba, C3a, and albumin for all study participants and by case/control status. For all patients, positive statistically significant correlations were

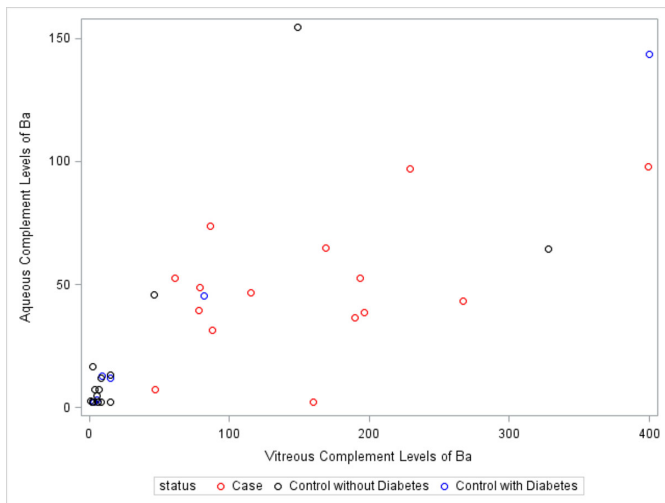


Figure 1. Plot of Ba in vitreous and aqueous by case and control (with and without diabetes) status.

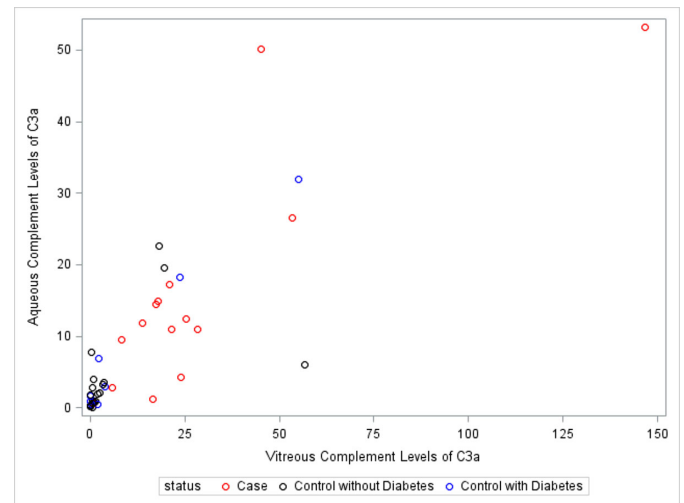


Figure 2. Plot of C3a in vitreous and aqueous by case and control (with and without diabetes) status.

Table 3. Correlations between Complement Normalized Ratios in Aqueous and Vitreous

	No. of Subjects	Mean (Standard Deviation) Median (Range)	Spearman Correlation Coefficient With Aqueous		
			All Patients <i>P</i> Value	Cases Only <i>P</i> Value	Controls Only <i>P</i> Value
Ba vitreous	38	6.8 (13.4) 4.0 (0.2–84.3)	0.41 0.014	0.49 0.106	0.45 0.030
Ba aqueous	38	8.3 (17.1) 5.2 (0.7–109)			
C3a vitreous	41	19.7 (48.3) 6.8 (0.2–287)	0.48 0.003	0.69 0.013	0.41 0.042
C3a aqueous	40	33.3 (46.5) 17.2 (0.10–245)			

present between aqueous and vitreous for each of the measured proteins (0.79 for Ba, 0.82 for C3a, and 0.67 for albumin; all *P* values < 0.0001). Correlations were also positive and significant within the control group and for C3a among cases; however, Ba and albumin were not significant for the cases-only group. Correlations for these proteins were not significant between the aqueous and plasma samples for any study group. Figures 1 and 2 show correlation plots for aqueous versus vitreous levels of C3a and Ba.

Table 3 shows the correlation between aqueous and vitreous levels of Ba and C3a after normalization with the $\frac{\text{Aqueous complement} \div \text{Aqueous albumin}}{\text{Plasma complement} \div \text{Plasma albumin}}$ ratio. Normalization was not done for albumin because it was the reference protein. In Table 3, statistically significant correlations were present across all patients and for the controls-only group for Ba and C3a. The correlation of normalized ratios for Ba did not reach statistical significance within the cases-only group (*P* = 0.106). Following normalization, levels of C3a and Ba were higher in aqueous than in vitreous (5.2 vs. 4.0 of Ba [*P* = 0.279] and 17.2 vs. 6.8 for C3a [*P* = 0.0002], although only significantly higher for C3a.

Discussion

In this study, we analyzed samples of aqueous, vitreous, and plasma from patients undergoing vitrectomy. The results demonstrate that specific complement levels in aqueous strongly correlate with their respective complement levels in vitreous. This finding provides a preliminary basis to use aqueous sampling for ascertainment of intraocular complement levels in future studies. The significance of using aqueous as opposed to vitreous is that aqueous is substantially safer, faster, and easier to obtain in a clinic setting. Based on our findings, future studies looking at the

intraocular complement environment will be made considerably more practical.

Good reasons exist to study complement activation in diabetic eye disease. The current literature on the subject convincingly points to involvement of the complement system, but has not yet identified a specific role. Muramatsu et al found significantly elevated levels of C5a in the vitreous of PDR eyes, although Manoharan et al. found elevated levels of factor D and C9.^{14,15} A study of cadaveric diabetic eyes showed lower levels of the complement inhibitors CD55 and CD59 as well as colocalized deposits C3 and C5b-9 (the membrane attack complex) within vessel walls.¹⁶ In our own study published previously on vitreous complement activity in PDR, we found increased ratios of C3a/C3, C5a/C5, and Ba to factor B, indicating local activation of complement in the vitreous cavity.³

Beyond DR, complement dysregulation is well-reported in a spectrum of ophthalmic diseases, including age-related macular degeneration, uveitis, and glaucoma.^{4,6,7} Outside the eye, complement clearly plays a role in systemic complications of diabetes. For example, Flyvbjerg showed the membrane attack complex directly mediated glomerular injury in diabetic nephropathy.¹⁷ Qin et al. showed inactivation of the complement regulatory protein CD59 in nerve biopsies from patients with diabetic neuropathy.¹⁸ Importantly, no studies have proposed a complement-mediated innate immune reaction to a pathogen as a cause of DR—the interest instead lies in complement dysregulation and its role as a component of inflammation and cell death. Because complement dysregulation is present in multiple ophthalmic diseases as well as system-wide in diabetes, it is clear the role of complement is important in the diabetic eye.

Despite previous studies showing intraocular complement is present in DR, a simple measurement of complement components in aspirated aqueous or

vitreous presents a problem: vitreous samples from diabetic eyes contain proteins leaked into the eye from the systemic circulation because of diabetic damage to the vascular endothelium. This fact makes it challenging to differentiate local activation of complement from generic diabetic vascular leakage. We sought to solve this problem in a previous paper using an adaptation of the Goldman–Witmer ratio, a normalizing ratio that has long been used to differentiate between local and systemic production of antibodies found in intraocular fluid.^{3,19} In that article, we used the ratio $\frac{\text{Vitreous complement} \div \text{Vitreous albumin}}{\text{Plasma complement} \div \text{Plasma albumin}}$ to normalize our samples, and we used the same ratio altered for aqueous in the present study: $\frac{\text{Aqueous complement} \div \text{Aqueous albumin}}{\text{Plasma complement} \div \text{Plasma albumin}}$. With this ratio, we were able to correct for vascular leakage, and our results are, therefore, more reflective of local complement activation as opposed to leakage of circulating systemic complement components.

There is a strong correlation between measured complement components in the vitreous and the aqueous. Because the volume of the anterior chamber is only 300 μL , most aqueous sampling for complement is limited by low volume, and thus we could only run assays for select complement components. We chose Ba and C3a because they were the most highly elevated components when we analyzed vitreous samples with the normalized ratio in our previous study and because they represent activation of complement. In the present study, Ba and C3a were elevated in both aqueous and vitreous, and the levels were moderately to strongly correlated.

Although C3a and Ba were elevated in both aqueous and vitreous, there was a relatively higher concentration of both components in aqueous. This finding suggests that the retina is not the only, and perhaps not even the most significant, site of complement dysregulation in diabetic eyes. If the retina were the source of all measured complement in the intraocular environment, then the vitreous should have a higher concentration of these components than the aqueous—the concentration would be expected to decrease further from the source. But instead, we found the opposite: the concentration is higher in the anterior segment. This disparity suggests that not all our measured complement components come from the retina. Rather, complement dysregulation is almost certainly present in the vascular structures of the anterior segment—the iris and ciliary body. Intuitively, this makes sense—microvascular networks prone to diabetic vasculopathy are present in both iris and ciliary body, just as they are in the retina. In fact, vascular leakage seen in fluorescein angiography of the iris precedes detectable changes in retinal angiography.^{20,21} A study looking at quantitative analysis of anterior chamber flare as a

measure of protein leakage into the aqueous showed that breakdown of the blood-aqueous barrier precedes the development of clinical DR.²² Our findings are consistent with the overall concept that diabetic vascular changes occur system wide, and that the iris and ciliary body, by virtue of their greater blood flow, are probably affected by diabetic vascular damage before the retina.

In this study, small volumes limited the number of samples that could be used for complement assays simply because the assay requires a minimum amount of fluid to run. Small volumes also mean that the number and variety of complement assays on aqueous is limited for this and other studies. Another limitation of this study is that we included diabetic patients without clinically detectable DR in our control group. Although none of these patients had clinically evident DR, it is possible that very subtle DR went undetected. It is worth acknowledging that many additional questions must be answered before proposing complement as a biomarker in DR, and future study is needed to determine the answers. The most relevant questions are around the correlation of complement in the aqueous with a causative role in DR. Other pertinent questions are whether complement is an essential part in the pathological process of DR and whether complement inhibition can treat DR.

This study brings important advances to the understanding of complement in DR. The conclusion that aqueous complement levels correlate with vitreous complement levels opens the door to easier and more widespread sampling of the intraocular complement environment. Future study should be directed toward understanding whether complement activity plays a causal role in DR. Understanding the relationship between complement activation and DR stage still needs to be determined, which would allow for the possibility that complement inhibition may be useful in managing the disease. In summary, we demonstrated that the correlation of complement levels between aqueous and vitreous and we found evidence of complement dysregulation in the iris and ciliary body of diabetic eyes. Taken together, these findings provide a basis for further study into new classes of diagnostic and therapeutic applications in DR.

Acknowledgment

This study was partially supported by a Challenge Grant to the University of Colorado Department of Ophthalmology from Research to Prevent Blindness, Inc.

Some of the data in this manuscript has been presented at the Annual Meeting of the Association for Research in Vision and Ophthalmology (ARVO) in Vancouver, BC, Canada, May 2, 2019.

Disclosure: **J.M. Smith**, None; **N. Mandava**, None; **V. Tirado-Gonzalez**, None; **R. Garcia-Santisteban**, None; **M.D. Geiger**, None; **J.L. Patnaik**, None; **A. Frazer-Abel**, None; **A.M. Lynch**, None; **N. Mandava**, None; **V.M. Holers**, None; **B.D. Wagner**, None; **I. Sanchez-Santos**, None; **D. Meizner**, None; **H. Quiroz-Mercado**, None; **A.G. Palestine**, None

References

1. Janeway CA, Jr., Medzhitov R. Innate immune recognition. *Annu Rev Immunol.* 2002;20:197–216.
2. Janeway CA, Travers P, Walport M, Capra DJ. *Immunobiology*. Abingdon, UK: Taylor & Francis Group: Garland Science; 2001.
3. Mandava N, Tirado-Gonzalez V, Geiger MD, et al. Complement activation in the vitreous of patients with proliferative diabetic retinopathy. *Invest Ophthalmol Vis Sci.* 2020;61:39.
4. Jha P, Bora PS, Bora NS. The role of complement system in ocular diseases including uveitis and macular degeneration. *Molec Immunol.* 2007;44:3901–3908.
5. Lynch AM, Mandava N, Patnaik JL, et al. Systemic activation of the complement system in patients with advanced age-related macular degeneration. *Eur J Ophthalmol.* 2019;30:1061–1068.
6. Hubens WHG, Beckers HJM, Gorgels T, Webers CAB. Increased ratios of complement factors C3a to C3 in aqueous humor and serum mark glaucoma progression. *Exp Eye Res.* 2021;204:108460.
7. Park DH, Connor KM, Lambris JD. The challenges and promise of complement therapeutics for ocular diseases. *Front Immunol.* 2019;10:1007.
8. Jha P, Sohn JH, Xu Q, et al. The complement system plays a critical role in the development of experimental autoimmune anterior uveitis. *Invest Ophthalmol Vis Sci.* 2006;47:1030–1038.
9. Jha P, Sohn JH, Xu Q, et al. Suppression of complement regulatory proteins (CRPs) exacerbates experimental autoimmune anterior uveitis (EAAU). *J Immunol.* 2006;176:7221–7231.
10. Clark SJ, Bishop PN. The eye as a complement dysregulation hotspot. *Semin Immunopathol.* 2018;40:65–74.
11. Tarr JM, Kaul K, Wolanska K, Kohner EM, Chibber R. Retinopathy in diabetes. *Adv Exp Med Biol.* 2012;771:88–106.
12. Rubsam A, Parikh S, Fort PE. Role of inflammation in diabetic retinopathy. *Int J Mol Sci.* 2018;19:942.
13. Adamis AP, Berman AJ. Immunological mechanisms in the pathogenesis of diabetic retinopathy. *Semin Immunopathol.* 2008;30:65–84.
14. Muramatsu D, Wakabayashi Y, Usui Y, Okunuki Y, Kezuka T, Goto H. Correlation of complement fragment C5a with inflammatory cytokines in the vitreous of patients with proliferative diabetic retinopathy. *Graefes Arch Clin Exp Ophthalmol.* 2013;251:15–17.
15. Manoharan N, Patnaik JL, Olson JL. Increased complement levels in human vitreous aspirates of proliferative diabetic retinopathy and retinal detachment eyes. *Retina.* 2018;39:2212–2218.
16. Zhang J, Gerhardinger C, Lorenzi M. Early complement activation and decreased levels of glycosylphosphatidylinositol-anchored complement inhibitors in human and experimental diabetic retinopathy. *Diabetes.* 2002;51:3499–3504.
17. Flyvbjerg A. The role of the complement system in diabetic nephropathy. *Nat Rev Nephrol.* 2017;13:311–318.
18. Qin X, Goldfine A, Krumrei N, et al. Glycation inactivation of the complement regulatory protein CD59: a possible role in the pathogenesis of the vascular complications of human diabetes. *Diabetes.* 2004;53:2653–2661.
19. Goldmann H, Witmer R. [Antibodies in the aqueous humor]. *Ophthalmologica.* 1954;127:323–330.
20. Algvere P, Kornacki B. Fluorescein angiography of the iris. A correlation of microangiopathy in the iris and retina. *Acta Ophthalmol (Copenh).* 1978;56:803–816.
21. Demeler U, Sautter H. [Iris angiography studies in patients with diabetes mellitus]. *Adv Ophthalmol.* 1978;36:233–244.
22. Moriarty AP, Spalton DJ, Moriarty BJ, Shilling JS, Ffytche TJ, Bulsara M. Studies of the blood-aqueous barrier in diabetes mellitus. *Am J Ophthalmol.* 1994;117:768–771.