

# Intracameral Bacteriophage Injection as Postoperative Prophylaxis for *Enterococcus faecalis*-Induced Endophthalmitis After Cataract Surgery in Rabbits

Tatsuma Kishimoto<sup>1</sup>, Waka Ishida<sup>1</sup>, Isana Nakajima<sup>1</sup>, Takako Ujihara<sup>2</sup>, Takashi Suzuki<sup>3</sup>, Jumpei Uchiyama<sup>4</sup>, Shigenobu Matsuzaki<sup>5</sup>, and Ken Fukuda<sup>1</sup>

<sup>1</sup> Department of Ophthalmology and Visual Science, Kochi Medical School, Kochi University, Kochi, Japan

<sup>2</sup> Science Research Center, Kochi University, Kochi, Japan

<sup>3</sup> Department of Ophthalmology, Toho University, Tokyo, Japan

<sup>4</sup> Department of Bacteriology, Graduate School of Medicine Dentistry and Pharmaceutical Sciences, Okayama University, Okayama, Japan

<sup>5</sup> Department of Medical Laboratory Science, Faculty of Health Sciences, Kochi Gakuen University, Kochi, Japan

**Correspondence:** Ken Fukuda, Department of Ophthalmology and Visual Science, Kochi Medical School, Kochi University, Kochi, Japan. e-mail: [k.fukuda@kochi-u.ac.jp](mailto:k.fukuda@kochi-u.ac.jp)

**Received:** January 28, 2022

**Accepted:** March 14, 2022

**Published:** April 1, 2022

**Keywords:** bacteriophage; endophthalmitis; cataract surgery; enterococcus faecalis; prophylaxis

**Citation:** Kishimoto T, Ishida W, Nakajima I, Ujihara T, Suzuki T, Uchiyama J, Matsuzaki S, Fukuda K. Intracameral bacteriophage injection as postoperative prophylaxis for *Enterococcus faecalis*-Induced endophthalmitis after cataract surgery in rabbits. *Transl Vis Sci Technol.* 2022;11(4):2. <https://doi.org/10.1167/tvst.11.4.2>

**Purpose:** Post-cataract surgery bacterial endophthalmitis is a serious postoperative complication, and *Enterococcus* spp.-induced endophthalmitis reportedly has a particularly poor visual prognosis. This study aimed to demonstrate the prophylactic effect of postoperative intracameral phage administration in *Enterococcus faecalis*-induced endophthalmitis after cataract surgery in rabbits.

**Methods:** Endophthalmitis was induced in rabbits by injecting *E. faecalis* into the anterior chamber just after lensectomy while simultaneously administering either phage phiEF24C-P2 or vehicle. Retinal function was evaluated using electroretinography. The number of viable bacteria and myeloperoxidase (MPO) activity in the eye and histopathologic examinations were analyzed 48 hours after infection.

**Results:** In the vehicle-treated group, retinal function at 24 hours after infection was impaired, and the number of viable bacteria and MPO activity in the eye increased 48 hours later. In the phage-administered group, retinal function was maintained; the number of viable bacteria and MPO activity were significantly suppressed. Histopathologic examinations showed disruption of the retinal layers and the presence of numerous *E. faecalis* in the lens capsule and vitreous cavity in vehicle-treated eyes. In contrast, retinal structures were intact, and no *E. faecalis* staining was observed in phage-treated eyes. No retinal dysfunction was observed in the group that received phage only without lensectomy; almost no phage was detected in the eyes after 14 days of treatment.

**Conclusions:** Phage administration in the anterior chamber did not cause retinal dysfunction and suppressed postoperative endophthalmitis in rabbits.

**Translational Relevance:** In vivo results of intracameral phage administration suggest that phages are a promising prophylactic candidate for postoperative endophthalmitis.

## Introduction

Cataracts are one of the most common eye diseases worldwide. Cataract surgery is reportedly performed in 1.6 million cases per year in Japan and 400,000 cases per year in the United Kingdom.<sup>1</sup> The incidence rate of postoperative endophthalmitis is approximately

0.025% to 0.136% in cataract surgery cases.<sup>2,3</sup> The incidence of postoperative endophthalmitis is low. However, once retinal damage occurs, it often results in permanent vision loss. Antimicrobial agents have been administered to the anterior chamber or by eye drops at the end of cataract surgery for the prophylaxis of postoperative endophthalmitis.<sup>4</sup> Hemorrhagic occlusive retinal vasculitis, however, has been reported

to be a serious side effect of vancomycin injected in the anterior chamber at the end of surgery. Therefore, an effective prophylactic measure must be developed.

The most common pathogenic bacteria for endophthalmitis are gram-positive bacteria, such as enterococci, coagulase-negative staphylococci, and staphylococci.<sup>5</sup> In Asia, enterococci account for a large proportion of endophthalmitis cases,<sup>6,7</sup> and enterococcal endophthalmitis results in poor visual outcomes due to retinal destruction.<sup>8</sup> All gram-positive isolates, including *Enterococcus* spp., were susceptible to vancomycin in the Endophthalmitis Vitrectomy Study in 1996.<sup>5</sup> However, the number of clinical reports of endophthalmitis caused by vancomycin-resistant *Enterococcus* spp. has been increasing in recent years.<sup>9–12</sup> Thus, a prophylactic agent to prevent antimicrobial-sensitive and antimicrobial-resistant enterococcal endophthalmitis is needed.

Bacteriophages (phages) are viruses that infect bacteria, replicate within bacteria, and lyse bacteria with endolysins. Phage therapy is the application of bacteriolytic activity of phages to treat bacterial infectious diseases. The advantages of phage therapy include fast action, effectiveness against antimicrobial-resistant bacteria, and no infection of mammalian cells. We have previously reported the therapeutic effects of phage therapy in a mouse model of ocular bacterial infections, including phage eye drops for *Pseudomonas aeruginosa* keratitis and phage vitreous injection for enterococcal endophthalmitis.<sup>13–15</sup> However, there have been no reports investigating phage therapy as a prophylactic to prevent endophthalmitis.

This study aimed to demonstrate the prophylactic effect of postoperative intracameral phage administration in *Enterococcus faecalis*-induced endophthalmitis after cataract surgery in rabbits.

## Methods

### Bacteria and Phages

*E. faecalis* strain EF24 and phage phiEF24C-P2 were isolated and prepared as previously described.<sup>16,17</sup> A plaque assay was applied to measure phage concentration and expressed in plaque-forming units (PFUs).

### Ethical Treatment of Animals

The study was approved by the Committee for Care and Use of Laboratory Animals at Kochi University (permit number O-54). Rabbits were housed in individually ventilated cages with a 14-hour light/10-hour dark cycle, maintained at  $21 \pm 1^\circ\text{C}$ , with ad libitum feeding.

The sample size was determined to be the minimum number for which statistically significant differences could be assessed. All procedures were performed in accordance with the Association for Research in Vision and Ophthalmology Statement for the Use of Animals in Ophthalmic and Vision Research.

### Rabbit Model of *E. faecalis* Endophthalmitis after Lensectomy

Lensectomy and inoculation of *E. faecalis* in rabbits were performed as previously described.<sup>18</sup> Eight-week-old specific pathogen-free female Japanese white rabbits (Japan SLC, Inc., Hamamatsu, Japan), weighing 1.5 kg, were used for the experiments. Pupil dilation was induced by topical application of 0.5% tropicamide and 0.5% phenylephrine (Nitten Pharmaceutical, Nagoya, Japan). The rabbits were anesthetized with an intramuscular injection of an anesthetic combination of 0.5 mg/kg medetomidine (Domitor; Nippon Zenyaku Kogyo, Tokyo, Japan), 2.0 mg/kg midazolam (Sandoz, Yamagata, Japan), and 0.5 mg/kg butorphanol (Vetorphale; Meiji Seika Pharma, Tokyo, Japan) and topical anesthesia with 0.4% oxybuprocaine hydrochloride (Nitten Pharmaceutical, Nagoya, Japan). A corneal incision was created, and the lens nucleus was emulsified using a phacoemulsification unit (Infinity Vision System; Alcon, Inc., Fort Worth, TX, USA). A rabbit model of endophthalmitis was induced by injecting  $2 \times 10^5$  *E. faecalis* EF24 in 25  $\mu\text{L}$  of physiologic saline into the anterior chamber with a 30-gauge needle in the right eye. After the bacterial injection,  $2 \times 10^9$  PFUs of phage phiEF24C-P2 in 25  $\mu\text{L}$  of physiologic saline or 25  $\mu\text{L}$  of physiologic saline alone was administered into the anterior chamber of the right eye.

### Electroretinography

The electroretinography (ERG) response was measured in rabbits under anesthesia, as described previously.<sup>18</sup> The amplitudes of the scotopic a- and b-waves were recorded in both eyes using a flash ERG.

### Measurement of Viable Bacteria and Phage in the Eye

Eyes were isolated 48 hours postinfection and rinsed with sterile physiologic saline. The aqueous humor was collected using a 30-gauge needle. The cornea was aseptically removed, and the iris and lens were detached. The vitreous body was then collected and disrupted with the homogenizer, Precellys

Evolution (Bertin Instruments, Montigny-le-Bretonneux, France), at 6000 rpm for 30 seconds, repeated three times, to release the bacteria and phage. The aqueous humor and the homogenate of the vitreous body were diluted with saline and plated on EF agar for culture at 37°C for 48 hours. To evaluate phage plaque formation, we used brain heart infusion medium-based agar with a double layer of 1.5% agar in the lower layer and 0.5% agar in the upper layer.

### Measurement of Phage in the Blood

Exactly 10  $\mu\text{L}$  of heparin sodium injection (Mochida Pharmaceutical, Tokyo, Japan) was aspirated into a 2.5-mL syringe with a 26-gauge needle, applied to the inner wall of the syringe, and 500  $\mu\text{L}$  of blood was drawn from a rabbit ear vein. Evaluation of phage plaque formation was the same as that for the eye.

### Assay of Myeloperoxidase Activity

The number of infiltrated neutrophils in the eye was estimated by measuring the myeloperoxidase (MPO) activity, as described previously.<sup>14</sup>

### Histologic Examination

Eyes isolated at 48 hours after infection were fixed with Super Fix (Kurabo, Osaka, Japan) for 2 days. The eyes were embedded in paraffin, cut into 2- $\mu\text{m}$  sections, and stained with hematoxylin and eosin. The sections were photographed using a fluorescence microscope (Biorevo BZ-X800; Keyence, Osaka, Japan).

### Immunofluorescence Staining of *E. faecalis*

Deparaffinized sections were heat treated in citrate buffer (pH 6.0) for 20 minutes and washed three times with phosphate-buffered saline (PBS). Sections were incubated for 1 hour at room temperature with 1% bovine serum albumin/PBS to block nonspecific binding. The sections were then rewashed three times with PBS, incubated overnight with fluorescein isothiocyanate-labeled *Enterococcus* antibody (Thermo Fisher Scientific, Waltham, MA, USA), washed with PBS, mounted in mounting medium containing 4'6-diamidino-2-phenylindole (Vector Laboratories, Inc., Burlingame, CA, USA), and analyzed with a fluorescence microscope (Biorevo BZ-X800; Keyence).

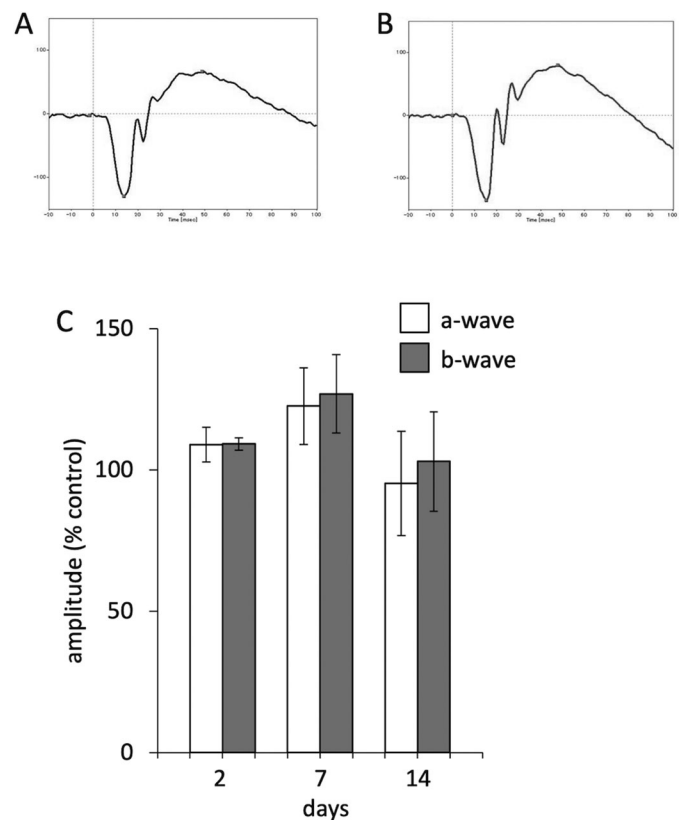
## Statistical Analysis

Statistical analysis was performed using statistical software (Statcel 4 software; OMS Publishing, Inc., Saitama, Japan). Quantitative data are presented as the mean  $\pm$  SEM and were analyzed using the Tukey–Kramer test or Student's unpaired *t*-test. Statistical significance was set at  $P < 0.05$ .

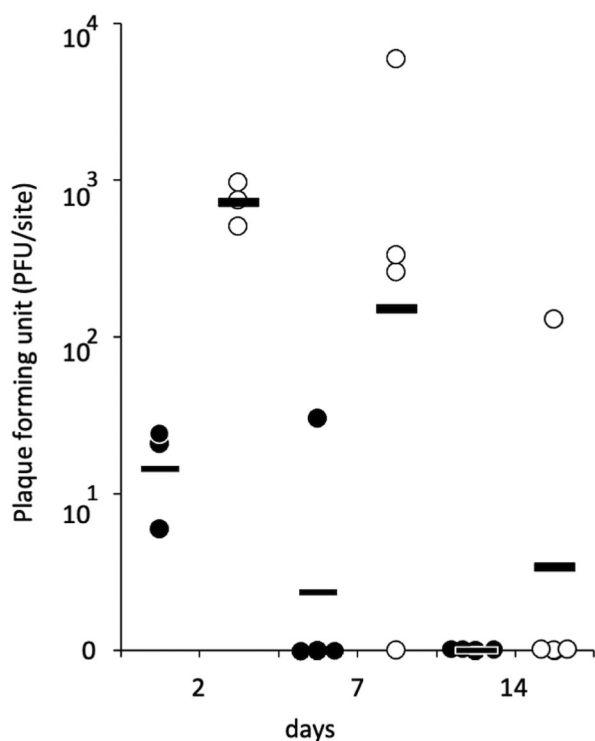
## Results

### Safety of Intracameral Phage Administration and Time of Phage Clearance From Eyes

We first evaluated the retinal safety of intracameral phage administration in rabbits using ERG. There was no difference in the a-wave and b-wave responses of the scotopic ERG at 2, 7, and 14 days after administration between the phage-injected eyes and vehicle-injected eyes, suggesting no retinal toxicity of phage (Fig. 1). Phage pharmacokinetics in the eyes were examined at



**Figure 1.** Retinal function after injection of phage into the anterior chamber. Representative ERG responses for untreated eyes (A) and eyes at 48 hours after injection of phages into the anterior chamber (B). The amplitude of the a-wave and b-wave (C) are expressed as a percentage of control and are means  $\pm$  SEMs for three eyes in each group ( $n = 3$ ).



**Figure 2.** Time of phage clearance in the eye. The persistence of phages in the eye was examined at 2, 7, and 14 days after administration of phiEF24C-P2 into the anterior chamber. The number of phages in the anterior chamber (closed circles) and in the vitreous body (open circles) at the indicated times is shown ( $n = 3$  or 4, respectively). Bars represent the mean of three or four eyes.

2, 7, and 14 days after the administration of phages into the anterior chamber. The number of phages in the anterior chamber decreased in a time-dependent manner, and phages were scarcely detected on day 7. Phages were detected in the anterior chamber and the vitreous body; they were more abundant in the vitreous body than in the anterior chamber at all time points examined. Phages in the vitreous body also gradually decreased and were almost undetectable 14 days after injection (Fig. 2). No phages were detected in the blood on any day (data not shown). MPO activity in the eyes injected with phage was almost undetectable (data not shown). Thus, phage alone did not cause retinal toxicity or intraocular inflammation.

### Effect of Intracameral Phage on *E. faecalis*-induced Postoperative Endophthalmitis in Rabbits

We then examined the effects of intracameral administration of phage in a rabbit model of post-cataract surgery endophthalmitis. *E. faecalis* ( $10^5$  cells) was inoculated into the anterior chamber immediately after cataract surgery in an aphakic rabbit.

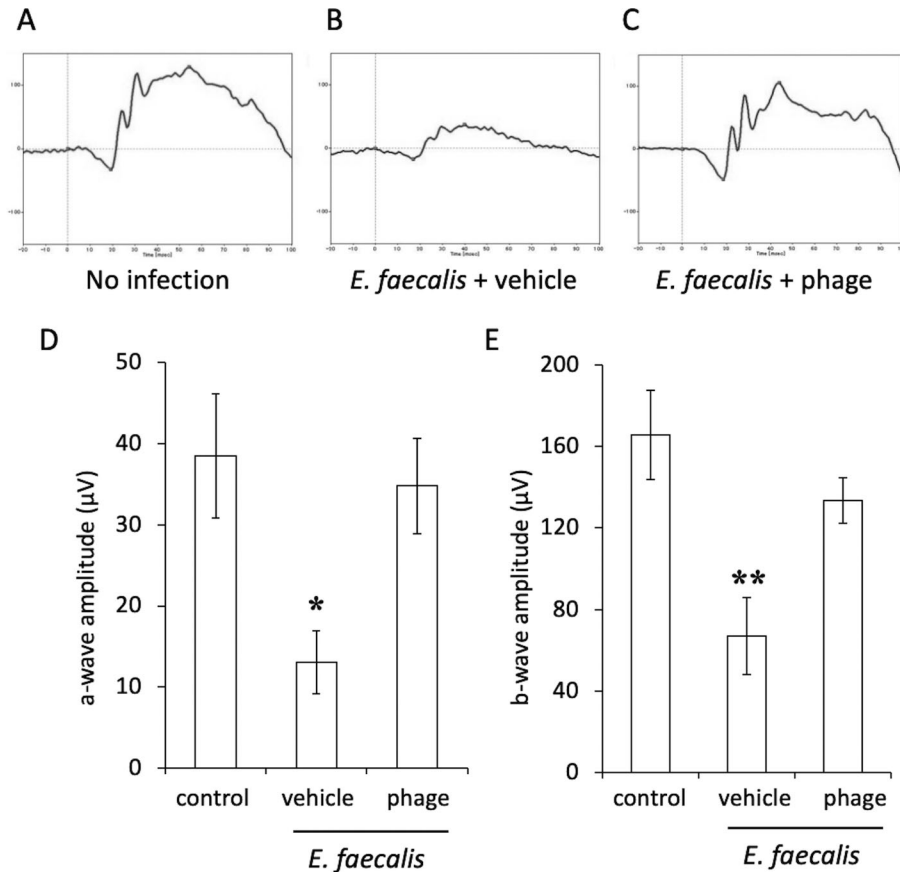
Then, the phage ( $10^9$  PFUs) or vehicle was injected into the anterior chamber after the administration of *E. faecalis*. ERG was performed in rabbits 1 day after surgery. The amplitude of both a- and b-waves was significantly decreased in rabbits with the administration of *E. faecalis* compared with rabbits that received cataract surgery alone (Fig. 3). The amplitudes of the a-wave and b-wave in the phage-treated group did not decrease and were similar to those in the group that received cataract surgery alone.

Histopathologic examinations of infected eyes at 2 days after infection with vehicle treatment showed massive infiltration of inflammatory cells in the lens capsule and vitreous cavity, as well as disruption of retinal layers (Figs. 4A–D). Immunostaining with an anti-*E. faecalis* antibody showed positive staining in the lens capsule and vitreous cavity (Figs. 4E, 4F). In contrast, few inflammatory cells were observed in the lens capsule and vitreous cavity in infected eyes following phage administration (Figs. 4G–I). Retinal structures were also apparently intact (Fig. 4J), and no positive staining was observed for anti-*E. faecalis* antibody in phage-treated eyes (Figs. 4K, 4L). The number of viable bacteria and MPO activity in the eyes were determined 2 days after surgery. The number of viable bacteria (Fig. 5A) and MPO activity (Fig. 5B) were significantly increased in the vehicle-treated group. In contrast, the bacterial load and MPO activity were significantly decreased in the phage-treated group. Therefore, the administration of the phage into the anterior chamber at the end of cataract surgery suppressed the development of endophthalmitis and retinal dysfunction.

## Discussion

We demonstrated in this study that intracameral administration of phages suppressed the development of *E. faecalis*-induced postoperative endophthalmitis in rabbits. To prevent post-cataract surgery bacterial endophthalmitis, eye drops or intracameral administration of antimicrobial agents is universally used. Although the application of perioperative antimicrobial eye drops is widely employed in many countries, its efficacy in the prophylaxis of endophthalmitis remains unclear.<sup>19,20</sup> Some studies have shown no difference in the frequency of post-cataract surgery endophthalmitis with or without topical antibiotics. Intracameral antibiotics have been shown to reduce the rate of postoperative endophthalmitis.<sup>4</sup> However, regardless of the administration method, frequent use of antibiotics can increase the risk of developing



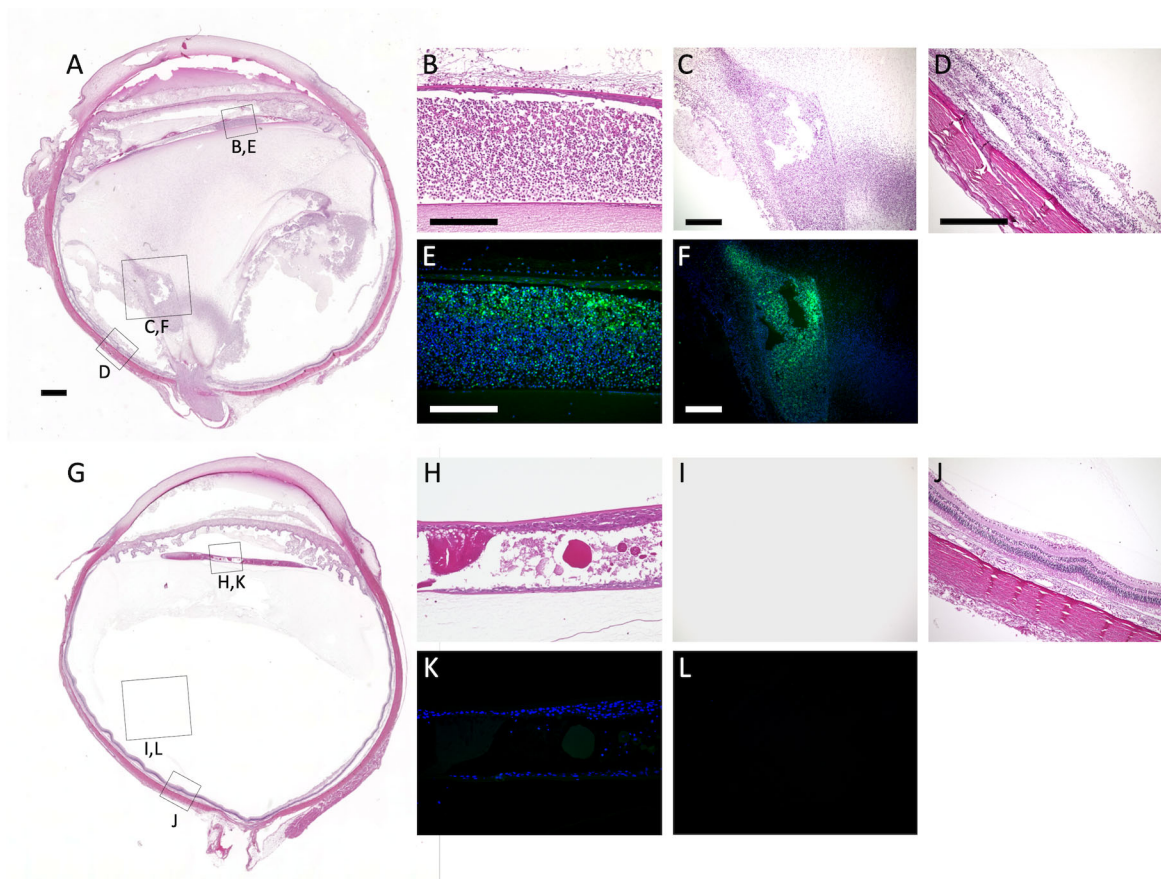


**Figure 3.** Retinal function in eyes with *E. faecalis*-induced postcataract endophthalmitis with or without intracameral phiEF24C-P2. Representative ERG responses for eyes that received cataract surgery alone (A), eyes that underwent cataract surgery and administration of *E. faecalis* (B), and eyes that received cataract surgery and administration of *E. faecalis* treated with phiEF24C-P2 (C). The amplitude of the a-wave (D) and b-wave (E) from ERG recordings is shown as mean  $\pm$  SEM for three eyes in each group ( $n = 3$ ). \* $P < 0.05$ , \*\* $P < 0.01$  (Tukey-Kramer test) versus cataract surgery alone.

drug-resistant bacterial infections. Endophthalmitis caused by drug-resistant bacteria has been increasing in recent years.<sup>9–12</sup> The advantages of using phages for prophylaxis of postoperative endophthalmitis are that they are effective for antibiotic-resistant bacteria and remain longer in the eye than antimicrobial agents. One of the characteristics of phages is their ability to infect specific bacterial strains. Thus, identifying a causative bacterial pathogen is important for the successful treatment or prevention of endophthalmitis. However, endophthalmitis progresses rapidly, resulting in irreversible retinal damage within a few days, and the pathogen is often not identified in cultures from the aqueous humor and vitreous body.<sup>5</sup> In most cases of postoperative endophthalmitis caused by gram-positive bacteria, a cocktail of several phages against various gram-positive bacteria, rather than only enterococci, may be effective when used as prophylaxis against endophthalmitis.

Mixing different phages as a cocktail broadens the antimicrobial spectrum and prevents the development of phage-resistant bacteria.<sup>21,22</sup> Phages that are also effective against drug-resistant bacteria may be a last resort against postoperative endophthalmitis caused by drug-resistant bacteria, which has been increasing in recent years. They may also be effective in postoperative prophylaxis for vancomycin-resistant *E. faecalis*-induced endophthalmitis.

Since the aqueous humor is replaced in approximately 100 minutes, the half-life of antimicrobial agents administered into the anterior chamber may be calculated at 50 minutes.<sup>23</sup> The half-life of intravitreally injected vancomycin in rabbits was 8.9 hours in aphakic eyes.<sup>24</sup> Effective vancomycin concentration in patients with postoperative endophthalmitis treated with intravitreally administered vancomycin reportedly lasts for 3 days.<sup>25</sup> In this study, phages were still detected in the aqueous humor on the second

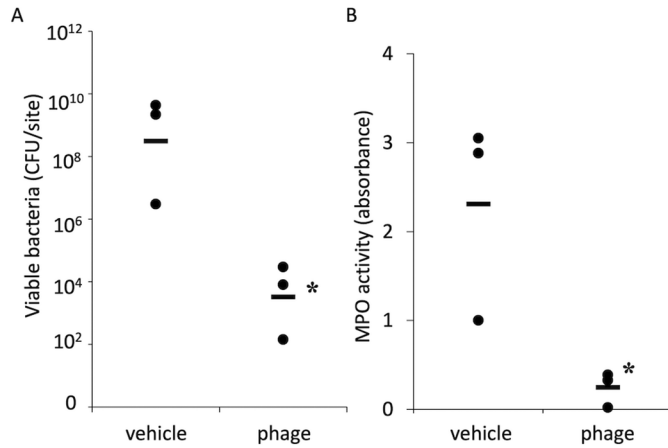


**Figure 4.** Histopathology of *Enterococcus faecalis* EF24-induced postcataract endophthalmitis in eyes in the absence or presence of intracameral phiEF24C-P2. Eyes were excised at 48 hours after infection with *E. faecalis* EF24 and subsequent intracameral administration of vehicle (**A–F**) and phiEF24C-P2 (**G–L**) for histologic analysis. Paraffin sections were stained with hematoxylin and eosin (**A–D**, **G–J**) or anti-*E. faecalis* antibody (green fluorescein) in vehicle-treated eyes (**E**, **F**) and phage-treated eyes (**K**, **L**). Blue fluorescein shows the cell nucleus. Scale bars: 1 mm (**A**) and 200  $\mu$ m (**B–F**).

day after administration into the anterior chamber. They were almost undetectable on the seventh day, but many phages that migrated into the vitreous body were detected until the seventh day. Most postoperative endophthalmitis cases occur within 3 days after cataract surgery.<sup>26</sup> The phages remain in the eye for several days after injection in the anterior chamber; thus, it is considered more effective in preventing the development of endophthalmitis than prophylactic treatment with antimicrobial agents. In this study, phages were not detected in the blood after the intravitreal administration of phages. Systemic administration of a phage by intravenous or oral administration may induce the migration of the phage to various organs throughout the body.<sup>27</sup> For endophthalmitis treatment, topical injection of the phage into the anterior chamber or vitreous cavity is preferable to minimize systemic migration of the phage, as in this study. It remains unclear where the phage administered in the anterior chamber is discharged to outside the eye, except that it is transferred to the vitreous body.

Endolysin produced by phages can be used as an antimicrobial agent, and its prophylactic and therapeutic capacities may be worth investigating.<sup>28–30</sup> In the future, it will be necessary to compare and clarify the antimicrobial effect and duration in the eye when the phage itself or endolysin is administered into the anterior chamber and whether problems occur such as antibody production and resistance to the phage. The combined use of bacteriophages and antimicrobial agents reportedly has a synergistic or additive effect on bacteriolysis, and the concentration of each can be reduced.<sup>31,32</sup> As a prophylactic or therapeutic agent for endophthalmitis, the combined use of phages and antibacterial agents may provide stronger antibacterial effects, and further studies are needed.

Limitations of this study include the lack of an examination of the efficacy of prophylaxis with a different phage and the lack of evaluation of the minimum effective concentration of phage for anterior chamber administration. Furthermore, future studies need to investigate the efficacy of prophylactic phage



**Figure 5.** Viable bacterial load and MPO activity for eyes with *E. faecalis* EF24-induced postcataract endophthalmitis with or without intracameral phiEF24C-P2. Viable bacterial load (A) and MPO activity (B) were measured in eyes excised 48 hours after infection with *E. faecalis* EF24 in the absence or presence of intracameral phiEF24C-P2. All data are presented as the mean  $\pm$  SEM for three eyes in each group ( $n = 3$ ). \* $P < 0.05$ , Student's unpaired *t*-test versus vehicle-treated eyes.

administration against endophthalmitis caused by drug-resistant bacteria.

In conclusion, we demonstrated the prophylactic effect of postoperative intracameral administration of phages in *E. faecalis*-induced endophthalmitis after cataract surgery in rabbits. Thus, the intracameral administration of phages may be a promising prophylactic candidate for postoperative endophthalmitis.

## Acknowledgments

Supported by The Eye Research Foundation for the Aged.

Disclosure: **T. Kishimoto**, None; **W. Ishida**, None; **I. Nakajima**, None; **T. Ujihara**, None; **T. Suzuki**, None; **J. Uchiyama**, None; **S. Matsuzaki**, None; **K. Fukuda**, None

## References

1. Charlesworth E, Alderson AJ, de Juan V, Elliott DB. When is refraction stable following routine cataract surgery? A systematic review and meta-analysis. *Ophthalmic Physiol Opt*. 2020;40(5):531–539.
2. Inoue T, Uno T, Usui N, et al. Incidence of endophthalmitis and the perioperative practices

of cataract surgery in Japan: Japanese Prospective Multicenter Study for Postoperative Endophthalmitis after Cataract Surgery. *Jpn J Ophthalmol*. 2018;62(1):24–30.

3. Zafar S, Dun C, Srikumaran D, et al. Endophthalmitis rates among medicare beneficiaries undergoing cataract surgery between 2011 and 2019. *Ophthalmology*. 2022;129(3):250–257.
4. Barry P. Adoption of intracameral antibiotic prophylaxis of endophthalmitis following cataract surgery: update on the ESCRS Endophthalmitis Study. *J Cataract Refract Surg*. 2014;40(1):138–142.
5. Han DP, Wisniewski SR, Wilson LA, et al. Spectrum and susceptibilities of microbiologic isolates in the Endophthalmitis Vitrectomy Study. *Am J Ophthalmol*. 1996;122(1):1–17.
6. Won JY, Kim M. Vancomycin-resistant *Staphylococcus hominis* endophthalmitis following cataract surgery. *Clin Ophthalmol*. 2013;7:1193–1195.
7. Suzuki T, Todokoro D, Kobayakawa S, et al. Postcataract endophthalmitis caused by *Enterococcus faecalis*. *Nippon Ganka Gakkai Zasshi*. 2014;118(1):22–27.
8. Todokoro D, Suzuki T, Kobayakawa S, Tomita H, Ohashi Y, Akiyama H. Postoperative *Enterococcus faecalis* endophthalmitis: virulence factors leading to poor visual outcome. *Jpn J Ophthalmol*. 2017;61(5):408–414.
9. Sharma S, Desai RU, Pass AB, Saffra NA. Vancomycin-resistant *enterococcal* endophthalmitis. *Arch Ophthalmol*. 2010;128(6):794–795.
10. Hillier RJ, Arjmand P, Rebick G, Ostrowski M, Muni RH. Post-traumatic vancomycin-resistant enterococcal endophthalmitis. *J Ophthalmic Inflamm Infect*. 2013;3(1):42.
11. Nguyen J, Hartnett ME. Successful management of post-traumatic vancomycin-resistant *enterococcus* endophthalmitis. *Am J Ophthalmol Case Rep*. 2017;5:117–118.
12. Babalola OE. Intravitreal linezolid in the management of vancomycin-resistant enterococcal endophthalmitis. *Am J Ophthalmol Case Rep*. 2020;20:100974.
13. Fukuda K, Ishida W, Uchiyama J, et al. *Pseudomonas aeruginosa* keratitis in mice: effects of topical bacteriophage KPP12 administration. *PLoS One*. 2012;7(10):e47742.
14. Kishimoto T, Ishida W, Fukuda K, et al. Therapeutic effects of intravitreously administered bacteriophage in a mouse model of endophthalmitis caused by vancomycin-sensitive or -resistant

- Enterococcus faecalis*. *Antimicrob Agents Chemother*. 2019;63(11):e01088–e01119.
15. Kishimoto T, Ishida W, Nasukawa T, et al. In vitro and in vivo evaluation of three newly isolated bacteriophage candidates, phiEF7H, phiEF14H1, phiEF19G, for treatment of *Enterococcus faecalis* endophthalmitis. *Microorganisms*. 2021;9(2):212.
  16. Uchiyama J, Rashel M, Maeda Y, et al. Isolation and characterization of a novel *Enterococcus faecalis* bacteriophage phiEF24C as a therapeutic candidate. *FEMS Microbiol Lett*. 2008;278(2):200–206.
  17. Uchiyama J, Takemura I, Satoh M, et al. Improved adsorption of an *Enterococcus faecalis* bacteriophage phiEF24C with a spontaneous point mutation. *PLoS One*. 2011;6(10):e26648.
  18. Suzuki T, Wada T, Kozai S, Ike Y, Gilmore MS, Ohashi Y. Contribution of secreted proteases to the pathogenesis of postoperative *Enterococcus faecalis* endophthalmitis. *J Cataract Refract Surg*. 2008;34(10):1776–1784.
  19. Friling E, Lundström M, Stenevi U, Montan P. Six-year incidence of endophthalmitis after cataract surgery: Swedish national study. *J Cataract Refract Surg*. 2013;39(1):15–21.
  20. Råen M, Sandvik GF, Drolsum L. Endophthalmitis following cataract surgery: the role of prophylactic postoperative chloramphenicol eye drops. *Acta Ophthalmol*. 2013;91(2):118–122.
  21. Goodridge LD. Designing phage therapeutics. *Curr Pharm Biotechnol*. 2010;11(1):15–27.
  22. Merabishvili M, Pirnay JP, Verbeken G, et al. Quality-controlled small-scale production of a well-defined bacteriophage cocktail for use in human clinical trials. *PLoS One*. 2009;4(3):e4944.
  23. Lehmann OJ, Thompson JP, White LO, Keys MF, Campbell MJ. Half-life of intracameral gentamicin after phacoemulsification. *J Cataract Refract Surg*. 1997;23(6):883–888.
  24. Aguilar HE, Meredith TA, el-Massry A, et al. Vancomycin levels after intravitreal injection: effects of inflammation and surgery. *Retina*. 1995;15(5):428–432.
  25. Ferencz JR, Assia EI, Diamantstein L, Rubinstein E. Vancomycin concentration in the vitreous after intravenous and intravitreal administration for postoperative endophthalmitis. *Arch Ophthalmol*. 1999;117(8):1023–1027.
  26. Chen Y, Zhang Y, Li X, Yan H. Incidence of acute-onset endophthalmitis after separate bilateral cataract surgeries less than 5 days apart. *BMC Ophthalmol*. 2019;19(1):32.
  27. Dąbrowska K. Phage therapy: What factors shape phage pharmacokinetics and bioavailability? Systematic and critical review. *Med Res Rev*. 2019;39(5):2000–2025.
  28. Imanishi I, Uchiyama J, Tsukui T, et al. Therapeutic potential of an endolysin derived from kayvirus S25-3 for staphylococcal impetigo. *Viruses*. 2019;11(9):769.
  29. Rashel M, Uchiyama J, Ujihara T, et al. Efficient elimination of multidrug-resistant *Staphylococcus aureus* by cloned lysin derived from bacteriophage phi MR11. *J Infect Dis*. 2007;196(8):1237–1247.
  30. Uchiyama J, Takemura I, Hayashi I, et al. Characterization of lytic enzyme open reading frame 9 (ORF9) derived from *Enterococcus faecalis* bacteriophage phiEF24C. *Appl Environ Microbiol*. 2011;77(2):580–585.
  31. Li X, He Y, Wang Z, et al. A combination therapy of phages and antibiotics: two is better than one. *Int J Biol Sci*. 2021;17(13):3573–3582.
  32. Tagliaferri TL, Jansen M, Horz HP. Fighting pathogenic bacteria on two fronts: phages and antibiotics as combined strategy. *Front Cell Infect Microbiol*. 2019;9:22.