

Relationship Between Renal Function and Choroidal Thickness in Type 2 Diabetic Patients Detected by Swept-Source Optical Coherence Tomography

Sen Liu^{1,2}, Wei Wang¹, Yan Tan², Miao He³, Lanhua Wang¹, Yuting Li¹, and Wenyong Huang²

¹ Zhongshan Ophthalmic Center, State Key Laboratory of Ophthalmology, Sun Yat-Sen University, Guangzhou, People's Republic of China

² School of Medicine, Sun Yat-sen University, Guangzhou, China

³ Department of Ophthalmology, Guangdong General Hospital, Guangdong Academy of Medical Sciences, Guangzhou, People's Republic of China

Correspondence: Wenyong Huang, Zhongshan Ophthalmic Center, State Key Laboratory of Ophthalmology, Sun Yat-sen University, 54 S. Xianlie Road, Guangzhou 510060, China. e-mail: andyhwyz@aliyun.com
Wei Wang, Zhongshan Ophthalmic Center, State Key Laboratory of Ophthalmology, Sun Yat-sen University, 54 S. Xianlie Road, Guangzhou 510060, China. e-mail: zoc_wangwei@yahoo.com

Received: October 22, 2019

Accepted: February 14, 2020

Published: April 24, 2020

Keywords: diabetes mellitus; swept source optical coherence tomography; choroidal thickness; renal function

Citation: Liu S, Wang W, Tan Y, He M, Wang L, Li Y, Huang W. Relationship between renal function and choroidal thickness in type 2 diabetic patients detected by swept-source optical coherence tomography. *Trans Vis Sci Tech.* 2020;9(5):17, <https://doi.org/10.1167/tvst.9.5.17>

Purpose: To investigate the relationship between renal function and choroidal thickness (CT) in ocular treatment-naïve patients with diabetes mellitus using swept-source optical coherence tomography (SS-OCT).

Methods: This cross-sectional study recruited type 2 diabetes mellitus (T2DM) patients with no history of ocular treatment from communities in Guangzhou, China. The estimated glomerular filtration rates (eGFR) were calculated by using the Xiangya formula. The impaired renal function was defined as eGFR < 60 mL/(min 1.73 m²). The choroid was imaged by using an SS-OCT, and the macular CT was quantified automatically in Early Treatment Diabetic Retinopathy Study maps, and only data from one eye was used. Univariate and multivariate linear regression analyses were performed to explore the influence of eGFR on CT.

Results: A total of 1395 patients with T2DM were included in the final analysis. The CT of all macular regions were significantly thinner in patients with renal impairment (all $P < 0.001$). A significantly positive correlation was observed between the average CT and eGFR ($\beta = 0.4$; 95% confidence interval, 0.041–0.8; $P = 0.029$) independent of age, sex, and other potential confounding factors. After adjusting for other factors, a higher eGFR was also associated with higher CT values in the central field ($P = 0.019$) and in the outer superior ($P = 0.047$), inner superior ($P = 0.018$), inner inferior ($P = 0.025$), and inner temporal ($P = 0.038$) regions.

Conclusions: CT decreased in parallel with renal impairment in ocular treatment naïve diabetic patients, providing an accessible window for monitoring renal status.

Translational Relevance: Knowledge of association between retinal microvasculature and renal microcirculation would allow applying in both clinical and research settings.

Introduction

Diabetes mellitus (DM) is a serious disease threatening human health. One in 11 adults worldwide has DM, and in 2015, it was reported that there were 415 million DM patients ages 20 to 79 in the worldwide popula-

tion, and that number is expected to reach 642 million by 2040.¹ Diabetic retinopathy (DR) and diabetic nephropathy (DN) are major diabetic microvascular complications that share a similar pathological alteration of changing the structure of microcirculation.^{2,3} In addition, in DN, a decrease of retinal blood flow has been reported.⁴ These similar effects indicate that

the alterations of renal function and associated retinal structure may share common features of pathogenesis, including glucose metabolism disorder, inflammatory reactions, and endothelial dysfunction.⁵

The choroid is a highly vascularized structure localized between the lamina fusca of the sclera and the retinal pigment epithelium (RPE). The main physiological function of the choroid is to provide oxygen and nutrients to the highly metabolized outer layer of the retina. The choroid is involved in many retinal diseases, including DR, and some studies have indicated that the morphological changes of the choroid may be a local manifestation of general vascular injury.⁶

Enhanced depth imaging (EDI) spectral-domain (SD) optical coherence tomography (OCT) provides an approach to obtaining cross-sectional images of the choroid in vivo and also to measure choroidal thickness (CT). This technology has expanded the understanding of the choroid in recent years. A large number of studies regarding measuring CT with SD-OCT have been performed, but the association of CT and renal function remains controversial.⁷⁻¹¹ Data from some studies show a thickening choroid in patients with renal injury, whereas other studies have found no difference or even a decrease of CT.⁷⁻¹²

Similarly, although the estimated glomerular filtration rate (eGFR) can act as a good biomarker to measure renal function, a correlation of CT and eGFR is also unclear. These controversial conclusions may be attributed to the following reasons. First, the EDI SD-OCT has limitations, such as unclear bounds of choroid images, bias from the manual measurement, and single point measurement. Second, the confounding factors have not been comprehensively adjusted for. The majority of these studies did not account for factors such as hemoglobin A1c (HbA1c), duration of DM, and axial length (AL), which could all affect CT.¹³⁻¹⁷ Third, the inclusion of patients with and without a history of ocular treatment may introduce selection bias because treatments such as retinal laser photocoagulation and antivascular endothelial growth factor treatment strongly affect CT.¹⁸⁻²⁰

The novel swept-source OCT (SS-OCT), introduced in recent years, provides advantages compared with the SD-OCT. The use of a longer laser wavelength (1050 nm) in SS-OCT helps to minimize dispersion caused by the RPE, which provides a clear boundary of the choroid.²¹ Moreover, SS-OCT measures CT in the whole macular region automatically, which presents a more representative structure of CT. However, few studies have evaluated renal function and CT using SS-OCT.⁷ Therefore, the objective of this study was to investigate the relationship between renal function and CT in ocular treatment-naïve diabetic

patients recruited from diabetic communities in China.

Methods

Participants

This cross-sectional study was performed at the Zhongshan Ophthalmic Centre, Sun Yat-sen University, China. The study was approved by the Institute's Ethics Committee, and performed according to the discipline of the tenets of the Helsinki Declaration. All participants signed a written informed consent before entering the study.

Participants were recruited from a community in the Yuexiu district, Guangzhou, China. Subjects meeting the following inclusion criteria were recruited: (1) patients with type 2 DM aged 30 to 80 years, (2) ocular treatment-naïve, (3) visual acuity of 0.1 or more and able to complete an eye examination, and (4) a spherical equivalent (SE) of -12 diopters (D) or less, astigmatism of 4D or less and AL of 30 mm or less. The SE was calculated as spherical degree plus half of cylinder degree ($SE = \text{spherical degree} + \text{cylinder degree} \times 1/2$). The participants were excluded if any of the following conditions were true: (1) any history of serious systemic diseases such as uncontrolled hypertension, serious cardiovascular or cerebrovascular diseases (ischemic heart disease, stroke), malignant tumors or nephritis; (2) any history of surgery, such as coronary artery bypass grafting, thrombolysis therapy, or kidney transplantation; (3) the presence of cognitive impairment, mental illness, or being unable to complete questionnaires and examinations; (4) any ocular diseases other than DR, such as glaucoma, vitreous-macular diseases (vitreous hemorrhage and retinal detachment), and amblyopia; (5) any history of ocular surgical interventions, such as a history of retina laser treatments or intraocular injections, glaucoma surgery, cataract surgery, or laser myopia surgery; and (6) abnormal refractive media (moderate to severe cataract, corneal ulcer, pterygium, corneal turbidity), poor fixation, and other characteristics that result in a poor quality of the fundus or OCT images.

Systemic and Laboratory Parameters

Standardized questionnaires were used to obtain the general information regarding age, sex, duration of diabetes, medication compliance, other systemic chronic diseases, and lifestyle data. Height, weight, systolic blood pressure and diastolic blood pressure were measured by a nurse, and all patients had blood

and urine samples taken. The following indices were determined using standard tests: serum creatinine, HbA1c, total cholesterol (TC), high-density lipoprotein cholesterol, low-density lipoprotein cholesterol, triglycerides (TG), and microalbuminuria. Because there is limited accuracy with traditional eGFR equations applied to Asian populations, the eGFR was calculated using the Xiangya formula in our study, which is more suitable for the Chinese population.²² Participants were divided into three groups according to their eGFR: a no chronic kidney disease (CKD) group for patients with an eGFR of 90 mL/min/1.73 m² or more; a mild CKD group for patients with an eGFR of 60 mL/min/1.73 m² to 89 mL/min/1.73 m²; and a moderate to severe CKD (MS-CKD) group for patients with an eGFR of 30 mL/min/1.73 m² to 59 mL/min/1.73 m². For comparisons between MS-CKD and non-CKD/mild CKD, patients with an eGFR lower than 60 mL/min/1.73 m² were defined as have impaired renal function.

Ocular Examination

Comprehensive ocular examinations were conducted for all participants. The anterior and posterior segments were evaluated by slit-lamp biomicroscopy and ophthalmoscopy. The evaluations of best corrected visual acuity and intraocular pressure were performed regularly using an EDTRS E chart and noncontact tonometer. The ocular biometric parameters were measured by using optical low-coherence reflectometry (LENSTAR LS900; Haag-Streit AG, Koeniz, Switzerland). Auto refractions were measured with an autorefractor (KR-8800; Topcon, Tokyo, Japan) after bilateral pupil dilation. Retinal photography was performed using a digital fundus camera, and the standard seven-field retinal images were obtained according to the Early Treatment Diabetic Retinopathy Study (ETDRS) criteria.

The SS-OCT (DRI OCT-2 Triton; Topcon, Tokyo, Japan) instrument was used to obtain high-definition images of the retina and choroid. This device has the speed of 100,000 A-scans/s and yields an 8 μm axial resolution in tissue. Three-dimensional imaging scans were obtained using a 6 × 6 mm raster scan protocol centered on the macula. The resultant images were analyzed by the automated layer segmentation software (version 9.12.003.04) built into the SS-OCT system. Several studies have reported the excellent performance of SS-OCT and segmentation software.^{23–25} The CTs in the nine subfields defined by the ETDRS were automatically calculated and displayed, where the grid divided the macular into two rings, inner and outer, at 1 to 3 mm and 3 to 6 mm,

respectively. The individual grids are referred to as the center field and the inner superior, inner nasal, inner inferior, inner temporal, outer superior, outer nasal, outer inferior, and outer temporal regions (Figure 1). In addition, the average CT of all nine grids were calculated. All OCT scans were performed by the same experienced technician who was blind to the study protocol. Before the scan was conducted, it was verified that none of the patients had consumed drinks with caffeine or had taken analgesic medications or alcohol for at least 24 hours before the procedure. Only subjects with eligible images (i.e., image quality > 50, without eye movement, without artefacts, and without segmentation failure) for both eyes were included in the study.

DR and DME status of the participants were classified according to the United Kingdom NHS Diabetic Eye Screening Programme guidelines.^{26, 27} DR was graded as four stages, R0 to R3. R0 represents for no DR. R1 represents for the background stage of DR, with at least one of the following features: microaneurysm (s); retinal hemorrhage(s); venous loop; any exudate in the presence of other features of DR; any number of cotton wool spots in the presence of other features of DR. R2 represents for the pre-proliferative stage of DR, with at least one of the following features: venous beading, venous reduplication, multiple blot hemorrhages, or intraretinal microvascular abnormality. R3 represents for the proliferative stage of DR, which is active proliferative retinopathy with at least one of these features: new vessels on the disc, new vessels elsewhere, preretinal or vitreous hemorrhage, or preretinal fibrosis with or without retinal traction. This study did not included patients with history of retinal laser treatment. DME was graded as M0 and M1. Patients with at least one of the following features: exudate within 1 disc diameter of the center of the fovea, or a collection of exudates within the macula were considered to have DME (i.e., M1 stage). Absence of any M1 features represents the stage of M0.

Statistical Analyses

The Kolmogorov-Smirnov test was carried out to verify normal distribution. When normality was confirmed, the *t*-test was conducted to evaluate intra-group differences in demographics and in systemic and ocular parameters. Fisher's exact test was used for categorical variables. Bivariate scatter plots were used to display the potential factors affecting CT. Linear regression analysis was performed to assess the association of CT with demographic or ocular parameters, such as age, sex, AL, HbA1c, and so on. The univariate analyses showed that the predictive variables were significant, and they were then entered into the

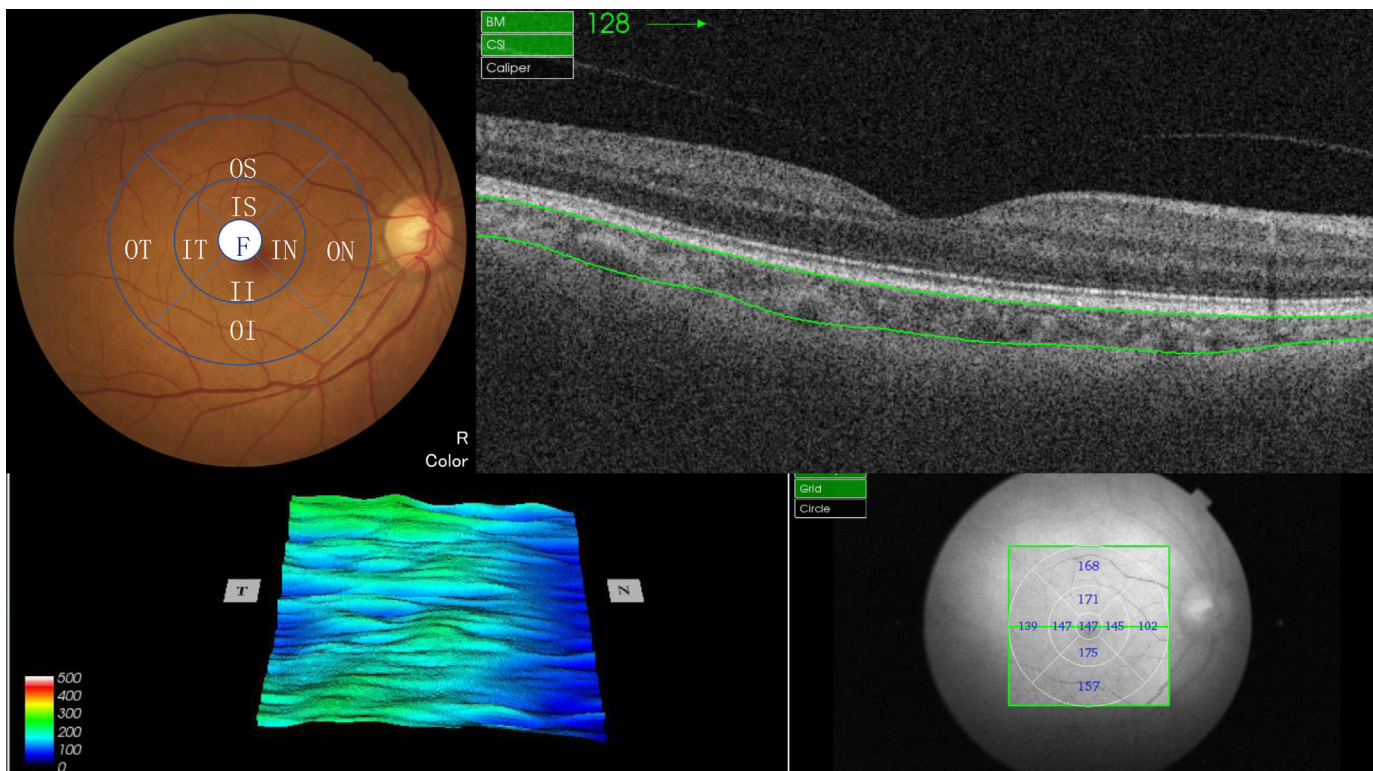


Figure 1. The swept source optical coherence tomography (SS-OCT) provides the measurements of choroidal thickness (CT) by automatically segmentation in 9 ETDRS grids. ETDRS, Early Treatment Diabetic Retinopathy Study; II, inner inferior; IN, inner nasal; IS, inner superior; IT, inner temporal; OI, outer inferior; ON, outer nasal; OS, outer superior; OT, outer temporal.

final multivariate equation. A P value of < 0.05 was considered statistically significant. All analyses were performed using Stata, version 14.0 (Stata Corporation, College Station, TX).

Results

Demographic and Clinical Features

A total of 1395 patients were included in the final statistical analysis. The basic demographic and clinical features are shown in [Table 1](#). Among the participants, 764 (58.37%) patients were female, the average age was 64.4 ± 7.8 years, the average duration of DM was 8.9 ± 7.0 years, and 1050 (80.21%) patients did not have DR. The severity of DR or presence of DME were not correlated with renal function ($P = 0.982$ and 0.688 , respectively). Of the 1256 patients without renal impairment, 733 (58.36%) were female, the average age was 64.2 ± 7.8 years. Of the 53 patients with impaired renal function, 31 (58.49%) were female and the average age was 71.0 ± 5.4 years. Demographically, participants with renal impairment were older,

had a longer duration of diabetes and had a higher BMI (all $P < 0.05$) compared to those without renal impairment, whereas sex, HbA1c, and blood pressure had no statistically significant differences (all $P > 0.05$) in the two groups. In terms of laboratory tests and ocular parameters, participants with renal impairment had higher serum creatinine levels, lower high-density lipoprotein cholesterol levels, higher serum uric acid levels, higher microalbuminuria, a higher best corrected visual acuity, and a lower intraocular pressure (all $P < 0.05$). There were no differences in TC, low-density lipoprotein cholesterol, TG, C-reactive protein, central corneal thickness, and AL between the groups (all $P > 0.05$).

CT and Renal Impairment

[Table 2](#) shows the CTs of different regions and the average values in the two groups. In patients with renal impairment, the average CT was $141.8 \pm 57.2 \mu\text{m}$, the thickest region of CT was inner temporal ($159.2 \pm 61.4 \mu\text{m}$), and the thinner one was outer nasal ($107.5 \pm 60.7 \mu\text{m}$). For patients without renal impairment, the average CT was $188.9 \pm 74.1 \mu\text{m}$, the

Table 1. Demographic and Clinical Characteristics of Study Participants

Characteristics	Overall	eGFR ≥ 60 mL/min/1.73 m ²	eGFR < 60 mL/min/1.73 m ²	P Value
No. of subjects	1395	1256	53	-
Female, %	764 (58.37%)	733 (58.36%)	31 (58.49%)	0.985
Mean age, year	64.4 \pm 7.8	64.2 \pm 7.8	71.0 \pm 5.4	<0.001
Duration of diabetes, year	8.9 \pm 7.0	8.8 \pm 7.0	12.3 \pm 8.3	<0.001
HbA1c, %	6.9 \pm 1.4	6.9 \pm 1.4	6.8 \pm 1.5	0.671
Body mass index, kg/m ²	24.7 \pm 3.3	24.6 \pm 3.3	25.5 \pm 3.3	0.031
Systolic blood pressure, mm Hg	134.8 \pm 18.8	134.6 \pm 18.9	136.8 \pm 19.6	0.416
Diastolic blood pressure, mm Hg	70.6 \pm 10.5	70.6 \pm 10.5	70.1 \pm 10.5	0.723
Total cholesterol, mmol/L	4.8 \pm 1.0	4.8 \pm 1.0	5.0 \pm 1.2	0.220
Serum creatinine, μ mol/L	71.2 \pm 19.9	69.1 \pm 17.0	120.4 \pm 23.6	<0.001
High-density lipoprotein cholesterol, mmol/L	1.3 \pm 0.4	1.3 \pm 0.4	1.2 \pm 0.4	0.027
Low-density lipoprotein cholesterol, mmol/L	3.1 \pm 0.9	3.1 \pm 0.9	3.2 \pm 1.1	0.534
Triglycerides, mmol/L	2.3 \pm 1.7	2.3 \pm 1.6	2.7 \pm 1.9	0.078
Serum uric acid, μ mol/L	367.2 \pm 97.9	362.7 \pm 97.2	438.5 \pm 92.8	<0.001
C-reactive protein, mg/L	2.7 \pm 6.8	2.6 \pm 7.0	4.4 \pm 7.2	0.066
Microalbuminuria, mg/mL	5.1 \pm 16.5	4.7 \pm 15.5	18.5 \pm 33.4	<0.001
BCVA, logMAR	0.2 \pm 0.1	0.2 \pm 0.1	0.3 \pm 0.1	0.032
Intraocular pressure, mmHg	16.2 \pm 2.8	16.2 \pm 2.8	15.4 \pm 3.1	0.039
Central corneal thickness, μ m	546.8 \pm 31.4	546.6 \pm 31.4	540.5 \pm 30.7	0.165
Axial length, mm	23.5 \pm 1.1	23.5 \pm 1.1	23.7 \pm 1.0	0.352
Diabetic retinopathy, %				0.857
Non-DR	1050 (80.21%)	1008 (80.25%)	42 (79.25%)	
Any DR	259 (19.79%)	248 (19.75%)	11 (20.75%)	
Severity of diabetic retinopathy, %				0.982
R0	1122 (80.43%)	1080 (96.26%)	42 (3.74%)	
R1	213 (15.27%)	204 (95.77%)	9 (4.23%)	
R2	33 (2.37%)	32 (96.97%)	1 (3.03%)	
R3	27 (1.94%)	26 (96.30%)	1 (3.70%)	
Presence of diabetic macular edema, %				0.688
M0	1326 (95.05%)	1275 (96.15%)	51 (3.85%)	
M1	69 (4.95%)	67 (97.10%)	2 (2.90%)	

Data are expressed as the mean \pm standard deviation or %. Bold indicates statistical significance.

BCVA, best corrected visual acuity; eGFR, estimated glomerular filtration rate.

thickest region was the central field ($206.6 \pm 83.9 \mu\text{m}$) and, similarly, the thinnest region was the outer nasal ($155.9 \pm 82.2 \mu\text{m}$). The average CT and CT values in each grid were all significantly lower in patients with renal impairment than in patients without renal impairment (all, $P < 0.001$). However, because of the large standard deviations of mean CTs, there is a large amount of overlap between the two groups. [Figure 2](#) shows the distribution of CT stratified by CKD status. The more serious the CKD, the thinner the CT (all $P < 0.05$), whether or not DR was present.

[Table 3](#) shows the differences in CT between patients with and without renal impairment after adjusting for other factors. The CT values were significantly lower in patients with impaired renal function after adjusting for age and sex. Further adjustment with disease duration of DM, systolic blood pressure, body mass index, serum triglycerides, total cholesterol, HbA1c, use of insulin, AL, and diabetic retinopathy status showed that the CT in all grids remained significantly thinner in the renal impairment group, with the exceptions of the outer temporal ($P = 0.092$) and inner temporal ($P = 0.079$) regions.

Table 2. Macular Choroidal Thickness in Patients With Diabetes Mellitus Stratified by eGFR

EDTRS Region	eGFR <60 mL/min/1.73 m ²	eGFR ≥60 mL/min/1.73 m ²	P Value
Outer superior, μm	150.4 ± 65.3	195.6 ± 75.3	<0.001
Inner superior, μm	155.8 ± 68.7	205.4 ± 81.0	<0.001
Outer temporal, μm	140.6 ± 49.8	177.0 ± 65.6	<0.001
Inner temporal, μm	159.2 ± 61.4	199.0 ± 74.9	<0.001
Central field, μm	156.3 ± 70.2	206.6 ± 83.9	<0.001
Inner nasal, μm	141.5 ± 66.5	194.7 ± 86.2	<0.001
Outer nasal, μm	107.5 ± 60.7	155.9 ± 82.2	<0.001
Inner inferior, μm	141.6 ± 65.2	193.5 ± 85.0	<0.001
Outer inferior, μm	122.9 ± 57.3	172.1 ± 79.3	<0.001
Average, μm	141.8 ± 57.2	188.9 ± 74.1	<0.001

Bold indicates statistical significance.
eGFR, estimated glomerular filtration rate.

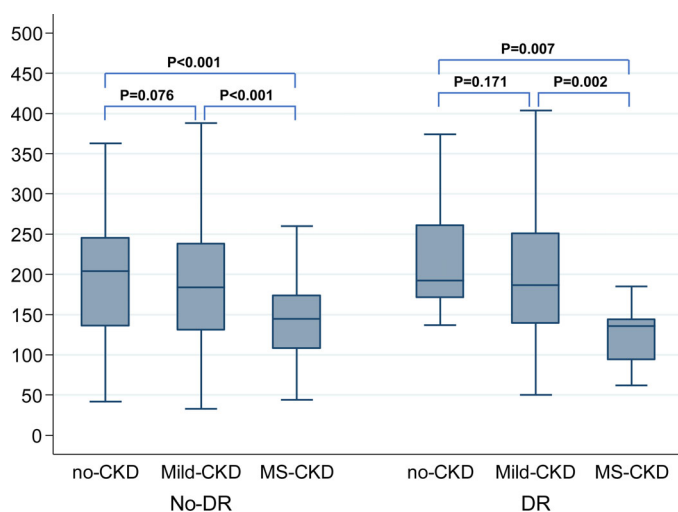


Figure 2. Boxplots showing the distribution of macular choroidal thickness measured by SS-OCT stratified by renal function and DR status. CKD, chronic kidney disease; CT, choroidal thickness; DR, diabetic retinopathy.

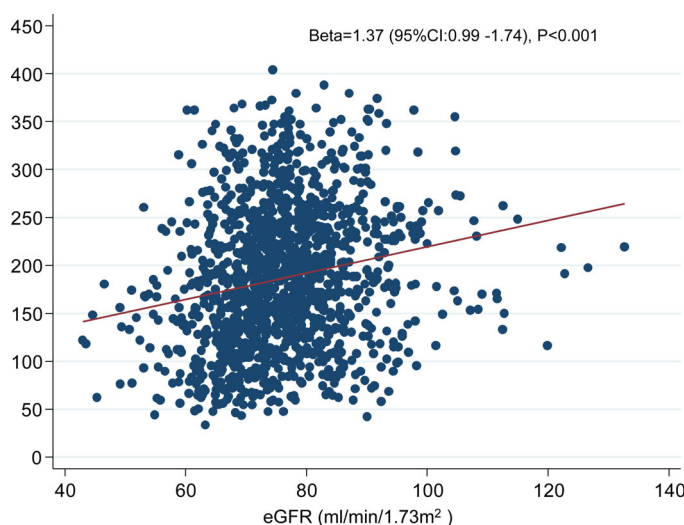


Figure 3. Scattergram showing linear regression analysis between average CT and eGFR. CT, choroidal thickness; eGFR, estimated glomerular filtration rate. Linear regression analysis showed positive association between average CT and eGFR, with coefficient (beta value) of 1.37 (95% confidence interval, 0.99–1.74; $P < 0.001$).

CT and eGFR

Figure 3 depicts the relationship between the average CT and eGFR and also shows the linear association. Table 4 presents the associations of CT in the macula with eGFR after adjusting for other factors. It persistently revealed that the average CTs ($\beta = 0.4$, $P = 0.029$) and the CTs in the central ($\beta = 0.5$, $P = 0.019$), outer superior ($\beta = 0.4$, $P = 0.047$), inner superior ($\beta = 0.5$, $P = 0.018$), inner inferior ($\beta = 0.5$, $P = 0.025$), and inner temporal ($\beta = 0.4$, $P = 0.038$) regions were positively associated with eGFR independent of age, sex, duration of DM, BMI, TG, TC, HbA1c, use of insulin, AL, and DR status.

Discussion

To the best of our knowledge, this is the first study to use SS-OCT to investigate an association of renal function and macular CT in ocular treatment naïve diabetic patients from the Chinese population. The results demonstrated that the CT was significantly thinner in diabetes patients with renal impairment, and the thicker CT was significantly correlated with the eGFR independent of age, sex and other potentially confounding factors.

Although the choroid is a highly vascularized structure that plays an important role in the regulation of ocular metabolism, few studies have evaluated the

Table 3. Changes of Macular Choroidal Thickness in Patients with Renal Impairment Compared with that in Patients without Renal Impairment after Adjusting Confounding Factors

Region	Model 1*		Model 2†	
	β (95% CI)	P Value	β (95% CI)	P Value
Average MCT, μm	-26.0 (-45.2 to -6.9)	0.008	-21.5 (-39.5 to -3.4)	0.020
Central field, μm	-29.8 (-51.9 to -7.7)	0.008	-24.9 (-45.7 to -4.1)	0.019
Outer superior, μm	-24.6 (-44.2 to -5.1)	0.014	-19.6 (-38.4 to -0.7)	0.042
Outer inferior, μm	-24.6 (-44.9 to -4.3)	0.018	-19.9 (-39.3 to -0.4)	0.045
Outer nasal, μm	-26.1 (-47.6 to -4.6)	0.017	-22.6 (-42.9 to -2.2)	0.030
Outer temporal, μm	-19.1 (-36.2 to -1.9)	0.029	-14.4 (-31.0 to 2.3)	0.092
Inner superior, μm	-29.3 (-50.6 to -8.0)	0.007	-24.0 (-44.3 to -3.7)	0.020
Inner inferior, μm	-28.8 (-50.9 to -6.7)	0.011	-25.4 (-46.4 to -4.4)	0.018
Inner nasal, μm	-30.3 (-52.8 to -7.7)	0.009	-25.8 (-46.9 to -4.6)	0.017
Inner temporal, μm	-21.8 (-41.6 to -2.0)	0.031	-16.9 (-35.7 to 2.0)	0.079

Renal impairment was defined as estimated glomerular filtration rate <60 mL/min/1.73 m² (i.e., MS-CKD patients in this study). Bold indicates statistical significance

* Adjusted for age and sex.

† Adjusted for age, sex, duration, systolic blood pressure, body mass index, serum triglycerides, total cholesterol, HbA1c, use of insulin, axial length, diabetic retinopathy status (yes or no).

Table 4. Multivariable Adjusted Associations of Choroidal Thickness in Macula with eGFR in Diabetic Patients

Per 1 eGFR Increase	Model 1*			Model 2†		
	β (95% CI)	P Value	R ²	β (95% CI)	P Value	R ²
Average MCT, μm	0.5 (0.1-0.9)	0.012	0.143	0.4 (0.041-0.8)	0.029	0.255
Central field, μm	0.6 (0.2-1.1)	0.007	0.112	0.5 (0.1-0.9)	0.019	0.231
Outer superior, μm	0.5 (0.1-0.9)	0.023	0.139	0.4 (0.005-0.8)	0.047	0.221
Outer inferior, μm	0.5 (0.1-0.9)	0.018	0.160	0.4 (0.001-0.8)	0.050	0.252
Outer nasal, μm	0.3 (-0.1 to 0.8)	0.113	0.119	0.3 (-0.1 to 0.7)	0.196	0.231
Outer temporal, μm	0.4 (0.03-0.7)	0.033	0.119	0.3 (-0.04 to 0.6)	0.084	0.187
Inner superior, μm	0.6 (0.2-1.0)	0.006	0.118	0.5 (0.1-0.9)	0.018	0.215
Inner inferior, μm	0.6 (0.1-1.0)	0.015	0.132	0.5 (0.1-0.9)	0.025	0.234
Inner nasal, μm	0.5 (0.1-1.0)	0.021	0.124	0.4 (-0.003 to 0.9)	0.052	0.238
Inner temporal, μm	0.5 (0.1-0.9)	0.014	0.105	0.4 (0.02-0.8)	0.038	0.203

eGFR, estimated glomerular filtration rate.

* Adjusted for age and sex.

† Adjusted for age, sex, duration, systolic blood pressure, body mass index, serum triglycerides, total cholesterol, HbA1c, use of insulin, axial length, diabetic retinopathy status (yes or no).

relationship between extraocular vascular disease and changes in the choroid, and the prior studies that have been conducted to evaluate a relationship between CT and renal function have led to conflicting results.^{9,12,28} Farias et al.¹⁰ found that the CT was thinner in patients with microalbuminuria, indicating that patients with renal impairment had thinner CTs. Kocasarac et al.²⁹ reported that the CT was reduced in diabetes patients with the comorbidity of DN. However, Melerbi et al.¹¹ found thicker CTs in type 1 DM patients, and the

CT was much thicker in patients with microalbuminuria than those with normal urine protein. They also found no independent correlation between CT and eGFR. Garrido-Hermosilla et al.⁹ also reported that CT had a positive relationship with albuminuria but no significant association with eGFR. However, the aforementioned studies included less than 50 patients, did not fully adjust for confounding factors and used EDI SD-OCT instead of SS-OCT. All of these may be potential reasons for the inconsistent results. This study

included a larger number of treatment naïve patients and confirmed that the CT was reduced in diabetic patients with renal impairments.

The choroid is a pure vascular structure that can be thinned to reflect microvascular damage, which may be a local manifestation of a wider range of vascular injuries.^{7,8} We hypothesize that oxidative stress, subclinical inflammation, endothelial dysfunction, and early vascular aging characterize CKD because it may explain why choroidal thinning is associated with impaired renal function at the initial stage. CT has a negative relationship with endothelial dysfunction and some markers of vascular inflammation, such as endothelin-1, asymmetric dimethyl arginine, and IL-6 levels.⁷ Studies have also found that CT reduction is associated with increased arterial stiffness.^{28,30,31} Because the choroidal blood vessels nourish the outer retinal layer and RPE, it is possible that retinopathy is secondary to choroidal damage. Dysfunction of the autonomic nervous system can also cause CT changes, and overactivation of the sympathetic nervous system is a feature of DN.^{3,27} In addition, the vascular smooth muscle may play a role in CT changes. Further basic studies are needed to clarify the mechanisms of CT thinning with renal impairment.

This study has potential value, both clinically and scientifically. The pathophysiological mechanism of thinning CT in patients with renal impairment in this study may share common pathways with DM and hypertension.^{7,8,32,33} The association of eGFR and CT were also reported in previous studies based on nondiabetic patients. Vadalà et al.³³ found that decreasing CT was significantly associated with decreasing eGFR and defects of renal function in patients with essential hypertension. Mulè et al.⁸ reported that eGFR was directly correlated with CT independent of age and other confounding factors, and the poorer the renal function, the thinner the CT. The present study further found that eGFR was independently related to CT in diabetic patients. Thus, renal function should be noted as a potential confounding factor and should be considered in all studies on CT. The results of this study suggested that CT may be used as a window to observe systemic microvascular conditions and may contribute to the clinical understanding of renal function. However, the value of OCT parameters in predicting renal function needs to be verified in future research with larger populations.^{6,33,34}

There was double-digit difference in the number of the patients between the groups. If the group with renal impairment had significantly severe DR, the data were skewed because the number of patients with renal impairment was quite small compared with the other. Among the included patients, the majority of them

were non-DR, with 80.25% in patients without renal impairment and 79.25% patients with renal impairment. The exact relationship between eGFR and DR remains controversial, with some studies reported a negative association, whereas others reported no association or indirect association. In this study, the severity of DR or presence of DME were not correlated with renal impairment, indicating that the distribution of DR severity might not affect the findings. Previous reports demonstrated that the DR severity and presence/absence of DME might affect the CT. However, the population-based Beijing Eye Study had the largest Chinese patients and reported that the CT were not related to the presence of DR ($P = 0.61$) or stage of DR ($P = 0.14$). In addition, only less than 5% patients in this study had relative severe DR. Therefore, we believe the rate of DR severity could not bias our findings.

The retina was considered to be a window to the kidney. The OCT imaging may be a novel way of estimating renal function in diabetic patients. Because renal disease is a major cause of morbidity and mortality, this may well turn into a useful clinical technique. However, from the data presented, there appears to be a large degree of overlap of choroidal thickness and renal function, as estimated by the eGFR. This may limit its usefulness as a single instance diagnostic test for an individual patient, but may be useful in following the same patient over time, as the authors point out in calling for further cohort studies. The association between the eGFR and CT needs to be better defined in the further longitudinal cohort studies.

The strengths of this study lie in the inclusion of only treatment naïve diabetic patients, the adoption of automatic SS-OCT, fully adjusting for confounding factors and a substantially larger sample size. There are, of course, limitations of the study as well. First, as a cross-sectional study, we cannot determine the causal relationship between renal function and CT, which needs to be verified in a cohort study. Second, participants enrolled in this study were all type 2 DM patients, the finding could not be generalized to type 1 DM directly. Furthermore, the majority of patients (80.21%) were non-DR diabetic patients, the relationship in DR patients still needs to be confirmed in further studies. Third, the choroid imaging was not performed at the same time. Diurnal variations of CT have been reported in a single day.^{35,36} However, the results were consistent with the primary analyses when the measuring time was included in the multivariate models. Fourth, because of the large degree of CT overlap between the groups, due to the large SD, clinical use for an individual may be limited.

However, this may be a good, easy, noninvasive way of following renal function in diabetic patients over time. Finally, participants were all recruited from communities in Guangzhou, China. The generalization of the conclusions is therefore limited, and further studies with multiethnic populations are needed to verify the findings.

Conclusions

In summary, this study demonstrated a significant association between CT reduction and renal impairment in ocular treatment-naïve diabetic patients using the innovative SS-OCT. The CT was independently positively correlated with eGFR. These findings confirm the close association of changes in retinal microvasculature and renal microcirculation. Further studies are needed to elaborate on the mechanism of pathogenesis in the association between CT and renal function and to determine whether a CT obtained with an SS-OCT can predict the prognosis of DN in DM patients.

Acknowledgments

This study was supported by the National Natural Science Foundation of China (81570843; 81530028; 81721003). The funding organization had no role in the design or conduct of the study; collection, management, analysis, and interpretation of the data; preparation, review, or approval of the manuscript; and decision to submit the manuscript for publication.

WW and WH had full access to all the data in the study and take responsibility for the integrity of the data and the accuracy of the data analysis. Study concept and design: WW, WL, MH, WH. Acquisition, analysis, or interpretation of data: LS, YT, YL, WL. Drafting of the manuscript: LS, WW. Critical revision of the manuscript for important intellectual content: All authors. Statistical analysis: WW. Obtained funding: WH. Administrative, technical, or material support: MH, WW. Study supervision: MH.

Disclosure: **S. Liu**, None; **W. Wang**, None; **Y. Tan**, None; **M. He**, None; **L. Wang**, None; **Y. Li**, None; **W. Huang**, None

References

1. Zheng Y, Ley SH, Hu FB. Global aetiology and epidemiology of type 2 diabetes mellitus and its complications. *Nat Rev Endocrinol*. 2018;14:88–98.
2. Leasher JL, Bourne RR, Flaxman SR, et al. Global estimates on the number of people blind or visually impaired by diabetic retinopathy: a meta-analysis from 1990 to 2010. *Diabetes Care*. 2016;39:1643–1649.
3. Anders HJ, Huber TB, Isermann B, Schiffer M. CKD in diabetes: diabetic kidney disease versus nondiabetic kidney disease. *Nat Rev Nephrol*. 2018;14:361–377.
4. Nagaoka T, Yoshida A. Relationship between retinal blood flow and renal function in patients with type 2 diabetes and chronic kidney disease. *Diabetes Care*. 2013;36:957–961.
5. Stitt AW, Curtis TM, Chen M, et al. The progress in understanding and treatment of diabetic retinopathy. *Prog Retin Eye Res*. 2016;51:156–186.
6. Singh SR, Vupparaboina KK, Goud A, Dansingani KK, Chhablani J. Choroidal imaging biomarkers. *Surv Ophthalmol*. 2019;64:312–333.
7. Balmforth C, van Bragt JJ, Ruijs T, et al. Chorioretinal thinning in chronic kidney disease links to inflammation and endothelial dysfunction. *JCI Insight*. 2016;1:e89173.
8. Mule G, Vadala M, La Blasca T, et al. Association between early-stage chronic kidney disease and reduced choroidal thickness in essential hypertensive patients. *Hypertens Res*. 2019.
9. Garrido-Hermosilla AM, Mendez-Muros M, Gutierrez-Sanchez E, et al. Renal function and choroidal thickness using swept-source optical coherence tomography in diabetic patients. *Int J Ophthalmol*. 2019;12:985–989.
10. Farias LB, Lavinsky D, Schneider WM, Guimaraes L, Lavinsky J, Canani LH. Choroidal thickness in patients with diabetes and microalbuminuria. *Ophthalmology*. 2014;121:2071–2073.
11. Malerbi FK, Regatieri CV, de Sa JR, Morales PH, Farah ME, Dib SA. Microalbuminuria is associated with increased choroidal thickness in type 1 diabetes mellitus patients without diabetic retinopathy. *Acta Ophthalmol*. 2018;96:e95–e97.
12. Kocasarac C, Yigit Y, Sengul E, Sakalar YB. Choroidal thickness alterations in diabetic nephropathy patients with early or no diabetic retinopathy. *Int Ophthalmol*. 2018;38:721–726.
13. Wang W, Zhang X. Choroidal thickness and primary open-angle glaucoma: a cross-sectional

- study and meta-analysis. *Invest Ophthalmol Vis Sci.* 2014;55:6007–6014.
14. Wang W, Zhou M, Huang W, Chen S, Ding X, Zhang X. Does acute primary angle-closure cause an increased choroidal thickness? *Invest Ophthalmol Vis Sci.* 2013;54:3538–3545.
 15. Wang W, He M, Zhong X. Sex-dependent choroidal thickness differences in healthy adults: a study based on original and synthesized data. *Curr Eye Res.* 2018;43:796–803.
 16. Sahinoglu-Keskek N, Altan-Yaycioglu R, Canan H, Coban-Karatas M. Influence of glycosylated hemoglobin on the choroidal thickness. *Int Ophthalmol.* 2018;38:1863–1869.
 17. Unsal E, Eltutar K, Zirtiloglu S, Dincer N, Ozdogan ES, Gungel H. Choroidal thickness in patients with diabetic retinopathy. *Clin Ophthalmol.* 2014;8:637–642.
 18. Zur D, Igllicki M, Busch C, Invernizzi A, Mariussi M, Loewenstein A. OCT biomarkers as functional outcome predictors in diabetic macular edema treated with dexamethasone implant. *Ophthalmology.* 2018;125:267–275.
 19. Yiu G, Manjunath V, Chiu SJ, Farsiu S, Mahmoud TH. Effect of anti-vascular endothelial growth factor therapy on choroidal thickness in diabetic macular edema. *Am J Ophthalmol.* 2014;158:745–751.
 20. Zhu Y, Zhang T, Wang K, Xu G, Huang X. Changes in choroidal thickness after panretinal photocoagulation in patients with type 2 diabetes. *Retina.* 2015;35:695–703.
 21. Ferrara D, Waheed NK, Duker JS. Investigating the choriocapillaris and choroidal vasculature with new optical coherence tomography technologies. *Prog Retin Eye Res.* 2016;52:130–155.
 22. Li DY, Yin WJ, Yi YH, et al. Development and validation of a more accurate estimating equation for glomerular filtration rate in a Chinese population. *Kidney Int.* 2019;95:636–646.
 23. Hanumunthadu D, Ilginis T, Restori M, et al. Repeatability of swept-source optical coherence tomography retinal and choroidal thickness measurements in neovascular age-related macular degeneration. *Br J Ophthalmol.* 2017;101:603–608.
 24. Sala-Puigdollers A, Figueras-Roca M, Hereu M, et al. Repeatability and reproducibility of retinal and choroidal thickness measurements in diabetic macular edema using swept-source optical coherence tomography. *Plos One.* 2018;13:e200819.
 25. Obis J, Garcia-Martin E, Orduna E, et al. Reproducibility of retinal and choroidal measurements using swept-source optical coherence tomography in patients with Parkinson's disease. *Arq Bras Oftalmol.* 2020;83:19–27.
 26. Jin G, Xiao W, Ding X, et al. Prevalence of and risk factors for diabetic retinopathy in a rural chinese population: the Yangxi eye study. *Invest Ophthalmol Vis Sci.* 2018;59:5067–5073.
 27. Scanlon PH. The English National Screening Programme for diabetic retinopathy 2003-2016. *Acta Diabetol.* 2017;54:515–525.
 28. Schuster AK, Leuschner A, Feretos C, et al. Choroidal thickness is associated with cardiovascular risk factors and cardiac health: the Gutenberg Health Study. *Clin Res Cardiol.* 2020;109:172–182.
 29. Kocasarac C, Yigit Y, Sengul E, Sakalar YB. Choroidal thickness alterations in diabetic nephropathy patients with early or no diabetic retinopathy. *Int Ophthalmol.* 2018;38:721–726.
 30. Jeon SJ, Park HL, Lee JH, Park CK. Relationship between systemic vascular characteristics and retinal nerve fiber layer loss in patients with type 2 diabetes. *Sci Rep.* 2018;8:10510.
 31. Akcay BI, Kardes E, Macin S, et al. Evaluation of subfoveal choroidal thickness in internal carotid artery stenosis. *J Ophthalmol.* 2016;2016:5296048.
 32. Chua J, Chin C, Hong J, et al. Impact of hypertension on retinal capillary microvasculature using optical coherence tomographic angiography. *J Hypertens.* 2019;37:572–580.
 33. Vadala M, Castellucci M, Guarrasi G, Terrasi M, La Blasca T, Mule G. Retinal and choroidal vasculature changes associated with chronic kidney disease. *Graefes Arch Clin Exp Ophthalmol.* 2019;257:1687–1698.
 34. Pearce I, Simo R, Lovestam-Adrian M, Wong DT, Evans M. Association between diabetic eye disease and other complications of diabetes: implications for care. A systematic review. *Diabetes Obes Metab.* 2019;21:467–478.
 35. Seidel G, Hausberger S, Herzog SA, et al. Circadian macular volume changes in the healthy human choroid. *Am J Ophthalmol.* 2015;159:365–371.
 36. Lee SW, Yu SY, Seo KH, Kim ES, Kwak HW. Diurnal variation in choroidal thickness in relation to sex, axial length, and baseline choroidal thickness in healthy Korean subjects. *Retina.* 2014;34:385–393.