

Article

Morselized Amniotic Membrane Tissue for Refractory Corneal Epithelial Defects in Cicatricial Ocular Surface Diseases

Anny M. S. Cheng¹, Lorraine Chua², Victoria Casas¹, and Scheffer C. G. Tseng^{1,2}

¹ Ocular Surface Center, Miami, FL, USA

² Research and Development Department, TissueTech, Inc., Miami, FL, USA

Correspondence: Scheffer C. G. Tseng, Ocular Surface Center and Ocular Surface Research & Education Foundation, 7000 SW 97th Avenue, Suite 213, Miami, FL 33173, USA. e-mail: stseng@ocularsurface.com

Received: 6 January 2016

Accepted: 15 April 2016

Published: 18 May 2016

Keywords: amniotic membrane; cicatricial ocular surface; inflammation; persistent epithelial defect; umbilical cord

Citation: Cheng AM, Chua L, Casas V, Tseng SC. Morselized amniotic membrane tissue for refractory corneal epithelial defects in cicatricial ocular surface diseases. *Trans Vis Sci Tech.* 2016;5(3):9, doi:10.1167/tvst.5.3.9

Purpose: To evaluate the clinical efficacy of morselized amniotic membrane and umbilical cord tissue (MAU) in treating refractory corneal epithelial defect in ocular cicatricial diseases.

Methods: Retrospective review of four patients with ocular cicatricial diseases treated with topical MAU for corneal epithelial defects refractory to conventional treatments including topical lubricants, autologous serum, bandage contact lens, and tarsorrhaphy. Their symptoms, corneal staining, conjunctival inflammation, and visual acuity were compared before and after treatment.

Results: After topical application of MAU twice daily, two patients demonstrated rapid corneal epithelialization with prompt visual acuity improvement at the first day. All patients showed corneal epithelialization in 7.3 ± 2.6 days accompanied by a significant relief of symptoms, reduction of ocular surface inflammation, and improvement of visual acuity.

Conclusion: This pilot study suggests topical MAU can be developed into a novel treatment for treating refractory corneal epithelial defects.

Translational Relevance: Topical MAU can be an effective novel treatment for refractory corneal epithelial defects.

Introduction

Cicatricial ocular surface diseases caused by diverse etiologies such as ocular cicatricial pemphigoid, Stevens-Johnson syndrome, toxic epidermal necrolysis, and chemical burns are frequently associated with a myriad of ocular complications leading to significant visual morbidity. Ocular surface involvement is characterized by conjunctival scarring that progresses to lid margin scarring, development of symblepharon, and foreshortening of the fornix.^{1,2} Depending on the location, symblepharon might obliterate the tear reservoir and interfere with effective replenishment of tears in the meniscus and ocular surface leading to dry eye. In addition, these cicatricial complications if associated with lid margin keratinization, scarring, and mal-aligned lashes invariably cause blink-related trauma to the ocular surface and correlate significantly with persistent

ocular surface inflammation leading to corneal epithelial breakdown.^{1,3,4} Consequently, corneal blindness frequently ensues in an advanced stage of cicatricial ocular surface diseases.⁵⁻⁸

Inflammation and fibrosis are the two main pathologic processes of the aforementioned cicatricial ocular surface diseases.⁶ Conceivably, measures directed to suppress this inflammatory/scarring cascade should be valuable. Conventional measures include systemic immunomodulators as well as topical tear lubricants, steroids, autologous serum, bandage contacts lens (BCL), and scleral lens.^{6,8-10} Another therapeutic modality is transplantation of cryopreserved amniotic membrane (AM), which has been shown to suppress inflammation, angiogenesis, and scarring so as to promote epithelial wound healing.¹¹ For example, persistent or refractory corneal epithelial defect has been successfully managed by securing single^{12,13} or multiple¹²⁻¹⁸ layers of AM by sutures or fibrin glue.¹⁹⁻²² To facilitate the ease and ready use in

Table. Summary of Relevant Clinical Data

Subject Number	Age, y	Gender	Eye	Concomitant Disease	Prior Treatment	Symptoms	
						Pre	Post
1	92	Female	R	Exposure keratopathy	Cyc, Tar, AT, AS, PO	pa, pho, i, BV, bur, mu	-
2	85	Female	R	DED, EBMD	Cyc, PK, AT, BCL, PO	pa, dry, i, BV, mu	mu
3	68	Female	L	HSV	Cyc, OMG, PK, AT, BCL, PO	dry, i, red, BV	-
4	69	Female	R	DED, RA	Cyc, PK, AT, BCL, PO	pa, dry, pho, i, BV, bur, mu	i, mu

AT, artificial tears; AS, autologous serum; BCL, bandage contact lens; bur, burning; BV, blurred vision; Cyc, cyclophosphamide; dry, dryness; i, irritation; L, left; mu, mucous; OMG, oral mucosal graft for lid reconstruction; pa, pain; pho, photophobia; PK, PROKERA placement; PO, punctal occlusion; Post, postoperative finding; Pre, preoperative finding; R, right; RA, rheumatoid arthritis; red, redness; Tar, tarsorrhaphy.

The definition of grading or severity is detailed in the text.

the office, sutureless self-retaining cryopreserved AM via PROKERA (Bio-Tissue, Inc., Miami, FL) has been developed to treat persistent and refractory corneal epithelial defects.^{23–27} Nonetheless, the aforementioned methods of applying cryopreserved AM may not be amenable in eyes with cicatricial processes. For example, symblepharon and fornix shortening may preclude the use of PROKERA. That was why we have developed a morselized form of cryopreserved AM and umbilical cord tissue (MAU) and presented our preliminary success of using topical application of MAU in treating refractory corneal epithelial defects in four consecutive cases of cicatricial ocular surface diseases.

Inc., Miami, FL). MAU consists of 25% to 33% wt/vol AM and UC tissues in 0.9% wt/vol sodium chloride added with 250 µg/mL Amphotericin B (Mediatech, Inc., Manassas, VA), an antifungal agent. MAU is packaged into ophthalmic tubes which delivers 20 to 50 µL of MAU per drop.

Patients

All four patients presented with ocular cicatricial diseases manifesting medial canthal scarring, fornicial shortening, symblepharon, occluded puncta, and distichiasis. Their inflammatory activity of the cicatricial disease had been treated with oral cyclophosphamide at the dosage of 1 to 2 mg/kg for a mean of 12.1 ± 10.4 months with titration according to monthly complete blood count and urine analysis to maintain the peripheral white cell count of at least 3000 cells/mm³.²

The [Table](#) summarizes the patients' demographics, ocular comorbidity, concomitant treatment, and clinical manifestations including symptoms and signs at the presentation. Conjunctival inflammation was graded according to the conjunctival injection as none (0), mild (1), moderate (2), and severe (3). The corneal surface integrity was scored as clear (0), scattered superficial punctate keratitis (SPK; 1+), moderate SPK (2+), and diffuse SPK with or without corneal epithelial defects (3+). The tear function was assessed by the fluorescein clearance test as reported²⁸ using the Schirmer paper strip following topical application of 5 µL of Fluroress (Akorn Inc., Abita Springs, LA). The diagnosis of dry eye disease (DED) was based on the wetting length of less than 3 mm at the 10th and 20th minute. For Case #2 who presented with epithelial basement membrane dystrophy (EBMD),

Methods

This study was approved by the ethics committee of the Ocular Surface Research and Education Foundation (Miami, FL) according to the Tenets of the Declaration of Helsinki to retrospectively review four patients with cicatricial ocular surface diseases that were consecutively seen at Ocular Surface Center (Miami, FL) between June 2015 and August 2015.

Preparation of MAU

AM and umbilical cord (UC) tissues are procured in compliance with American Association of Tissue Banks Standards from eligible pregnant women following elective cesarean section delivery under full informed consent. The AM and UC tissues are aseptically processed in accordance with current Good Manufacturing Practices and current Good Tissue Practices regulations into a morselized form by the proprietary CRYOTEK method (TissueTech,

Table. Extended

Subject Number	Conjunctival Grading		Corneal Grading		Visual Acuity	
	Pre	Post	Pre	Post	Pre	Post
1	1	1	3	1	20/400	20/50
2	2	1	3	1	20/400	20/100
3	2	1	3	0	20/60	20/40
4	2	1	3	1	20/80	20/50

the diagnosis was confirmed by observing corneal epithelial wrinkles or breaks by the “screwdriver test,” which applies a dry Weck-Cel sponge (Beaver-Visitec International, Inc., Waltham, MA) directly to the corneal surface and makes a 90° twist upon contact.²³ Consequently, epithelial debridement was performed to remove the entire loose epithelium. Because their persistent corneal epithelial defects were refractory to a number of conventional treatments (summarized in the Table), MAU tissue was applied twice daily in all four patients. Their clinical responses during the follow-up visits were documented in the same manner afterward. Descriptive statistics for continuous variables are reported as the mean \pm SD and analyzed using SPSS software, version 19.0 (SPSS Inc., Chicago, IL). A *P* value less than 0.05 was considered statistically significant.

Results

As summarized in the Table, all four patients were female with the average age of 78.5 ± 11.9 years. Associated comorbidity included exposure keratopathy (Case #1), EBMD (Case #2), DED (Case #2 and #4), Herpes Simplex Keratitis (HSV; Case #3), and rheumatoid arthritis (Case #4). At presentation, the inflammatory activity of two patients (Case #1 and #2) had been controlled by oral cyclophosphamide while that of the other two (Case #3 and #4) remained active. Besides systemic cyclophosphamide, they had been treated with the conventional medical treatments including lubricating drops or ointments ($n = 4$), autologous serum ($n = 1$), and BCL ($n = 3$). All eyes had punctal occlusion caused by the disease process. Three eyes (Case #2, #3, and #4) had received placement of self-retained cryopreserved AM (PROKERA) 18, 44, and 1.5 months ago, respectively, without success due to the presence of symblepharon. Case #1 underwent nasal and temporal tarsorrhaphy. Case #3 received oral mucosa graft for eyelid reconstruction.

Despite the aforementioned treatment, these patients complained of ocular irritation and blurred

vision and ocular pain ($n = 3$), dryness ($n = 3$), mucous discharge ($n = 3$), photophobia ($n = 2$), burning ($n = 2$), and redness ($n = 1$). Examination confirmed the presence of symblepharon with fornicial shortening, occluded puncta, and distichiasis. Case #1 presented with an infrequent and incomplete blinking. The conjunctiva inflammation was graded as 1 (Case #1) and 2 in the other three eyes. All eyes had corneal epithelial defects and 3+ SPK. The visual acuity was 0.5 (Case #3), 0.6 (Case #4), and 1.3 logMAR (Case #1 and #2).

All four patients used MAU tissue twice daily without other treatments for 7.3 ± 2.6 days without any difficulty or adverse effect. Within a few days after application, all patients reported a significant relief of symptoms as evidenced by consistent reduction of ocular surface inflammation and rapid corneal epithelialization at Day 1 for Case #1 (Fig. 1) and Case #2 (Fig. 2), Day 2 for Case #3 (Fig. 3) and Day 4 for Case #4 (Fig. 4). Intriguingly, regardless of incomplete epithelialization, two eyes (Case #1 and #2) at Day 1 exhibited improvement of the visual acuity from 1.3 to 0.6 logMAR and from 1.3 to 1 logMAR, respectively. Complete epithelialization was noted in 5 days (Case #1), 6 days (Case #3), 7 days (Case #2), and 11 days (Case #4), respectively. Conjunctival inflammation was reduced from grade 2 to 1 in three eyes (Cases #2, #3, and #4) and remained unchanged as grade 1 in one eye (Case #1). Ocular pain was resolved in all three eyes (Case #1, #2, and #4) and two eyes (Case #1 and #3) reported complete symptomatic resolution of irritation ($n = 2$), blurred vision ($n = 2$), pain ($n = 1$), dryness ($n = 1$), photophobia ($n = 1$), redness ($n = 1$), burning ($n = 1$), and mucus formation ($n = 1$). The other two eyes had most symptoms resolved but there remained mild irritation (Case #4) as well as mucus formation (Case #2 and #4). There was also an improved visual acuity in all eyes from 0.9 ± 0.4 to 0.45 ± 0.1 logMAR ($P = 0.7$) when corneal epithelialization was completed.

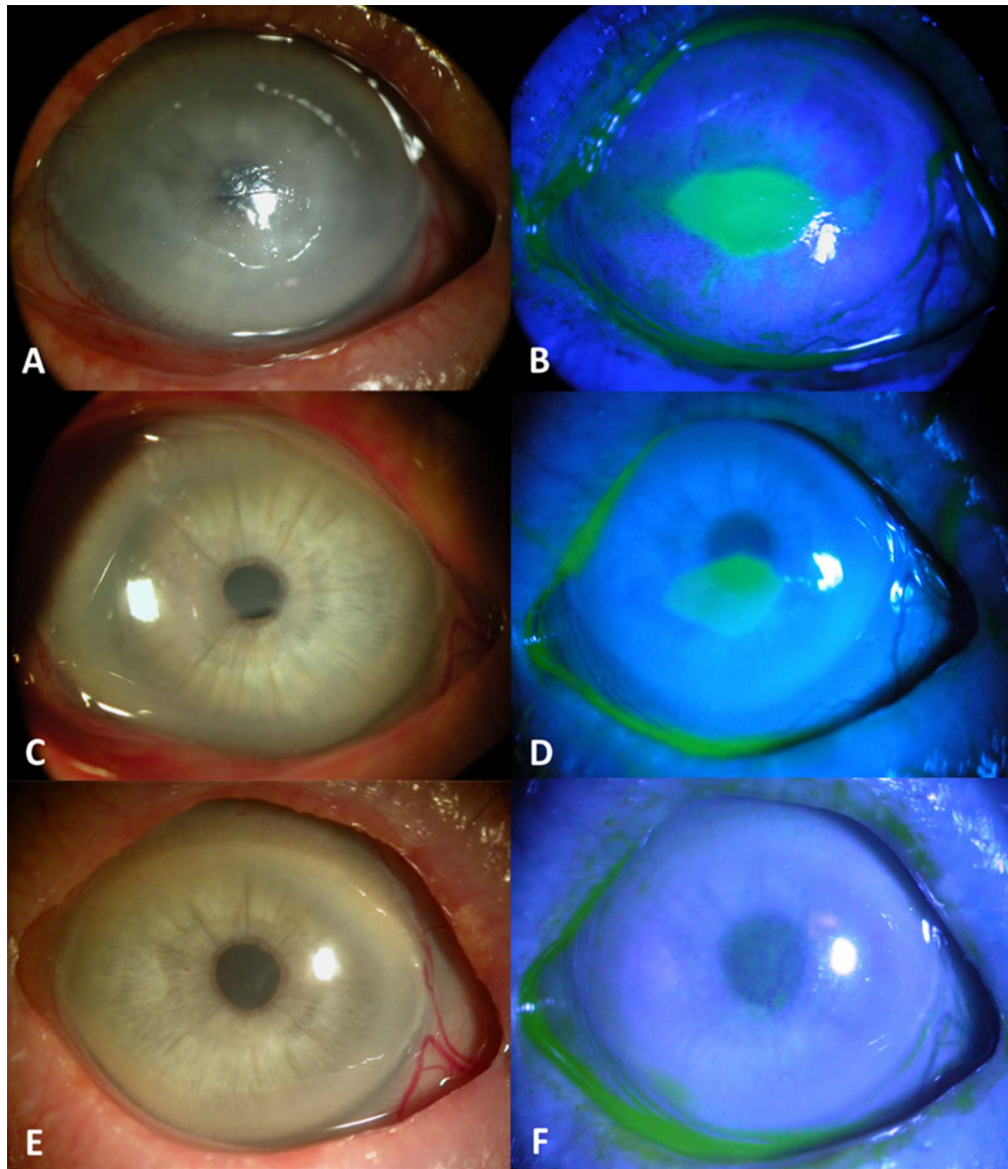


Figure 1. Clinical Course of Case #1. The refractory central corneal epithelial defect with sharp, distinct, irregular border in OD (right eye) (A, B) showed progressive improvement at Day 1 (C, D), and Day 5 (E, F) after topical application of MAU with the visual acuity improved rapidly from 20/400 to 20/80 at the first day. The defect size greatly reduced with progressive epithelialization as suggested by a smoothed edge in 1 day (C, D). All symptoms resolved and visual acuity regained to 20/50 at Day 5.

Discussion

Persistent or recurrent corneal epithelial defect is a frequent corneal complication in cicatricial ocular surface diseases and the prime reason leading to corneal blindness.⁶ Indeed, cicatrization-induced severe dry eye and lid margin/tarsal related micro-trauma are significantly correlated with corneal pathologies.¹ As shown herein, conservative treatments such as topical lubricants, autologous serum,

bandage contact lens, and tarsorrhaphy failed to treat these corneal epithelial defects. Although refractory cases can be benefited by scleral contact lens,²⁹ its use was limited in patients as illustrated in this study due to the presence of significant symblepharon. Similarly, placement of PROKERA could not be instituted due to symblepharon in three of four patients. To circumvent these limitations, we have developed MAU and shown its encouraging efficacy in promoting epithelialization, reducing corneal

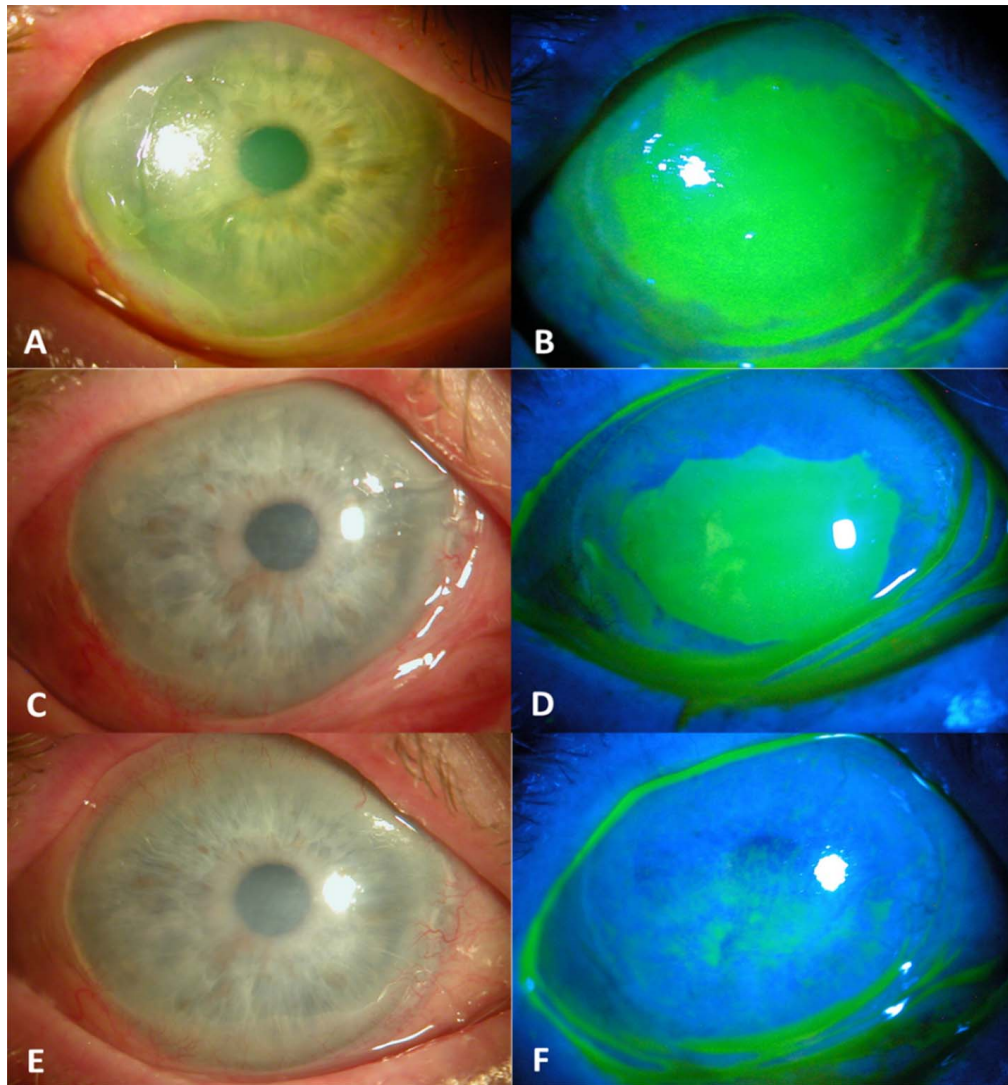


Figure 2. Clinical Course of Case #2. The OD (right eye) received corneal epithelial debridement to remove the entire loose epithelium due to EBMD (A, B). This large corneal epithelial defect showed rapid epithelialization at Day 1 (C, D) and completely healed at Day 7 (E, F) after topical application of MAU. Ocular surface inflammation was reduced and the visual acuity improved rapidly from 20/400 to 20/200 at the first day. Most symptoms resolved and visual acuity eventually regained to 20/100 at Day 7.

staining and conjunctival inflammation, and improving the visual acuity.

Although pathogenic elements of these cicatricial diseases can be multiple, the common denominators are chronic inflammation and fibrosis, which are also interrelated. The clinical efficacy of MAU might be attributed to AM's anti-inflammatory, antiscarring, and antiangiogenic actions. To pursue the active relevant tissue characteristics in AM, we have biochemically purified and characterized a unique matrix termed HC-HA/PTX3 from AM responsible for AM's anti-inflammatory, antiscarring, and antiangiogenic actions^{30–36} (also reviewed in refs. 37, 38). HC-HA/PTX3 is formed by a tight association

between pentraxin 3 (PTX3) and HC-HA complex, which consists of high molecular weight hyaluronic acid (HA) covalently linked to heavy chain 1 (HC1) of inter- α -trypsin inhibitor (I α I) through the catalytic action of tumor necrosis factor-stimulated gene-6. We have recently reported that HC-HA/PTX3 is also present in the UC.^{39,40} HC-HA/PTX3's anti-inflammatory action applies to activated but not resting neutrophils,^{30,35} macrophages,³⁵ and lymphocytes³⁰ (i.e., extending from innate to adaptive immune responses). In addition, HC-HA/PTX3's antiscarring action applies to human corneal fibroblasts to downregulate the transforming growth factor- β 1 promoter activity³⁶ and its antiangiogenic

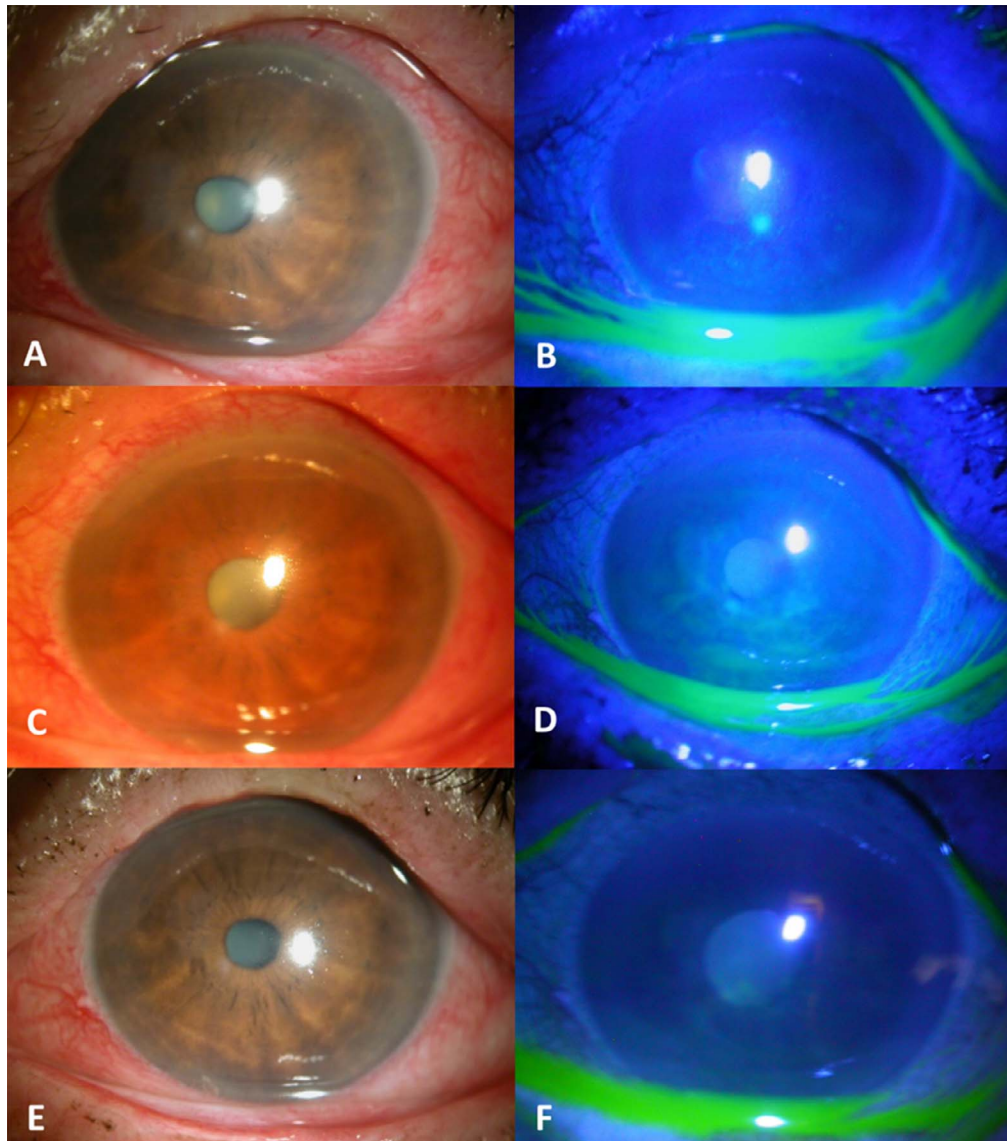


Figure 3. Clinical Course of Case #3. The refractory corneal epithelial defect in OS (left eye) (A, B) showed epithelialization at Day 2 (C, D) and continuous improvement with reduced SPK and inflammation at Day 6 (E, F) after topical application of MAU. Her visual acuity improved from 20/60 to 20/40. The cicatricial disease remained active despite oral cyclophosphamide treatment.

action applies to human umbilical vascular endothelial cells to inhibit cell viability, proliferation, migration, and tube formation.⁴¹ Besides exerting anti-inflammatory, antiscarring, and antiangiogenic effects, HC-HA/PTX3 also distinctively maintains limbal niche cells to support the quiescence of limbal epithelial stem cells toward regeneration.⁴² Collectively, these data explain how MAU can be an effective alternative to treat refractory corneal epithelial defects in cicatricial ocular surface diseases.

We formulated MAU by combining AM with UC from the same donor taking advantage of the high

content of high molecular HA in UC.^{39,40,42} The high HA content might help lubricate the ocular surface to stabilize the tear film⁴³ and might explain why Case #1 and #2 experienced instant symptomatic relief and rapid improvement of vision one day after topical administration even before complete epithelialization (Figs. 1 and 2). Importantly, the epithelialization rate of Case #1 and #2 was faster than that of Case #3 and #4, suggesting that epithelialization might be influenced by the underlying inflammatory activity, which was controlled in the former two cases, but not the latter two cases, by oral cyclophosphamide. In this study, topical application of MAU twice a day

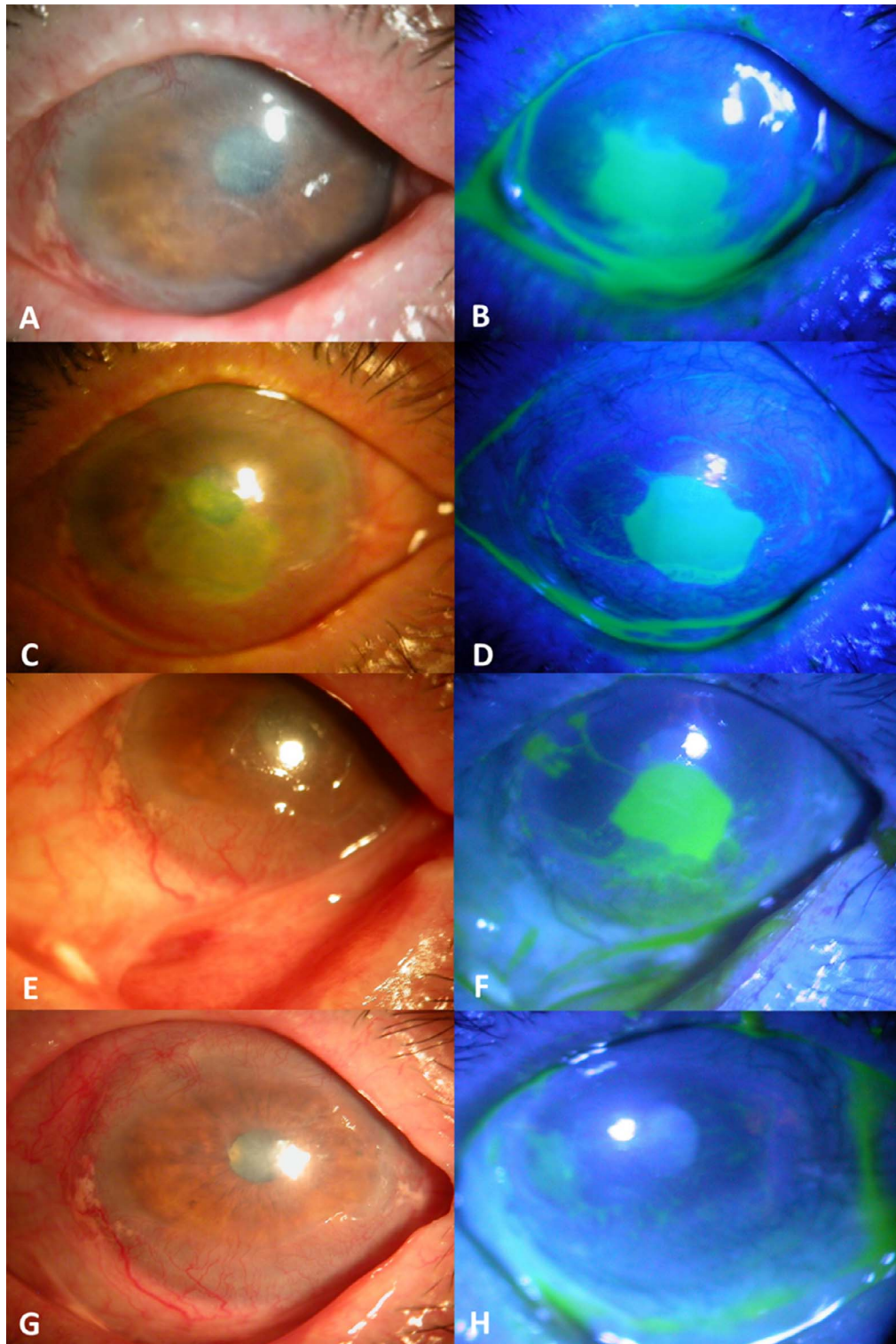


Figure 4. Clinical Course of Case #4. The refractory corneal epithelial defect in OD (right eye) (A, B) showed progressive improvement at Day 4 (C, D), Day 7 (E, F), and Day 11 (G, H) after topical application of MAU. Her visual acuity improved from 20/80 to 20/50. The cicatricial disease remained active despite oral cyclophosphamide treatment. Pressure patching for 2 days was performed because of the sunken globe to avoid nocturnal exposure.⁴⁴ At Day 4 post application, 0.05 mL inferior subconjunctival kenalog was injected to control conjunctival inflammation.

appeared to be sufficient in all four patients presumably because of punctal occlusion that delays tear drainage. In line with this thinking, topical MAU might also be applied in eyes with bandage contact lens or scleral lens. Future studies are needed to determine the optimal application regimen in eyes without punctal occlusion. Our preliminary success reported herein warrants additional prospective controlled studies.

Acknowledgments

The authors thank Sean Tighe for assisting in editing the text.

Supported in part by TissueTech, Inc., Miami, FL.

Disclosure: Dr. Tseng has obtained a patent (US 14/729,489 and PCT/US2015/033955) for the method of preparation and clinical uses of amniotic membrane and morselized form of cryopreserved AM and umbilical cord tissue. **A.M. Cheng**, Ocular Surface Center (E); **L. Chua**, TissueTech, Inc. (E); **S.C. Tseng**, TissueTech, Inc. (E, F) (P)

References

- Di Pascuale MA, Espana EM, Liu DT, et al. Correlation of corneal complications with eyelid cicatricial pathologies in patients with Stevens-Johnson syndrome and toxic epidermal necrolysis syndrome. *Ophthalmology*. 2005;112:904–912.
- Ahmed M, Zein G, Khawaja F, Foster CS. Ocular cicatricial pemphigoid: pathogenesis, diagnosis and treatment. *Prog Retin Eye Res*. 2004;23:579–592.
- Holbach LM. Diseases of the eyelid-conjunctival complex and corneal complications of lid disease. *Curr Opin Ophthalmol*. 1995;6:39–43.
- Cher I. Blink-related microtrauma: when the ocular surface harms itself. *Clin Experiment Ophthalmol*. 2003;31:183–190.
- Dart J. Cicatricial pemphigoid and dry eye. *Semin Ophthalmol*. 2005;20:95–100.
- Saw VP, Dart JK. Ocular mucous membrane pemphigoid: diagnosis and management strategies. *Ocul Surf*. 2008;6:128–142.
- Kheirkhah A, Casas V, Sheha H, Raju VK, Tseng SC. Role of conjunctival inflammation in surgical outcome after amniotic membrane transplantation with or without fibrin glue for pterygium. *Cornea*. 2008;27:56–63.
- Sobolewska B, Deuter C, Zierhut M. Current medical treatment of ocular mucous membrane pemphigoid. *Ocul Surf*. 2013;11:259–266.
- Tsubota K, Satake Y, Ohyama M, et al. Surgical reconstruction of the ocular surface in advanced ocular cicatricial pemphigoid and Stevens-Johnson syndrome. *Am J Ophthalmol*. 1996;122:38–52.
- Pullum KW, Whiting MA, Buckley RJ. Scleral contact lenses: the expanding role. *Cornea*. 2005;24:269–277.
- Liu J, Sheha H, Fu Y, Liang L, Tseng SC. Update on amniotic membrane transplantation. *Expert Rev Ophthalmol*. 2010;5:645–661.
- Chen H-J, Pires RTF, Tseng SC. Amniotic membrane transplantation for severe neurotrophic corneal ulcers. *Br J Ophthalmol*. 2000;84:826–833.
- Prabhasawat P, Tesavibul N, Komolsuradej W. Single and multilayer amniotic membrane transplantation for persistent corneal epithelial defect with and without stromal thinning and perforation. *Br J Ophthalmol*. 2001;85:1455–1463.
- Lee SH, Tseng SC. Amniotic membrane transplantation for persistent epithelial defects with ulceration. *Am J Ophthalmol*. 1997;123:303–312.
- Kruse FE, Rohrschneider K, Völcker HE. Multilayer amniotic membrane transplantation for reconstruction of deep corneal ulcers. *Ophthalmology*. 1999;106:1504–1511.
- Hanada K, Shimazaki J, Shimmura S, Tsubota K. Multilayered amniotic membrane transplantation for severe ulceration of the cornea and sclera. *Am J Ophthalmol*. 2001;131:324–331.
- Solomon A, Meller D, Prabhasawat P, et al. Amniotic membrane grafts for nontraumatic corneal perforations, descemetocelles, and deep ulcers. *Ophthalmology*. 2002;109:694–703.
- Rodriguez-Ares MT, Tourino R, Lopez-Valladares MJ, Gude F. Multilayer amniotic membrane transplantation in the treatment of corneal perforations. *Cornea*. 2004;23:577–583.
- Kobayashi A, Yoshita T, Sugiyama K, et al. Amniotic membrane transplantation in acute phase of toxic epidermal necrolysis with severe corneal involvement. *Ophthalmology*. 2006;113:126–132.
- Meallet MA, Espana EM, Grueterich M, Ti SE, Goto E, Tseng SC. Amniotic membrane transplantation with conjunctival limbal autograft for total limbal stem cell deficiency. *Ophthalmology*. 2003;110:1585–1592.
- Tseng SC. Amniotic membrane transplantation for persistent corneal epithelial defect. *Br J Ophthalmol*. 2001;85:1400–1401.

22. Anderson DF, Ellies P, Pires RT, Tseng SC. Amniotic membrane transplantation for partial limbal stem cell deficiency. *Br J Ophthalmol*. 2001;85:567–575.
23. Huang YS, Tseng SG. Self-retained amniotic membrane transplantation for recurrent corneal erosion. *J Clin Exp Ophthalmol*. 2013;4:272.
24. Sheha H, Tighe S, Cheng AM, Tseng SC. Amniotic membrane transplantation. In: Ichhpujani P, Spaeth G, Yanoff M, eds. *Expert Techniques in Ophthalmic Surgery*. New Delhi, India: JAYPEE Publishers; 2015:167–175.
25. Sheha H, Liang L, Li J, Tseng SC. Sutureless amniotic membrane transplantation for severe bacterial keratitis. *Cornea*. 2009;28:1118–1123.
26. Kheirkhah A, Casas V, Raju VK, Tseng SC. Sutureless amniotic membrane transplantation for partial limbal stem cell deficiency. *Am J Ophthalmol*. 2008;145:787–794.
27. Kobayashi A, Shirao Y, Yoshita T, et al. Temporary amniotic membrane patching for acute chemical burns. *Eye*. 2003;17:149–158.
28. Prabhasawat P, Tseng SC. Frequent association of delayed tear clearance in ocular irritation. *Br J Ophthalmol*. 1998;82:666–675.
29. Ciralsky JB, Chapman KO, Rosenblatt MI, et al. Treatment of refractory persistent corneal epithelial defects: a standardized approach using continuous wear PROSE therapy. *Ocul Immunol Inflamm*. 2015;23:219–224.
30. He H, Li W, Tseng DY, et al. Biochemical characterization and function of complexes formed by hyaluronan and the heavy chains of inter-alpha-inhibitor (HC*HA) purified from extracts of human amniotic membrane. *J Biol Chem*. 2009;284:20136–20146.
31. Zhang S, He H, Day AJ, Tseng SC. Constitutive expression of inter-alpha-inhibitor (IalphaI) family proteins and tumor necrosis factor-stimulated gene-6 (TSG-6) by human amniotic membrane epithelial and stromal cells supporting formation of the heavy chain-hyaluronan (HC-HA) complex. *J Biol Chem*. 2012;287:12433–12444.
32. Blom AM, Morgelin M, Oyen M, Jarvet J, Fries E. Structural characterization of inter-alpha-inhibitor. Evidence for an extended shape. *J Biol Chem*. 1999;274:298–304.
33. Zhuo L, Hascall VC, Kimata K. Inter-alpha-trypsin inhibitor, a covalent protein-glycosaminoglycan-protein complex. *J Biol Chem*. 2004;279:38079–38082.
34. Shay E, He H, Sakurai S, Tseng SC. Inhibition of angiogenesis by HC.HA, a complex of hyaluronan and the heavy chain of inter-alpha-inhibitor, purified from human amniotic membrane. *Invest Ophthalmol Vis Sci*. 2011;52:2669–2678.
35. He H, Zhang S, Tighe S, Son J, Tseng SC. Immobilized heavy chain-hyaluronic acid polarizes lipopolysaccharide-activated macrophages toward m2 phenotype. *J Biol Chem*. 2013;288:25792–25803.
36. He H, Tan Y, Duffort S, Perez VL, Tseng SC. In vivo downregulation of innate and adaptive immune responses in corneal allograft rejection by HC-HA/PTX3 complex purified from amniotic membrane. *Invest Ophthalmol Vis Sci*. 2014;55:1647–1656.
37. Tseng SC. HC-HA/PTX3 purified from amniotic membrane as novel regenerative matrix: insight into relationship between inflammation and regeneration. *Invest Ophthalmol Vis Sci*. 2016;57:ORSFh1-8.
38. Tseng SC, He H, Zhang S, Chen SY. Niche Regulation of limbal epithelial stem cells relationship between inflammation and regeneration. *Ocul Surf*. 2016;14:100–112.
39. Cooke M, Tan EK, Mandrycky C, He H, O'Connell J, Tseng SC. Comparison of cryopreserved amniotic membrane and umbilical cord tissue with dehydrated amniotic membrane/chorion tissue. *J Wound Care*. 2014;23:465–476.
40. Tan EK, Cooke M, Mandrycky C, et al. Structural and biological comparison of cryopreserved and fresh amniotic membrane tissues. *J Biomater Tissue Eng*. 2014;4:379–388.
41. Shay E, Khadem JJ, Tseng SC. Efficacy and limitation of sutureless amniotic membrane transplantation for acute toxic epidermal necrolysis. *Cornea*. 2010;29:359–361.
42. Chen SY, Han B, Zhu YT, et al. HC-HA/PTX3 purified from amniotic membrane promotes bmp signaling in limbal niche cells to maintain quiescence of limbal epithelial progenitor/stem cells. *Stem Cells*. 2015;33:3341–3355.
43. Kaya S, Schmidl D, Schmetterer L, et al. Effect of hyaluronic acid on tear film thickness as assessed with ultra-high resolution optical coherence tomography. *Acta Ophthalmol*. 2015;93:439–443.
44. Liang L, Sheha H, Fu Y, Liu J, Tseng SC. Ocular surface morbidity in eyes with senile sunken upper eyelids. *Ophthalmology*. 2011;118:2487–2492.