

An Endovascular Cannulation Needle with an Internal Wire for the Fragmentation of Thrombi in Retinal Vein Occlusion

Tetsu Asami^{1,2}, Hiroki Kaneko¹, Kensaku Miyake², Ichiro Ota², Goichiro Miyake², Seiichi Kato³, Shunsuke Yasuda¹, Takeshi Iwase¹, Yasuki Ito¹, and Hiroko Terasaki¹

¹ Department of Ophthalmology, Nagoya University Graduate School of Medicine, Nagoya, Japan

² Miyake Eye Hospital, Nagoya, Japan

³ Department of Pathology and Laboratory Medicine, Nagoya University Hospital, Nagoya, Japan

Correspondence: Tetsu Asami, Department of Ophthalmology, Nagoya University Graduate School of Medicine, 65 Tsuruma-cho, Showa-ku, Nagoya, Aichi 466-8550, Japan. e-mail: asamit325@yahoo.co.jp

Received: 21 March 2016

Accepted: 2 August 2016

Published: 30 September 2016

Keywords: endovascular cannulation; branch retinal vein occlusion; recanalization; thrombus; internal wire; clot fragmentation; vitrectomy

Citation: Asami T, Kaneko H, Miyake K, Ota I, Miyake G, Kato A, Yasuda S, Iwase T, Ito Y, Terasaki H. An endovascular cannulation needle with an internal wire for the fragmentation of thrombi in retinal vein occlusion. *Trans Vis Sci Tech.* 2016; 5(5):9, doi:10.1167/tvst.5.5.9

Purpose: We report a newly developed device to fragment thrombi in retinal vein occlusion.

Methods: The new instrument consists of a 23-gauge (G) pipe and a 37-G needle with an internal wire. A total of 40 porcine eyes were used; 20 eyes for experiments in the branch retinal vein (BRV group) and 20 eyes for experiments in the central retinal vein (CRV group). We placed 25-G 3-port trocars, and core vitrectomy was performed. Another 23-G scleral incision was performed for insertion of the needle. The needle pierced the retinal vein at a distance of three- to four- or one-disc diameters from the optic disc (BRV or CRV group, respectively), and the internal wire was advanced toward the disc. The success rates of needle piercing and cannulation of the internal wire were recorded in each group. In the CRV group, the cannulation was deemed successful when the tip reached inside the optic disc. Real-time optical coherence tomography imaging also was performed using the Zeiss Rescan 700 device in porcine eyes. Histologic examination of the retinal vessel inserted with the internal wire was performed.

Results: The success rates of needle piercing into the BRV and CRV were 85% and 95%, respectively. The success rates of cannulation of the internal wire into the BRV and CRV were 85% and 0%, respectively. The process of cannulation was recorded successfully with the Rescan 700. Histologic examination showed no damages to the endothelial cell layer.

Conclusions: The needle and internal wire intended to be used for recanalization of BRV occlusion were successfully pierced and cannulated into the BRV.

Translational Relevance: This newly developed device could become a treatment modality for retinal vein occlusion to fragment thrombi that present treatment methods cannot reach and remove directly.

Introduction

Retinal vein occlusions are one of the most common causes of vision impairment. They can be divided into two categories according to the site in which the retinal vessel is occluded: branch retinal vein (BRV) and central retinal vein (CRV) occlusions. The occlusion of a BRV occurs commonly at the arteriovenous (A/V) crossing sites, and occlusion of the CRV occurs at the lamina cribrosa of the optic disc.¹ The pathogenesis of a retinal vein occlusion follows the principles of Virchow's triad for thrombogenesis: vessel damage, stasis, and hypercoagula-

bility. Damage to the endothelial layer of the retinal vessel by atherosclerosis changes the rheological properties near the adjacent vein, leading to the formation of thrombus.² Thus, the bent portions of the vessel are the sites that most frequently suffer occlusion.

There have been many attempts to treat the vein obstruction and subsequent macular edema, including intravitreal injection of triamcinolone acetonide^{3,4} and intravitreal injection of antivascular endothelial growth factor agents, such as ranibizumab⁵⁻⁸ and aflibercept.⁹ However, these treatment modalities are directed mainly to macular edema

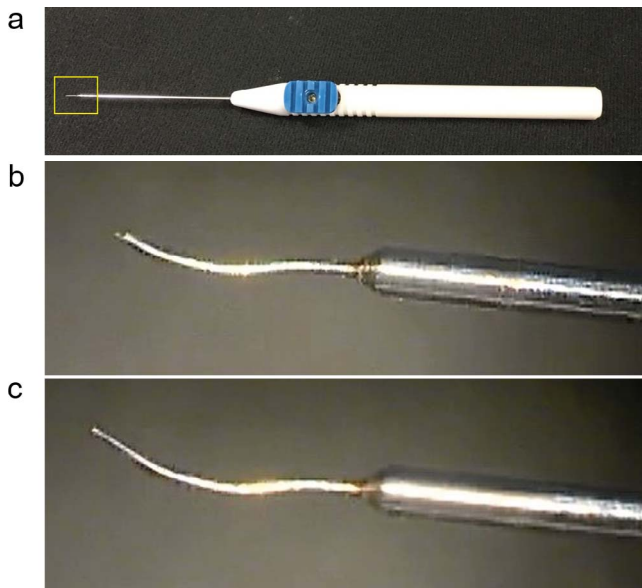


Figure 1. Characteristics of an endovascular cannulation needle. (a) Image of the device. The handgrip has a projection on the side and a 23-G pipe, which can be inserted through a sclerotomy site. (b) Close-up view of the *square* in Figure 1a. A 37-G needle is attached on the tip of the 23-G pipe. (c) An internal 100- μ m wire is thrust out of the 37-G needle.

resulting from the vein obstruction, and their effects sometimes are temporary. Surgical treatments have been attempted, such as surgical decompression of A/V crossing by sheathotomy for BRV occlusion¹⁰ and radial optic neurotomy for CRV occlusion.^{11,12} However, these treatment modalities have shown limited success because intravascular clots cannot be removed directly, and, in some cases, there have been severe complications.^{13–15} Recently, more direct approaches to the clot in the retinal vein have been attempted, such as intravascular injection of tissue plasminogen activator (tPA) into the retinal vein using a microneedle,^{16,17} microglass pipette,^{18–23} and a polyimide 44-gauge (G) cannula.²⁴ However, whether it is possible to use the direct injection method to remove the thrombus in the vein remains to be proved, because resolution of the intraretinal hemorrhage after surgery may be observed even during the natural course of the disease. To overcome these issues, we developed an instrument with a 37-G needle and an internal wire that can be inserted into the retinal vein to directly fragment the thrombus from the vein. In this study, we introduced this instrument and demonstrated its performance in porcine eyes.




Figure 2. Images of scanning electron microscopy of the tip of the 37-G needle. (a) The tip of the needle has a sharp edge. (b) The surface of the internal wire is smooth and has a dull edge to avoid any damage to the endothelial cells of the vessels.

Materials and Methods

Characteristics of an Endovascular Cannulation Needle for BRV Occlusion

This 23-G instrument is attached with a 37-G needle (Fig. 1a). An internal 100 μ m solid metal wire, made of nitinol (a shape memory alloy; a material that remembers its original shape), is slid inside the needle and can be thrust out of the 37-G needle with a projection on the side of the instrument sliding toward the needle (Figs. 1b, 1c). The 37-G needle is soft, and the angle can be adjusted along with the curved surface of the fundus (Figs. 1b, 1c).

Observation of the Endovascular Cannulation Needle with Scanning Electron Microscopy

The tip of the instrument was coated with osmium tetroxide using osmium plasma coater (NL-OPC80NS; Nippon Laser & Electronics Lab, Nagoya, Japan), and the tip was observed and photographed using scanning electron microscopy (JSM-7610F; JEOL Ltd., Tokyo, Japan; Fig. 2).

Animal Use and Surgical Technique

We used 40 enucleated porcine eyes to test the ability of the catheter for piercing the vessel and cannulation of the internal wire. The porcine eyes, not a model for BRV occlusion, were delivered and used within 12 hours of enucleation. We placed 25-G 3-port trocars, and core vitrectomy was performed. Another incision was made on the right side using V-lance without placing the trocar because the bent shape of the instrument prevented itself from being introduced through the trocar.

The eyes were divided into two groups; one in which the instrument was intended to be inserted into a BRV (BRV group; 20 eyes) and another in which the instrument was intended to be inserted into a CRV (CRV group; 20 eyes). In the BRV group, the needle pierced the BRV at a distance of three to four disc diameters from the optic disc, distal to or at the bifurcation of the retinal vein, and the internal wire then was intended to be cannulated toward the disc inside the vein. In the CRV group, the needle pierced the BRV at a distance of one disc diameter from the optic disc, and the internal wire then was cannulated toward the disc, with an attempt to guide it into the central vein of the optic disc. These procedures were performed manually, and the instrument was held with one hand. The success of the needle piercing was defined when the tip of the needle pierced the vessel wall, and the success of the cannulation of the internal wire was defined when the elongated wire was cannulated inside the vessel, particularly in the CRV group, when the internal wire reached the vessel inside the optic disc. The success rate of the needle piercing of the vessel wall and cannulation of the internal wire into the vessels in each group was evaluated.

After the procedures had been performed, the retina from an eye of the BRV group was examined histopathologically. The retina was trimmed to a size of 3×5 mm with a blade, including the vessels from the piercing site to the optic disc. The specimen was fixed in 10% formalin neutral buffer solution, gradually dehydrated, and embedded in paraffin. The retinal vessel in which the internal wire was inserted was sectioned transversely and the sections were mounted every 300 μ m. Hematoxylin-eosin staining was performed and the sections were observed and photographed by an Olympus microscope (BX50; Olympus, Tokyo, Japan).

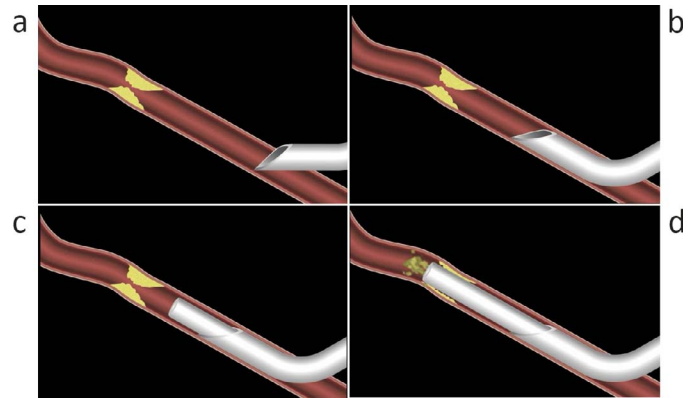


Figure 3. Illustration of the process in which the needle and wire are inserted into a vessel and how the thrombus is fragmented. (a) The 37-G needle pierces the vessel. (b) The tip of the needle is inserted into the vessel. (c) The internal wire is thrust out of the needle and advances toward the thrombus. (d) The thrombus is fragmented with the wire.

Illustration of the Procedure of Thrombus Fragmentation with the Instrument in a Retinal Vessel

Figure 3 illustrates a hypothetical process of clot fragmentation with this instrument. The 37-G needle pierces the vessel wall (Fig. 3a), and the cutting plane is placed entirely inside the vessel (Fig. 3b). Then, the internal wire is protruded toward the clot (Fig. 3c) and chips the clot off from the vessel wall (Fig. 3d). Finally, the fragment of the clot is washed away (Fig. 3d).

Real-Time Optical Coherence Tomography (OCT)

Real-time OCT imaging was performed using a microscope-integrated spectral domain OCT (Zeiss Opmi Lumera 700 and Zeiss Rescan 700; Carl Zeiss Meditec, Jena, Germany) in the porcine cadaver eyes. After three-port core vitrectomy had been performed, the process of piercing the vessel with the needle and the cannulation of the internal wire was recorded.

Results

The BRVs were pierced successfully with the 37-G needle after overcoming a slight resistance, and the internal wire was cannulated into the vein (Fig. 4). The success rate of needle piercing in the BRV group was 17/20 eyes (85%) and that of cannulation of the internal wire in the same group was 17/20 eyes (85%). On the other hand, the success rate of needle piercing

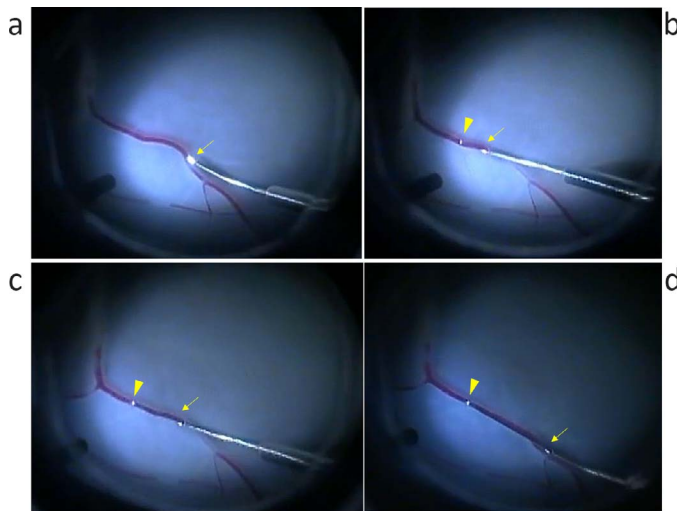


Figure 4. Process of insertion of the needle and the internal wire during 23-G three-port vitrectomy in a postmortem porcine eye (*arrow* shows tip of the needle, *arrowhead* shows tip of the internal wire). (a) The tip of the 37-G needle pierces the retinal vein. (b) The internal wire is thrust out of the needle. (c, d) The wire is prolonged toward the bifurcation of the retinal vein.

in the CRV group was 19/20 (95%) and that of cannulation of the internal wire in the same group was 0/20 (0%; [Table 1](#)).

The scanning electron microscopy images showed that the angle of the cutting plane of the needle from the axis of the needle was 30°, sharp enough to pierce the vessel wall ([Fig. 2a](#)). The tip of the internal wire has a flat surface with a dull edge that prevents damage to the endothelial cell of the vessel wall ([Fig. 2b](#)).

[Figure 4](#) demonstrates the process of piercing the retinal vein with the needle and the cannulation with the internal wire in a porcine cadaver eye. The tip of the needle approached the BRV and pierced the vein with a little resistance but without damaging the surrounding retina ([Fig. 4a](#)). After the tip of the needle was inserted, the surgeon held the grip of the instrument without any significant movement and then projected the internal wire into the vein by

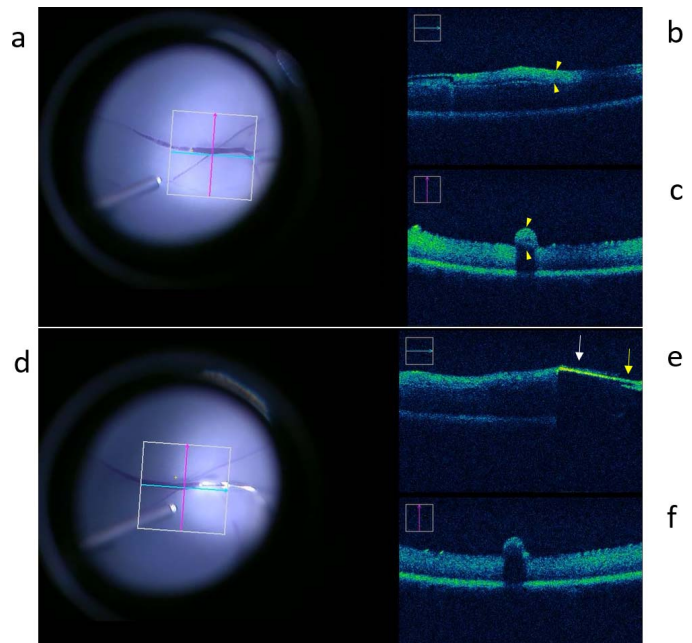


Figure 5. Real-time OCT images of a microscope-integrated spectral domain OCT (Zeiss Rescan 700). The images of a normal retinal vein (a–c). The *blue* and *red* arrows in the images indicate where the OCT is scanning (a). Longitudinal (b) and transverse (c) scans show a retinal vessel on the retina as a clearly distinct and protruded structure (*arrowhead*). The images of the process of the cannulation (d–f) show an internal wire ([e], *white arrow*) and a needle ([e], *yellow arrow*) inserted in the retinal vessel as an object with a high reflection and acoustic shadow.

sliding the projection on the side of the grip ([Fig. 4b](#)). The internal wire was prolonged and advanced toward the optic disc without any distortion of the vein during the procedure ([Figs. 4c, 4d](#); see [Supplementary Video](#)).

Real-time OCT images using the Rescan 700 device showed a retinal vein ([Fig. 5a](#)) as a protrusion from the retinal surface in longitudinal ([Fig. 5b](#)) and transverse ([Fig. 5c](#)) sections. The process of cannulation was recorded successfully ([Fig. 5d](#)), and the wire was shown as an object with a high reflection and

Table. The Success Rate of Piercing of the Needle into the Retinal Vein and Cannulation of the Internal Wire

Target Vessel	Number of Successful Procedure	
	Piercing of the Needle	Cannulation of the Internal Wire
Branch retinal vein, $n = 20$	17 (85%) ^a	17 (85%)
Central retinal vein, $n = 20$	19 (95%) ^b	0 (0%)

^a Piercing of the needle was performed on the branch retinal vein 3 to 4 disc diameters from the optic disc, distal to or at the bifurcation of the retinal vein.

^b Piercing of the needle was performed on the branch retinal vein near the optic disc.

acoustic shadow (Fig. 5e; white arrow) thrusting out of the needle (Fig. 5e; yellow arrow).

Histopathologic examination revealed that the endothelial layer of the retinal vessels in 8 sections in which the internal wire was inserted was not damaged. The representative Figure is shown in Figure 6.

Discussion

A newly developed endovascular cannulation device demonstrated successful piercing and cannulation of BRVs in postmortem porcine eyes. On the other hand, the internal wire was difficult to be cannulated into CRVs in the optic disc.

The success rate of needle piercing was higher in the CRV group than that in the BRV group. One reason is that the piercing site was closer to the optic disc in the CRV group than in the BRV group; that is, the diameter of the vessels was larger near the optic disc than in peripheral veins, which might allow the needle to be inserted into the vessels. Another reason is that some porcine cadaver eyes, even fresh ones, had developed retinal detachment, making it difficult to pierce the vessels with the needle. In the CRV group, the piercing site was closer to the optic disc, which acts like a tethering anchor allowing easier piercing. To improve the success rate in the BRV group, the cutting edge of the needle probably had to be sharper to reduce the resistance during piercing.

In the CRV group, the internal wire inserted in the retinal vein could not progress to the CRV at the edge of the optic disc where the vessel was bent. The wire used in this study is made of nitinol, a shape memory alloy, and despite being soft and flexible, it could not reach the CRV in the optic disc. A histopathologic study of CRV occlusion patients has revealed a thrombus in the region of the lamina cribrosa.¹ If the tip of the internal wire was much more flexible and reached that site, it could fragment the clot there and could restore the retinal venous outflow. Therefore, the instrument currently is undergoing further improvements.

Insertion of the 37-G needle into the retinal vein requires stability of the surgeon's hand and the patient's eye. Furthermore, the internal wire is thrust out of the 37-G needle by sliding the projection on the side of the instrument with the surgeon's thumb, requiring fine manipulation. A tremor of the surgeon's hand and an eye movement may lead to an unsuccessful attempt. Therefore, to enhance the success rate of needle piercing and cannulation of

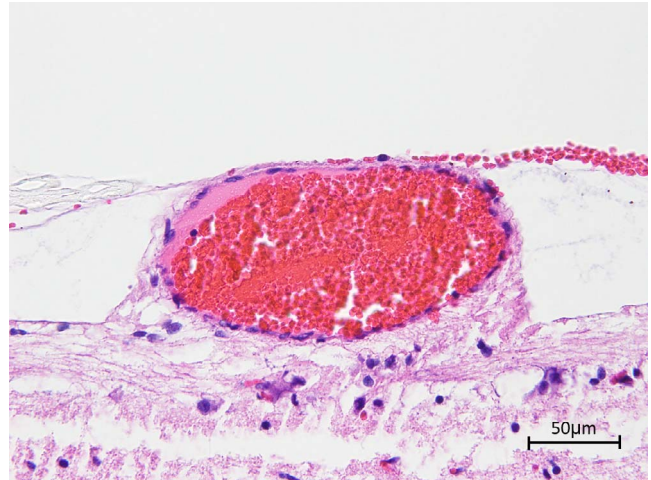

Figure 6. Histopathologic examination of the retinal vein in which the internal wire was inserted. The microscopic image shows no visible damage to the endothelium of the vessel. Scale bar: 50 μ m.

the internal wire, an auxiliary device, such as a robot-assisted ophthalmic surgery device,²⁵ may be helpful to reduce the tremor of the surgeon's hand, and retrobulbar anesthesia may be helpful to reduce eye movement.

The process of thrombus formation in coronary arteries is considered to be a gradual constriction of the arterial lumen due to atherosclerosis. However, the actual process has been revealed; in this process, the lipid plaque is covered by an endothelial cell layer at first. When the layer breaks, the lipid plaques are exposed to blood. Thereafter, the platelets aggregate at the site and result in the formation of a thrombus.²⁶ This process of thrombus formation in the coronary arteries may be applied in the understanding of clot formation of BRV and CRV occlusions. In this theory, rheological properties might change because of the damage of the endothelial layer at the A/V crossing site² or at the lamina cribrosa. Recently, Muraoka et al.²⁷ reported that the retinal vein seems to curve and run deep beneath the artery at the A/V crossing site and that intravenous thrombi are detected downstream of the A/V crossing. When the wire is inserted intravenously, it must reach beyond the A/V crossing through the curve of the vessel. Therefore, it should be soft enough to advance along its curve and stiff enough to hold its shape even in crooked vessels. The width of the internal wire of our instrument is 100 μ m, which makes it easy to cannulate into the BRV. The wire is made of nitinol, a shape memory alloy, and it is soft and easily bent with a slight force,

restoring then to its original state. The tip of the internal wire has a slight round shape and no sharp edges to prevent damage to the endothelial layer of the vessel. This is an advantage of this instrument. Although our results demonstrated that this device did not cause any damage to the endothelial layer, there still is a possibility that it could damage the vessel. Furthermore, if the original damage of the endothelial layer persists even after the thrombus is removed with this instrument, there is a possibility of the recanalized vessel occluding after a while. However, even if it reoccludes, the thrombus that would deteriorate the retinal tissue permanently should be removed even temporarily. In addition, there is one more possibility that the fragments of the clot could occlude the vessels downstream.

Several attempts have been made to treat BRV and CRV occlusions with endovascular methods. A major concept of endovascular surgery has been the injection of tPA into retinal vessels by different methods of administration. Attempts to inject tPA into CRV with a glass pipette have been reported.^{18–23,28} The outer diameter of the glass micropipette was 40 to 50 μm ,²³ which is sufficiently small to be inserted into retinal veins. However, the glass pipette may have some disadvantages because the pipette is fragile and transparent, offering poor visibility of the pipette and damage to the vessel walls due to the bluntness of the pipette.¹⁶ This would be a limitation of this method. A microneedle with an outer diameter of 40 to 50 μm also has been developed and has shown an excellent success rate for microvascular piercing and intravascular injection of tPA.¹⁶ This needle seems to be a feasible method for stably injecting tPA because the needle is considered stiffer and able to withstand a high pressure during the injection. Tameesh et al.²⁴ have reported an intravascular cannulation system for injection of tPA into retinal veins. This system consists of a hybrid of two different sizes of polyimide cannulas: a 26-G polyimide tube housing a 44-G polyimide tube with a glass tip, which is inserted intravenously and can be cannulated close to the thrombi.

Attempts to inject tPA into retinal veins in BRV or CRV occlusions seem to have limitations. Just after the onset of the occlusion, the thrombi in retinal veins consist only of aggregated platelets and fibrin, and can be lysed by tPA. However, the thrombus becomes organized into a chronic fibrotic occlusion several weeks to several months after the occlusion and may not dissolve easily with tPA anymore.²⁶ Another limitation is that if the occlusion by the thrombi is complete, the tPA injected downstream to the

occluded lesion may not reach the portion responsible for the occlusion unless the pressure of the injection is extremely high. The needle must be small to allow injection into retinal vessels. However, the smaller the needle, the more difficult it is to produce high pressure during the injection. Considering all these demerits, we believe that our method has great merits because it physically fragments the thrombus. On the other hand, cannulation with our device seems to have a limitation. Because most BRV and CRV occlusions are temporal and recanalize spontaneously at the time of diagnosis, our treatment modality might be useless in those cases. In addition, another limitation would be that as the enucleated porcine eyes we used were not a model for retinal vein occlusion, we could not have direct evidence that the device we developed could actually fragment the clots.

The histopathologic examination in this study revealed that the endothelial layer of the retinal vessels was not damaged. We used postmortem porcine eyes that were fixed just after the experiment. To verify that the internal wire does not damage the endothelial layer, a time-course experiment might be necessary in live animals. Thus, this is a limitation of this study.

In conclusion, this instrument may become a feasible treatment modality for BRV occlusion and has a possibility to become useful for CRV occlusion if the tip of the wire is modified.

Acknowledgments

The authors thank Gaku Yasuda of Miyake Eye Hospital for his technical support of drawing an illustration, and Koji Itakura, technical staff of Division for Medical Research Engineering, Nagoya University Graduate School of Medicine, for his technical support of electron microscopy.

Tetsu Asami has applied for patent rights on this instrument in Japan (No. 2016-018614) on February 3, 2016 and will apply for a patent in the United States, claiming priority based on the patent application in Japan.

References

1. Green WR, Chan CC, Hutchins GM, Terry JM. Central retinal vein occlusion: a prospective histopathologic study of 29 eyes in 28 cases. *Trans Am Ophthalmol Soc.* 1981;79:371–422.

2. Wong TY, Scott IU. Clinical practice. Retinal-vein occlusion. *N Engl J Med*. 2010;363:2135–2144.
3. Scott IU, Ip MS, VanVeldhuisen PC, et al. A randomized trial comparing the efficacy and safety of intravitreal triamcinolone with standard care to treat vision loss associated with macular edema secondary to branch retinal vein occlusion: the Standard Care vs Corticosteroid for Retinal Vein Occlusion (SCORE) study report 6. *Arch Ophthalmol*. 2009;127:1115–1128.
4. Scott IU, VanVeldhuisen PC, Oden NL, et al. Baseline characteristics and response to treatment of participants with hemiretinal compared with branch retinal or central retinal vein occlusion in the standard care vs corticosteroid for retinal vein occlusion (SCORE) study: SCORE study report 14. *Arch Ophthalmol*. 2012;130:1517–1524.
5. Campochiaro PA, Heier JS, Feiner L, et al. Ranibizumab for macular edema following branch retinal vein occlusion: six-month primary end point results of a phase III study. *Ophthalmology*. 2010;117:1102–1112.
6. Brown DM, Campochiaro PA, Bhisitkul RB, et al. Sustained benefits from ranibizumab for macular edema following branch retinal vein occlusion: 12-month outcomes of a phase III study. *Ophthalmology*. 2011;118:1594–1602.
7. Heier JS, Campochiaro PA, Yau L, et al. Ranibizumab for macular edema due to retinal vein occlusions: long-term follow-up in the HORIZON trial. *Ophthalmology*. 2012;119:802–809.
8. Varma R, Bressler NM, Suñer I, et al. Improved vision-related function after ranibizumab for macular edema after retinal vein occlusion: results from the BRAVO and CRUISE trials. *Ophthalmology*. 2012;119:2108–2118.
9. Clark WL, Boyer DS, Heier JS, et al. Intravitreal aflibercept for macular edema following branch retinal vein occlusion: 52-week results of the VIBRANT study. *Ophthalmology*. 2016;123:330–336.
10. Opremcak EM, Bruce RA. Surgical decompression of branch retinal vein occlusion via arteriovenous crossing sheathotomy: a prospective review of 15 cases. *Retina*. 1999;19:1–5.
11. Opremcak EM, Bruce RA, Lomeo MD, Ridenour CD, Letson AD, Rehmar AJ. Radial optic neurotomy for central retinal vein occlusion: a retrospective pilot study of 11 consecutive cases. *Retina*. 2001;21:408–415.
12. Aggermann T, Brunner S, Krebs I, et al. A prospective, randomised, multicenter trial for surgical treatment of central retinal vein occlusion: results of the Radial Optic Neurotomy for Central Vein Occlusion (ROVO) study group. *Graefes Arch Clin Exp Ophthalmol*. 2013;251:1065–1072.
13. Schneider U, Inhoffen W, Grisanti S, Bartz-Schmidt KU. Characteristics of visual field defects by scanning laser ophthalmoscope microperimetry after radial optic neurotomy for central retinal vein occlusion. *Retina*. 2005;25:704–712.
14. Schneider U, Inhoffen W, Grisanti S, Völker M, Bartz-Schmidt KU. Chorioretinal neovascularization after radial optic neurotomy for central retinal vein occlusion. *Ophthalmic Surg Lasers Imaging*. 2005;36:508–511.
15. Maia M, Farah ME, Aggio FB, Rodrigues EB, de Souza EC, Magalhães O Jr. Peripapillary haemorrhagic retinal pigment epithelium detachment following radial optic neurotomy. *Clin Experiment Ophthalmol*. 2007;35:672–674.
16. Kadonosono K, Arakawa A, Yamane S, Uchio E, Yanagi Y. An experimental study of retinal endovascular surgery with a microfabricated needle. *Invest Ophthalmol Vis Sci*. 2011;52:5790–5793.
17. Kadonosono K, Yamane S, Arakawa A, et al. Endovascular cannulation with a microneedle for central retinal vein occlusion. *JAMA Ophthalmol*. 2013;131:783–786.
18. Bynoe LA, Weiss JN. Retinal endovascular surgery and intravitreal triamcinolone acetonide for central vein occlusion in young adults. *Am J Ophthalmol*. 2003;135:382–384.
19. Bynoe LA, Hutchins RK, Lazarus HS, Friedberg MA. Retinal endovascular surgery for central retinal vein occlusion: initial experience of four surgeons. *Retina*. 2005;25:625–632.
20. Feltgen N, Junker B, Agostini H, Hansen LL. Retinal endovascular lysis in ischemic central retinal vein occlusion: one-year results of a pilot study. *Ophthalmology*. 2007;114:716–723.
21. Feltgen N, Agostini H, Auw-Haedrich C, Hansen LL. Histopathological findings after retinal endovascular lysis in central retinal vein occlusion. *Br J Ophthalmol*. 2007;91:558–559.
22. Yamamoto T, Kamei M, Sakaguchi H, et al. Comparison of surgical treatments for central retinal vein occlusion; RON vs. cannulation of tissue plasminogen activator into the retinal vein. *Retina*. 2009;29:1167–1174.
23. Suzuki Y, Matsushashi H, Nakazawa M. In vivo retinal vascular cannulation in rabbits. *Graefes Arch Clin Exp Ophthalmol*. 2003;241:585–588.

24. Tameesh MK, Lakhanpal RR, Fujii GY, et al. Retinal vein cannulation with prolonged infusion of tissue plasminogen activator (t-PA) for the treatment of experimental retinal vein occlusion in dogs. *Am J Ophthalmol.* 2004;138:829–839.
25. Fine HF, Wei W, Goldman R, Simaan N. Robot-assisted ophthalmic surgery. *Can J Ophthalmol.* 2010;45:581–584.
26. Fuster V, Badimon L, Badimon JJ, Chesebro JH. The pathogenesis of coronary artery disease and the acute coronary syndromes (1). *N Engl J Med.* 1992;326:242–250.
27. Muraoka Y, Tsujikawa A, Murakami T, et al. Morphologic and functional changes in retinal vessels associated with branch retinal vein occlusion. *Ophthalmology.* 2013;120:91–99.
28. Tsilimbaris MK, Lit ES, D’Amico DJ. Retinal microvascular surgery: a feasibility study. *Invest Ophthalmol Vis Sci.* 2004;45:1963–1968.