

# Intravitreal Injection with a Conjunctival Injection Device: A Single-Center Experience

Yu Qiang Soh<sup>1</sup>, Nathalie Pei Yu Chiam<sup>1</sup>, Andrew Shih Hsiang Tsai<sup>1</sup>,  
Gemmy Chui Ming Cheung<sup>1-3</sup>, Tien Yin Wong<sup>1-3</sup>, Ian Yew San Yeo<sup>1-3</sup>,  
Edmund Yick Mun Wong<sup>1-3</sup>, and Anna Cheng Sim Tan<sup>1-3</sup>

<sup>1</sup> Singapore National Eye Centre, Singapore

<sup>2</sup> Singapore Eye Research Institute, Singapore

<sup>3</sup> Duke-NUS Medical School, Singapore

**Correspondence:** Anna C.S. Tan,  
Singapore National Eye Centre, 11  
Third Hospital Avenue, Singapore  
168751. e-mail:

[anna.tan.c.s@singhealth.com.sg](mailto:anna.tan.c.s@singhealth.com.sg)

**Received:** April 28, 2020

**Accepted:** June 5, 2020

**Published:** July 17, 2020

**Keywords:** InVitria; intravitreal;  
injection; surgery

**Citation:** Soh YQ, Chiam NPY, Tsai  
ASH, Cheung GCM, Wong TY, Yeo  
IYS, Wong EYM, Tan ACS. Intravitreal  
injection with a conjunctival  
injection device: A single-center  
experience. *Trans Vis Sci Tech.*  
2020;9(8):28,  
<https://doi.org/10.1167/tvst.9.8.28>

**Purpose:** To evaluate the clinical performance of the intravitreal injection assistant device (InVitria) compared with the conventional freehand technique for delivering intravitreal injections.

**Methods:** Seventy patients were randomized to receive intravitreal injections via the conventional freehand technique while 70 received injections using the InVitria. Half of all procedures in each group were performed by junior surgeons, while the rest were performed by senior surgeons.

**Results:** Mean injection times were  $90.0 \pm 23.3$  seconds and  $64.9 \pm 26.8$  seconds for conventional versus InVitria ( $P < 0.001$ ). Mean injection times with the conventional technique were  $85.5 \pm 23.0$  seconds vs.  $94.2 \pm 23.0$  seconds for senior versus junior surgeons ( $P = 0.120$ ). Mean injection times with the InVitria were  $56.1 \pm 26.1$  seconds vs.  $66.3 \pm 26.9$  seconds ( $P = 0.211$ ) for senior versus junior surgeons. There were no significant differences in pain scores regardless of technique (conventional versus In Vitria:  $2.03 \pm 1.73$  vs.  $2.13 \pm 2.20$ ,  $P = 0.770$ ).

**Conclusions:** In our experience, the InVitria is a comparable alternative to the conventional freehand technique of delivering intravitreal injections, with the potential for faster injection times and without compromising on patient comfort.

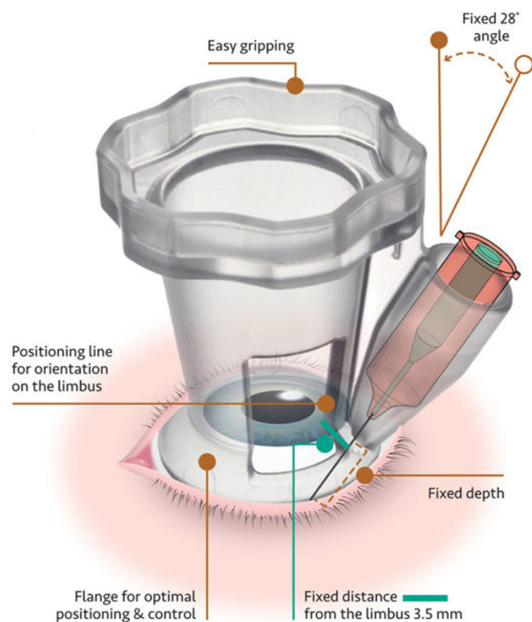
**Translational Relevance:** The study provides evidence to suggest that the InVitria may be deployed effectively in clinical practice.

## Introduction

Intravitreal anti-vascular endothelial growth factor (anti-VEGF) agents are the current standard of care for a large number of retinal pathologies. Diseases that can currently be treated with anti-VEGF injections include diabetic macular edema,<sup>1-3</sup> macular edema secondary to retinal vein occlusions,<sup>4</sup> polypoidal choroidal vasculopathy,<sup>5</sup> and choroidal neovascularization secondary to a myriad of causes such as age-related macular degeneration (AMD),<sup>6-8</sup> pathologic myopia,<sup>9</sup> and infectious and inflammatory conditions.<sup>10</sup> Intravitreal anti-VEGF injections have a growing number of indications, and intensive, long-

term treatment with repeated injections has been shown to optimize visual outcomes.<sup>11-13</sup> New indications for intravitreal injections and novel intravitreal therapies for retinal diseases,<sup>14</sup> in addition to the exponentially growing global disease burden of AMD<sup>6</sup> and diabetes,<sup>1</sup> will only add to the number of intravitreal injections performed globally. At our center, the annual number of intravitreal injections delivered has increased: 5995 in 2015, 8624 in 2016, and 10,918 in 2017, equivalent to an average annual growth of 35% (institutional audit data).

In most clinics and hospitals, intravitreal injections are performed in the outpatient clinic or in a semisterile procedure room. To service the increasing load of intravitreal injections, a large quantity of reusable



**Figure 1.** Schematic representation of the InVitria. Image obtained from manufacturer's website (<https://fci-ophthalmic.com/products/InVitria-intravitreal-injection-assistant>).

surgical instruments (e.g., measuring calipers, lid speculum) must be kept in stock to ensure there are sufficient instruments available for use daily. Reusable surgical instruments must also be cleaned and sterilized following each procedure. These requirements may reduce the overall cost-effectiveness of intravitreal injections.

The InVitria (FCI Ophthalmics, Pembroke MA, USA) is a device designed to assist ophthalmologists in the administration of intravitreal injections (Fig. 1).<sup>15</sup> The InVitria has been marketed based on manufacturer claims of potential advantages over the conventional method of intravitreal injection, chief among which includes greater predictability, ease of administration, and enhanced patient safety. As it is a single-use disposable device, there is no need for instrument cleaning and sterilization, leading to potential savings in costs and manpower.<sup>15</sup> A previous study reported a significantly lower visual analog pain score when the InVitria was used compared with the conventional freehand technique.<sup>15</sup> The authors also report ease of use of the InVitria, with good globe stability and a safe, reproducible entry site and angle of needle insertion.<sup>15</sup>

We hypothesized that the InVitria may be advantageous to the conventional freehand intravitreal injection technique, with faster injection times, lower patient-reported pain scores, and improved satisfaction and safety by the injecting doctor regardless of their expertise or prior experience. To test this hypothesis, we conducted a prospective randomized trial comparing intravitreal injections delivered via either the conven-

tional freehand technique or with the assistance of a single-use disposable device (InVitria) and to have the procedure performed by either a senior surgeon or a junior surgeon.

## Methods

This was a prospective and randomized pilot study comparing intravitreal injection via the conventional freehand method versus injection with assistance of the InVitria device.

## Ethics Statement

The following study was approved by the Singapore Health Services Centralized Institutional Review Board (R1195/1/2015). Informed consent was obtained from all patients prior to participation in the study. This study complied with the Health Insurance Portability and Accountability Act of 1996 and adhered to the tenets of the Declaration of Helsinki.

## Injection Methods

### Conventional Freehand Method

The patient's eyelids and periorbital skin were cleaned with 10% povidone iodine solution and the ocular surface with 5% povidone iodine solution. Following the application of sterile surgical drapes, the eyelids were retracted with a Barraquer lid speculum. Topical anesthetic (tetracaine hydrochloride 1.0%; Bausch and Lomb, New York, NY, USA) was applied to the ocular surface. The anti-VEGF agent was drawn into a 1-mL syringe attached to a 30-gauge needle. A trans-pars plana injection was administered at a distance of either 3.5 mm from the limbus for pseudophakic patients or 4 mm for phakic patients. Distances were marked out, via scleral indentation, with a measuring caliper. Following injection, a sterile cotton-tip applicator was used to tamponade the injection site to minimize vitreous reflux and hemorrhage.

### Alternate Method—InVitria

Cleaning, draping, and application of topical anesthesia were performed as per the conventional method. This method did not require the use of a lid speculum or measuring caliper. The InVitria device was placed onto the ocular surface, with its flanges resting on the perilimbal sclera. The device was then rotated to position the injection port and displace the conjunctiva. With its positioning line aligned with the corneal limbus, the injection port would have been 3.5 mm away

from the limbus. A 30-gauge needle was then inserted through the guide tube; this helped ensure trans-pars plana ocular penetration at a fixed angle of 28 degrees and injection depth of 5.6 mm. Following injection of the medication, the needle was withdrawn from the guide tube. The InVitria device was then rotated back to its horizontal position and gentle pressure was applied to exert a tamponade on the injection site via its flanges, prior to removal of the InVitria device.

## Medication and Device Type

Conventional and alternative injection techniques were used to administer a variety of intravitreal anti-VEGF agents: bevacizumab (Avastin, Genentech Inc., South San Francisco, CA, USA), ranibizumab (Lucentis; Roche Pharmaceuticals, Basel, Switzerland), or aflibercept (Eylea, Regeneron Inc., Tarrytown, NJ, USA). At our center, Avastin is compounded by a central pharmacy, followed by repackaging into multiple individual dosages, each stored under refrigeration, within a latex-free 1-mL luer slip syringe (Omnifix-F Luer Solo; B.Braun Melsungen AG, Melsungen, Germany). A 30 × 1/2-gauge (0.3 × 13-mm) needle (BD PrecisionGlide Needle; BD, Franklin Lakes, NJ, USA) was affixed to the 1-mL syringe via a luer slip mechanism prior to injection. Lucentis was supplied by the manufacturer (Roche Pharmaceuticals) in a prefilled syringe containing 0.5 mg ranibizumab, to which a 30 × 1/2-gauge (0.3 × 13-mm) needle (BD PrecisionGlide Needle; BD) was affixed with a luer slip mechanism prior to injection. Eylea was withdrawn from a sterile glass vial supplied by the manufacturer (Regeneron Inc., Tarrytown, NJ, USA) into a latex-free 1-mL luer slip syringe (Omnifix-F Luer Solo; B.Braun Melsungen AG), to which a 30 × 1/2-gauge (0.3 × 13-mm) needle (BD PrecisionGlide Needle; BD) was affixed with a luer slip mechanism prior to injection. The MW-200-P model of the InVitria device, designed to fit the model of the disposable needle used at our center (30-gauge 13-mm BD PrecisionGlide Needle; BD), was procured for the purpose of this study.

## Surgeon Selection

Intravitreal injections were administered by a total of eight junior surgeons and six senior surgeons. A junior surgeon is defined as either a clinical associate or a junior ophthalmology resident who has previously performed an average of approximately 20 injections. A senior surgeon is defined as either a senior ophthalmology resident or a fully qualified consultant ophthalmologist

who would have on average performed at least 100 injections prior to this study.

## Device Familiarization

All doctors randomized to perform intravitreal injections using InVitria had no previous experience with the device. Prior to performing the injection, they were required to view an instructional video from the device manufacturer (Medical Workshop, Groningen, The Netherlands), which demonstrated its salient features and proper methods of device handling. Following this, they were issued with a print-out from the manufacturers' website with details of the device's technical specifications (Fig. 1). All doctors were allowed hands-on experience with a sample device and opportunities to practice needle insertion into the guide tube without actual patient injection. No limits were imposed on time taken for device familiarization.

## Patient Selection

A total of 140 patients who were recommended to receive anti-VEGF intravitreal injections for retinal pathologies were recruited from the medical and surgical retina clinics in our institution from April 2015 to October 2016. Patients who had never received an intravitreal injection were excluded. Only patients who had prior intravitreal injections were recruited as we wanted to collect patient feedback on how the InVitria device compared with the previously used conventional injection technique. Patients who were noncommunicative, were unable to provide informed consent, and had previously undergone glaucoma filtration surgery (GFS) or glaucoma drainage device (GDD) insertion were not included in this study. Patients with GFS and GDD were excluded in view of risks of structural damage to the filtering blebs and drainage devices from the wide flanges of the InVitria device. Of the 140 patients, 70 received injections via the conventional technique, while the rest received injections with the InVitria device. Half of all procedures in each group were performed by junior surgeons, while the rest were performed by senior surgeons.

## Data Collected

### Time Taken for Injection

Time taken for completion of the intravitreal injection was measured by an independent observer. All doctors were requested to sterilize the ocular surface with 5% povidone iodine solution prior to scleral indentation with the measuring calipers (for the conventional method) or prior to placement of

the InVitria device on the ocular surface (if using InVitria). Timing would commence on contact of the ocular surface with 5% povidone iodine and cease upon complete withdrawal of the 30-gauge needle from the eye.

### Subjective Patient Indicators

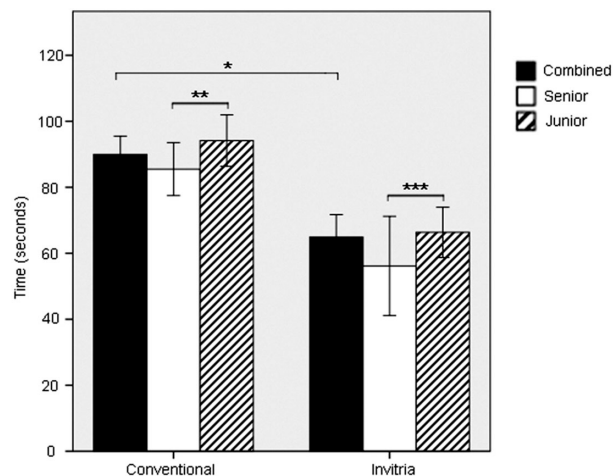
Intraoperative perceived pain was quantified using a visual analog scale (VAS) pain score (on a scale of 1–10), with greater pain associated with a higher VAS score. Patients on whom the InVitria device was used were also asked if they preferred the InVitria technique over the conventional technique of injection and reasons for their preferences. Postprocedural VAS pain scoring and subjective questioning were performed by an independent and blinded assessor immediately after the intravitreal injection following removal of the sterile drape and cleansing of iodine from the patient's eyelids.

### Surgeon Feedback

Surgeons who used the InVitria device were asked to provide open-ended feedback in regard to their perceptions on the ease of use of the InVitria and whether or not they thought the device was safe to use. They were asked if they would recommend InVitria to other patients and were also given the opportunity to provide suggestions for improvement in the design of the device.

### Statistical Method

Sample size estimation was based on time taken for injections. Preliminary findings indicated a surgical duration of approximately 65 seconds for InVitria and 80 seconds for the conventional method, with a  $\delta$  value of approximately 20 seconds. Assigning  $\alpha$ - and  $\beta$ -error values of 0.05 and 0.1, respectively, we would require at least 59 patients in each group. SPSS (version 18.0; SPSS, Inc., Chicago, IL, USA) was used for data analysis. One-way analysis of variance was performed to evaluate the effects of injection method and doctor group on patient satisfaction, pain score, and time taken for injection. Values were deemed to be significant when a significance level with a  $P$  value of less than 0.05 was achieved. Unless otherwise indicated, all numeric data obtained are expressed as mean  $\pm$  standard deviation.



**Figure 2.** Mean injections times were  $90.0 \pm 23.3$  and  $64.9 \pm 26.8$  seconds for conventional versus InVitria techniques respectively ( $*P < 0.001$ ). Mean injection times with the conventional technique were  $85.5 \pm 23.0$  vs.  $94.2 \pm 23.0$  seconds for senior versus junior surgeons, respectively ( $**P = 0.120$ ). With the InVitria, mean injection times for senior versus junior surgeons were  $56.1 \pm 26.1$  and  $66.3 \pm 26.9$  seconds, respectively ( $***P = 0.211$ ). Error bars represent 95% confidence intervals.

## Results

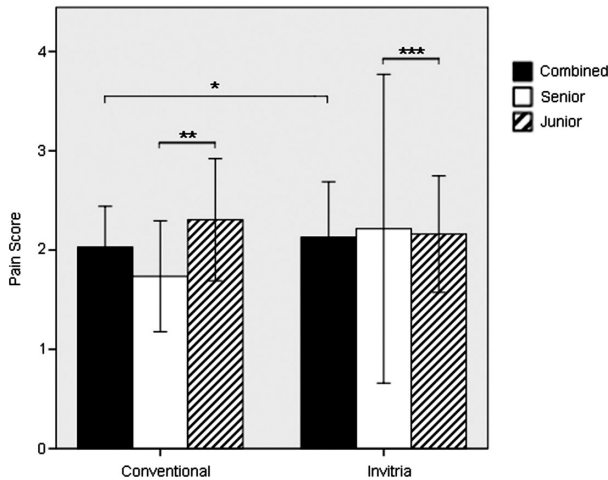
### Injection Times

Intravitreal injection times are summarized in Figure 2. Intravitreal injections could be administered faster with the assistance of the InVitria device compared with the conventional freehand method ( $64.9 \pm 26.8$  vs.  $90.0 \pm 23.3$  seconds,  $P < 0.001$ ). With the conventional freehand method, senior surgeons took an average of  $85.5 \pm 23.0$  seconds to deliver the injections, while junior surgeons took  $94.2 \pm 23.0$  seconds ( $P = 0.120$ ). Within the InVitria group, there was also no statistically significant difference in terms of the time taken for senior and junior surgeons to perform the injections ( $56.1 \pm 26.1$  and  $66.3 \pm 26.9$  seconds, respectively,  $P = 0.211$ ).

### Pain Score

VAS pain score findings are summarized in Figure 3. VAS pain score was low regardless of injection methods, and there were no differences in VAS pain score between the conventional freehand and InVitria injection methods ( $2.03 \pm 1.73$  vs.  $2.13 \pm 2.20$ , respectively,  $P = 0.770$ ). For both injection techniques, surgeon seniority did not appear to have any statistically significant effects on VAS pain score. In the conventional injection group, mean pain scores for injections delivered by senior and junior doctors were





**Figure 3.** VAS pain score findings. There were no significant differences in pain scores regardless of technique ( $2.03 \pm 1.73$  vs.  $2.13 \pm 2.20$ ,  $*P = 0.770$ ). In the conventional injection group, mean pain scores for injections delivered by senior and junior doctors were  $1.74 \pm 1.60$  vs.  $2.31 \pm 1.82$  ( $**P = 0.169$ ), respectively. In the InVitria group, mean pain scores for senior and junior doctors were  $2.21 \pm 2.69$  vs.  $2.16 \pm 2.06$  ( $***P = 0.936$ ), respectively. Error bars represent 95% confidence intervals.

$1.74 \pm 1.60$  vs.  $2.31 \pm 1.82$  ( $P = 0.169$ ), respectively. In the InVitria group, mean pain scores for senior and junior doctors were  $2.21 \pm 2.69$  vs.  $2.16 \pm 2.06$  ( $P = 0.936$ ), respectively.

## Patient Preferences

Of the 70 patients who received intravitreal injection using the InVitria device, 44 (62.9%) preferred the InVitria over the conventional freehand method of injection, 17 (24.3%) preferred the conventional freehand method over the InVitria, and 9 (12.9%) were equally satisfied with either method of injection. Among patients who preferred the InVitria, reasons cited for their preference included shorter procedure time ( $n = 5$ ) and greater comfort as a result of reduced manipulation of the eye ( $n = 4$ ). Among patients who preferred the conventional freehand method, the most commonly cited reason was that the InVitria flange (which was of a fixed diameter) felt excessively large, which contributed to discomfort as it was being manipulated in between the eyelids ( $n = 4$ ).

## Surgeon Feedback

Of the 14 surgeons who performed intravitreal injections with the InVitria device, 12 (86%) felt that the device was easy to use, 11 (78.6%) felt that it was a safe device to use, and 11 (78.6%) would actively recommend the device to their next patients. Surgeons

provided open-ended feedback following usage of the InVitria device, some of which included (1) inability to directly visualize the injection site when using the InVitria device, making it feel like a “blind” procedure, which contributed toward perceptions of it being unsafe; (2) the device comes in only a single size and may not be universally suitable for use in all patients, especially in elderly female Asian patients in whom the palpebral aperture is often small, resulting in significant discomfort to the patient when fitting the device; and (3) concerns regarding the fixed injection distance of 3.5 mm from the limbus, instead of 4 mm, even for phakic patients, which may predispose them to crystalline lens trauma during intravitreal injection.

## Surgical Complications

No serious intraoperative or postoperative complications were encountered during this study for intravitreal injections performed via either the conventional freehand or InVitria techniques (serious complications referred to infective endophthalmitis, retinal detachment, and extreme intraocular pressure spikes leading to central retinal vein or artery occlusions). Of the 70 planned InVitria injections, 6 procedures (8.6%) were abandoned and had to be converted to the conventional freehand technique as the patients’ palpebral apertures were too small to accommodate fitting of the InVitria device.

## Cost Analysis

Both the conventional freehand and InVitria techniques require the use of a sterile, disposable dressing set. The conventional technique also requires procurement and sterilization of reusable Barraquer lid speculums and measuring calipers, leading to an approximate operating cost of S\$2266 (US\$ 1632) per month (S\$5.67 (US\$ 4.10) per injection) or S\$27,192 (US\$ 19,578) a year, assuming a total load of 400 intravitreal injections per month. While reusable lid speculums and measuring calipers are not required with the InVitria technique, additional cost is incurred from procurement of the single-use InVitria devices. As such, the monthly operating cost with the InVitria technique is estimated to be S\$9020 (US\$ 6494) per month, which is higher than the conventional method. This translates to an increase in our operating costs, attributable to the delivery of intravitreal injections with the InVitria technique, by approximately S\$17 (US\$ 12.20) per injection, almost quadrupling the cost of administering each intravitreal injection compared with the conventional freehand technique. However, use of the InVitria is associated with an average of

25.1 seconds saved per injection. Assuming 400 injections per month, the total time saved (i.e.,  $400 \times 25.1$  seconds = 10,040 seconds) can be used to deliver an additional 155 injections per month.

## Medication Type

Of the 70 procedures performed with the conventional freehand technique, 55 (78%) were Avastin injections, 13 (19%) were Lucentis injections, and 2 (3%) were Eylea injections. Of the 70 procedures performed with the InVitria technique, 58 (83%) were Avastin injections, 8 (11%) were Lucentis injections, and 4 (6%) were Eylea injections.

## Discussion

Our results indicate that intravitreal injections may be delivered faster with the InVitria in contrast to the conventional freehand technique. While pain scores were similarly low regardless of injection technique, most patients who had experienced injections with both techniques indicated that they preferred the InVitria over the conventional freehand technique. From a surgeon's perspective, the InVitria was found to be a safe and effective instrument regardless of seniority or clinical experience, and most surgeons would recommend the use of this device should such an option be available.

Our findings in favor of the InVitria device are in line with those of a previous study that evaluated the outcomes of intravitreal injections delivered with the InVitria versus conventional freehand injection technique.<sup>15</sup> While the aforementioned study indicated lower periprocedural pain as the main advantage when using the InVitria, such a difference was not noted in our study. Instead, our findings of substantially quicker procedures with the InVitria, regardless of surgeon experience, suggest that the cardinal advantage associated with this device may be attributed to its ability to enhance service delivery efficiency, especially in the setting of a high-volume practice. In contrast to the conventional freehand technique, which requires preprocedure preparation (e.g., adjustment of the measurement caliper and preplacement of the cotton-tip applicator for postprocedural tamponade), these steps are eliminated with use of the InVitria, which is an "all-in-one" device.

In this study, timing of each procedure was commenced on contact of the ocular surface with 5% povidone iodine and ceased upon complete withdrawal of the 30-gauge needle from the eye. An identical

method was used to evaluate injection timings for both techniques. Instillation of 5% povidone iodine on the ocular surface was chosen as the starting point, as it represented a common initial step required for both techniques. For the conventional technique, in particular, this allows inclusion of the time taken for all subsequent steps, such as lid speculum insertion and perilimbal distance marking, which we hypothesized to be time-consuming and potentially avoidable with the conjunctival device. Complete withdrawal of the 30-gauge needle was chosen as the common endpoint, as subsequent surgical steps (i.e., tamponade followed by lid-speculum/conjunctival-device removal) were relatively similar for both conventional and alternative techniques, and we did not expect any significant differences in surgical timings attributable to these steps, regardless of technique.

Intravitreal injections administered with the conjunctival device took an average of  $64.9 \pm 26.8$  seconds versus the conventional technique, which required an average of  $90.0 \pm 23.3$  seconds ( $P < 0.001$  for difference). This represents an approximately 28% reduction in procedural time when the conjunctival device is used, in contrast to the conventional technique. We believe that such a reduction will be noticeable and appreciated by patients, as evidenced by this factor being the most commonly stated reason, by patients, for preference of the conjunctival device over the conventional technique. From a service provider's point of view, a reduction in 25 seconds per procedure translates to approximately 40 minutes of total procedural time saved per 100 intravitreal injections; we believe this to be significantly beneficial as well.

Besides the 2 surgical techniques described in our study, there are several other methods by which intravitreal injections may be delivered, such as with the Desmarres retractor<sup>16</sup> or cotton-tip swab sticks. Regardless of technique employed, it may be challenging to administer intravitreal injections in certain patient subtypes, such as in patients with smaller palpebral apertures due to normal ethnic/anatomical variations (e.g., Asian eyes, which have relatively smaller palpebral apertures compared to Caucasian eyes) or in noncompliant/anxious patients who squeeze their eyelids tight intraoperatively. Placement of the InVitria on the ocular surface simultaneously achieves lid retraction, globe stabilization, and standardization of needle position/angle/depth. While this facilitates the delivery of intravitreal injections especially in patients who struggle excessively and in those with a strong Bell's reflex, the standardized size of the InVitria device may result in significant discomfort for patients with small palpebral apertures, as observed in

this study. In contrast, while conventional techniques involving the use of lid speculums with varying widths may result in greater comfort for patients with small palpebral apertures, the manual dexterity required to simultaneously manipulate several surgical instruments such as calipers, swab sticks, and retractors may be challenging in uncooperative patients, especially for an inexperienced injector.

No adverse events were noted in any of the cases where the InVitria was used in our study. Endophthalmitis is a rare but important risk of any intravitreal injection; in our study cohort with either method, there were no occurrences of endophthalmitis. While most surgeons in this study felt that the InVitria was a safe device to use, a major limitation that was highlighted by several surgeons pertains to the fact that it is a “one-size-fits-all” device (i.e., the injection port is sited at a fixed distance of 3.5 mm away from the corneoscleral limbus for all patients). While 3.5 mm is a reasonable anatomical landmark to ensure the safe delivery of a trans-pars plana intravitreal injection in a pseudophakic eye, a longer distance of 4.0 mm would be preferable in phakic patients in order to avoid iatrogenic crystalline lens trauma. While no adverse events of needle-related lens subluxation or capsule penetration were observed in our study, which involved a relatively small number of patients, the safety of such an approach has to be further verified in clinical studies involving longer-term follow-up of larger cohorts of patients.

Cost effectiveness is a key determinant for the adoption of new devices and technology in our center. In our analysis, a switch from the conventional freehand technique to the InVitria device for all patients receiving intravitreal injections at our center is associated with a threefold increase in operating costs, mainly due to the high cost of the InVitria device. However, we would like to emphasize that the results of this cost analysis are specific to our institution and would most likely not be directly applicable to other institutions. Moreover, as mentioned, use of the InVitria device allows intravitreal injections to be delivered more efficiently, allowing an average of 160 more injections to be performed each month in contrast to the conventional freehand technique. Additionally, we found that the InVitria device facilitates safe and quick intravitreal injections by both junior and senior surgeons. In recent years, a burgeoning load of intravitreal injections in developed nations has prompted the creation of alternative workflows in ophthalmology outpatient clinics, whereby intravitreal injections may now be administered by trained vitreoretinal nurses, under supervision by ophthalmologists. In 2018, the Royal

College of Ophthalmologists (RCOphth) released a set of Ophthalmic Service Guidances on intravitreal injection therapy, supporting the abovementioned, with the caveat that intravitreal injections performed by any of such nonmedical health care professionals remain off-label for the licensed drugs. Recent studies in the United Kingdom and other countries such as Singapore have indicated that nurse-led injections can be safe and effective<sup>17,18</sup> when such programs are administered appropriately with inbuilt checks and balances. To extrapolate, the favorable safety profile of this device even when used by novices implies its potential to be deployed as an assistive device to facilitate the administration of intravitreal injections by trained vitreoretinal nurses, further reducing the injection burden on doctors.<sup>19</sup>

A collective analysis of these observations implies that use of the InVitria may in fact bring about overall cost savings when considering the additional revenue that may potentially be gained from the delivery of more injections, especially when such routine injections may be safely delegated to nurses and junior surgeons rather than senior surgeons. We further hypothesize that these potential cost savings may be of interest especially to high-volume practices, wherein the effects of quicker procedural times and increased revenue associated with a greater number of procedures will be amplified.

Other competing devices available on the market to assist intravitreal injections include the rapid access vitreal injection (RAVI) guide.<sup>20</sup> The auto-clave safe, reusable titanium RAVI guide has a small baseplate that sits on the perilimbal sclera with a flange at one end to hold the lids away, and injections are administered through a small hole on the baseplate. There are also experimental machines that allow full automation of intravitreal injections.<sup>21</sup> In line with our efforts to explore alternative approaches to the conventional freehand technique to optimize the delivery of intravitreal injections, we will be keen to perform similar evaluations of these other devices at our center in the near future.

A major limitation of our study relates to the small sample size. However, this was an early stage study primarily designed to gain an initial understanding of the ease of use and safety of the InVitria technique in clinical practice. Without first obtaining pilot data with a smaller set of trial patients as we have done in this study, it would have been difficult to justify the significant expenditure necessary to finance the procurement of a larger batch of InVitria devices to perform a more detailed analysis. Additionally, as mentioned above, the InVitria was evaluated at our center on a population of Asian patients whose anatomical characteristics

and preferences may differ significantly from patients seen in other countries and institutions. As such, while our findings provide valuable guidance regarding the possibility of the InVitria leading to improvements in service delivery standards and cost-effectiveness at our center, these findings may not necessarily be directly applicable to other institutions. In this study, we have excluded patients with glaucoma who have previously undergone GFS or GDD implantation. For such patients, we prefer to administer intravitreal injections with the conventional technique, which allows clear visualization of the scleral/conjunctival anatomy and facilitates precise selection of a safe injection site located away from the filtering bleb and/or GDD tube. The wide flange of the InVitria device may also result in inadvertent trauma to filtering blebs, especially when forcibly inserted under the upper eyelid in patients with small palpebral apertures, which in the worse-case scenario may lead to endophthalmitis.<sup>22</sup>

In conclusion, faster procedural time and a demonstrable clinical safety profile regardless of surgeon seniority represent the major advantages of the InVitria device found in this study. Coupled with the potential cost-savings associated with use of this device in a high-volume practice, the InVitria represents a clinically acceptable and potentially cost-effective, comparable alternative to the conventional freehand technique for delivery of intravitreal injections.

## Acknowledgments

Supported by the vitreoretinal department at the Singapore National Eye Centre. No external grants or sources of funding were used. Data cannot be shared publicly because of the Singapore Personal Data Protection Act of 2012. Data are available from the Singapore Health Services Centralized Institutional Review Board (contact via office.research@singhealth.com.sg) for researchers who meet the criteria for access to confidential data.

Author Contributions: Y.Q. Soh: performed the study, collection and assembly of data, data analysis and interpretation of data, manuscript writing; N.P.Y. Chiam: performed the study, collection and assembly of data; A.S.H. Tsai, E.Y.M. Wong, A.C.S. Tan: conception and design, patient recruitment, final approval of manuscript; G.C.M. Cheung, T.Y. Wong, I.Y.S. Yeo: editing and final approval of manuscript.

Disclosure: **Y.Q. Soh**, None; **N.P.Y. Chiam**, None; **A.S.H. Tsai**, None; **G.C.M. Cheung**, None; **T.Y. Wong**,

None; **I.Y.S. Yeo**, None; **E.Y.M. Wong**, None; **A.C.S. Tan**, None

## References

1. Wong TY, Cheung CMG, Larsen M, Sharma S, Simó R. Diabetic retinopathy. *Nat Rev Dis Primer*. 2016;2:16012.
2. Cheung N, Mitchell P, Wong TY. Diabetic retinopathy. *Lancet Lond Engl*. 2010;376:124–136.
3. Tan GS, Cheung N, Simó R, Cheung GCM, Wong TY. Diabetic macular oedema. *Lancet Diabetes Endocrinol*. 2017;5:143–155.
4. Wong TY, Scott IU. Clinical practice: retinal-vein occlusion. *N Engl J Med*. 2010;363:2135–2144.
5. Cheung CMG, Li X, Mathur R, et al. A prospective study of treatment patterns and 1-year outcome of Asian age-related macular degeneration and polypoidal choroidal vasculopathy. *PLoS One*. 2014;9:e101057.
6. Wong WL, Su X, Li X, et al. Global prevalence of age-related macular degeneration and disease burden projection for 2020 and 2040: a systematic review and meta-analysis. *Lancet Glob Health*. 2014;2:e106–e116.
7. Ng WY, Cheung CMG, Mathur R, et al. Trends in age-related macular degeneration management in Singapore. *Optom Vis Sci*. 2014;91:872–877.
8. Lim LS, Mitchell P, Seddon JM, Holz FG, Wong TY. Age-related macular degeneration. *Lancet*. 2012;379:1728–1738.
9. Ohno-Matsui K, Ikuno Y, Lai TYY, Gemmy Cheung CM. Diagnosis and treatment guideline for myopic choroidal neovascularization due to pathologic myopia. *Prog Retin Eye Res*. 2018;63:92–106.
10. Ganesh S, Ahmed A, Biswas J. Analysis of the clinical profile and management of inflammatory choroidal neovascular membranes in uveitic eyes: a study from a tertiary referral center. *Ocul Immunol Inflamm*. 2019;27:424–434.
11. Rosenfeld PJ, Brown DM, Heier JS, et al. Ranibizumab for neovascular age-related macular degeneration. *N Engl J Med*. 2006;355:1419–1431.
12. Wykoff CC, Ou WC, Croft DE, et al. Neovascular age-related macular degeneration management in the third year: final results from the TREX-AMD randomised trial. *Br J Ophthalmol*. 2018;102:460–464.
13. Koh A, Lee WK, Chen L-J, et al. EVEREST study: efficacy and safety of verteporfin photodynamic therapy in combination with ranibizumab or alone



- versus ranibizumab monotherapy in patients with symptomatic macular polypoidal choroidal vasculopathy. *Retina*. 2012;32:1453–1464.
14. Koo T, Park SW, Jo DH, et al. CRISPR-LbCpf1 prevents choroidal neovascularization in a mouse model of age-related macular degeneration. *Nat Commun*. 2018;9:1855.
  15. Ratnarajan G, Nath R, Appaswamy S, Watson S-L. Intravitreal injections using a novel conjunctival mould: a comparison with a conventional technique. *Br J Ophthalmol*. 2013;97:395–397.
  16. Mason RWH. Use of a Desmarres retractor for upper lid and lash isolation during intravitreal injections. *Retina*. 2013;33:2175–2176.
  17. Gregg E. Nurse-led ranibizumab intravitreal injections in wet age-related macular degeneration: a literature review. *Nurs Stand*. 2017;31:44–52.
  18. Teo AWJ, Rim TH, Wong CW, et al. Design, implementation, and evaluation of a nurse-led intravitreal injection programme for retinal diseases in Singapore [published online May 7, 2020]. *Eye*.
  19. Michelotti MM, Abugreen S, Kelly SP, et al. Transformational change: nurses substituting for ophthalmologists for intravitreal injections - a quality-improvement report. *Clin Ophthalmol*. 2014;8:755–761.
  20. Han DP, McKenney KC, Kim JE, Weinberg DV, Musch DC, Singh RSJ. Clinical evaluation of the rapid access vitreal injection guide: a handheld instrument for assisting intravitreal injections. *Retina*. 2017;37:778–781.
  21. Ullrich F, Michels S, Lehmann D, Pieters RS, Becker M, Nelson BJ. Assistive device for efficient intravitreal injections. *Ophthalmic Surg Lasers Imaging Retina*. 2016;47:752–762.
  22. Baneke AJ, Vakros G, Sharma V, Wong SC. Bleb-related endophthalmitis after use of the InVitria injection guide. *Retin Cases Brief Rep*. 2020;13:33–34.