

# Aqueous Humor Markers in Retinoblastoma, a Review

Benjamin K. Ghiam<sup>1</sup>, Liya Xu<sup>2</sup>, and Jesse L. Berry<sup>3,4</sup>

<sup>1</sup> Oakland University, William Beaumont School of Medicine, Rochester, MI, USA

<sup>2</sup> Department of Biological Sciences, Dornsife College of Letters, Arts, and Sciences, University of Southern California, Los Angeles, CA, USA

<sup>3</sup> The Vision Center at Children's Hospital Los Angeles, Los Angeles, CA, USA

<sup>4</sup> USC Roski Eye Institute, Keck School of Medicine of USC, University of Southern California (USC), Los Angeles, CA, USA

**Correspondence:** Jesse L. Berry, Children's Hospital Los Angeles and USC Roski Eye Institute, Keck School of Medicine of USC, University of Southern California, Los Angeles, 1450 San Pablo Street, Los Angeles, CA 90033, USA. e-mail: jesse.berrynd@gmail.com.

**Received:** 6 August 2018

**Accepted:** 1 January 2019

**Published:** 9 April 2019

**Keywords:** aqueous humor; retinoblastoma; biomarkers; biopsy

**Citation:** Ghiam BK, Xu L, Berry JL. Aqueous humor markers in retinoblastoma, a review. *Trans Vis Sci Tech.* 2019;8(2):13. <https://doi.org/10.1167/tvst.8.2.13>  
Copyright 2019 The Authors

**Purpose:** Retinoblastoma (Rb) is the most common primary intraocular cancer in children. Unlike with most solid tumors, direct biopsy is contraindicated due to risk of tumor dissemination. However, recent therapeutic techniques have allowed for the safe extraction of aqueous humor (AH) from eyes undergoing therapy, providing the unique opportunity to use AH as a liquid biopsy for Rb. Although the extraction of AH in Rb eyes undergoing therapy is new, the consideration of whether there are tumor biomarkers in the AH is not. The current manuscript is a systematic review of all studies that have examined biomarkers in the AH of Rb eyes. The authors hypothesized that AH sampling and analysis of tumor biomarkers may have new clinical relevance for the diagnosis, prognosis, and/or management of Rb.

**Methods:** A comprehensive database search (PubMed, Web of Science, Embase, and Cochrane Databases) was conducted in accordance with the Preferred Reporting Items for Systematic Reviews and Meta-Analyses statement to identify articles on AH markers in Rb eyes. Inclusion criteria included English language articles with original reports on AH markers in the eyes of patients with confirmed Rb. Data on marker type, number of eyes, marker means and ranges, and when available, control values and clinicopathological correlations were collected. Articles were stratified based on marker type, and assessed quantitatively and qualitatively.

**Results:** An initial database search produced 325 articles, and an additional 11 articles were identified through searching citations. After removing duplicates and applying the eligibility criteria, we selected 27 articles to be included in the current review. A total of 463 eyes with histologically confirmed Rb were included in this review. The various markers and their values, with comparison to controls and clinicopathological correlations, are discussed.

**Conclusions:** AH sampling and tumor biomarker analysis in eyes without undergoing enucleation have the potential to revolutionize the management of Rb.

**Translational Relevance:** Although previous studies evaluated markers in the AH only after enucleation and not at diagnosis or during therapy, the clinical relevance of these markers was limited. However, recent changes in the management of Rb have allowed for safe sampling of the aqueous during therapy and, thus, correlation of tumor biomarkers with disease course. Thus, the authors felt it important to revisit previous research to evaluate whether these markers may now be applicable for the diagnosis, prognosis, or management of Rb

## Introduction

Retinoblastoma (Rb) is the most common primary intraocular cancer in children, comprising 4% of all pediatric malignancies.<sup>1,2</sup> Intraocular disease often

goes undiagnosed until the tumor is advanced and threatens the globe; although survival rates are in excess of 90% in developed countries, a critical focus of Rb therapy is globe (and vision) preservation.<sup>3,4</sup> Historically, any attempt to biopsy or obtain fluid from Rb eyes had been contraindicated for risk of

tumor seeding and dissemination.<sup>5–10</sup> However, aqueous humor (AH) paracentesis is now a standard part of the protocol for intravitreal chemotherapy (melphalan and/or topotecan) injections for Rb.<sup>11</sup> As a safety measure, a volume of 0.1 mL of aqueous fluid is aspirated to induce transient hypotony prior to the intravitreal injection to prevent reflux to the injection site. Current clinical indications for intravitreal chemotherapy and, therefore, aqueous paracentesis include active seeding requiring further therapy and the eye must meet the following conditions to ensure safety: (1) presence of clear medium, (2) absence of invasion of the anterior and posterior chamber on ultrasound biomicroscopy, (3) absence of tumor at planned entry site, (4) absence of vitreous seeds at entry site, and (5) the absence of retinal detachment at the entry site.<sup>11</sup> These features are aimed at protecting the safety of the pars plana injection site, which includes the aspiration of AH. Intravitreal injection of chemotherapy for seeding has now been widely adopted, and the risk of extraocular spread is considered extremely low (0 reported cases with the safety enhanced procedure).<sup>12–17</sup> With this demonstrated safety record, we can now access the AH in eyes with Rb undergoing active therapy and evaluate for the presence of biomarkers that may correlate with features of the intraocular tumor and provide diagnostic and prognostic value. It should be noted that aside from active research protocols, there are no clinical tests commercially available at this time that are indicated for diagnostic or prognostic evaluation in Rb.

AH is the clear intraocular fluid produced by the ciliary processes that fills the anterior and posterior chambers of the eye.<sup>18,19</sup> AH functions to maintain intraocular pressure; provide nutrients for the lens, cornea, and trabecular meshwork; remove waste products of metabolism; and protect against oxidative damage.<sup>20</sup> AH has been shown to be a rich source of information for intraocular disease, including Rb, although due to safety concerns previous studies were done on AH from enucleated eyes only. In 1971, Dias et al.<sup>21</sup> first explored the AH in enucleated eyes from children with Rb and identified that an increase in lactic acid dehydrogenase (LDH) activity correlated with disease activity; the authors suggested this may aid in diagnosis. Following that initial report, further studies explored the various clinicopathological correlations associated with LDH as an AH marker of ocular disease.<sup>22,23</sup> Over the past few decades, numerous studies have explored AH in enucleated Rb eyes and have uncovered various markers that

may demonstrate clinical value for diagnosis, clinicopathological associations,<sup>22,23</sup> monitoring response to treatment,<sup>24–26</sup> and possibly serve as targets for therapy.<sup>27</sup> However, because all previous studies were from enucleated eyes, clinical correlations were difficult if impossible to make and the role of the AH in management of Rb remained limited. A recent study by the authors demonstrated that Rb tumor DNA is present in the AH in sufficient concentrations for subsequent sequencing and analysis.<sup>28</sup> This study suggested the AH has the potential to serve as a surrogate to direct tumor biopsy, thus providing tumor genetic information in eyes undergoing salvage therapy (e.g., without enucleation of the eye).<sup>28</sup> A broader evaluation demonstrated that genomic evaluation of the cell-free tumor DNA (cfDNA) in the AH may be predictive of aggressive tumor activity and the need for enucleation.<sup>29</sup> AH is now routinely extracted during intravitreal chemotherapy injections for eyes undergoing salvage therapy; thus, the authors hypothesized that AH sampling and analysis, without enucleation, may now be clinically applicable for the diagnosis, prognosis, and/or management of Rb. The current systematic review summarized all studies that have explored AH markers that may be of value in the diagnosis, prognosis, or characterization of Rb.

## Methods

### Search Strategy

This study was conducted according to the Preferred Reporting Items for Systematic Reviews and Meta-Analyses (PRISMA) guidelines (Supplementary File S1).<sup>30</sup> A comprehensive electronic search of databases, including PubMed, Web of Science, Embase, and Cochrane Databases, was conducted on August 1, 2018 with keywords “aqueous humor” or “aqueous humour” and “retinoblastoma”. The search strategy was developed for PubMed and then applied to other databases. The search results were imported into a reference manager (Paperpile), and duplicates were excluded. Abstracts of all related studies were evaluated, and full texts were obtained through PubMed, Google Scholar, and other related databases. The reference list of the included articles was also examined to identify additional studies that were not previously found with the electronic search. Full texts of articles were then evaluated by two authors (B.K.G. and J.L.B.) to be included in the review. Disagreements among the reviewers were resolved by discussion and subsequent consensus.

## Selection Criteria

Eligible studies included all original research articles that were published in English up to 2018, which examined markers within the AH of eyes with histologically confirmed Rb.

Excluded were (1) nonresearch articles such as brief reports and case reports; (2) studies examining markers in the serum (or other non-AH fluid compartments; i.e., tears) only; (3) studies examining markers in non-Rb eyes only; and (4) studies that were not written in English, or where an English translation was not available. The search was not limited to specific years. Studies that quantitatively measured markers and compared their levels against control groups were sought out, although studies that did not perform control group comparisons were also discussed in this review.

## Quantitative and Qualitative Data Extraction

The characteristics extracted from the studies included type of marker, number of eyes, and, when possible, means and ranges of markers examined from each study. If the study compared Rb marker levels to control groups, the control means and ranges were also extracted, along with the *P* values (if available). Quantitative data on the number of eyes examined from each study were combined to determine the total number of eyes examined for each marker type, and when available, ranges of markers for Rb and control groups were processed and combined to create unified ranges for each marker. The narrative synthesis of qualitative findings for each marker was performed to discuss clinicopathological correlations of each marker. Studies were stratified based on the marker type evaluated.

## Quality Assessment

The review was conducted in accordance with the PRISMA approach<sup>30</sup> to ensure the transparent and complete report of our sensitive search, systematic screening, and independent quality assessment. Quality assessment was performed for all studies by independently using the protocols of the National Institute of Health Quality Assessment Tool checklist (Supplementary File S2). The checklist consists of 12 different items that evaluate various aspects of the case-control methodology, including sampling methods, control status, and adjustment of confounders. Studies were grouped in three categories (good, fair, and poor). This information was used to assess the quality and strength of markers in clinical care.

## Results

An initial database search produced 325 articles, and an additional 11 articles were identified through searching citations. After removing duplicates and applying the eligibility criteria, we selected 27 articles to be included in the current review. The PRISMA flowchart representing information on the selection process of articles is illustrated in the [Figure](#).

Data from the 27 included articles were extracted into a table with core characteristics of these studies (author[s] and year, type of marker, number of eyes, mean value of marker in AH for Rb eyes [if available], range of marker values in AH for Rb eyes [if available], number of control eyes [if available], mean value of markers in AH for control eyes [if available], range of marker values in AH for control eyes [if available], *P* value [if available], and quality assessment rating) ([Table 1](#)).

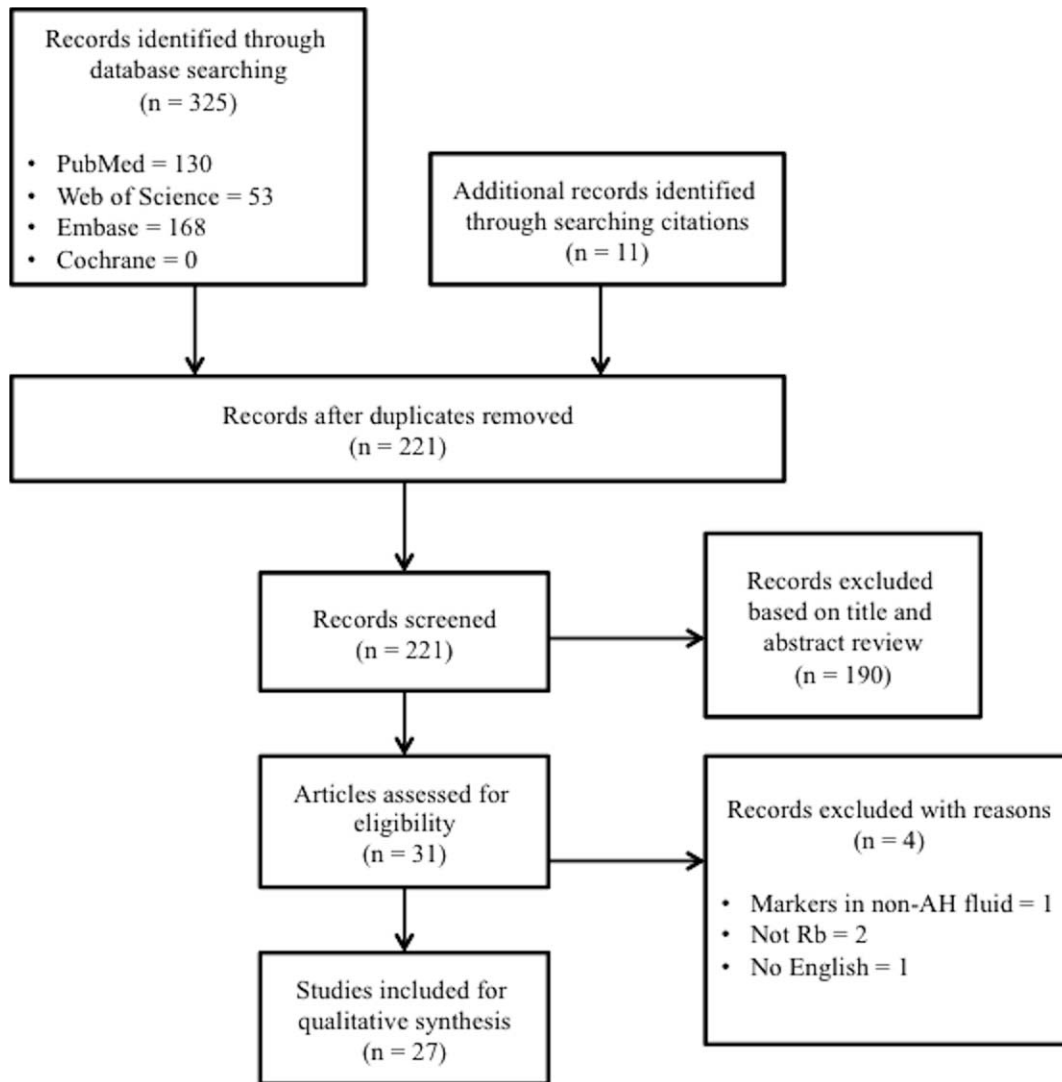
[Table 2](#) includes quantitative and qualitative data from the included articles, stratified based on the different markers. Quantitative data analysis from the included articles has been performed to arrive at a total number of Rb and control eyes. The values of the biomarkers from different studies have been processed and combined to produce unified ranges for both Rb and control eyes. Also, a narrative synthesis of qualitative findings for each marker has been performed to include clinicopathological correlations ([Table 2](#)).

A total of 463 eyes with histologically confirmed Rb were included in this review, and 302 eyes in which the diagnosis of Rb was excluded were used as controls. Twelve studies examined levels of LDH in AH.<sup>21–24,31–38</sup> Five studies examined neuron-specific enolase.<sup>26,39–42</sup> Two studies examined levels of survivin,<sup>43,24</sup> and one of which additionally examined transforming growth factor beta (TGF- $\beta$ ) and LDH.<sup>24</sup> One study examined levels of uric acid.<sup>44</sup> Three studies analyzed proteins in AH, including protein concentrations<sup>25,31</sup> and protein analysis.<sup>27</sup> One study examined the cytokines, chemokines, matrix metalloproteinases, and acute-phase protein concentrations.<sup>45</sup> Two studies examined levels of aromatic amino acids and catecholamine metabolites.<sup>46,47</sup> One study performed nucleic acid analysis<sup>28</sup> and another performed genomic evaluation<sup>29</sup> ([Table 1](#)).

## Discussion

### Lactate Dehydrogenase

LDH is an enzyme found in nearly all cells as a regulator of metabolism. Clinically, LDH has been



**Figure.** Article selection process based on Preferred Reporting Items for Systematic Reviews and Meta-Analysis (PRISMA).

used as a nonspecific marker found within body fluids in various pathological conditions, including malignant tumors.<sup>48</sup> Our search found 12 studies that have examined LDH activity in the AH of children with Rb. A total of 245 eyes with histologically confirmed Rb were included, compared to 206 patients without Rb as controls.

Dias et al.<sup>21</sup> were among the first to examine LDH levels in the AH, obtaining a 0.1-mL sample of AH from enucleated eyes from children with Rb. Early reports demonstrated a significant increase in the levels of LDH within the AH of enucleated eyes with Rb when compared to patients without Rb, such that levels of >1000 U/L strongly support the diagnosis of Rb.<sup>21–24,33–38,49</sup> Additionally, Rb AH demonstrates a characteristic pattern of the LDH isoenzyme pattern

in which isoenzymes LDH4 and LDH5 are characteristically elevated, which may be useful information in the diagnosis of Rb.<sup>34,37</sup> Clinicopathological parameters that significantly correlate to AH LDH levels include tumor cell necrosis,<sup>49</sup> presence of tumor in the anterior chamber,<sup>33</sup> and increasing duration of untreated tumor.<sup>22,49</sup> It was demonstrated that children with later classifications of the disease (Reese Ellsworth classification IV and V) had significantly higher levels than children with early classification (I to III).<sup>36</sup> These studies suggest that further elevations of AH LDH may correspond to a greater severity of disease.

Shehata et al.<sup>24</sup> examined serum LDH levels before and after treatment with chemoreduction with focal consolidation therapies (cryotherapy, laser thermo-

**Table 1.** Included Articles with Core Characteristics

Author(s), Date	Type of Marker	Number of Rb Eyes	Rb AH Marker Mean	Rb AH Marker Range
Dias et al. 1971 <sup>21</sup>	LDH (U/L)	4	2452.5	1,800–3,250
Kabak and Romano 1975 <sup>32</sup>	LDH (U/L)	4	542.5	56–1,832
Piro et al. 1978 <sup>33</sup>	LDH (U/L)	23	1886	10–15,920
Abramson et al. 1979 <sup>34</sup>	LDH (U/L)	24	1825	10–15,920
Dias 1979 <sup>22</sup>	LDH (U/L)	24	2429.75	1,220–3,650
Dias 1979 <sup>23</sup>	LDH (U/L)	7	-	1,460–3,400
Das et al. 1983 <sup>35</sup>	LDH (U/L)	14	-	-
Dias 1985 <sup>49</sup>	LDH (U/L)	5	3656	1,660–7,000
Dayal et al. 1985 <sup>36</sup>	LDH (U/L)	20	-	-
Singh et al. 1991 <sup>37</sup>	LDH isoenzymes	15	-	-
Mukhopadhyay et al. 2008 <sup>38</sup>	LDH (U/L)	21	3396.9	863–4819
Shehata et al. 2016 <sup>24</sup>	LDH (U/L)	88	591.34	325.25–1,270
	Survivin (pg/mg protein)		31.84	17.63–52.70
	TGF- $\beta$ (pg/mg protein)		90.79	17.63–49.32
Abramson et al. 1989 <sup>41</sup>	NSE (ng/mL)	17	3829	619–60,000
Comoy et al. 1990 <sup>26</sup>	NSE (ng/mL)	7	-	83–17,900
Nakajima et al. 1986 <sup>42</sup>	NSE isoenzymes	12	-	-
Shine et al. 1990 <sup>40</sup>	NSE isoenzymes	10	-	-
Wu et al. 1997 <sup>39</sup>	NSE isoenzymes	21	-	-
Shehata et al. 2010 <sup>43</sup>	Survivin (pg/mg protein)	21	28.27	17.63–49.32
Mendelsohn et al. 1998 <sup>44</sup>	Uric acid ( $\mu$ /mL)	38	18.3	4.72–31
	Xanthine ( $\mu$ /mL)		2.43	0.27–8.03
	Protein content (g/100 mL)		1.15	0.9–1.4
Dias 1979 <sup>31</sup>	Protein content (mg/mL)	2	3.44	0.89–6.9
Hadjistilianou et al. 2012 <sup>25</sup>	Protein analysis	8	-	-
Cheng et al. 2017 <sup>27</sup>	Cytokines/chemokines	10	-	-
Cheng et al. 2017 <sup>45</sup>	Catecholamine metabolites	35	-	-
Abramson et al. 1978 <sup>47</sup>	Aromatic amino acids (catechols)	5	-	-
Abramson et al. 1993 <sup>46</sup>	Nucleic acid analysis	-	-	-
Berry et al. 2017 <sup>28</sup>	Genomic analysis	3	-	-
Berry et al. 2018 <sup>29</sup>		-	-	-

therapy, and brachytherapy), external beam radiotherapy, and/or enucleation. Shehata et al.<sup>24</sup> demonstrated a significant reduction of serum LDH concentrations after treatment, suggesting a possible role in monitoring serum LDH as an index of therapeutic response and tumor regression in children with Rb. However, serum and AH LDH levels do not appear to correlate with each other,<sup>36</sup> and AH LDH levels have not been shown to correlate with prior therapy, nor tumor or patient demographics.<sup>33</sup> Moreover, one study from Dias<sup>23</sup> in 1979 showed persistent elevation in AH LDH after irradiation of the eye, despite no visible Rb tissue ophthalmoscopically. This argues against the use of AH LDH as a marker for tumor regression. Additionally, tumor

regression is best monitored via indirect ophthalmoscopy by an ocular oncologist; however, an accurate test for early recurrence or recurrence under a calcified otherwise regressed scar would have clinical utility. This would also be clinically applicable if levels correlated with high-risk histopathologic disease (e.g., suggesting some metastatic risk to attempted salvage of the globe), but this has not yet been shown.

In summary, multiple studies on LDH levels in the AH from enucleated eyes were done between the years 1971–2008, which found that LDH levels were significantly elevated compared to controls and more elevated in advanced eyes with delayed diagnosis; however, these levels did not correlate with other clinical features or outcomes and did not correlate

**Table 1.** Extended

Author(s), Date	Ctl Eyes	Ctl AH Mean	Ctl AH Range	P Value	Quality Rating
Dias et al. 1971 <sup>21</sup>	33	-	0–350	-	Fair
Kabak and Romano 1975 <sup>32</sup>	7	24	0–99	-	Fair
Piro et al. 1978 <sup>33</sup>	-	-	-	-	Fair
Abramson et al. 1979 <sup>34</sup>	34	47	10–167	<0.02	Good
Dias 1979 <sup>22</sup>	-	-	-	-	Fair
Dias 1979 <sup>23</sup>	6	-	180–420	-	Good
Das et al. 1983 <sup>35</sup>	10	-	-	<0.01	Fair
Dias 1985 <sup>49</sup>	-	-	-	-	Fair
Dayal et al. 1985 <sup>36</sup>	-	-	-	-	Good
Singh et al. 1991 <sup>37</sup>	15	-	-	-	Good
Mukhopadhyay et al. 2008 <sup>38</sup>	21	90.6	48–146	<0.001	Good
Shehata et al. 2016 <sup>24</sup>	80	62.18	19.38–181.25	<0.01	Good
		20.2	6.5–38	<0.01	
		23.07	11.22–52.14	<0.01	
Abramson et al. 1989 <sup>41</sup>	-	-	-	-	Fair
Comoy et al. 1990 <sup>26</sup>	19	5.0	-	-	Fair
Nakajima et al. 1986 <sup>42</sup>	-	-	-	-	Good
Shine et al. 1990 <sup>40</sup>	-	-	-	-	Good
Wu et al. 1997 <sup>39</sup>	-	-	-	-	Good
Shehata et al. 2010 <sup>43</sup>	17	20.57	6.5–38	<0.05	Good
Mendelsohn et al. 1998 <sup>44</sup>	17	7.67	6.91–8.43	<0.05	Good
		0.43	0.37–0.49	<0.05	
Dias 1979 <sup>31</sup>	10	-	0–0.17	-	Good
Hadjistilianou et al. 2012 <sup>25</sup>	10	0.19	0.16–0.24	<0.01	Good
Cheng et al. 2017 <sup>27</sup>	-	-	-	-	Good
Cheng et al. 2017 <sup>45</sup>	20	-	-	<0.05	Fair
Abramson et al. 1978 <sup>47</sup>	-	-	-	-	Fair
Abramson et al. 1993 <sup>46</sup>	-	-	-	-	Fair
Berry et al. 2017 <sup>28</sup>	-	-	-	-	Good
Berry et al. 2018 <sup>29</sup>	-	-	-	-	Good

with serum LDH levels. Elevations in AH LDH levels have also been described in patients with other ocular conditions, including primary open angle glaucoma<sup>50</sup> and Coats' disease.<sup>51</sup> Additionally, 6 out of the 12 studies that examined AH LDH have a fair quality assessment rating<sup>21,31–33,35,49</sup> (the remaining studies are graded good) largely due to the absence of statistical evidence and calculated *P* value. Although LDH was the first described marker of tumor activity in the AH, the lack of specificity and correlation with patient or tumor features limits its use clinically. Due to this lack of correlation as well as inability to extract AH from eyes undergoing treatment, this research was mostly abandoned.

## Enolase/Neuron-Specific Enolase

Neuron-specific enolase (NSE) is an isoenzyme of the glycolytic enzyme enolase that occurs as gamma gamma and alpha gamma dimers and is highly specific for neurons and peripheral neuroendocrine cells. The findings of increased body fluid levels of NSE have been found to occur with malignant proliferation and, thus, have been of value in the diagnosis and characterization of neuroendocrine tumors, including small cell lung cancer<sup>52</sup> and, recently, Rb.<sup>53</sup>

Five studies in our review examined NSE in the AH of Rb patients that include 67 enucleated Rb eyes compared to 65 normal eye controls.<sup>26,39–42</sup> Three high-quality studies used an enzyme immunoassay

**Table 2.** Quantitative Aqueous Humor Marker Data with Clinocopathological Correlations<sup>a</sup>

Marker	Studies	Rb, <i>n</i>	Ctl, <i>n</i>	Rb Range	Control Range
LDH	Dias et al. 1971 <sup>21</sup> Kabak and Romano 1975 <sup>32</sup> Piro et al. 1978 <sup>33</sup> Abramson et al. 1979 <sup>34</sup> Dias 1979 <sup>22</sup> Dias 1979 <sup>23</sup> Das et al. 1983 <sup>35</sup> Dias 1985 <sup>49</sup> Dayal et al. 1985 <sup>36</sup> Singh et al. 1991 <sup>37</sup> Mukhopadhyay et al. 2008 <sup>38</sup> Shehata et al. 2016 <sup>24</sup>	245	206	10–15,920 U/L	0–420 U/L
NSE	Abramson et al. 1989 <sup>41</sup> Comoy et al. 1990 <sup>26</sup> Nakajima et al. 1986 <sup>42</sup> Shine et al. 1990 <sup>40</sup> Wu et al. 1997 <sup>39</sup>	67	19	83–60,000 ng/mL	5 ± 7.7
Survivin	Shehata et al. 2010 <sup>43</sup> Shehata et al. 2016 <sup>24</sup>	109	97	17.63–52.70 pg/mg	6.5–38 pg/mg
TGF-β	Shehata et al. 2016 <sup>24</sup>	88	80	40.54–166.86 pg/mg	11.22–52.14 pg/mg
Uric acid	Mendelsohn et al. 1998 <sup>44</sup>	38	17	4.72–31 μg/mL	6.91–8.43 μg/mL
Xanthine	Mendelsohn et al. 1998 <sup>44</sup>	38	17	0.27–8.03 μg/mL	0.37–0.49 μg/mL
Protein content	Dias 1979 <sup>31</sup> Hadjistilianou et al. 2012 <sup>25</sup> Cheng et al. 2017 <sup>27</sup> Cheng et al. 2017 <sup>45</sup>	55	40	0.89–6.9 mg/mL	0–0.24 mg/mL
Nucleic acid (cfDNA)	Berry et al. 2017 <sup>28</sup> Berry et al. 2018 <sup>29</sup> Total eyes	32 463	3 302	0.084–56 ng/μL	0.05–0.16 ng/μL

<sup>a</sup> RE, Reese Ellsworth classification; IFN-γ, interferon gamma; PIGF-1, placenta growth factor 1; VEGF-A, vascular endothelial growth factor A; β-NGF, nerve growth factor beta; HGF, hepatocyte growth factor; EGF, epidermal growth factor; FGF-2, fibroblast growth factor 2; OR, odds ratio; CI, confidence interval.

**Table 2.** Extended

Marker	Take-Home Points and Clinicopathological Correlations
LDH	<ul style="list-style-type: none"> <li>• Nonspecific indicator of Rb tumor presence</li> <li>• Possible correlations with tumor invasion in anterior chamber, increased duration of tumor, and late stage (RE IV and V)</li> </ul>
NSE	<ul style="list-style-type: none"> <li>• Significant histopathological correlation with tumor invasion in anterior chamber (<math>t = 2.5</math>, <math>P = 0.05</math>) and inflammation (<math>t = 2.7</math>; <math>P = 0.05</math>)</li> <li>• Possible index of remission</li> </ul>
Survivin	<ul style="list-style-type: none"> <li>• Significantly elevated levels in Rb AH, compared to control AH (<math>P &lt; 0.01</math>)</li> <li>• Higher levels in late stages (RE III, IV, and V; <math>n = 15</math>) <math>31.302 \pm 10.97</math> than (early stages I and II; <math>n = 5</math>) <math>20.495 \pm 1.86</math> (<math>P = 0.002</math>)</li> <li>• Significant correlation with optic nerve invasion (<math>P = 0.003</math>)</li> <li>• Significant reduction of serum concentrations after treatment (<math>P &lt; 0.01</math>).</li> <li>• Proposed cutoff value of AH survivin = 25.2 pg/mg (62% sensitivity, 100% specificity)</li> </ul>
TGF- $\beta$	<ul style="list-style-type: none"> <li>• Significantly elevated levels in Rb AH, compared to controls AH (<math>P &lt; 0.01</math>).</li> <li>• Statistically significant higher concentration of AH TGF-<math>\beta</math>1 in undifferentiated tumors (<math>P &lt; 0.0006</math>)</li> <li>• Proposed cutoff value of AH TGF-<math>\beta</math>1 = 39.8 pg/mg (100% sensitivity, 90% specificity)</li> </ul>
Uric acid	<ul style="list-style-type: none"> <li>• Significantly elevated AH concentrations compared to controls (<math>P &lt; 0.05</math>)</li> </ul>
Xanthine	<ul style="list-style-type: none"> <li>• Significantly elevated AH concentrations compared to controls (<math>P &lt; 0.05</math>)</li> </ul>
Protein content	<ul style="list-style-type: none"> <li>• Significantly elevated AH protein concentrations compared to controls (<math>P &lt; 0.01</math>)</li> <li>• Significantly decreased protein concentration in Rb eyes following treatment with intra-arterial melphalan, compared to nontreated Rb eyes (<math>P &lt; 0.01</math>)</li> <li>• IL-6, IL-7, IL-8, IFN-<math>\gamma</math>, PIGF-1, VEGF-A, <math>\beta</math>-NGF, HGF, EGF, and FGF-2 were significantly higher in the Rb AH, compared to controls (<math>P &lt; 0.05</math>)</li> <li>• PEDF (downregulated) and STRA6 (upregulated) as possible candidates in targeted therapy for Rb.</li> </ul>
Nucleic acid (cfDNA)	<ul style="list-style-type: none"> <li>• Tumor-specific DNA is present in the AH of Rb eyes and can be safely extracted and evaluated without undergoing enucleation</li> <li>• The AH CfDNA concentration in 8 Rb eyes ranged from 0.084 to 56 ng/<math>\mu</math>L (eyes receiving melphalan treatment, mean: 0.2 ng/<math>\mu</math>L; Eyes with large untreated tumors that underwent primary enucleation, mean: 43.6 ng/<math>\mu</math>L)</li> <li>• Median concentration of DNA in control AH was 0.15 ng/<math>\mu</math>L (mean, 0.12; range, 0.05–0.16 ng/<math>\mu</math>L).</li> <li>• Genomic evaluation of Rb AH samples demonstrated the presence of any RB SCNA in enucleated eyes was 12/13 (92%), whereas the fraction in salvaged eyes was 6/16 (38%) (<math>P = 0.006</math>)</li> <li>• Presence of 6p gain in the AH was associated with a ten-fold increased odds of an eye requiring enucleation (<math>P = 0.0092</math>) (OR, 10; 95%CI, 1.8–55.6)</li> </ul>

and electrophoresis to examine the isoenzyme patterns of enolase in the AH of enucleated eyes of children with Rb<sup>39,40,42</sup> and demonstrated that the gamma subunits, indicating NSE, were elevated in AH Rb, whereas enolase was not detectable in the AH

from controls. Two fair quality studies quantified NSE levels in AH of Rb eyes.<sup>26,41</sup> Abramson et al.<sup>41</sup> found elevations in NSE significantly correlated with inflammation and tumor invasion into the anterior chamber. NSE levels did not correlate, however, with



histological tumor parameters (tumor necrosis, calcification, and optic nerve/choroidal invasion) as well as clinicopathological parameters (sex, enucleation age, presentation age, family history, prior treatment, and metastatic disease).<sup>41</sup> In 1990, Comoy et al.<sup>26</sup> examined NSE in the AH in enucleated eyes of children with Rb compared to patients in which the diagnosis of Rb was excluded and demonstrated an Rb AH NSE range of 83 to 17,900 ng/mL, whereas the values of NSE in 19 controls was between 0 and 12.5 ng/mL. In two presumed cured children who had no recurrence of Rb after 5 years, NSE levels were found to be within the control range (2.8 and 8.6 ng/mL, respectively).<sup>26</sup> In addition to demonstrating higher levels in Rb eyes than non-Rb eyes, these findings by Comoy et al.<sup>26</sup> suggest that NSE may be used clinically to indicate remission status. Although obtaining serial AH NSE measurements may have a significant role in determining tumor status in Rb patients in the future, additional, higher quality evidence is required to further substantiate the use of this tumor marker clinically.

### Survivin and TGF- $\beta$ 1

Survivin is a bifunctional inhibitor of an apoptosis protein that has been implicated in the regulation of mitosis and protection from apoptosis.<sup>54</sup> It has garnered significant interest as a diagnostic and prognostic factor in human neoplasms, including Rb. Elevated survivin levels are found in most human neoplasms,<sup>55</sup> and it is used as a prognostic factor in several human neoplasms, including lung and colorectal cancers.<sup>56</sup>

Survivin expression in enucleated eyes of children with Rb was examined by Shehata et al.<sup>43</sup> in 2010 and found to be significantly elevated in both AH and serum, when compared to patients with non-malignant ophthalmic disease, such as congenital cataracts and glaucoma ( $P < 0.05$ ).<sup>24</sup> This high-quality study found that within AH, survivin levels significantly correlated with tumor stage and histopathologic postlaminar optic nerve involvement. A follow-up study by Shehata et al.<sup>24</sup> similarly examined survivin and TGF- $\beta$ 1 expression in the AH of enucleated Rb eyes and found that both markers were significantly higher than the corresponding control group. The study also examined the expression of both markers in the serum of children with Rb before and after 6 months of treatment with focal consolidation therapies (cryotherapy, laser thermotherapy, and brachytherapy), external beam radiotherapy, and/or enucleation and found a significant reduction of serum concentrations after treatment ( $P < 0.01$ ; aqueous

was not assayed).<sup>24</sup> The study also reported a significant correlation between AH TGF- $\beta$ 1 levels and poor differentiation of the tumor. Proposed optimal cutoff values of AH survivin of 25.2 pg/mg corresponded with 62% sensitivity and 100% specificity, and cutoff values of AH TGF- $\beta$ 1 of 39.8 pg/mg corresponded with 100% sensitivity and 90% specificity.<sup>24,43</sup> The high sensitivity, specificity, and accuracy of serum and AH survivin and TGF- $\beta$ 1 proteins make them promising markers for the early detection and follow up of Rb patients. The authors of that study proposed that the roles of these markers in their pathogenesis of Rb should be further investigated, as they may be described as potential future targets for Rb therapy.

### Uric Acid and Xanthine

During cell turnover, nucleic acids and nucleotides are degraded into xanthine and uric acid. Elevated levels of serum uric acid have been associated with many malignancies, as well as after the rapid destruction of malignant tissues after treatment with chemotherapy or radiation. Mendelsohn et al.<sup>44</sup> examined the levels of uric acid and xanthine in the AH and tears of 38 eyes of children with Rb compared to 17 eyes of patients with senile and congenital cataracts as controls. The study demonstrated significantly elevated concentrations of uric acid and xanthine in the AH of Rb patients compared with control eyes including senile and congenital cataracts ( $P < 0.05$ ). No significant difference was found in the concentrations of uric acid in the tears of patients with Rb and those of normal patients. The mean concentrations of uric acid and xanthine in Rb AH were found to be 18.3 and 2.43  $\mu$ g/mL, respectively, compared to control values of 7.67 and 0.43  $\mu$ g/mL, respectively.<sup>44</sup> Elevated levels of xanthine and uric acid in AH may support the diagnosis of Rb in suspected children; however, further studies are necessary to establish optimal cutoffs, explore clinicopathological correlations, and compare Rb levels to lesions simulating Rb (Coats' disease and persistent fetal vasculature).

### Protein Content

In nonpathologic states, AH is virtually protein free. Protein concentration in the AH is known to be low due to the need for a clear optical region between the cornea and the lens for vision.<sup>57,58</sup> However, early studies demonstrated that Rb has been associated with an increase in globulin content and an albumin/globulin of  $<1$ .<sup>31</sup> To investigate the AH protein content in Rb patients, Hadjistilianou et al.<sup>25</sup> performed gel electrophoresis on the AH from

enucleated eyes with Rb and found that the AH protein concentration was significantly higher in Rb patients compared to controls with cataracts ( $P < 0.01$ ); in addition, significantly decreased protein concentration was demonstrated in eyes following treatment with selective intra-arterial chemotherapy (melphalan injection in the ophthalmic artery) that were subsequently enucleated after attempts at salvage compared to nontreated eyes ( $P < 0.01$ ).<sup>25</sup> Another study examined 45 cytokines/chemokines, matrix metalloproteinases, and acute-phase proteins in the AH of 35 enucleated eyes with Rb and 20 eyes with cataracts as controls.<sup>45</sup> The study found that the concentrations of interleukin 6 (IL-6), IL-7, IL-8, interferon  $\gamma$ , placenta growth factor 1, vascular endothelial growth factor A, nerve growth factor  $\beta$ , hepatocyte growth factor, epidermal growth factor, and fibroblast growth factor 2 were significantly higher in the AH of patients with Rb than those in the control group ( $P < 0.05$ ).<sup>45</sup> Two additional studies, with fair quality-assessment ratings due to the lack of control group comparisons, assayed AH from Rb patients postenucleation with electrochemical liquid chromatography and identified more than 20 metabolites of tyrosine, tryptophan metabolic pathways, catecholamine degradation pathways, and ascorbate.<sup>46,47</sup> Thus, although the technique is not currently used clinically, the determination of protein concentration in AH may be of value to monitor response to treatment.

One study further assessed AH proteins by using the comparative proteomic technique of isobaric tags for relative and absolute quantitation coupled with offline two-dimensional liquid chromatography-tandem mass spectrometry.<sup>27</sup> A total of 83 proteins that were expressed differently between the controls and patients' AH samples were identified using isobaric tags for relative and absolute quantitation analysis, including pigment epithelium-derived factor (PEDF) and retinoic acid 6 (STRA6).<sup>27</sup> The study revealed that the expression level of PEDF was lower in Rb than that in control samples. PEDF has been demonstrated to be an inhibitor of tumor cell invasion, migration, and metastasis and has been identified as a potent inhibitor of angiogenesis in the eye.<sup>59–61</sup> The anti-angiogenic effect of PEDF makes it a possible candidate as a therapy target for Rb. The study also demonstrated upregulated STRA6 in the AH of children with Rb. Overexpression of STRA6 has been observed in numerous types of human cancer, including Wilm kidney tumors; melanomas; and colorectal, ovarian, and endometrial cancer.<sup>62</sup> This suggests a

possible role for STRA6 in targeted therapy for Rb, although further research is required to identify the function of STRA6 in the development of Rb.

## Nucleic Acids

Nucleic acid levels (DNA, RNA, and microRNA) have recently been studied in AH samples from three Rb patients, namely, two post primary enucleation and one from a patient undergoing active therapy.<sup>28</sup> The AH samples from the latter patient were obtained through paracentesis with an extraction of 0.1 mL of AH, which was performed routinely as part of the procedure for intravitreal injection of melphalan.<sup>11,15</sup> The DNA concentration found in the AH was significantly higher in the eyes with primary enucleation (median, 30 ng/ $\mu$ L) than that in the treated eye (median, 0.2 ng/ $\mu$ L). Despite the low concentration, the DNA could be amplified and sequenced for chromosomal copy number alterations (gains and loss of regions of chromosomes). The genomic profiles from the DNA in the AH were consistent with those obtained from the tumor tissue postenucleation, demonstrating proof of principle that Rb tumor DNA can be found in the AH of advanced eyes.<sup>28</sup> These novel findings suggest that AH may serve as a surrogate tumor biopsy (a liquid biopsy) that could allow for an analyses of tumor-derived DNA in children with Rb, without undergoing enucleation, unlike all the previous studies included in this review. A subsequent analysis by Berry et al.<sup>29</sup> in 2018 showed that the genomic evaluation of cfDNA in the AH has significant prognostic potential. In the study, concentrations of cfDNA in the AH of eight Rb eyes ranged from 0.084 to 56 ng/ $\mu$ L, with a mean of 0.2 ng/ $\mu$ L for eyes receiving melphalan treatment, and much higher concentrations for large untreated tumors that underwent primary enucleation (mean, 43.6 ng/ $\mu$ L) than that of control eyes from children with congenital glaucoma (two patients) and pediatric cataracts (one patient), which demonstrated median cfDNA concentrations of 0.15 ng/ $\mu$ L (mean, 0.12 ng/ $\mu$ L; range, 0.05–0.16 ng/ $\mu$ L). Additionally, AH from 13 enucleated Rb eyes were compared against the AH extracted via paracentesis from 16 salvaged (saved) eyes. The presence of detectable somatic chromosomal copy number alterations was 92% in enucleated eyes versus 38% in salvaged eyes ( $P = 0.006$ ), with a gain of chromosome 6p being the most common. There were significantly increased odds of an eye failing therapy and requiring enucleation due to persistent or progressive disease activity if a gain of chromosome 6p was demonstrated in the AH cfDNA.

Further research is required before this information can be applied clinically, including AH sampling at diagnosis; however, this was the first time that tumor chromosomal changes could be compared between eyes that responded to therapy and those that failed therapy due to the ability to safely access AH in Rb eyes undergoing salvage therapy.

## Conclusion

Despite significant investigation into tumor markers for Rb spanning more than 4 decades, currently there are no active uses for the AH in a clinical setting. Diagnosis is made on the basis of examination, and imaging findings without a biopsy and molecular tumor markers are not used for diagnosis, prognosis, or to monitor therapeutic response (from any fluid including AH, serum, or tumor). This is due in large part to the contraindication to biopsy in Rb; therefore, previously neither tumor nor AH was evaluated outside of specimens from enucleated eyes, which clearly limited significant clinical correlations. However, with recent advances in local therapy for Rb, paracentesis with extraction of the AH has now been shown to be safe. This opens the door to use the AH as a liquid biopsy or surrogate to tumor biopsy for Rb.

This review highlights the various markers within AH that can now be safely examined in children with Rb without undergoing enucleation. Of specific interest are tumor biomarkers that may be associated with findings that cannot be determined by clinical examination and imaging alone; this includes associations with poorly differentiated tumors and post-laminar optic nerve invasion that are associated with higher risk disease and a small but present increased risk of metastatic disease for the child. Survivin and TGF- $\beta$ 1 may be valuable markers to associate with these features. High-quality studies from Shehata et al.<sup>24,43</sup> demonstrated the prognostic implications of AH survivin and TGF- $\beta$ 1, and the high sensitivity, specificity, and accuracy of serum and AH survivin and TGF- $\beta$ 1 make them promising markers for early detection and follow up of Rb patients. The gain of chromosome 6p is another marker associated with poor therapeutic outcomes and an aggressive tumor phenotype.<sup>29</sup> Taken together, these markers may better guide the clinician to understanding which eyes are likely to respond to therapy and benefit from attempts at salvage.

Other markers of clinical utility include those that correlate with treated disease and tumor status. In general, this can be determined by direct ophthalmic

examination; however, whether or not there are lurking vitreous seeds or tumor under calcified Rb scars can be difficult to determine on examination or imaging alone. Findings by Comoy et al.<sup>26</sup> have suggested that serial AH NSE measurements may have a significant role in determining tumor status in Rb patients, and future studies may further clinically substantiate the use of this tumor marker. Additionally, a high-quality study from Hadjistilianou et al.<sup>25</sup> demonstrated significantly decreased protein concentration in eyes following treatment with selective intra-arterial chemotherapy. If AH markers such as NSE, protein concentration, PEDF, or STRA6 could reliably indicate remission in treated eyes, this would be a significant clinical benefit to both the patients and the practitioners. Furthermore, these authors have suggested that PEDF and STRA6 should be further examined for future directions in targeted therapy in Rb.<sup>62</sup> The remaining biochemical markers that have been previously investigated, including xanthine and uric acid, have shown potential in diagnostic utility; however, further studies would be necessary to elucidate their significant clinical utility, including prognostic, clinicopathological, and therapeutic implications.

In the late 20th century, biochemical markers, including LDH, were widely investigated within body fluids in various pathological and malignant conditions. Although LDH was the first described marker of tumor activity in the AH, the lack of specificity and correlation with patient or tumor features limit its use clinically. Trends in the choice of biomarker surveillance have evolved over time and reflect the limits of technology during the era in which they were identified. Accordingly, a shift from biochemical toward genomic markers has also occurred. The 2017 study from Berry et al.<sup>28</sup> was the first to describe AH as a surrogate tumor biopsy, allowing clinicians to safely examine tumor DNA in children with Rb during therapy (e.g., in an eye that has not been enucleated). A follow-up study by Berry et al.<sup>29</sup> demonstrated significantly increased odds of an eye failing therapy and requiring enucleation due to persistent or progressive disease activity if a gain of chromosome 6p was demonstrated in the AH cfDNA, suggesting prognostic potential. Furthermore, this suggests a possible marker for targeted therapy by evaluation of chromosome 6p.<sup>29</sup> Expression analysis has identified genes targeted by 6p genomic gain, in which the specific genes DEK and E2F3 showed developmental regulation.<sup>63</sup> The study further showed that E2F3 and DEK mRNA overexpression was

associated with protein overexpression, which was determined by immunoblotting or immunofluorescent staining of primary tumors, relative to the adjacent normal retina.<sup>63</sup> Both DEK and E2F3 have important oncogenic roles in multiple cancers. DEK, first discovered in acute myeloid leukemia, is overexpressed in multiple cancers, including melanoma, hepatocellular carcinomas, brain tumors, and breast cancers, and evidence has suggested that DEK overexpression may facilitate tumor progression and perhaps chemoresistance.<sup>64–67</sup> Additionally, E2F3 overexpression has been implicated in bladder, prostate, lung, and breast cancers, and small interfering RNA-mediated knock down of this gene has significantly reduced its proliferative capacity.<sup>65,67–69</sup> These results suggest that inactivation of DEK and E2F3 remains an attractive therapeutic target in multiple cancers, including Rbs.<sup>70</sup>

With increased access to AH in Rb eyes, future investigation of these genes, as well as the previously mentioned biochemical markers, is possible. Although AH evaluation is currently not used clinically for patients with Rb, with further investigation into specific biochemical and genomic markers and their associations with treatment response and potential as therapeutic targets, AH sampling and analysis has the potential to revolutionize the way Rb is managed.

## Acknowledgments

Supported by Knights Templar Eye Foundation; The Larry and Celia Moh Foundation; The Institute for Families, Inc.; Children's Hospital Los Angeles; an unrestricted departmental grant from Research to Prevent Blindness; USC Dornsife College of Letters, Arts and Sciences; National Cancer Institute of the National Institutes of Health award number K08CA232344; and American Cancer Society number IRG-16-181-57.

Disclosure: **B.K. Ghiam**, None; **L. Xu**, None; **J.L. Berry**, None

## References

1. Shields JA, Shields CL. Management and prognosis of retinoblastoma. In: *Intraocular Tumors: a*

*Text and Atlas*. Philadelphia, PA: WB Saunders; 1992:377–391.

2. Shields JA, Shields CL. *Intraocular Tumors: an Atlas and Textbook*. Philadelphia, PA: Lippincott Williams & Wilkins; 2008:570–574.
3. Pavan-Langston D. *Manual of Ocular Diagnosis and Therapy*. Philadelphia, PA: Lippincott Williams & Wilkins; 2008:500–533.
4. Shields CL, Honavar SG, Shields JA, Demirci H, Meadows AT, Naduvilath TJ. Factors predictive of recurrence of retinal tumors, vitreous seeds, and subretinal seeds following chemoreduction for retinoblastoma. *Arch Ophthalmol*. 2002;120:460–464.
5. Karcioğlu ZA. Fine needle aspiration biopsy (FNAB) for retinoblastoma. *Retina*. 2002;22:707–710.
6. Shields JA, Shields CL, Ehya H, Eagle RC Jr, De Potter P. Fine-needle aspiration biopsy of suspected intraocular tumors. The 1992 Urwick Lecture. *Ophthalmology*. 1993;100:1677–1684.
7. Eide N, Syrdalen P, Walaas L, Hagmar B. Fine needle aspiration biopsy in selecting treatment for inconclusive intraocular disease. *Acta Ophthalmol Scand*. 1999;77:448–452.
8. Eide N, Walaas L. Fine-needle aspiration biopsy and other biopsies in suspected intraocular malignant disease: a review. *Acta Ophthalmol*. 2009;87:588–601.
9. Eriksson O, Hagmar B, Ryd W. Effects of fine-needle aspiration and other biopsy procedures on tumor dissemination in mice. *Cancer*. 1984;54:73–78.
10. Ali MJ, Honavar SG, Vemuganti GK, Singh AD. Fine needle aspiration biopsy of retinal tumors. In: *Monographs in Clinical Cytology*. 2011:72–81.
11. Munier FL, Soliman S, Moulin AP, Gaillard M-C, Balmer A, Beck-Popovic M. Profiling safety of intravitreal injections for retinoblastoma using an anti-reflux procedure and sterilisation of the needle track. *Br J Ophthalmol*. 2012;96:1084–1087.
12. Ghassemi F, Shields CL, Ghadimi H, Khodabandeh A, Roohipoor R. Combined intravitreal melphalan and topotecan for refractory or recurrent vitreous seeding from retinoblastoma. *JAMA Ophthalmol*. 2014;132:936.
13. Lawson BM, Saktanasate J, Say EAT, Shields CL. Intravitreal chemotherapy provides control for massive vitreous seeding from retinoblastoma. *J Pediatr Ophthalmol Strabismus*. 2014;51:e92–4.
14. Francis JH, Schaiquevich P, Buitrago E, Del Sole MJ, Zapata G, Croxatto JO, et al. Local and systemic toxicity of intravitreal melphalan for

- vitreous seeding in retinoblastoma: a preclinical and clinical study. *Ophthalmology*. 2014;121:1810–1817.
15. Munier FL, Gaillard M-C, Balmer A, Beck-Popovic M. Intravitreal chemotherapy for vitreous seeding in retinoblastoma: recent advances and perspectives. *Saudi J Ophthalmol*. 2013;27:147–150.
  16. Smith SJ, Smith BD. Evaluating the risk of extraocular tumour spread following intravitreal injection therapy for retinoblastoma: a systematic review. *Br J Ophthalmol*. 2013;97:1231–1236.
  17. Smith SJ, Smith BD, Mohny BG. Ocular side effects following intravitreal injection therapy for retinoblastoma: a systematic review. *Br J Ophthalmol*. 2013;98:292–297.
  18. Cole DF. Secretion of the aqueous humour. *Exp Eye Res*. 1977;25:161–76.
  19. Macknight AD, McLaughlin CW, Peart D, Purves RD, Carre DA, Civan MM. Formation of the aqueous humor. clinical and experimental pharmacology and physiology. 2000;27:100–106.
  20. To CH, Kong CW, Chan CY, Shahidullah M, Do CW. The mechanism of aqueous humour formation. *Clin Exp Optom*. 2002;85:335–349.
  21. Dias PL, Shanmuganathan SS, Rajaratnam M. Lactic dehydrogenase activity of aqueous humour in retinoblastoma. *Br J Ophthalmol*. 1971;55:130–132.
  22. Dias PL. Correlation of aqueous humour lactic acid dehydrogenase activity with intraocular pathology. *Br J Ophthalmol*. 1979;63:574–577.
  23. Dias PL. Prognostic significance of aqueous humour lactic dehydrogenase activity. *Br J Ophthalmol*. 1979;63:571–573.
  24. Shehata HH, Abou Ghalia AH, Elsayed EK, Ahmed Said AM, Mahmoud SS. Clinical significance of high levels of survivin and transforming growth factor beta-1 proteins in aqueous humor and serum of retinoblastoma patients. *J AAPOS*. 2016;20:444.e1–444.e9.
  25. Hadjistilianou T, Giglioni S, Micheli L, Vannoni D, Brogi E, Cevenini G, et al. Analysis of aqueous humour proteins in patients with retinoblastoma. *Clin Experiment Ophthalmol*. 2012;40:e8–15.
  26. Comoy E, Roussat B, Henry I, Bloch-Michel E. [Neuron-specific enolase in the aqueous humor. Its significance in the differential diagnosis of retinoblastoma]. *Ophthalmologie*. 1990;4:233–235.
  27. Cheng Y, Meng Q, Huang L, Shi X, Hou J, Li X, et al. iTRAQ-based quantitative proteomic analysis and bioinformatics study of proteins in retinoblastoma. *Oncol Lett*. 2017;14:8084–8091.
  28. Berry JL, Xu L, Murphree AL, Krishnan S, et al. Potential of aqueous humor as a surrogate tumor biopsy for retinoblastoma. *JAMA Ophthalmol*. 2017;135:1221–1230.
  29. Berry JL, Xu L, Kooi I, et al. Genomic analysis of aqueous humor cell-free DNA in retinoblastoma predicts eye salvage: the surrogate tumor biopsy for retinoblastoma. *Mol Cancer Res*. 2018;16:1701–1712.
  30. Moher D, Liberati A, Tetzlaff J, Altman DG, The PRISMA Group. Preferred reporting items for systematic reviews and meta-analyses: the PRISMA statement. *PLoS Med*. 2009;6:e1000097.
  31. Dias PL. Postinflammatory and malignant protein patterns in aqueous humour. *Br J Ophthalmol*. 1979;63:161–164.
  32. Kabak J, Romano PE. Aqueous humour lactic dehydrogenase isoenzymes in retinoblastoma. *Br J Ophthalmol*. 1975;59:268–269.
  33. Piro PA Jr, Abramson DH, Ellsworth RM, Kitchin D. Aqueous humor lactate dehydrogenase in retinoblastoma patients. Clinicopathologic correlations. *Arch Ophthalmol*. 1978;96:1823–1825.
  34. Abramson DH, Piro PA, Ellsworth RM, Kitchin FD, McDonald M. Lactate dehydrogenase levels and isozyme patterns. Measurements in the aqueous humor and serum of retinoblastoma patients. *Arch Ophthalmol*. 1979;97:870–871.
  35. Das A, Roy IS, Maitra TK. Lactate dehydrogenase level and protein pattern in the aqueous humour of patients with retinoblastoma. *Can J Ophthalmol*. 1983;18:337–339.
  36. Dayal Y, Goyal JL, Jaffery NF, Agarwal HC. Lactate dehydrogenase levels in aqueous humor and serum in retinoblastoma. *Jpn J Ophthalmol*. 1985;29:417–422.
  37. Singh R, Kaurya OP, Shukla PK, Ramputty R. Lactate dehydrogenase (LDH) isoenzymes patterns in ocular tumours. *Indian J Ophthalmol*. 1991;39:44–47.
  38. Mukhopadhyay S, Ghosh S, Biswas PN, Dutta SK, Chattopadhyay D. A cross-sectional study on aqueous humour lactate dehydrogenase level in retinoblastoma. *J Indian Med Assoc*. 2008;106:99–100.
  39. Wu Z, Yang H, Pan S, Chen Z. Electrophoretic determination of aqueous and serum neuron-specific enolase in the diagnosis of retinoblastoma. *Yan Ke Xue Bao*. 1997;13:12–16.
  40. Shine BS, Hungerford J, Vaghela B, Sheraidah GA. Electrophoretic assessment of aqueous and serum neurone-specific enolase in retinoblastoma

- and ocular malignant melanoma. *Br J Ophthalmol*. 1990;74:427–430.
41. Abramson DH, Greenfield DS, Ellsworth RM, et al. Neuron-specific enolase and retinoblastoma. Clinicopathologic correlations. *Retina*. 1989;9:148–152.
  42. Nakajima T, Kato K, Kaneko A, Tsumuraya M, Morinaga S, Shimosato Y. High concentrations of enolase, alpha- and gamma-subunits, in the aqueous humor in cases of retinoblastoma. *Am J Ophthalmol*. 1986;101:102–106.
  43. Shehata HH, Abou Ghalia AH, Elsayed EK, Ziko OO, Mohamed SS. Detection of survivin protein in aqueous humor and serum of retinoblastoma patients and its clinical significance. *Clin Biochem*. 2010;43:362–366.
  44. Mendelsohn ME, Abramson DH, Senft S, Servodidio CA, Gamache PH. Uric acid in the aqueous humor and tears of retinoblastoma patients. *J AAPOS*. 1998;2:369–371.
  45. Cheng Y, Zheng S, Pan C-T, et al. Analysis of aqueous humor concentrations of cytokines in retinoblastoma. *PLoS One*. 2017;12:e0177337.
  46. Abramson DH, Senft SH, Servodidio CA, Ellsworth RM, Gamache PH. Retinoblastoma aqueous humor: aromatic amino acids. *Ophthalmic Paediatr Genet*. 1993;14:127–130.
  47. Abramson DH, Piro PA, DeCresce R, Ellsworth RM, Kitchin D. Catecholamine metabolites in the aqueous of retinoblastoma. *J Pediatr Ophthalmol Strabismus*. 1978;15:77–78.
  48. Wroblewski F. The clinical significance of alterations in lactic dehydrogenase activity of body fluids. *Am J Med Sci*. 1957;234:301–312.
  49. Dias PL. Electrolyte imbalances in the aqueous humour in retinoblastoma. *Br J Ophthalmol*. 1985;69:462–463.
  50. Jovanovic P, Zoric L, Stefanovic I, et al. Lactate dehydrogenase and oxidative stress activity in primary open-angle glaucoma aqueous humour. *Bosn J Basic Med Sci*. 2010;10:83–88.
  51. Jakobiec FA, Abramson D, Scher R. Increased aqueous lactate dehydrogenase in Coats' disease. *Am J Ophthalmol*. 1978;85:686–689.
  52. Isgrò MA, Bottoni P, Scatena R. Neuron-specific enolase as a biomarker: biochemical and clinical aspects. *Adv Exp Med Biol*. 2015;867:125–143.
  53. Kivelä T. Neuron-specific enolase in retinoblastoma. *Acta Ophthalmol*. 2009;64:19–25.
  54. Andersen MH, Svane IM, Becker JC, Straten PT. The universal character of the tumor-associated antigen survivin. *Clin Cancer Res*. 2007;13:5991–5994.
  55. Rohayem J, Diestelkoetter P, Weigle B, et al. Antibody response to the tumor-associated inhibitor of apoptosis protein survivin in cancer patients. *Cancer Res*. 2000;60:1815–1817.
  56. Johnson ME, Howerth EW. Survivin: a bifunctional inhibitor of apoptosis protein. *Vet Pathol*. 2004;41:599–607.
  57. Freddo TF, Bartels SP, Barsotti MF, Kamm RD. The source of proteins in the aqueous humor of the normal rabbit. *Invest Ophthalmol Vis Sci*. 1990;31:125–137.
  58. Barsotti MF, Bartels SP, Freddo TF, Kamm RD. The source of protein in the aqueous humor of the normal monkey eye. *Invest Ophthalmol Vis Sci*. 1992;33:581–595.
  59. Dawson DW. Pigment epithelium-derived factor: a potent inhibitor of angiogenesis. *Science*. 1999;285:245–248.
  60. Subramanian P, Deshpande M, Locatelli-Hoops S, et al. Identification of pigment epithelium-derived factor protein forms with distinct activities on tumor cell lines. *J Biomed Biotechnol*. 2012;2012:1–12.
  61. Guan M, Tripathi V, Zhou X, Popescu NC. Adenovirus-mediated restoration of expression of the tumor suppressor gene DLC1 inhibits the proliferation and tumorigenicity of aggressive, androgen-independent human prostate cancer cell lines: prospects for gene therapy. *Cancer Gene Ther*. 2008;15:371–381.
  62. Szeto W, Jiang W, Tice DA, et al. Overexpression of the retinoic acid-responsive gene Stra6 in human cancers and its synergistic induction by Wnt-1 and retinoic acid. *Cancer Res*. 2001;61:4197–4205.
  63. Orlic M, Spencer CE, Wang L, Gallie BL. Expression analysis of 6p22 genomic gain in retinoblastoma. *Genes Chromosomes Cancer*. 2006;45:72–82.
  64. von Lindern M, Fornerod M, van Baal S, et al. The translocation (6;9), associated with a specific subtype of acute myeloid leukemia, results in the fusion of two genes, dek and can, and the expression of a chimeric, leukemia-specific dek-can mRNA. *Mol Cell Biol*. 1992;12:1687–1697.
  65. Corson TW, Gallie BL. One hit, two hits, three hits, more? Genomic changes in the development of retinoblastoma. *Genes Chromosomes Cancer*. 2007;46:617–634.
  66. Privette Vinnedge LM, Ho SM, Wikenheiser-Brokamp KA, Wells SI. The DEK oncogene is a target of steroid hormone receptor signaling in breast cancer. *PLoS One*. 2012;7:e46985.

67. Privette Vinnedge LM, Kappes F, Nassar N, Wells SI. Stacking the DEK: from chromatin topology to cancer stem cells. *Cell Cycle*. 2013;12:51–66.
68. Vimala K, Sundarraj S, Sujitha MV, Kannan S. Curtailing overexpression of E2F3 in breast cancer using siRNA (E2F3)-based gene silencing. *Arch Med Res*. 2012;43:415–422.
69. Olsson AY, Feber A, Edwards S, et al. Role of E2F3 expression in modulating cellular proliferation rate in human bladder and prostate cancer cells. *Oncogene*. 2007;26:1028–1037.
70. Theriault BL, Dimaras H, Gallie BL, Corson TW. The genomic landscape of retinoblastoma: a review. *Clin Experiment Ophthalmol*. 2014;42:33–52.