

Article

Relationship Between Neutralizing Antibodies Against Adeno-Associated Virus in the Vitreous and Serum: Effects on Retinal Gene Therapy

Suhwan Lee^{1,*}, Im Kyeong Kang^{2,3,*}, Ji Hyun Kim^{2,3}, Bok Kyoung Jung⁴, Keerang Park⁵, Heesoon Chang⁶, Joo Yong Lee^{3,4}, and Heuiran Lee^{2,3}

¹ Department of Ophthalmology, Kangwon National University Hospital, Kangwon National University Graduate School of Medicine, Chuncheon, Korea

² Department of Microbiology, University of Ulsan College of Medicine, Seoul, Korea

³ Bio-Medical Institute of Technology, University of Ulsan College of Medicine, Seoul, Korea

⁴ Department of Ophthalmology, Asan Medical Center, University of Ulsan College of Medicine, Seoul, Korea

⁵ Biopharmaceutical R&D Center, Chungbuk Health & Science University, Cheongju-si, Chungbuk, Korea

⁶ KRgeneBIO Co., Ltd., Cheongju-si, Chungbuk, Korea

Correspondence: Joo Yong Lee, Department of Ophthalmology, Asan Medical Center, University of Ulsan, College of Medicine, 88 Olympic-ro 43 Gil Songpa-gu, Seoul 05505, Republic of Korea. e-mail: ophthalmology@amc.seoul.kr
Heuiran Lee, Department of Microbiology, Bio-Medical Institute of Technology, University of Ulsan, College of Medicine, 88 Olympic-ro 43 Gil Songpa-gu, Seoul 05505, Republic of Korea. e-mail: heuiran@amc.seoul.kr

Received: 10 September 2018

Accepted: 26 December 2018

Published: 9 April 2019

Keywords: neutralizing antibody; adeno-associated virus serotype; vitreous humor; serum; gene therapy; blood-retinal barrier

Citation: Lee S, Kang IK, Kim JH, Jung BK, Park K, Chang H, Lee JY, Lee H. Relationship between neutralizing antibodies against adeno-associated virus in the vitreous and serum: effects on retinal gene therapy. *Trans Vis Sci Tech.* 2019;8(2):14, <https://doi.org/10.1167/tvst.8.2.14>
Copyright 2019 The Authors

Purpose: We determine the prevalence of neutralizing antibodies (NAbs) to adeno-associated virus (AAV) in the vitreous humor and serum of patients with vitreoretinal diseases and investigate the relationship between NAb titers in the vitreous humor and serum.

Methods: We analyzed NAbs to AAV serotypes 2, 5, 8, and 9 via in vitro neutralization in the vitreous humor and serum from 32 patients requiring vitrectomy for vitreoretinal diseases. The blood-retinal barrier (BRB) was evaluated for integrity based on preoperative examinations, with vitreous hemorrhage (VH) on funduscopy or dye leakage on fluorescein angiography observed indicating disruption.

Results: NAb levels were much lower in the vitreous humor than in the serum regardless of serotype. Patients with VH had higher levels of NAbs in the vitreous humor than those without VH. The NAb ratio (ratio between NAb titers in the serum and vitreous humor) was much lower in patients with epiretinal membrane with than in those without leakage. A significantly lower NAb ratio was noticed in patients with than in those without BRB disruptions.

Conclusions: The NAb ratio between levels in serum and vitreous humor varies according to the condition of the BRB. Therefore, in addition to measuring the serum NAb level, physicians should examine BRB integrity when planning retinal gene therapy.

Translational Relevance: This study provides substantial basis for retinal gene therapy using AAVs and how maintenance of BRB integrity in target diseases should be considered.

Introduction

Adeno-associated virus (AAV) vectors are common gene delivery tools in gene therapy due to their

major safety and efficiency advantages.¹⁻⁴ As AAV vector-based retinal gene therapy proved to be successful in early clinical trials of inherited disorders, the clinical application of gene therapy recently has

expanded to acquired retinal diseases, such as age-related macular degeneration (AMD).^{5,6}

Humoral anti-AAV antibody-mediated immunity, especially pre-existing immunity resulting from childhood exposure to AAVs, is a well-known, significant limiting factor to the efficacy of gene therapy using AAV as a gene delivery vehicle.^{7,8} Thus, the possibility of such baseline serum antibodies directed against AAV having negative effects on transgene expression is a crucial subject that must be investigated. Several previous studies conducted in humans and large animal models suggest that high levels of pre-existing neutralizing antibodies (Nabs) in the serum could interfere with transgene expression in retinal gene therapy, especially after intravitreal delivery.^{6,9}

However, whether the presence of serum antibodies against AAVs would have a direct effect on transgene expression of retinal gene therapy remains controversial. This is because retinal gene therapy uses a subretinal or intravitreal space, which is considered immunologically different from other tissues.^{10,11} Nonetheless, little information regarding pre-existing NAbs is present in the human vitreous humor, which would be the basis for answering these questions. Accordingly, the correlation between NAb titers in the serum and vitreous humor also is not established to our knowledge. Moreover, many components of the immune-privileged status of the eye, such as the presence of blood–retinal barriers (BRBs), could be compromised under pathologic conditions.¹² Therefore, an investigation of the immunologic status of the intraocular space of a diseased eye in relation to the healthy eye is necessary for future developments.

We report, to our knowledge, the first analytical examination of NAbs against four different serotypes of AAV (2, 5, 8, and 9) in the vitreous humor and serum of patients with various vitreoretinal diseases. Each serotype represents a phylogenetically divergent clade of the AAV family; the origin of serotypes 2, 5, and 9 is human, whereas serotype 8 is thought to have originated in the rhesus macaque.^{13,14} The usefulness of these AAVs with distinct tissue tropisms has been investigated intensively in preclinical and clinical trial studies.^{14,15} The relationship between NAb titers in the serum and vitreous humor was scrutinized further to determine whether differences existed depending on the pathologic disease status of the retina.

Materials and Methods

Patients and Grouping

Patients requiring pars plana vitrectomy for treatment of vitreoretinal diseases at the Department of Ophthalmology of Asan Medical Center, Seoul, Korea, from September 21, 2017, to January 18, 2018, were included consecutively in this study. The study was approved by the institutional review board and ethics committee of Asan Medical Center (2017-0968) and adhered to the tenets of the Declaration of Helsinki. All patients gave their written informed consent before enrollment. Patients younger than 18 or older than 80 years and those who had previously undergone pars plana vitrectomy were excluded from the study. Each patient underwent complete ophthalmologic examination preoperatively according to disease status. Based on preoperative evaluation, especially with regard to the presence of vitreous hemorrhage (VH) on fundus examination and leakage at the peak phase on fluorescein angiography (FA), we assessed the status of BRB maintenance (Fig. 1). The integrity of the BRB was considered disrupted when there was evidence of VH or leakage on FA.

Samples

Pars plana vitrectomy was performed by a vitreoretinal surgeon (JYL) using the standard 25-gauge vitrectomy system. The vitreous samples were collected in the operating room through undiluted lines using a vitreous cutter. Undiluted vitreous samples were obtained using a 3-mL syringe connected directly to the handpiece until the eye was visibly noted to soften. At least 2 mL of undiluted vitreous was collected in each case; 3 mL serum samples were collected on the day before or day of surgery. The samples were maintained in the collection syringe and were delivered to the clinical laboratory immediately after they were obtained. Blood was clotted overnight at 4°C, and the serum was collected after centrifugation. Both samples were aliquoted and stored at –80°C until use.

Cell Culture and Preparation of AAV Serotypes

HeLa cells were cultured in Dulbecco's modified Eagle medium (DMEM; Invitrogen, Carlsbad, CA) with 10% fetal bovine serum (FBS; Invitrogen), 15 mM HEPES (Sigma-Aldrich Corp., St. Louis, MO), GlutaMAX-1 (2 mM), and penicillin (100 IU/mL/

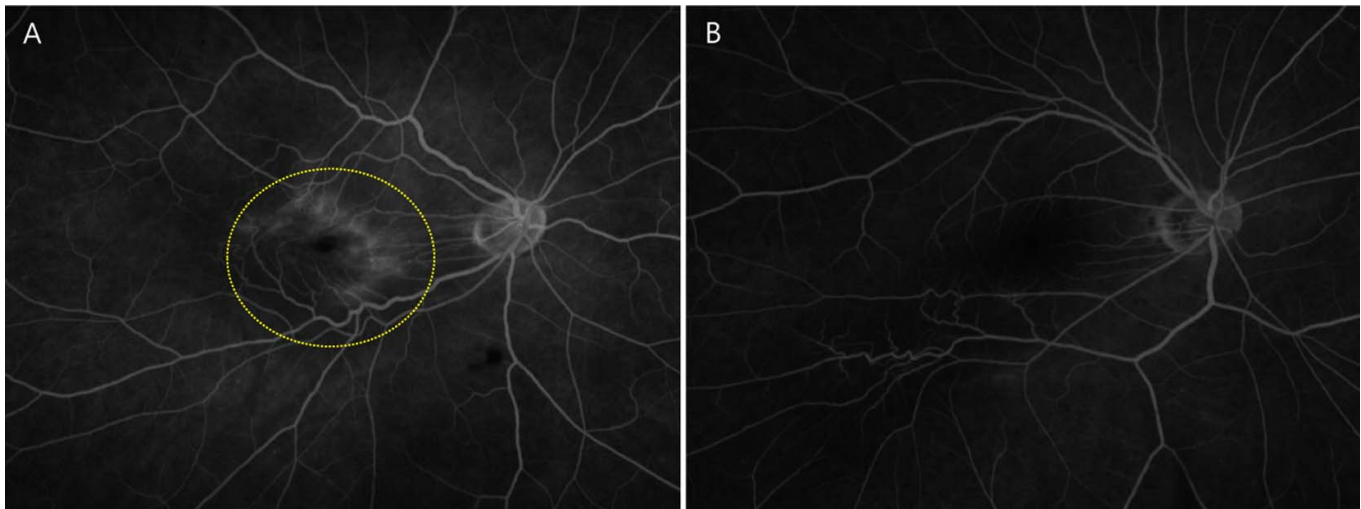


Figure 1. Classification of patients with ERM according to dye leakage in FA images. (A) FA image of patient with leakage observed in the macula area at peak phase (dotted yellow line). (B) FA image of patient without leakage. ERM = epiretinal membrane; FA = fluorescein angiography.

streptomycin (50 $\mu\text{g}/\text{mL}$) and then maintained at 37°C under humidified 5% CO_2 . The AAV serotypes 2, 5, 8, 9 expressing green fluorescent protein (GFP) were produced using a triple cotransfection method as described previously¹⁶ and were supplied by Cdmogen Co., Ltd. (Cheongju, Korea).

Neutralizing Antibody Determination

HeLa cells in 96-wells were infected with AAV2, 5, 8, and 9 to achieve approximately 50% of GFP-positive cells at multiplicity of infection (MOI) values of 200, 200, 5000, and 10,000, respectively. The cells were coinfecting with adenovirus 5 for efficient transduction. After 2 days, the percentage of cells showing GFP signal was determined under fluorescence microscopy. Neutralizing titers of the sample were calculated as the highest dilution that inhibited 50% of transduction. Samples were considered to have neutralizing activity if 1:20 dilution inhibited vector transduction by at least 50%.

Statistical Analysis

The Wilcoxon signed rank test was used to compare the NAb titers in serum and vitreous humor for each patient. The Mann–Whitney U test was used to determine the significant differences between the two groups. For correlation between the NAb titers in serum and vitreous humor, we used Spearman's correlation test. All statistical analyses were performed using SPSS 22.0 for Windows (SPSS, Chica-

go, IL), and $P < 0.05$ was considered statistically significant.

Results

Patient Characteristics

A total of 32 consecutive patients (16 men, 16 women; median age, 65.5 years; interquartile range, 54.3–70.0) were enrolled in this study (Supplementary Table S1). The presence of an epiretinal membrane (ERM) was the most common reason for surgery ($n = 15$, 46.9%), followed by diabetic VH ($n = 10$, 31.3%), macular hole ($n = 3$, 9.3%), intraocular lens dislocation ($n = 2$, 6.3%), and VH associated with retinal vein occlusion ($n = 1$, 3.1%) and with AMD ($n = 1$, 3.1%). Among patients with an ERM, nine did not and six did show dye leakage on preoperative FA (Fig. 1).

Pre-existing NAb in Serum

The results of NAb titers against each serotype in serum are shown in Table 1 and Figure 2. Among all serotypes, serotype 2 showed overwhelmingly high NAb titers, followed by AAV5, AAV9, and AAV8. When the seropositive criteria were set at 1:100 and 1:400 dilution, NAb against serotype 2 were observed most frequently. Although no patient had an NAb titer >2000 against AAV8 or AAV9, 19 (59.4%) and three (9.4%) patients had NAb titers >2000 against AAV2 and AAV5, respectively. No patient had an NAb titer >400 against AAV8. Most patients with NAb to serotype 5, 8, or 9 had coprevalent

Table 1. Neutralizing Titers to AAV in Serum and Vitreous Humor From 32 Patients

| Serotype | Neutralizing Titer in Serum Median (IQR) | Neutralizing Titer in Vitreous Humor Median (IQR) | P Value |
|----------|---|--|---------|
| AAV2 | 2673.0 (607.0–13226.5) | 20.0 (2.0–86.3) | <0.001 |
| AAV5 | 171.0 (46.5–520.0) | 2.0 (2.0–4.8) | <0.001 |
| AAV8 | 10.5 (6.3–40.8) | 2.0 (2.0–2.0) | <0.001 |
| AAV9 | 92.0 (13.5–280.3) | 2.0 (2.0–2.0) | <0.001 |

NABs to serotype 2. Only one patient was negative for NABs against AAV2, but positive for another serotype at the seropositive criterion of 1:100 (Supplementary Figure S1).

Pre-existing NAb Titer in the Vitreous Humor

The neutralizing activities for vitreous humor are shown in Table 1 and Figure 3. Similar to the results for serum, NAb titer against serotype 2 in the vitreous humor was confirmed to be the highest and NAb titer against serotype 8 was the lowest. However, the absolute value of NAb titer in the vitreous humor was much lower than that in the serum. NAb titers >100 were observed against serotype 2 in seven patients (21.9%) and against serotype 5 in one (3.1%); titers >400 were observed only against serotype 2 in three patients (9.4%). Among the underlying vitreoretinal disease conditions in the eight patients with NAb titers >100, five patients had diabetic VH, one had VH associated with AMD, and one had a macular hole. All patients with NAb titers >400 had diabetic VH. All patients with NABs to serotypes 5 or 9 had coprevalent NABs to serotype 2 (Supplementary Figure S2).

Comparison According to Disease Characteristics

Presence or Absence of VH

Of the 32 patients, 12 had VH and 20 did not. Table 2 shows the NAB titers in the serum and vitreous humor, and the ratio between NAB titers in the serum and vitreous humor (NAB ratio) against serotypes 2 and 5 according to the presence or absence of VH. There was no difference between the two groups in NAB titers in the serum, but patients with VH had significantly higher NAB titers to serotypes 2 and 5 in the vitreous humor (113.0 vs. 9.5, $P = 0.004$, and 4.5 vs. 2.0, $P = 0.028$) and lower NAB ratios to serotype 2 (28.0 vs. 216.2, $P < 0.001$) compared with patients who did not have VH.

Presence or Absence of Leakage in Patients With ERM

Table 3 shows the NAB titers in the serum and vitreous humor, and the ratio between NAB titers in the serum and the vitreous humor (NAB ratio) against serotypes 2 and 5 according to the presence or absence of leakage in patients with ERM. Patients with leakage that was observed on a preoperative FA scan

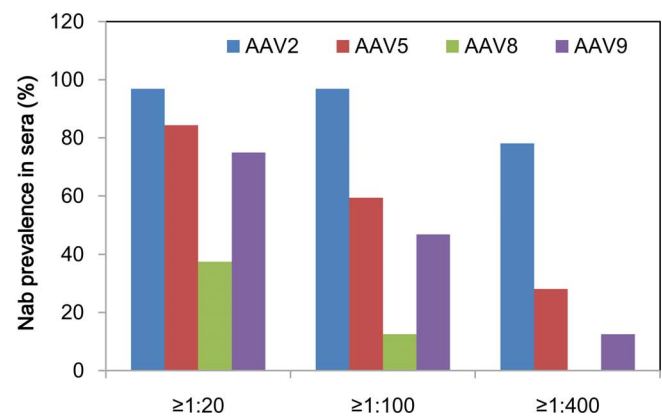
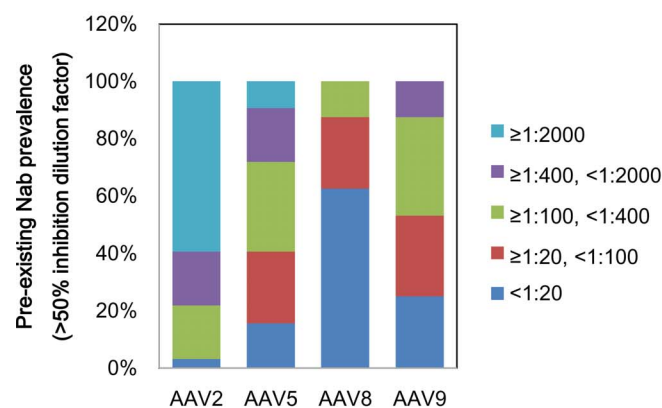


Figure 2. Prevalence of pre-existing NABs in the serum. Samples from 32 subjects were assayed within 1 month after pars plana vitrectomy. The percentages of serum titer ranges are shown for samples positive for NABs against each serotype, as well as the distribution by range of neutralizing titers against AAV2, AAV5, AAV8, and AAV9. AAV = adeno-associated virus; NABs = neutralizing antibodies.

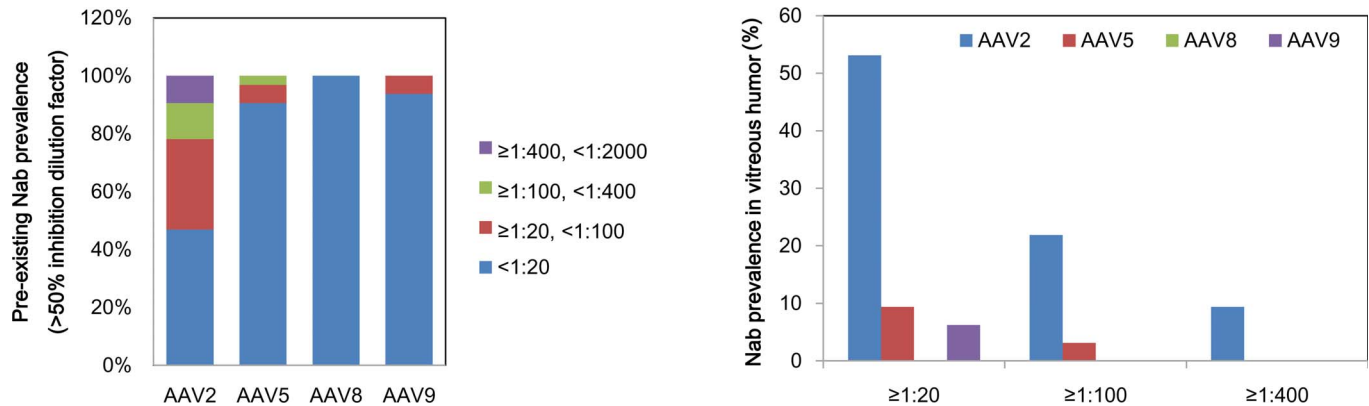


Figure 3. Prevalence of pre-existing NABs in the vitreous humor. The percentages of vitreous humor titer ranges are shown for samples positive for NABs against each serotype, as well as the distribution by range of neutralizing titers against AAV2, AAV5, AAV8, and AAV9. AAV = adeno-associated virus; NABs = neutralizing antibodies.

had significantly lower NAb ratios to serotypes 2 and 5 than those without leakage (80.0 vs. 324.0, $P=0.004$ and 10.6 vs. 85.5, $P=0.037$).

Presence or Absence of a Disrupted BRB

Nineteen patients with preoperative VH or ERM with preoperative fluorescein leakage were classified as having a disease in which the BRB had been disrupted (group A), and 13 were classified as having a disease in which the BRB was intact (group B; Table 4). Among the 19 group A patients, 12 had VH and 7 had ERM along with leakage. Group B had eight patients with ERM without leakage, three with a macular hole, and two with intraocular lens dislocation. There were no differences between the two groups in NAb titers in the serum and NAb titers to serotype 2 in the vitreous humor, but group A patients had significantly higher NAb titers to serotype 5 in the vitreous humor (3.0 vs. 2.0, $P=0.036$) and lower NAb ratios to serotypes 2 and 5 (48.9 vs. 350.0, $P<0.001$, and 26.5 vs. 85.5, $P=0.001$) than group B patients.

Relationship Between Neutralizing Activity Against Serotype 2 in the Serum and Vitreous Humor

Overall, there were no significant correlations between the titers of NABs in the serum and vitreous humor (Fig. 4). However, when the data were analyzed according to BRB maintenance, a strong positive correlation was found between the NABs titers in the serum and vitreous humor in patients with disrupted BRBs ($r=0.917$, $P<0.001$), whereas no significant correlation was found in patients with intact BRBs ($r=0.381$, $P=0.199$). In most cases of intact BRB, NAb titers in the vitreous humor remained low, regardless of NAb titers in the serum.

Discussion

We surveyed the prevalence of pre-existing NABs against various AAV serotypes in the human vitreous humor. The relationship between NAb titers in the serum and vitreous humor also was examined by determining differences in these values according to

Table 2. Comparison of NAb Titer and NAb Ratio to AAV2 and AAV5 According to Presence or Absence of VH

| Serotype | Variable | Patients With VH, | Patients Without VH, | <i>P</i> Value |
|----------|------------------------------------|-------------------------------|-------------------------------|----------------|
| | | <i>n</i> = 12 Median (IQR) | <i>n</i> = 20 Median (IQR) | |
| AAV2 | NAb titer in serum | 6513.0 (304.0–13653.0) | 2560.0 (607.0–8960.0) | 0.639 |
| | NAb titer in vitreous humor | 113.0 (16.0–498.0) | 9.5 (2.0–34.5) | 0.004 |
| | NAb ratio (serum / vitreous humor) | 28.0 (17.8–52.2) | 216.2 (80.0–864.0) | <0.001 |
| AAV5 | NAb titer in serum | 179.0 (40.0–640.0) | 165.5 (49.3–290.3) | 0.716 |
| | NAb titer in vitreous humor | 4.5 (2.0–12.8) | 2.0 (2.0–2.75) | 0.028 |
| | NAb ratio (serum / vitreous humor) | 42.7 (10.5–63.6) | 80.0 (14.4–138.1) | 0.106 |

Table 3. Comparison of NAb Titer and NAb Ratio to AAV2 and AAV5 According to Presence or Absence of Leakage in Patients With ERM

| Serotype | Variable | Patients With ERM Accompanying Leakage in FA, <i>n</i> = 7 Median (IQR) | Patients With ERM not Accompanying Leakage in FA, <i>n</i> = 8 Median (IQR) | <i>P</i> Value |
|----------|------------------------------------|--|--|----------------|
| AAV2 | NAb titer in serum | 213.0 (160.0–3413.0) | 2855.0 (1920.3–8704.0) | 0.081 |
| | NAb titer in vitreous humor | 20.0 (2.0–35.0) | 9.5 (2.0–19.0) | 0.632 |
| | NAb ratio (serum / vitreous humor) | 80.0 (62.7–85.3) | 324.0 (210.5–1216.0) | 0.004 |
| AAV5 | NAb titer in serum | 48.0 (10.0–187.0) | 171.0 (69.0–290.3) | 0.105 |
| | NAb titer in vitreous humor | 2.0 (2.0–4.0) | 2.0 (2.0–2.0) | 0.047 |
| | NAb ratio (serum / vitreous humor) | 10.6 (5.0–46.8) | 85.5 (34.5–145.1) | 0.037 |

BRB robustness. Of significance, we found that the level of pre-existing NABs in the vitreous humor was much lower than that in the serum, regardless of AAV serotype. This novel finding supplements previous studies of the NABs level in the aqueous humor.^{17,18} For instance, Amado et al.¹⁷ reported that NAB titers to AAV2 in the anterior chamber in control human subjects were at or near background levels, even in cases of very high serum NAB titers. In patients with Leber hereditary optic neuropathy (LHON), baseline NAB levels in the anterior chamber also were much lower than serum levels in all participants.¹⁸ Although the NAB levels in the aqueous humor cannot represent those in the vitreous humor, which directly affect retinal gene therapy, these findings are concordant with our results. The differences in NAB levels between the systemic circulation and the intraocular space could be a result of the immune-privileged nature of the healthy eye.

The origin of immune privilege in the ocular system is a complex and dynamic process involving multiple physiologic, anatomic, and immunologic properties.^{10,11} The BRB, which is composed of

nonfenestrated capillaries of retinal vessels forming the inner part, as well as tight junctions of the retinal pigment epithelium forming the outer layers, is an important anatomic structure that maintains the immune privilege of the posterior segment of the eye. This restricts the movement of inflammatory cells and inflammatory macromolecules from the circulatory system into the eye.^{12,19} Several retinal diseases are associated with alterations in the inner or outer BRB, leading to disruption of the immune-privileged state of the retina. Our study showed that the pre-existing immune status of the vitreous humor may be different under such conditions.

Patients with VH (i.e., severely disrupted inner BRB) had higher titers of NABs in the vitreous humor than patients with an intact inner BRB, regardless of their serum titers. Significantly lower NAB ratios were observed in patients with ERM whose FA scan revealed dye leakage (i.e., mildly disrupted inner BRB) compared to those of patients without leakage. Taken as a group, patients with VH and ERM with leakage had significantly lower NAB ratios than patients with intact BRB.

Table 4. Comparison of NAb Titer and NAb Ratio to AAV2 and AAV5 According to Maintenance of the BRB

| Serotype | Variable | Group A: Patients With Disrupted BRB, <i>n</i> = 19 Median (IQR) | Group B: Patients With Intact BRB, <i>n</i> = 13 Median (IQR) | <i>P</i> Value |
|----------|------------------------------------|---|--|----------------|
| AAV2 | NAb titer in serum | 2194.0 (160.0–11947.0) | 3150.0 (1237.5–13653.0) | 0.218 |
| | NAb titer in vitreous humor | 40.0 (3.0–211.0) | 9.0 (2.0–30.0) | 0.062 |
| | NAb ratio (serum / vitreous humor) | 48.9 (23.0–80.0) | 350.0 (157.2–1280.0) | <0.001 |
| AAV5 | NAb titer in serum | 53.0 (13.0–551.0) | 171.0 (122.0–480.0) | 0.233 |
| | NAb titer in vitreous humor | 3.0 (2.0–10.0) | 2.0 (2.0–2.0) | 0.036 |
| | NAb ratio (serum / vitreous humor) | 26.5 (6.3–62.3) | 85.5 (61.0–155.3) | 0.001 |

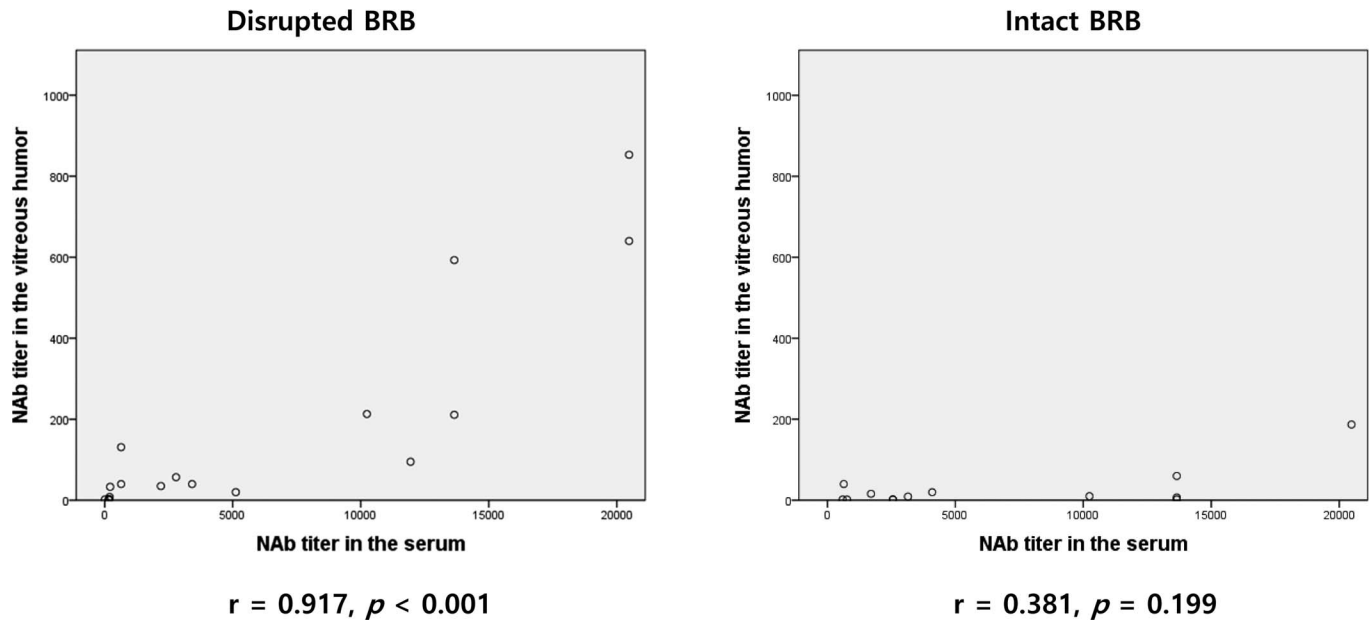


Figure 4. Difference in the relationship between neutralizing activity against AAV serotype 2 in serum and vitreous humor according to BRB maintenance. AAV = adeno-associated virus; BRB = blood–retina barrier; NAb = neutralizing antibody.

The difference that BRB-dependent, pre-existing immune status makes is clearer when the relationship between the NAb titers in the serum and vitreous humor is considered. Our study showed that when the BRB is intact, the NABs level in the vitreous humor remains low even if the level in the serum is high. However, the levels in serum and vitreous humors are positively correlated when BRB is disrupted.

These results indicated that the level of NABs in the vitreous humor could be higher in cases of BRB disruption, and that the absolute value of NABs in the vitreous humor could be influenced by the extent of BRB disruption and the level of NABs in the serum.

Recently, two major clinical trials of human retinal gene therapy using AAV2 vectors delivered by intravitreal injection reported conflicting results regarding the serum NABs levels and the efficacy of gene therapy.^{6,18} One trial examined the safety and tolerability of AAV2-sFLT01 in patients with advanced neovascular AMD, and the other trial investigated the effects of AAV2(Y444,500,730F)-P1ND4v2 in LHON patients. The study with AMD patients reported an inverse correlation between the presence of NABs to AAV2 and the ability of AAV2-sFLT01 to produce the sFLT01 protein. On the other hand, the study with LHON patients suggested that high serum NABs levels may not be a barrier to successful ocular gene therapy, because the four patients who showed the most improvement in visual acuity with the treatment had the highest serum NABs

levels. Based on our findings, these conflicting results could be explained by the differences in BRB maintenance status in the target disease. Neovascular AMD is a frequent retinal disease that involve the breakdown of the BRB, especially the outer BRB, whereas LHON is an inherited mitochondrial disorder that is not associated with BRB disruption, as shown by the absence of dye leakage in a typical FA image. However, the results of a nonhuman primate study were different from those of human studies, because the primate study reported that the presence of pre-existing NAB titers in the serum of healthy monkeys was correlated strongly with weak transgene expression after intravitreal delivery of AAV.⁹ It is presumed that immunologic heterogeneity and differences in BRB structure between nonhuman primates and humans may account for the differences between the results of these studies.²⁰

Another factor to consider regarding the immunologic aspect of retinal gene therapy is the route of administration; that is, the subretinal or intravitreal space, as they are immunologically slightly different.^{17,21,22} A mouse study demonstrated that intravitreal administration of AAV generated a humoral immune response against AAV capsid equivalent to that of systemic administration, whereas subretinal administration did not trigger a humoral immune response and did not affect subsequent intravitreal or subretinal administration of AAV.²¹ Other studies demonstrated that initial subretinal injection of

AAV2 does not prevent readministration of AAV2 to the contralateral eye.^{17,22} Human studies targeting neovascular AMD with subretinal injections of AAV2 have reported that the presence of anti-AAV antibodies in the serum at baseline does not affect the outcome, in contrast to the findings of Heier et al. for intravitreal injections in patients with the same disease.^{5,6,23} Because of difficulties in measuring the level of pre-existing NABs in the subretinal space, the relationship between the serum and subretinal space pertaining to pre-existing immunity is difficult to evaluate. However, this relationship may be different from the relationship between the serum and intravitreal space because of the differential effect of serum NABs on transgene expression based on the injection route for the same disease; that is, neovascular AMD, which is associated with breakdown of the BRB.

The significance of our study is that, to our knowledge, it is the first to measure pre-existing NAB titers in the human vitreous humor and to examine pre-existing NAB titers in Korean populations to provide insights on AAV vector-based gene therapy. By surveying patients with various vitreoretinal diseases, we demonstrated the possibility of differences in the relationship between NAB titers in the serum and vitreous humor according to BRB status, and we determined the factors to be considered when performing retinal gene therapy in relation to the inhibitory effect of NABs.

Nonetheless, our study has some limitations. The small sample size limited the statistical strength of our analysis, and there is potential ethnic bias, as only Korean patients were represented. Further large-scale studies that span a wider demographic will be crucial to confirm our findings. Our results are important for the development of gene therapy for neovascular AMD in the future. However, because VHS caused by wet AMD are uncommon,²⁴ only one patient with neovascular AMD has been included in this study. We investigated the integrity of the BRB qualitatively with FA. However, future studies are required to determine whether quantification of vitreous albumin is a comparatively reliable method for evaluating the BRB integrity.

In conclusion, the presence of baseline NABs in serum may not be a limiting factor for successful retinal gene therapy using AAV vectors. This is particularly true if their BRB is intact. However, baseline NAB levels in the serum and the extent of BRB breakdown must be considered when planning gene therapy for diseases associated with breakdown of the BRB, because NAB levels in the vitreous humor

are affected by these two factors and may be high enough to impact successful transduction. Therefore, the characteristics of diseases associated with maintenance of the BRB should be considered in retinal gene therapy using AAV vectors.

Acknowledgments

The authors thank Paula Khim for her proofreading and editing.

Supported by grants from Basic Science Research Program through the National Research Foundation of Korea (NRF-2017R1A2B4012769, 2017 to H. Lee), the Ministry of Health & Welfare (HI15C2599, 2016 to J.Y. Lee), National Research Foundation of Korea (NRF-2018R1D1A1A02045583, 2018 to J.Y. Lee), and Asan Institute for Life Sciences (2013-0826; J.Y. Lee), Asan Medical Center, Republic of Korea. The sponsor or funding organization had no role in the design or conduct of this research.

Disclosure: **S. Lee**, None; **I.K. Kang**, None; **J.H. Kim**, None; **B.K. Jung**, None; **K. Park**, None; **H. Chang**, None; **J.Y. Lee**, None; **H. Lee**, None

*SL and IKK contributed equally to this work.

References

1. Balakrishnan B, Jayandharan GR. Basic biology of adeno-associated virus (AAV) vectors used in gene therapy. *Curr Gene Ther.* 2014;14:86–100.
2. Maguire AM, Simonelli F, Pierce EA, et al. Safety and efficacy of gene transfer for Leber's congenital amaurosis. *N Engl J Med.* 2008;358:2240–2248.
3. Bainbridge JW, Mehat MS, Sundaram V, et al. Long-term effect of gene therapy on Leber's congenital amaurosis. *N Engl J Med.* 2015;372:1887–1897.
4. MacLaren RE, Groppe M, Barnard AR, et al. Retinal gene therapy in patients with choroideremia: initial findings from a phase 1/2 clinical trial. *Lancet.* 2014;383:1129–1137.
5. Rakoczy EP, Lai CM, Magno AL, et al. Gene therapy with recombinant adeno-associated vectors for neovascular age-related macular degeneration: 1 year follow-up of a phase 1 randomised clinical trial. *Lancet.* 2015;386:2395–2403.
6. Heier JS, Kherani S, Desai S, et al. Intravitreal injection of AAV2-sFLT01 in patients with

- advanced neovascular age-related macular degeneration: a phase 1, open-label trial. *Lancet*. 2017; 390:50–61.
7. Louis Jeune V, Joergensen JA, Hajjar RJ, Weber T. Pre-existing anti-adenovirus antibodies as a challenge in AAV gene therapy. *Hum Gene Ther Methods*. 2013;24:59–67.
 8. Masat E, Pavani G, Mingozzi F. Humoral immunity to AAV vectors in gene therapy: challenges and potential solutions. *Discov Med*. 2013;15:379–389.
 9. Kotterman MA, Yin L, Strazzeri JM, Flannery JG, Merigan WH, Schaffer DV. Antibody neutralization poses a barrier to intravitreal adeno-associated viral vector gene delivery to non-human primates. *Gene Ther*. 2015;22:116–126.
 10. Niederkorn JY, Stein-Streilein J. History and physiology of immune privilege. *Ocul Immunol Inflamm*. 2010;18:19–23.
 11. Perez VL, Saeed AM, Tan Y, Urbietta M, Cruz-Guilloty F. The eye: a window to the soul of the immune system. *J Autoimmun*. 2013;45:7–14.
 12. Cunha-Vaz J. The blood-retinal barrier in the management of retinal disease: EURETINA award lecture. *Ophthalmologica*. 2017;237:1–10.
 13. Hewitt FC, Li C, Gray SJ, Cockrell S, Washburn M, Samulski RJ. Reducing the risk of adeno-associated virus (AAV) vector mobilization with AAV type 5 vectors. *J Virol*. 2009;83:3919–3929.
 14. Lisowski L, Tay SS, Alexander IE. Adeno-associated virus serotypes for gene therapeutics. *Curr Opin Pharmacol*. 2015;24:59–67.
 15. Srivastava A. In vivo tissue-tropism of adeno-associated viral vectors. *Curr Opin Virol*. 2016;21: 75–80.
 16. Ahn J, Woo HN, Ko A, et al. Multispecies-compatible antitumor effects of a cross-species small-interfering RNA against mammalian target of rapamycin. *Cell Mol Life Sci*. 2012;69:3147–3158.
 17. Amado D, Mingozzi F, Hui D, et al. Safety and efficacy of subretinal readministration of a viral vector in large animals to treat congenital blindness. *Sci Transl Med*. 2010;2:21ra16.
 18. Guy J, Feuer WJ, Davis JL, et al. Gene therapy for leber hereditary optic neuropathy: low- and medium-dose visual results. *Ophthalmology*. 2017; 124:1621–1634.
 19. Cunha-Vaz J, Bernardes R, Lobo C. Blood-retinal barrier. *Eur J Ophthalmol*. 2011;21(suppl 6):S3–S9.
 20. Flage T. A defect in the blood-retina barrier in the optic nerve head region in the rabbit and the monkey. *Acta Ophthalmol (Copenh)*. 1980;58: 645–651.
 21. Li Q, Miller R, Han PY, et al. Intraocular route of AAV2 vector administration defines humoral immune response and therapeutic potential. *Mol Vis*. 2008;14:1760–1769.
 22. Bennett J, Wellman J, Marshall KA, et al. Safety and durability of effect of contralateral-eye administration of AAV2 gene therapy in patients with childhood-onset blindness caused by RPE65 mutations: a follow-on phase 1 trial. *Lancet*. 2016;388:661–672.
 23. Constable IJ, Pierce CM, Lai CM, et al. Phase 2a randomized clinical trial: Safety and post hoc analysis of subretinal rAAV.sFLT-1 for wet age-related macular degeneration. *EBioMedicine*. 2016;14:168–175.
 24. Spraul CW, Grossniklaus HE. Vitreous Hemorrhage. *Surv Ophthalmol*. 1997;42:3–39.