

# Identifying olanzapine induced liver injury in the setting of acute hepatitis C: A case report

Andrea Brelje, MD<sup>1</sup>; Bailey Fay, MD<sup>2</sup>; Scott Mariouw, MD<sup>3</sup>; Amy VandenBerg, PharmD<sup>4</sup>

**How to cite:** Brelje A, Fay B, Mariouw S, VandenBerg A. Identifying olanzapine induced liver injury in the setting of acute hepatitis C: A case report. *Ment Health Clin [Internet]*. 2022;12(3):210-3. DOI: 10.9740/mhc.2022.06.210.

**Submitted for Publication:** June 30, 2021; **Accepted for Publication:** March 29, 2022

## Abstract

Olanzapine is linked to asymptomatic, transient elevations of liver aminotransferases but is historically thought to rarely cause significant hepatotoxicity. Underlying liver disease is a risk factor for drug-induced liver injury and may complicate the differential diagnosis of acute transaminitis in patients taking medications associated with hepatotoxicity. Ms L presented with 2 months of new psychotic symptoms resulting in hospitalizations. Although psychosis previously improved with haloperidol, she reported symptoms concerning for akathisia. Restlessness improved and psychotic symptoms resolved after initiation of olanzapine. Concurrently, her alanine aminotransferase (ALT) was elevated, prompting further workup and new diagnosis of acute hepatitis C. Over the course of hospitalization, her ALT increased exponentially. Initially attributed solely to acute hepatitis C infection, ALT rapidly decreased after holding olanzapine, implying it was contributing to her liver injury. Subsequently, given her prior response, haloperidol was retried with close monitoring for adverse effects. Her subjective restlessness was treated with additional agents, and she was then transitioned to monthly haloperidol decanoate injections to further assist her adherence. Prior to discharge, she had resolution of psychosis and transaminitis. Olanzapine may contribute to hepatotoxicity with concurrent viral hepatitis, and clarity can be obtained by a trial of stopping the suspected medication. Furthermore, olanzapine, when combined with underlying liver disease, may have an additive effect on liver injury, resulting in accelerated elevations in liver aminotransferases.

**Keywords:** olanzapine, transaminitis, hepatitis, intravenous drug use, case report

<sup>1</sup> (Corresponding author) Resident Physician, Department of Psychiatry, University of Michigan Hospital, Ann Arbor, Michigan, [berkemas@umich.edu](mailto:berkemas@umich.edu), ORCID: <https://orcid.org/0000-0001-5099-2245>; <sup>2</sup> Resident Physician, Department of Psychiatry, University of Michigan Hospital, Ann Arbor, Michigan, ORCID: <https://orcid.org/0000-0001-8381-8278>; <sup>3</sup> Assistant Professor, Department of Psychiatry, University of Michigan Hospital, Ann Arbor, Michigan, ORCID: <https://orcid.org/0000-0002-1971-6215>; <sup>4</sup> Adjunct Clinical Associate Professor, College of Pharmacy, University of Michigan, Ann Arbor, Michigan, ORCID: <https://orcid.org/0000-0002-2294-2694>

**Disclosures:** The authors declare that they have no conflicts of interest.

## Background

Drug induced liver injury (DILI) is the most common cause of acute liver failure in the developed world.<sup>1,2</sup> It can be classified as either predictable with higher likelihood of

liver injury or idiosyncratic with lower likelihood of liver injury.<sup>3</sup> Idiosyncratic DILI, marked by an unpredictable time of onset, has 3 subtypes (hepatocellular, cholestatic, or mixed) differentiated by the patterns of elevated liver enzymes, namely, alanine aminotransferase (ALT) and alkaline phosphatase (ALP; Table).<sup>3,7</sup> Druschky et al<sup>8</sup> recently published data on adverse drug events among more than 330 000 patients treated with antipsychotics across multiple sites since the early 1990s. Based on their findings, olanzapine, perazine, and clozapine were the most common antipsychotic agents associated with significant DILI (0.12% for olanzapine and 0.09% each for perazine and clozapine), which they defined as an elevation of ALT or ALP greater than 5 times the ULN.<sup>8</sup> Haloperidol, by contrast, had a 0.008% reported rate of DILI.<sup>8</sup> Of these agents, olanzapine carried the greatest risk



**TABLE: Type of idiosyncratic drug-induced liver injury (DILI) defined by transaminitis pattern<sup>4,5</sup>**

DILI Type	Ratio of ALT to ALP	Most Prominent Liver Enzyme
Cholestatic	$\leq 2$	ALP $\geq 2 \times$ ULN
Hepatocellular	$\geq 5$	ALT $> 2 \times$ ULN
Mixed	Between 2 and 5	ALT $> 2 \times$ ULN

ALP = alkaline phosphatase; ALT = alanine aminotransferase.

for DILI and was the only medication associated with acute liver failure.<sup>8</sup>

There are several factors that may increase the risk of developing DILI, including genetics, age, sex, environmental factors, and medical comorbidities.<sup>3,5</sup> Underlying liver disease—most commonly hepatitis C and non-alcohol-related fatty liver disease—are examples of known risk factors for DILI and similarly manifest with transaminitis.<sup>8</sup> Diagnosis of DILI can be elusive and tends to be one of exclusion because it has no unique clinical or laboratory findings. Whenever DILI is being considered, so too should other causes of acute liver injury, including infectious etiologies; a diagnosis with 1 liver injury does not preclude a different simultaneous injury.<sup>9-11</sup> Acute hepatitis C may be high on the differential for any patient with history of intravenous drug use (IVDU) and ALT  $\geq 5 \times$  ULN.<sup>12</sup> Although acute hepatitis C is often asymptomatic, it frequently transitions into a chronic infection, which can subsequently lead to fatal diagnoses of liver cirrhosis or hepatocellular carcinoma.<sup>13</sup> Additionally, there is increasing availability of highly effective, curative treatments for this viral infection.<sup>14</sup>

We present a case of transaminitis worsening upon initiation of olanzapine in a patient with a history of IVDU and newly diagnosed hepatitis C. As highlighted above, both acute hepatitis C and DILI cause a similar elevation in liver enzymes and presence of one can mask the other. It is recommended that patients with DILI should be considered for repeat testing for viral hepatitis C antibodies to verify that the diagnosis is not lost amid the DILI.<sup>11</sup> This case highlights that the reverse is also true: even after a viral hepatitis has been identified in a patient with transaminitis, DILI can still simultaneously occur.

## Case Report

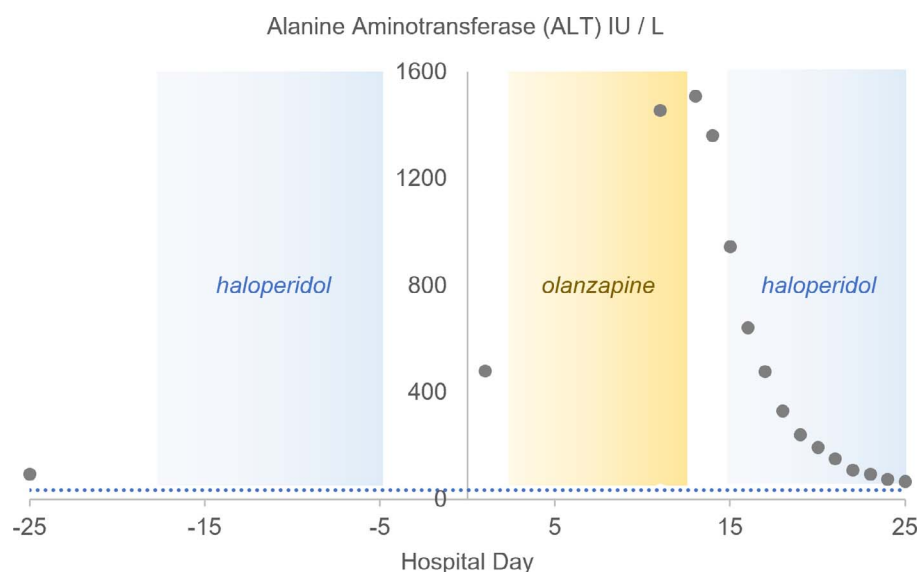
Ms L, a 27-year-old female with restless leg syndrome, anxiety, depression, polysubstance use disorder (IV heroin, IV methamphetamine, hydrocodone, cocaine, cannabis), 1 suicide attempt via overdose (1 year prior), and 2 months of new psychotic symptoms presented with acute psychosis and anxiety in the setting of medication

nonadherence 5 days after discharge from an outside psychiatric hospital where she was treated for psychosis. Her psychotic symptoms on admission included thought blocking, thought broadcasting, auditory hallucinations, and paranoid delusions. Ms L reported using cannabis on the day of presentation but was 8 weeks sober from all other substances. She denied associated depressive symptoms, and her anxiety was primarily related to her psychotic symptoms.

On arrival to the psychiatric emergency room (hospital day [HD] 1), her heart rate was 129 beats/min, and she attempted to elope when meeting with the care team due to profound anxiety; lorazepam 1 mg by mouth decreased anxiety. Physical exam was otherwise unremarkable. Home medications, initiated during her recent psychiatric hospitalization, were haloperidol 10 mg twice daily and benztropine 1 mg twice daily; however, ongoing restlessness led to nonadherence.

Baseline labs, collected within an hour of arrival, were notable for cannabinoids on urine drug screen and transaminitis ALT of 482 IU/L ( $13 \times$  ULN; ref  $\leq 35$  IU/L). Per outside hospitalization records, 25 days prior, her ALT was 96 IU/L. Given this continued elevation in her ALT, iron studies and hepatitis screening were obtained for further workup. On HD 5, she was found to be hepatitis C antibody positive, and on HD 9, hepatitis C viral load was 3.5 million IU/mL, consistent with a diagnosis of acute hepatitis C. Hepatology was subsequently consulted and planned to initiate hepatitis C treatment outpatient.

Meanwhile, she was started on risperidone 2 mg at night on HD 2 to address her acute psychotic symptoms; haloperidol was not restarted given Ms L's concerns about it causing restlessness. She endorsed constant full-body restlessness while on risperidone but not after receiving a single 5 mg oral dose of olanzapine for acute agitation on HD 4. It was unclear whether this restlessness was akathisia from the antipsychotics or anxiety from her psychosis. Using patient-centered decision making, risperidone was discontinued, and olanzapine was initiated at 5 mg four times daily on HD 4 to target her significant symptoms of agitation and restlessness. Olanzapine was subsequently titrated to 10 mg every morning, 20 mg every evening by HD 7 with full resolution of all positive symptoms of psychosis. Medications used to treat her persistent anxiety, tachycardia, and restlessness were introduced and titrated to symptoms throughout her hospitalization. Final doses for these auxiliary agents included gabapentin 600 mg 3 times daily, propranolol extended release 80 mg daily, trazodone 50 mg at bedtime as needed ( $\sim$ nightly) hydroxyzine 50 mg as needed ( $\sim 2$ /day), and lorazepam 1 mg as needed ( $\sim 1$ /day).



**FIGURE:** Graph of ALT (IU/L) by hospital day (HD). The dashed line at 35 IU/L indicates ALT ULN. Twenty-five days before admission, prior to initiation of any antipsychotic, ALT was mildly elevated to 96 IU/L. No liver function tests are available during initial treatment with haloperidol at outside hospital. ALT on HD 1 was elevated to 482 IU/L (13× ULN) attributed to her acute hepatitis C diagnosed during the admission. Olanzapine was initiated to treat her psychosis (on HD 4), and on repeat testing on HD 10, ALT had dramatically risen to 41× ULN. Due to concern that liver injury may be caused by both the acute hepatitis and olanzapine, olanzapine was held after her morning dose on HD 13. Haloperidol was reinitiated with caution and ALT continued to downtrend.

On HD 10, a comprehensive metabolic panel, repeated as part of continued assessment of hepatitis C, revealed worsened transaminitis (ALT 1456 IU/L; Figure). The hepatology consult service attributed this to acute hepatitis C infection. It was uncertain, however, if the olanzapine was contributing to the liver injury. Of the new medications she was taking, olanzapine was both the most important for managing her chief concern of psychosis and the most likely to cause liver injury. The hepatology team deferred to the primary psychiatry team to weigh the risks and benefits of holding olanzapine to further test the DILI hypothesis.

By HD 13, her ALT was 1510 IU/L, yet her ALP remained <2× ULN and other markers (INR, bilirubin, albumin) remained within normal limits. With shared decision making between the psychiatry service, hepatology service, and Ms L, olanzapine was held on HD 13, and her ALT began down trending the next day (1362 IU/L). Haloperidol was initiated at 5 mg every bedtime on HD 15 with a daily liver function test and close monitoring for akathisia. Although it is possible that her transaminitis on admission could have resulted from prior haloperidol use, it was not considered causative due to nonadherence and selected based on lower reported rate of severe hepatotoxicity.<sup>8</sup> Furthermore, Ms L's positive symptoms of psychosis had resolved with haloperidol during her previous hospitalization; it was appealing for all parties to choose this antipsychotic with known good response in this patient rather than trialing a new antipsychotic that

could potentially further prolong hospitalization. This low initial dose of haloperidol was chosen given Ms L's reported history of akathisia. Benzotropine 1 mg at bedtime was also initiated on HD 15. By HD 16, her ALT had dropped to 644 IU/L, a marked improvement since olanzapine was stopped roughly 72 hours prior. The rapid improvement in ALT further supported DILI diagnosis as it would be atypical for such a rapid change in ALT due to a viral hepatitis C process alone.

Her liver enzymes continued to improve; however, her psychotic symptoms briefly resurfaced beginning HD 17. With further titration to haloperidol 10 mg twice daily (HD 21) and initiation of haloperidol decanoate 100 mg (HD 26), her symptoms of psychosis improved. Her discharge medication regimen included bridging haloperidol 10 mg twice daily, benzotropine 0.5 mg twice daily, lorazepam 1 mg twice daily as needed, propranolol extended release 80 mg daily, trazodone 50 mg at bedtime as needed, nicotine replacement therapy, and a naloxone kit. She was discharged home on HD 27 after several days of consistent improvement in her psychotic symptoms and labs (ALT 67 IU/L); she continued to endorse the restlessness that had been present throughout her entire admission.

## Discussion

Olanzapine-induced liver injury is well-documented in the literature and is known to occur anywhere between 12

days and 8 years after initiating olanzapine.<sup>6,15-17</sup> Approximately 0.2% of individuals given olanzapine develop severe liver injury,<sup>8</sup> but there are no known fatalities associated with olanzapine-induced liver injury.<sup>17</sup> Injuries also appear to be dose-independent and do not have a consistent pathological pattern: there are hepatocellular, cholestatic, and mixed type liver injuries associated with olanzapine.<sup>17</sup> As such, there is still no consensus about the specific mechanism by which olanzapine injures the liver. Consequently, large psychiatry professional societies have refrained from recommending widespread asymptomatic testing.

Ms L's case demonstrates the importance of considering multiple probable causes of transaminitis in patients with underlying hepatic disease. By HD 1, she had ALT > 13× ULN, and acute hepatitis C infection was quickly diagnosed. During her hospitalization, she developed ALT > 41× ULN and an elevated ALT-to-ALP ratio consistent with hepatocellular injury. Given the history of IVDU and newly diagnosed hepatitis C, DILI could have been easily overlooked as an additional cause of transaminitis. However, the substantial increase in ALT from admission to HD 12 correlated with initiation of olanzapine, and liver enzymes immediately began returning to normal after stopping olanzapine. The RUCAM (Roussel Uclaf Causality Assessment Method) score in this case of hepatocellular injury was 7, suggesting that olanzapine was a “probable cause of DILI.”<sup>18(p5)</sup> Ms L's acute hepatitis may have predisposed her to developing liver injury after only 6 days of receiving olanzapine. A repeat challenge with olanzapine outside of the acute phase of hepatitis C could help provide better clarity on the causality assessment.

## Conclusion

When patients present with acute worsening of liver enzymes, even in the setting of concurrent liver disease, medications should be reviewed carefully as potential causes. Olanzapine is associated with a rare, acute, reversible liver toxicity. If transaminitis is thought to be associated with olanzapine, a short trial off medication can provide causative clarity as ALT elevation due to DILI typically improves within days of stopping the medication.

## References

- Bernal W, Wendon J. Acute liver failure. *N Engl J Med.* 2013; 369(26):2525-34. DOI: [10.1056/NEJMra1208937](https://doi.org/10.1056/NEJMra1208937). PubMed PMID: [24369077](https://pubmed.ncbi.nlm.nih.gov/24369077/).
- Garcia-Cortes M, Robles-Diaz M, Stephens C, Ortega-Alonso A, Lucena MI, Andrade RJ. Drug induced liver injury: an update. *Arch Toxicol.* 2020;94(10):3381-407. DOI: [10.1007/s00204-020-02885-1](https://doi.org/10.1007/s00204-020-02885-1). PubMed PMID: [32852569](https://pubmed.ncbi.nlm.nih.gov/32852569/).
- Kaplowitz N. Drug-induced liver injury. *Clin Infect Dis.* 2004;38 Suppl 2:S44-8. DOI: [10.1086/381446](https://doi.org/10.1086/381446). PubMed PMID: [14986274](https://pubmed.ncbi.nlm.nih.gov/14986274/).
- Katarey D, Verma S. Drug-induced liver injury. *Clin Med (Lond).* 2016;16(Suppl 6):S104-9. DOI: [10.7863/clinmedicine.16-6-S104](https://doi.org/10.7863/clinmedicine.16-6-S104). PubMed PMID: [27956449](https://pubmed.ncbi.nlm.nih.gov/27956449/).
- David S, Hamilton JP. Drug-induced liver injury. *US Gastroenterol Hepatol Rev.* 2010;6:73-80. PubMed PMID: [21874146](https://pubmed.ncbi.nlm.nih.gov/21874146/).
- Ozcanli T, Erdogan A, Ozdemir S, Onen B, Ozmen M, Doksat K, et al. Severe liver enzyme elevations after three years of olanzapine treatment: a case report and review of olanzapine associated hepatotoxicity. *Prog Neuropsychopharmacol Biol Psychiatry.* 2006;30(6):1163-6. DOI: [10.1016/j.pnpbp.2006.03.014](https://doi.org/10.1016/j.pnpbp.2006.03.014). PubMed PMID: [16632162](https://pubmed.ncbi.nlm.nih.gov/16632162/).
- Bénichou C. Criteria of drug-induced liver disorders. Report of an international consensus meeting. *J Hepatol.* 1990;11(2):272-6. DOI: [10.1016/0168-8278\(90\)90124-a](https://doi.org/10.1016/0168-8278(90)90124-a). PubMed PMID: [2254635](https://pubmed.ncbi.nlm.nih.gov/2254635/).
- Druschky K, Toto S, Bleich S, Baumgärtner J, Engel RR, Grohmann R, et al. Severe drug-induced liver injury in patients under treatment with antipsychotic drugs: data from the AMSP study. *World J Biol Psychiatry.* 2021;22(5):373-86. DOI: [10.1080/15622975.2020.1819565](https://doi.org/10.1080/15622975.2020.1819565). PubMed PMID: [32892689](https://pubmed.ncbi.nlm.nih.gov/32892689/).
- Stirmann G, Kessebohm K, Lauterburg B. Liver injury caused by drugs: an update. *Swiss Med Wkly.* 2010;140:w13080. DOI: [10.4414/SMW.2010.13080](https://doi.org/10.4414/SMW.2010.13080). PubMed PMID: [20927685](https://pubmed.ncbi.nlm.nih.gov/20927685/).
- Lee WM, Senior JR. Recognizing drug-induced liver injury: current problems, possible solutions. *Toxicol Pathol.* 2005;33(1):155-64. DOI: [10.1080/01926230590522356](https://doi.org/10.1080/01926230590522356). PubMed PMID: [15805067](https://pubmed.ncbi.nlm.nih.gov/15805067/).
- Grewal P, Ahmad J. Beware of HCV and HEV in patients with suspected drug-induced liver injury. *Curr Hepatol Rep.* 2018; 17(3):270-5. DOI: [10.1007/s11901-018-0410-1](https://doi.org/10.1007/s11901-018-0410-1). PubMed PMID: [30766771](https://pubmed.ncbi.nlm.nih.gov/30766771/).
- Kwo PY, Cohen SM, Lim JK. ACG Clinical guideline: evaluation of abnormal liver chemistries. *Am J Gastroenterol.* 2017;112(1):18-35. DOI: [10.1038/ajg.2016.517](https://doi.org/10.1038/ajg.2016.517). PubMed PMID: [27995906](https://pubmed.ncbi.nlm.nih.gov/27995906/).
- Global hepatitis report 2017 [Internet]. Geneva; 2017 [cited 2022 Jan 28]. Available from: <https://www.who.int/publications/i/item/global-hepatitis-report-2017>
- Schillie S, Wester C, Osborne M, Wesolowski L, Ryerson AB. CDC recommendations for hepatitis C screening among adults—United States, 2020. *MMWR Recomm Rep.* 2020;69(2):1-17. DOI: [10.15585/mmwr.rr6902a1](https://doi.org/10.15585/mmwr.rr6902a1). PubMed PMID: [32271723](https://pubmed.ncbi.nlm.nih.gov/32271723/).
- Devarbhavi H, Dierkhising R, Kremers WK, Sandeep MS, Karanth D, Adarsh CK. Single-center experience with drug-induced liver injury from India: causes, outcome, prognosis, and predictors of mortality. *Am J Gastroenterol.* 2010;105(11):2396-404. DOI: [10.1038/ajg.2010.287](https://doi.org/10.1038/ajg.2010.287). PubMed PMID: [20648003](https://pubmed.ncbi.nlm.nih.gov/20648003/).
- Dusi N, Comacchio C, Lasalvia A. Late-onset cholestatic liver injury during combination treatment with chlorpromazine and olanzapine: a case report. *J Clin Psychopharmacol.* 2019;39(2):175-6. DOI: [10.1097/JCP.0000000000000999](https://doi.org/10.1097/JCP.0000000000000999). PubMed PMID: [30640795](https://pubmed.ncbi.nlm.nih.gov/30640795/).
- Björnsson ES, Hoofnagle JH. Categorization of drugs implicated in causing liver injury: critical assessment based on published case reports. *Hepatology.* 2016;63(2):590-603. DOI: [10.1002/hep.28323](https://doi.org/10.1002/hep.28323). PubMed PMID: [26517184](https://pubmed.ncbi.nlm.nih.gov/26517184/).
- Danan G, Teschke R. RUCAM in drug and herb induced liver injury: the update. *Int J Mol Sci.* 2015;17(1):14. DOI: [10.3390/ijms17010014](https://doi.org/10.3390/ijms17010014). PubMed PMID: [26712744](https://pubmed.ncbi.nlm.nih.gov/26712744/).