



# Proton Beam Therapy for Thymic Carcinoma with Pericardial Involvement

Pierre Loap, MSc; Nathaniel Scher, MD; Farid Goudjil, PhD; Youlia Kirova, MD; Nicolas Girard, MD; Kim I. Cao, MD

Department of Radiation Oncology, Institut Curie, Paris, France

## Abstract

**Purpose:** Thymic malignancies are the most common anterior mediastinal tumors. Advanced thymic carcinoma treatment relies on chemotherapy and definitive radiation therapy when possible. However, pericardial involvement is problematic for radiation therapy treatment planning owing to significant cardiac radiation exposure. We report the first case of definitive proton beam therapy (PBT) for an advanced thymic carcinoma with pericardial invasion.

**Materials and Methods:** We report the case of a 69-year-old patient treated with definitive radiation therapy for a stage IVB thymic carcinoma with pericardial invasion. Mean doses delivered to critical organs at risk were compared between deep inspiration breath-hold (DIBH) volumetric modulated arc therapy (VMAT) and DIBH-PBT.

**Results:** When compared to DIBH-VMAT, DIBH-PBT reduced the mean doses delivered to the heart by 3.72 Gy (19.0% dose reduction), to the right lung by 5.9 Gy (41.7% dose reduction), to the left lung by 3.63 Gy (19.0% dose reduction), and to the esophagus by 3.57 Gy (21.3% dose reduction). Despite an early mediastinal relapse after 3.0 months, our patient is still alive after a 14-month follow-up, without any radiation-induced cardiac adverse events and is undergoing pembrolizumab-based immunotherapy.

**Conclusion:** Proton beam therapy is an option for definitive irradiation of thymic malignancies invading the pericardium; in this situation, PBT reduces doses to the heart and may help to reduce cardiotoxicity when compared with photon techniques.

**Keywords:** thymic carcinoma; cardiotoxicity; deep inspiration breath-hold; proton beam therapy

Submitted 10 Apr 2020  
Accepted 23 Sept 2020  
Published 16 Nov 2020

### Corresponding Author:

Pierre Loap, MSc  
Department of Radiation  
Oncology  
Institut Curie  
Paris, France  
Phone: +33631339838  
pierre.loap@gmail.com

### Case Report

DOI  
10.14338/IJPT-20-00023.1

© Copyright  
2020 The Author(s)

Distributed under  
Creative Commons CC-BY

### OPEN ACCESS

<http://theijpt.org>

## Introduction

Thymic malignancies are the most common anterior mediastinal tumors [1]. Optimal management is based on complete surgical excision [2]. However, advanced thymic carcinomas are mostly unresectable and their treatment usually relies on chemotherapy possibly followed by definitive radiation therapy [2]. Yet, radiation therapy planning is hazardous when pericardium is involved, since heart sparing is difficult and radiation-induced cardiotoxicity consequently becomes a major concern. In this situation, precise irradiation techniques are needed. In this article, we report the first case of definitive proton beam therapy (PBT) for a stage IV thymic carcinoma with pericardial invasion.

## Case Report

A 69-year old man was referred to our hospital with an anterior mediastinal mass. The initial presentation was a dry cough. Computed tomography (CT) revealed a

heterogeneous tumor filling the thymic space, sized  $53 \times 50 \times 64$  mm. Pericardium was involved, as evidenced by necrotic nodules, effusion, and diffuse thickened parietal layer. In addition, a bilateral pleural effusion was visualized. 18-FDG positron emission tomography (PET) showed mediastinal and left internal mammary lymph node involvement. No distant metastasis was found. Computed tomography-guided biopsies yielded the diagnosis of invasive epidermoid carcinoma, with CD117 and CD5 expression. The final clinical diagnosis was a stage IVB thymic carcinoma. The tumor was considered unresectable and paclitaxel-carboplatin-based chemotherapy was recommended. After 3 cycles, CT assessment showed a partial response, with tumor shrinkage by 70%. Despite reduced size, pericardial nodules and initially enlarged lymph nodes were still detectable. After completion of 2 additional cycles of chemotherapy, definitive radiation therapy was proposed.

A simulation CT scan was acquired with deep inspiration breath-hold (DIBH) for treatment planning purposes. DIBH volumetric modulated arc therapy (VMAT) was initially planned to deliver 60 Gy to the mediastinal mass, to the visible pericardial nodules, and to the left internal mammary chain. However, these target volumes were in direct contact with the heart and the most conformal VMAT would have delivered significant doses to the heart (mean heart dose = 19.38 Gy), to the lungs (mean dose to the right lung = 14.16 Gy, to the left lung = 19.08 Gy), and to the esophagus (mean dose = 16.8 Gy).

Proton beams deliver most of their energy nearby the end of proton courses, a phenomenon known as Bragg peak, and allow low distant-to-target dose deposition when compared with megavoltage photon beams. Therefore, our patient subsequently underwent PBT treatment planning (**Figure 1**). Spirometry-monitored DIBH-PBT was planned by using two 235-MeV double-scattered beams to treat the planned target volumes to 60 Gy (RBE = 1.1) in 30 fractions of 2 Gy during a period of 6 weeks. Dose-volume histograms of DIBH-VMAT and DIBH-PBT plans are provided in **Figure 2**. Compared with optimal DIBH-VMAT planning, DIBH-PBT allowed reduction of the mean dose to the heart by 3.72 Gy (15.66 Gy versus 19.38 Gy, 19.0% dose reduction), to the right lung by 5.9 Gy (8.26 Gy versus 14.16 Gy, 41.7% dose reduction), to the left lung by 3.63 Gy (15.45 Gy versus 19.08 Gy, 19.0% dose reduction), and to the esophagus by 3.57 Gy (13.23 Gy versus 16.8 Gy, 21.3% dose reduction). With the exception of grade 1 radiodermatitis, no acute radiation-induced adverse events were reported during treatment.

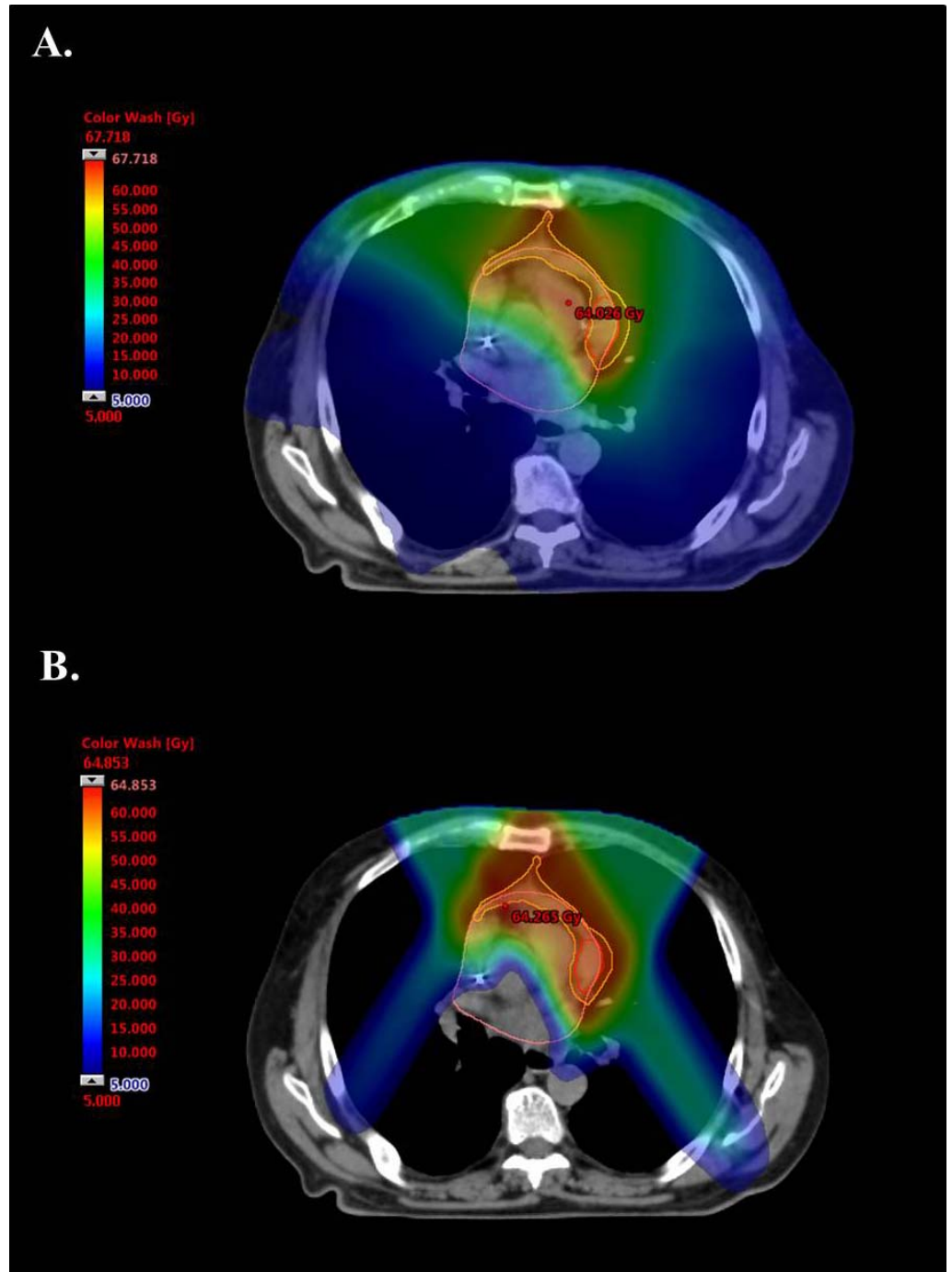
After PBT completion, CT reassessment showed a thin thymic scar tissue without apparent pericardial nodules, lymph nodes, or serous effusions. The patient was clinically asymptomatic. Local regional control was achieved for 3 months. A planned PET-CT subsequently revealed 2 abnormal hypermetabolic foci involving the posterior pericardial wall and the anterior superior mediastinum, the latter being an in-field recurrence. At the present time, after a 14-month follow-up, our patient is alive without any radiation-induced cardiac adverse events and is undergoing pembrolizumab-based immunotherapy.

## Discussion

To our knowledge, this is the first described case of a definitive radiation therapy treatment for a thymic malignancy invading the pericardium. In our case, a stage IVB thymic carcinoma with pericardial nodules, heart sparing was of foremost importance. Proton beam therapy was preferred to VMAT technique for dosimetric considerations.

Definitive radiation therapy is a standard of care for locally advanced stage III-IVA thymoma [2]. Proton therapy, which allows dose reduction to organs at risk without affecting coverage of the target volumes, has shown encouraging results in the postoperative setting [3], but also as a preoperative treatment [4] facilitating surgical resection. A prospective cohort study describing adjuvant and definitive PBT for thymic disease management was published in 2016 by Vogel et al [5]. Twenty-seven patients (median age, 56 years) with thymomas were treated by using PBT with a median prescribed dose of 63.6 Gy. This study reported low toxicities (no grade 3 event) and an excellent target coverage (99.3% of the target volumes received 95% of the prescribed dose). Three-year regional control was 96%. Another prospective cohort study of 30 patients (median age, 53 years) was published in 2019 by Mercado et al [6] and showed similar low rate of acute toxicities, mainly dermatitis (37%) and cough (13%). In those 2 cohorts, few patients were treated with definitive proton therapy (6 of 27 patients in Vogel et al [5] and 4 of 30 in Mercado et al [6]). These patients had mostly stage III or IVA thymic disease. Stage IVB thymoma is actually rare [2]. One case of a stage IVB thymoma treated with definitive PBT was reported by Vogel et al [5]: For this patient, regional relapse occurred in pericardial lymph nodes after 7.9 months. Our patient, with a stage IVB thymic carcinoma invading the pericardium, experienced an early in-field mediastinal relapse after 3.0 months. It should be recalled that proton beam technique is very sensitive to uncertainties, such as range or motion uncertainty. DIBH was used

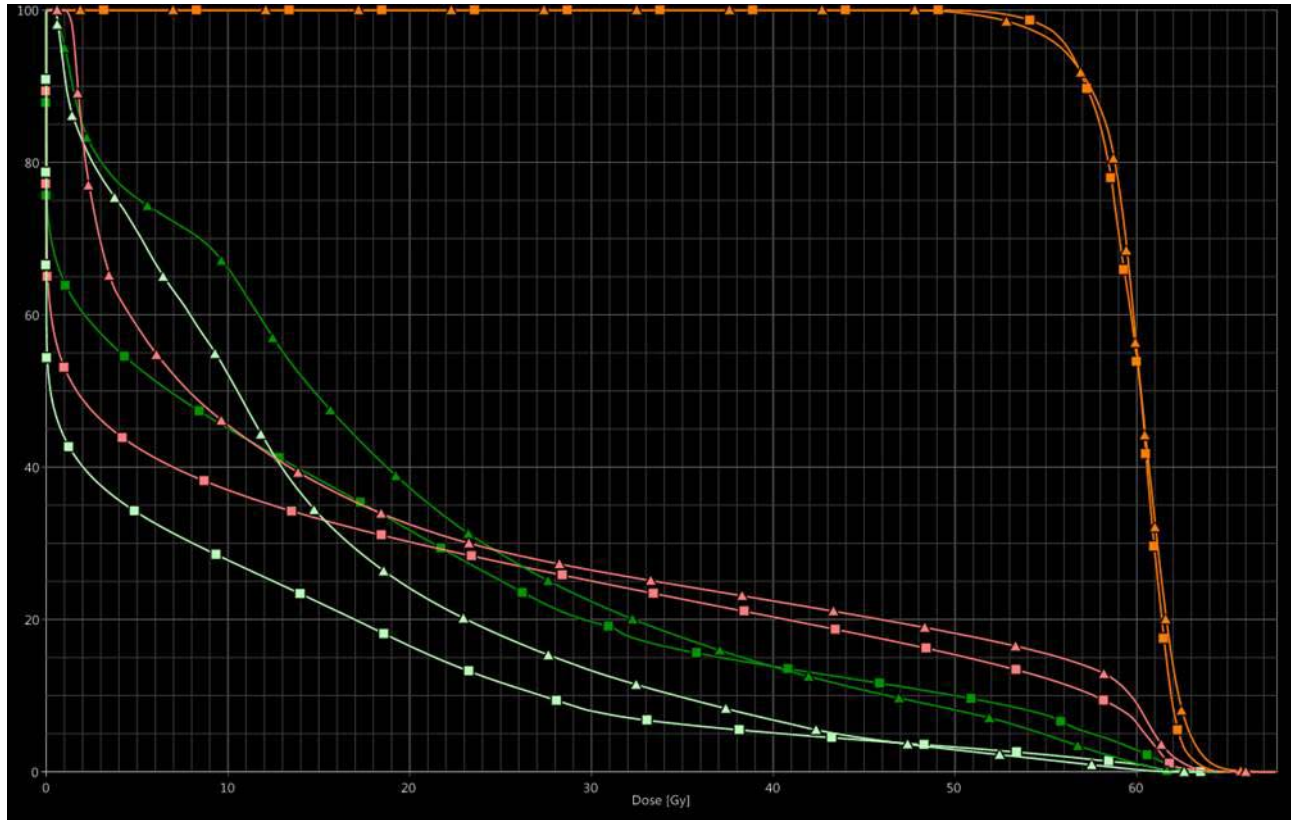
**Figure 1.** Comparison between DIBH volumetric modulated arc therapy planning (A) and DIBH double-scattering proton beam therapy planning (B). The GTV is delineated in red (on this simulation CT scan slice, a malignant pericardial nodule is visible); the CTV is delineated in orange; the heart is contoured in pink. Abbreviations: CT, computed tomography; CTV, clinical target volume; DIBH, deep inspiration breath-hold; GTV, gross tumor volume.



to limit breathing-induced chest wall motion, which uncertainty could have resulted in target underdosing. However, owing to spatial proximity between the heart and the target volume, cardiac motion might have led to geographic miss by the proton beams. In this context, relying on electrocardiography-gated 4-dimensional CT while planning PBT could be clinically beneficial. Overall, these observations tend to show that local regional control of stage IVB thymic malignancies remains challenging, even using optimal PBT combined with chemotherapy.

However, in our case, PBT followed by immunotherapy led to prolonged disease control, possibly suggesting synergistic interaction between radiation therapy and immunotherapy, as observed in other cancer types such as head and neck squamous cell carcinoma or non-small cell lung cancer.

In our case, irradiation pattern was complex because of pericardium involvement. Our clinical target volume had to include pericardial malignant nodules, which were directly adjacent to the heart. Static or rotational intensity-modulated

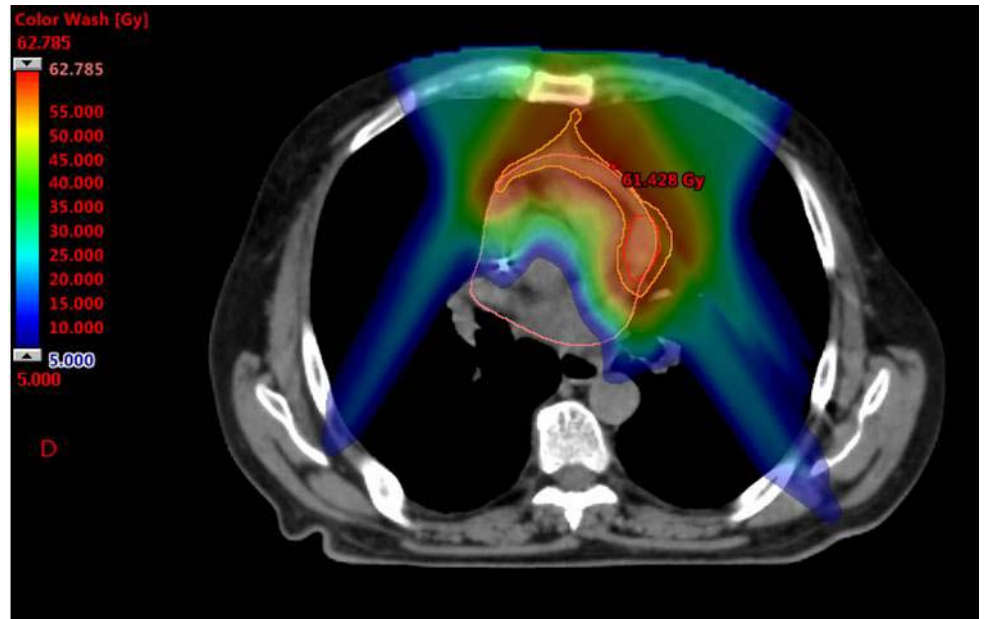


**Figure 2.** Dose-volume histograms of VMAT and DS PBT plans. Symbol legend: triangles – DS PBT; squares – VMAT. Color legend: orange – PTV; pink – heart; dark green – left lung; light green – right lung. X-axis: dose (Gy). Y-axis: relative volume (%). Abbreviations: DS, double-scattering; PBT, proton beam therapy; PTV, planned target volume; VMAT, volumetric modulated arc therapy.

radiation therapy (IMRT) techniques were considered not conformal enough to limit heart irradiation and we thought that proton therapy would be a more appropriate treatment modality to limit cardiac toxicities, which could include pericarditis, congestive heart failure, heart infarct, valvulopathies, and rhythmic troubles [7]. It has been shown that mean heart dose is significantly associated with grade  $\geq 3$  radiation-induced cardiotoxicity risk for lung cancer irradiation [8] and that the irradiated cardiac volume correlates with the severity of heart perfusion defects [9]. Owing to the radiobiological properties of proton beams, PBT demonstrated a substantial dosimetric benefit for cardiac sparing when compared with conventional photon radiation therapy for thymoma treatment, which may consequently result in fewer cardiac adverse events: 2 retrospective dosimetric studies comparing PBT versus IMRT for adjuvant thymoma irradiation reported a relative mean heart dose reduction of 36.5% to 42.5% [3, 10]. In our case, PBT treatment resulted in a 19% mean heart dose reduction from 19.38 Gy to 15.66 Gy. It should be noted that this mean heart dose is substantially higher than what has been observed in the cohort of Vogel et al (9.616 Gy) [5]. However, this observation was expected because malignant pericardial nodules were in direct contact with the heart and had to be included in the target volumes. Consequently, it follows that further heart sparing would have probably been arduous, regardless of the irradiation technique.

Most publications on PBT for thymic diseases report double-scattering (DS) techniques. Pencil-beam scattering (PBS) for thymoma is still rare and has been seldomly published [6]. Pencil-beam scattering has tended to become a standard of care for proton therapy worldwide: it increases conformity and uniformity in target coverage. A PBS plan for our patient has been retrospectively re-planned and is provided in **Figure 3**. Nevertheless DS usually tends to exhibit smaller lateral penumbra than PBS [11], which is worthwhile when sharp dose gradients are needed for precise irradiation. We took advantage of spirometry-controlled DIBH, to further limit nontarget irradiation and reduce heart toxicity. DIBH-PBT has been shown to decrease exposure of organs at risk and mean heart dose for mediastinal lymphoma irradiation [12]. Further dosimetric comparisons between PBS and DS, with or without DIBH, are needed to define the optimal technique for thymic proton therapy.

**Figure 3.** Pencil-beam scattering PBT plan. A PBS-PBT plan was re-planned by using the same dose constraints that were initially used for the treatment DS-PBT plan. Doses to the organs at risk are reported. Abbreviations: DS, double-scattering; PBS, pencil-beam scattering; PBT, proton beam therapy.



Structure	Double scattering PBT	Pencil beam scanning PBT
Heart (mean dose, Gy)	15.66	15.00
Left lung (mean dose Gy)	15.45	13.66
Right lung (mean dose Gy)	8.26	7.13
Esophagus (mean dose Gy)	13.23	9.70
Thyroid (mean dose Gy)	7.20	9.70
Skin (max. dose Gy)	60.67	51.08

## Conclusion

Proton beam therapy is an option for definitive irradiation of thymic malignancies invading the pericardium. In this situation, PBT reduces doses to the heart and may help to reduce cardiotoxicity when compared with photon radiation therapy techniques.

## ADDITIONAL INFORMATION AND DECLARATIONS

**Conflicts of Interest:** The authors have no conflicts of interest to disclose.

**Funding:** The authors have no funding to disclose.

**Ethical Approval:** Institutional review board approval was not required by our institution to report this single case.

## References

- Carter BW, Okumura M, Detterbeck FC, Marom EM. Approaching the patient with an anterior mediastinal mass: a guide for radiologists. *J Thorac Oncol.* 2014;9:S110–8.
- Falkson CB, Bezjak A, Darling G, Gregg R, Malthaner R, Maziak DE, Yu E, Smith CA, McNair S, Ung YC, Evans WK, Lung Cancer Disease Site Group of Cancer Care Ontario's Program in Evidence-Based Care. The management of thymoma: a systematic review and practice guideline. *J Thorac Oncol Off Publ Int Assoc Study Lung Cancer.* 2009;4:911–9.
- Parikh RR, Rhome R, Hug E, Tsai H, Cahlon O, Chon B, Goenka A. Adjuvant proton beam therapy in the management of thymoma: a dosimetric comparison and acute toxicities. *Clin Lung Cancer.* 2016;17:362–6.
- Kojima H, Isaka M, Nagata M, Onoe T, Murayama S, Ohde Y. Preoperative proton beam therapy for thymoma: a case report. *Ann Thorac Cardiovasc Surg.* 2016;22:186–8.
- Vogel J, Berman AT, Lin L, Pechet TT, Levin WP, Gabriel P, Khella SL, Singhal S, Kucharczuk JK, Simone CB 2nd. Prospective study of proton beam radiation therapy for adjuvant and definitive treatment of thymoma and thymic carcinoma: early response and toxicity assessment. *Radiother Oncol J Eur Soc Ther Radiol Oncol.* 2016;118:504–9.

6. Mercado CE, Hartsell WF, Simone CB, Tsai HK, Vargas CE, Zhu HJ, Henderson RH, Zeng J, L Larson GL, Hoppe BS. Proton therapy for thymic malignancies: multi-institutional patterns-of-care and early clinical outcomes from the Proton Collaborative Group and the University of Florida prospective registries. *Acta Oncol Stockh Swed.* 2019;58:1036–40.
7. Darby SC, McGale P, Taylor CW, Peto R. Long-term mortality from heart disease and lung cancer after radiotherapy for early breast cancer: prospective cohort study of about 300 000 women in US SEER cancer registries. *Lancet Oncol.* 2005; 6:557–65.
8. Dess RT, Sun Y, Matuszak MM, Sun G, Soni PD, Bazzi L, Murthy VL, Hearn JWD, Kong, FM Kalemkerian GP, Hayman JA, Ten Haken RK, Lawrence TS, Schipper MJ, Jolly S. Cardiac events after radiation therapy: combined analysis of prospective multicenter trials for locally advanced non–small-cell lung cancer. *J Clin Oncol.* 2017;35:1395–402.
9. Marks LB, Yu X, Prosnitz RG, Zhou S-M, Hardenbergh PH, Blazing M, Hollis D, Lind P, Tisch A, Wong TZ, Borges-Neto S. The incidence and functional consequences of RT-associated cardiac perfusion defects. *Int J Radiat Oncol Biol Phys.* 2005;63:214–23.
10. Zhu HJ, Hoppe BS, Flampouri S, Louis D, Pirris J, Nichols RC, Henderson RH, Mercado CE. Rationale and early outcomes for the management of thymoma with proton therapy. *Transl Lung Cancer Res.* 2018;7:106–13.
11. Safai S, Bortfeld T, Engelsman M. Comparison between the lateral penumbra of a collimated double-scattered beam and uncollimated scanning beam in proton radiotherapy. *Phys Med Biol.* 2008;53:1729–50.
12. Dabaja BS, Hoppe BS, Plastaras JP, Newhauser W, Rosolova K, Flampouri S, Mohan R, Mikhaeel NG, Kirova Y, Specht L, Yahalom J. Proton therapy for adults with mediastinal lymphomas: The International Lymphoma Radiation Oncology Group guidelines. *Blood.* 2018;132:1635–46.