



Case Report

Primary Adenocarcinoma at Ileostomy—A Rare Late Complication: Three Cases and Literature Review

Murad Bani Hani, Bryan Butler, Jeffery Visco, Bashir Alttuwaybi

Colon and Rectal Surgery, State University of New York at Buffalo, Buffalo, New York, USA

Introduction: Primary adenocarcinoma at the ileostomy site is a rare complication, with only 57 cases reported in the literature. The primary diagnosis is usually ulcerative colitis (UC) or familial adenomatous polyposis (FAP).

Cases: We present 3 cases of adenocarcinoma at the ileostomy site. Two of our 3 cases have a previous diagnosis of cancer, with no previous diagnosis of UC or FAP.

Discussion: Adenocarcinoma at ileostomy is a rare late complication of permanent ileostomy. Possible etiologies are chronic irritation and changes in bacterial flora that lead to metaplasia and cancer development.

Conclusion: Adenocarcinoma at the ileostomy site is a rare complication with good prognosis if detected early. Diagnosis is by biopsy, and treatment is surgical. A biopsy should be considered in any abnormal growth around the ileostomy.

Key words: Ileostomy – Adenocarcinoma – Small bowel cancer – Ulcerative colitis – Familial adenomatous polyposis

A permanent end ileostomy is indicated in patients who require a total proctocolectomy in which ileal pouch anal anastomosis is not possible. This procedure is usually performed in patients with ulcerative colitis (UC) or familial adenomatous polyposis (FAP) and certain patients with Crohn's disease. In other cases, a temporary ileostomy can become permanent if the patient is medically unfit or decides not to proceed with ileostomy closure.

Primary adenocarcinoma at the ileostomy site is a rare complication, with only 57 cases reported in the literature.¹ Of those, 15 patients had a primary diagnosis of FAP and 42 had a primary diagnosis of UC.⁴

End ileostomy adenocarcinoma is a late complication. The reported interval between TPC with ileostomy formation and diagnosis of ileostomy adenocarcinoma ranged from 3 to 51 years for UC

Corresponding author: Murad Bani Hani, MD.
E-mail: drmuradhani@gmail.com

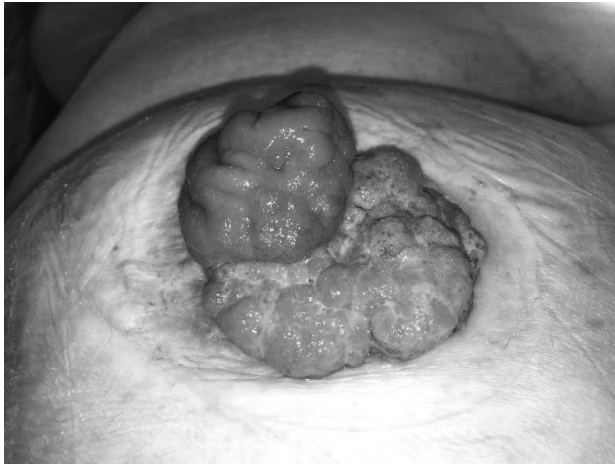

Fig. 1 Adenocarcinoma at ileostomy site.

and from 9 to 40 years for FAP,^{1,10,11} with a mean interval of 30 and 26 years, respectively.¹

We report 3 cases of adenocarcinoma at the ileostomy site; 2 of these cases had no previous diagnosis of UC or FAP.

Case Report 1

The first case is a 39-year-old female with a body mass index (BMI) of 49 kg/m² and a history of FAP treated with a total proctocolectomy with ileostomy in 1998. In 2003, she required laparotomy for small bowel obstruction secondary to adhesions. At that time, the mesentery was noted to be thickened in several areas, with whitish fibrous bands, suggestive of early desmoid tumors. The patient was placed on Celebrex. The patient developed a parastomal hernia with minimal symptoms for which she declined surgery. She continued her upper gastrointestinal endoscopic surveillance as per the established guidelines. Gastric fundic polyps and diminutive duodenal adenomatous polyps were removed.

The patient had yearly follow-up appointments that were unremarkable. She presented in December 2015 with a 2-month history of a “lump” next to her ileostomy with difficulty keeping the appliance in place, a foul odor, and bloody ileostomy output (Figs. 1 and 2). A biopsy was done in the office confirming a well-differentiated adenocarcinoma. A computed tomography (CT) scan demonstrated a large parastomal hernia and an ill-defined oblong infiltrating mass in the small bowel mesentery measuring 11 cm in length and 3 cm in diameter, consistent with a desmoid tumor.

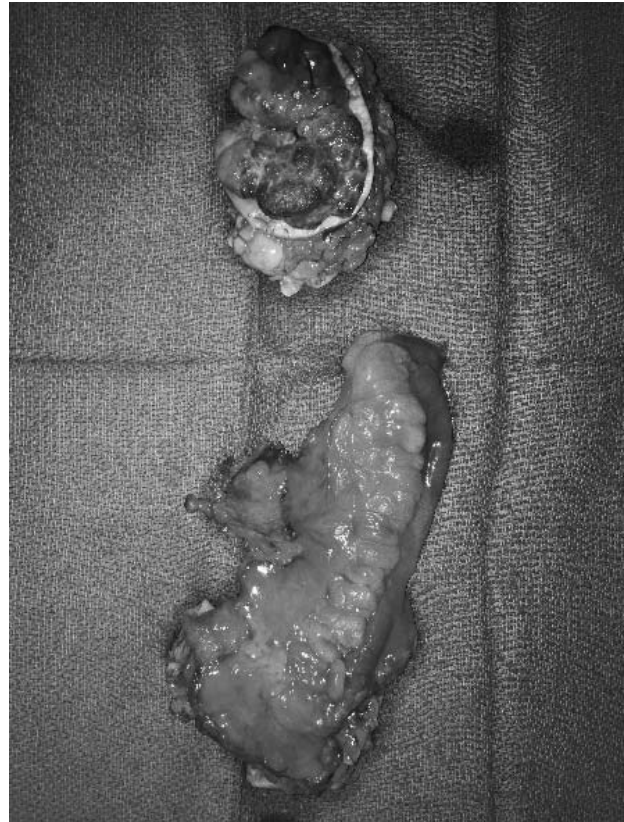

Fig. 2 Adenocarcinoma specimen.

Ileoscopy evaluated the distal 40 cm of the ileum without abnormality. Baseline CEA level was 5.2 ng/mL.

Surgical management consisted of a partial small bowel resection including the adenocarcinoma at the ileostomy site and repair of parastomal hernia with excision of the hernia sac and primary closure of the fascia. Plastic surgery was on standby in the event that the patient would require resiting of the ileostomy along with a complex abdominal wall closure. A closed surgical drain was used.

The patient recovered well and was discharged home on postoperative day 4 with the drain in place. This drain was removed on postoperative day 13. She presented 5 days later with a subcutaneous abscess adjacent to the ileostomy. This was managed with intravenous antibiotics and percutaneous drainage with resolution.

Case Report 2

This case is an 86-year-old male with a history of multiple medical problems. Initially, he had a right colectomy for carcinoid tumor in 2001; he recovered

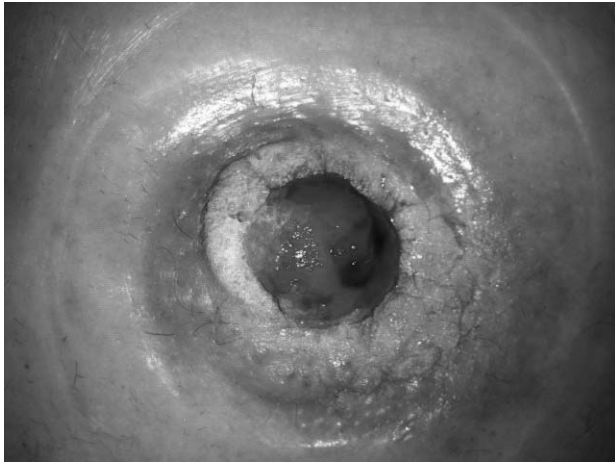


Fig. 3 Mucinous adenocarcinoma at ileostomy.

well from the first surgery. In 2005, he was diagnosed with descending colon cancer; he had completion colectomy and end ileostomy. In 2013, he presented with abnormal growth at the mucocutaneous junction and ileostomy bleeding. Biopsy of the growth showed mucinous adenocarcinoma for which he underwent a resection with relocation of ileostomy.

Case Report 3

This case is a 64-year-old female with a history of low rectal cancer and right colon cancer. She underwent total proctocolectomy and end ileostomy. Sixteen months later, she presented with ileostomy irritation, and a biopsy confirmed adenocarcinoma. She was treated with wide excision and ileostomy relocation. The follow-up PET scan was negative.

Discussion

Since the introduction of permanent ileostomy as a surgical treatment option, a number of complications have been observed including skin excoriations, retraction or prolapse of the stoma, stenosis, intestinal obstruction, abscess, fistula, ileitis, and inflammatory polyps.⁸ Malignancy at the ileostomy site is also a known but rare complication.^{1,3,9,11}

The incidence of small bowel malignancy in the general population is 0.7 per 100,000.¹ The ileum is most frequently involved (49%) followed by the jejunum (29%) and duodenum (22%). In contrast, adenocarcinoma of the small bowel is least commonly found in the ileum (22%), followed by the

jejunum (38%) and duodenum (40%). Suarez *et al* estimated the incidence of ileostomy carcinomas in Britain to be 2–4 per 1000 ileostomies.^{5,7}

Primary adenocarcinoma at the ileostomy site after total proctocolectomy for FAP is even more unusual, with a very low number of published cases.⁶

Our first case report illustrates the complicated management of a patient with 2 rare manifestations of FAP. Carcinomas of the upper gastrointestinal tract in FAP are rare.¹ Furthermore, the operative decision making was complicated by the presence of high BMI and a large parastomal hernia. Fortunately, there was a large amount of small bowel and mesentery in the parastomal hernia, and this allowed for an adequate oncologic resection without a need for laparotomy. Primary closure of the fascia was feasible, obviating the need for a laparotomy and additional intra-abdominal surgical trauma that may have accelerated the growth of the desmoid. A more extensive repair of the hernia would have likely required a complex abdominal wall closure. The tradeoff was accepting a higher risk of recurrence of the parastomal hernia, but we considered this to be preferable than the potential progression of the desmoid.

Our search showed that the most common malignancy at ileostomy site is adenocarcinoma.¹

We found 57 cases of adenocarcinoma reported in the literature¹: 42 adenocarcinoma after TPC for UC and 15 adenocarcinoma after TPC for FAP,⁴ 6 cases were SCC, and 1 case was lymphoma.¹

Our second and third reported cases has no history of UC or FAP.

Symptoms are bleeding, difficulty fitting the stoma appliance, and bowel obstruction.^{1,4}

The differential diagnosis is Crohn's disease, ileitis, or backwash ileitis at the stoma, pseudoepitheliomatous hyperplasia, extensive pseudopolyposis or granulation tissue, pyoderma gangrenosum, and squamous cell carcinoma.¹

On examination, a polypoidal friable bleeding mass or ulcerative lesion at the mucocutaneous junction of the ileostomy.^{1,4}

The etiology of ileostomy adenocarcinoma is unclear.^{1,9} Patients with a long-standing ileostomy following TPC for UC and FAP appear to be at a greater risk of developing adenocarcinoma at the ileostomy site than patients with an end ileostomy because of other non-UC and/or no FAP disease.⁴

Possible etiologies are mentioned in the literature: chronic irritation may predispose the ileal mucosa to colonic metaplasia, dysplasia, and frank malignant

Table 1 Reported ileostomy adenocarcinoma

Author, year	Age at primary diagnosis (yr)	Interval from surgery to AdenoCA (yr)	Primary diagnosis	Treatment
Sigler, 1969	40	19	UC	
Cuesta, 1976	29	31	UC	
Johnson, 1980	39	3	UC	
Roth, 1982	35	9	FAP	
Styker, 1983	41	25	UC	
Baciewicz, 1983	13	32	UC	
Suarez, 1985	25	4	UC	
Bedetti, 1986	22	23	UC	
Vasilevsky, 1986	22	38	UC	
Longo, 1986	45	28	UC	
Suarez, 1986	29	4	UC	
Suarez, 1987	30	4	UC	
Ross, 1987	24	32	FAP	
O'Connell, 1987	34	36	UC	
Carter, 1988	36	43	UC	
Suarez, 1988	11	29	FAP	
Suarez, 1988	35	4	UC	
Smart, 1988	32	28	UC	
Coen, 1988	39	3	UC	
Primrose, 1988	47	25	FAP	
Ewing, 1989	28	30	UC	
Roberts, 1989	23	31	UC	
Roberts, 1989	33	25	UC	
Berman, 1989	27	34	UC	
Pellissier, 1990	28	33	UC	
Fernandez Rivera, 1990	36	23	UC	
Gadacz, 1990	26	34	UC	
Lopez, 1991	23	27	FAP	
Gilson, 1992	29	40	FAP	
Lux, 1993	47	25	FAP	
Carey, 1993	28	36	UC	
Starke, 1993	27	35	UC	
Johnson, 1993	40	25	FAP	
Listinsky, 1994	51	11	UC	
Attanoos, 1995	33	36	UC	
Attanoos, 1995	37	27	UC	
Cox, 1997	22	17	UC	
Reissman, 1997	16	48	UC	
Wu, 1998	25	42	FAP	
Mumira, 1999	33	21	FAP	
Carne, 2001	25	41	UC	
Pranesh, 2002	20	58	UC	
Ramanujam, 2002	25	51	UC	
Lizuki, 2002	55	14	FAP	
Hata, 2003	25	32	FAP	
Abela, 2004	18	30	UC	
Achneck, 2005	39	46	UC	
Agibiti, 2005		31	UC	
Azem, 2005	19	29	UC	
Quah, 2005	43	35	UC	
Annam, 2008	30	35	UC	
Shenoy, 2009	25	10	FAP	
Mohandas, 2010	13	48	UC	
Chang, 2014	29	21	UC	
Procaccino, 2015	35	50	UC	
Procaccino, 2015	48	30	FAP	
Huntington, 2017	17	24	FAP	
	39	17	FAP	
	86	8	Carcinoid/colon adenoCA	
	64	2	Right colon and rectal adenoCA	

change,^{1,2,4} and the disease process that precipitated the formation of ileostomy may play a causative role in carcinoma formation.⁴ Changes in the bacterial flora also have been reported to be associated with cancer occurrence, as well as an association between ileitis or backwash ileitis and mucosal dysplasia and cancer transformation.^{1,9}

Malignant transformation in a preexisting benign adenoma.³ Some authors have hypothesized that ileostomies created more than 20 years ago are at an increased risk. The potential for this malignant transformation should serve as a reminder to monitor the ileostomy in these patients and biopsy any mucosal abnormalities.⁴

Two of our reported cases had no UC or FAP, which suggests that ileostomy adenocarcinoma development could occur regardless of the primary etiology that led to creation of the permanent ileostomy.

The treatment remains surgical. An en bloc wide local excision of the ileostomy with the adjacent anterior abdominal wall with or without transposition of the stoma to a new site has been shown to provide the best prognosis for an adenocarcinoma arising from an ileostomy,^{1,2,4,10} with an 85% survival rate.^{1,2}

Lymph node involvement is reported in 19% of cases, and in this group of patients, adjuvant therapy may have additional benefit.¹

Table 1 summarizes all the reported ileostomy adenocarcinoma cases; the last 3 cases in the table are the cases reported in this paper.

Conclusion

Although ileostomy adenocarcinoma is rare, its incidence seems to be on the rise with increasing number of case reports in the last few years.¹

The patient, ostomy nurse, and surgeon should be aware of this late complication, and an annual examination for ileostomy is advised.^{1,9} Any abnormal growth and/or nonhealing wound should be considered for biopsy. Treatment is wide excision

with lymph node sampling, and overall prognosis seems to be good.

References

1. James SD, Hawkins AT, M'Koma AE. Adenocarcinoma at the ileostomy site after a proctocolectomy for ulcerative colitis and/or familial adenomatous polyposis: an overview. *Ostomy Wound Manage* 2018;**64**:30–40
2. Procaccino L, Rehman S, Abdurakhmanov A, McWhorter P, La Gamma N, Bhaskaran MC *et al*. Adenocarcinoma arising at ileostomy sites: two cases and a review of the literature. *World J Gastrointest Surg* 2015;**7**:94–97
3. Hammad A, Tayyem R, Milewski PJ, Gunasekaran S. Primary adenocarcinoma in the ileostomy of a woman with familial adenomatous polyposis: a case report and literature review. *J Med Case Rep* 2011;**5**:556
4. Mohanda S, Lake S. Primary adenocarcinoma of ileostomy: case report with review of the literature. *Case Rep Med* 2010
5. Aparicio T, Zaanan A, Svrcek M, Laurent-Puig P, Carrere N, Manfredi S *et al*. Small bowel adenocarcinoma: epidemiology, risk factors, diagnosis and treatment. *Digestive Liver Dis* 2014;**46**:97–104
6. Iizuka T, Sawada T, Hayakawa K, Hashimoto M, Udagawa H, Watanabe G. Successful local excision of ileostomy adenocarcinoma after colectomy for familial adenomatous polyposis: report of a case. *Surg Today* 2002;**32**:638–641
7. Suarez V, Alexander-Williams J, O'Connor HJ, Campos A, Fuggle WJ, Thompson H *et al*. Carcinoma developing in ileostomies after 25 or more years. *Gastroenterology* 1988;**95**: 205–208
8. Brooke BN. The management of an ileostomy, including its complications. *Lancet* 1952;**2**:102–104
9. Roberts PL, Veidenheimer MC, Cassidy S, Silverman ML. Adenocarcinoma arising in an ileostomy. Report of two cases and review of the literature. *Arch Surg* 1989;**124**:497–499
10. Sigler L, Jedd FL. Adenocarcinoma of the ileostomy occurring after colectomy for ulcerative colitis: report of a case. *Dis Colon Rectum* 1969;**12**:45–48
11. Gilson TP, Sollenberger LL. Adenocarcinoma of an ileostomy in a patient with familial adenomatous polyposis. Report of a case. *Dis Colon Rectum* 1992;**35**:261–265