



## Case Report

# Rare Case of Colonic Perforation From Disseminated Fungal Infection in Immunocompetent Patient

Ju Yong Cheong<sup>1</sup>, Shadi Faraj<sup>2</sup>

<sup>1</sup>Department of Colorectal Surgery, Royal Prince Alfred Hospital, University of Sydney, Sydney, Australia

<sup>2</sup>Department of General Surgery, Blacktown Mount Druitt Hospital, New South Wales, Australia

**Introduction:** Fungal infection is a serious complication seen in immunosuppressed patients. Fungal dissemination and infection of the intestine is a rare complication noted in the literature. We report an extremely rare case of colonic perforation from dissemination fungal infection in an immunocompetent patient.

**Case presentation:** A 76-year-old man presented with a 1-week history of pneumonia-like symptoms of fever, lethargy, productive cough, and night sweats. On examination he was hypotensive and hypoxic. Chest X-ray showed bilateral diffuse consolidation. Peripheral blood showed raised white cell count and inflammatory markers. His background history included chronic lymphocytic leukemia for which he has been in remission for over 7 years. Preliminary diagnosis of pneumonia was made and the patient was started on intravenous antibiotics. His condition deteriorated over the course of 3 weeks, culminating in multi-organ failure, including acute renal failure requiring dialysis, respiratory failure requiring intubation, and hypotension requiring inotropic support. Culture of bronchial washing revealed growth of *Pseudomonas aeruginosa* and *Candida glabrata*. On the 19th day of admission, the patient's condition further deteriorated with colonic perforation and feculent peritonitis. Emergency laparotomy with removal of involved colon and end colostomies were performed. Histopathology of the involved colon showed 1.5 cm perforation with inflammatory infiltration. Histopathologic staining showed angioinvasive fungal infection with *Aspergillus*.

**Discussion/conclusion:** *Aspergillus* usually spreads hematogenously from the lungs. Gastrointestinal involvement is difficult to diagnose as the symptoms are often vague and

---

Corresponding author: Ju Yong Cheong, MBBS, PhD, FRACS, Department of Colorectal Surgery, Royal Prince Alfred Hospital, University of Sydney, 50 Missenden Rd, Camperdown NSW 2050, Australia.  
Tel.: +61 409 110 219; E-mail: juyong.cheong@gmail.com

masked by other systemic symptoms. Computed tomography scan can show bowel wall thickening. However, often the diagnosis is only made postoperatively.

*Key words:* Colonic perforation – Dissemination – Fungal infection

**F**ungal infection is a known and serious complication seen in immunosuppressed patients. The causative organisms are usually *Candida* or *Aspergillus*, *Histoplasma capsulatum*, and occasionally a phycomyete such as *Mucor*.<sup>1</sup> The number of cases of invasive and disseminated fungal infection is increasing, and may be attributed to development of more effective, but more toxic chemotherapy agents.<sup>2,3</sup> Disseminated *Aspergillus* infection is highly lethal. The most common portal of entry in disseminated *Aspergillus* is the lung. From there it spreads to cranial sinuses, the brain, gastrointestinal tract, liver, and heart.<sup>3,4</sup> The reported cases of intestinal dissemination and perforation from fungal infection have been on immunosuppressed patients.<sup>1,3,4-8</sup> We present an extremely rare case of colonic perforation from disseminated fungal infection in a non-immunosuppressed patient.

### Case Report

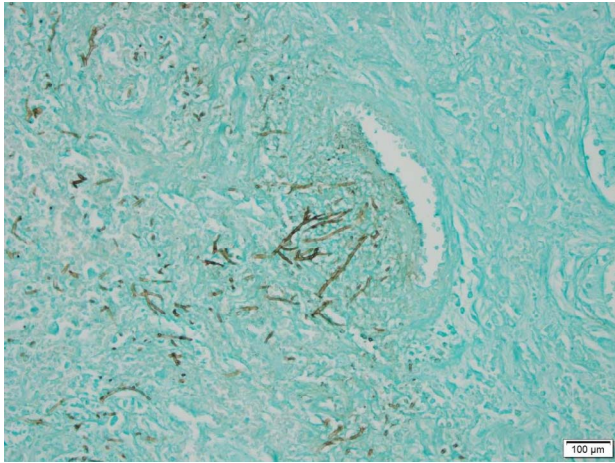
A 76-year-old man presented with a 1-week history of pneumonia like symptoms including fever, myalgia, lethargy, productive cough, and night sweats. On examination the patient was pale and hypotensive with blood pressure of 93/70 and heart rate of 98. His oxygen saturation was low at 88% on room air. On chest auscultation, there were diffuse crackles bilaterally. Chest X-ray showed bilateral diffuse consolidations. Full blood count showed raised white cell count of  $20.4 \times 10^9 / L$  ( $4-11 \times 10^9 / L$ ) with raised lymphocytes count of  $12 \times 10^9 / L$  ( $1.5-3.5 \times 10^9 / L$ ) and c-reactive protein level of 494.4 mg/L (1.0-3.0 mg/L). Past medical history included chronic lymphocytic leukemia diagnosed 7 years ago, which has been in remission. The patient has not been on any cytotoxic agents nor immunosuppressants. Initial diagnosis of community acquired pneumonia was made and patient was started on intravenous antibiotics (ceftriaxone and azithromycin). Patient condition deteriorated with multi-organ failure. He developed respiratory failure requiring intubation and tracheostomy, acute renal failure requiring hemodialysis, and hypotension requiring inotropic support. Subsequent investigation including bronchial washing and culture

showed growth of *Pseudomonas aeruginosa* and *Candida glabrata*. On the 19<sup>th</sup> day of admission patient developed abdominal distension, rising inotropic requirement to maintain blood pressure, and computed tomography (CT) scan showed free fluid and gas in the peritoneum (Fig. 1). Emergency laparotomy showed heavily soiled feculent peritonitis, with 1-1.5 cm perforation in the mid-transverse colon. Extended right hemicolectomy was performed, involving removal of right colon and transverse colon to splenic flexure. No anastomosis was performed due to hemodynamic instability and a left-sided colostomy and right-sided end ileostomy was fashioned.

Histopathology of the colon showed inflammation at the site of perforation of the transverse colon with lymphocyte and neutrophil infiltration. Thrombosed vessels with angioinvasive fungal elements were identified on hematoxylin and eosin (H&E) staining (Image 2) and Grocott's methenamine silver (GMS) staining (Fig. 2). The fungal hyphae had acute angle branching with septation, suggestive of *Aspergillus*. Abundant fungal elements were seen within the ulcer slough at the site of perforation, suggestive of ischemic perforation secondary to fungal thrombi. There was no hematologic and immunohistologic features suggestive of relapse of leukemia (normal distribution of CD3, CD5, CD10, CD20, CD21, CD23, CD43, CD 79a, cyclin D1, bcl2, bcl6).

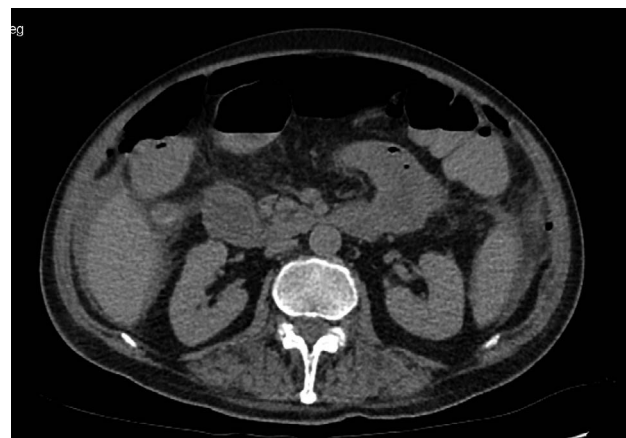

Fig. 1 CT showing free intraabdominal gas.



**Fig. 2** GMS stain showing fungal hyphae.

## Discussion/Conclusion

*Aspergillus* invades and proliferates in the blood vessels, becoming a bacterial embolism with subsequent haematogenous dissemination. Invasive aspergillosis is associated with high mortality and most affected patients have neutropenia. The most common portal of entry in disseminated *Aspergillus* is the lung. From there it spreads to cranial sinuses, the brain, gastrointestinal tract, liver, and heart.<sup>3,4</sup> Disseminated aspergillosis can cause bowel infarction or diffuse peritonitis from a small bowel perforation. Involvement of intestine in the absence of primary pulmonary disease is unusual. One study reported that 12 of 14 patients with lower gastrointestinal fungal infection also had pulmonary and upper gastrointestinal infection.<sup>5</sup> Another study reported that 25 of 27 patients with aspergillosis had pulmonary involvement.<sup>9</sup>

Establishing the diagnosis of intestinal aspergillosis in a neutropenic patient is difficult because the symptoms of abdominal pain and systemic infection is non-specific. Also as was with our patient, the lung is usually the primary site of infection and a preliminary diagnosis of community acquired pneumonia is usually made. Blood and sputum cultures are usually negative in the majority of cases.<sup>6</sup> Contrast-enhanced CT scan is indicated for acute abdominal pain and the findings can include segmental wall thickening, localized ischemia, small bowel obstruction secondary to segmental mural thickening, diffuse small bowel distension with a “target sign,” inflammation of the mesenteric fat, and perforation.<sup>1,3,10</sup> However, as was with our

patient, often the final diagnosis is most often established by the pathologic findings of a surgically resected specimen.

## Acknowledgments

The paper is not based on previous communication to a society or meeting. This article has not been submitted to another journal. All authors are in agreement over the content of the article. All authors declare no direct interest, including financial interest associated with the subject matter or material of this study. All authors declare there has been no support in the form of grants, equipment, drugs or all of these for this study.

## References

1. Brett MT, Kwan JTC, Bending MR., Caecal perforation in a renal transplant patient with disseminated histoplasmosis. *J Clin Pathol* 1988;**41**(9):992–995
2. Alonso MAS, Ramos IJ, Lleti MS, Peman J. Epidemiology of invasive fungal infections due to *Aspergillus spp* and *Zygomycetes*. *Clin Microbial Infect* 2006;**12**(7):2–6
3. Tresallet C, Nguyen-Thanh Q, Aubriot-Lorton MH, Akakpo JP, Al Jijakli A, Cardot V *et al*. Small-bowel infarction from disseminated aspergillosis. *Dis Colon Rectum* 2004;**47**(9):1515–1518
4. Catalano L, Picardi M, Anzivino D, Insabato L, Notaro R, Rotoli B. Small bowel infarction by *Aspergillus*. *Haematologica* 1997;**82**(2):182–183
5. Prescott RJ, Harris M, Banerjee SS. Fungal infections of the small and large intestine. *J Clin Pathol* 1992;**45**(9):806–811
6. Enjoji M, Ohtsukasa S, Nagano H, Matsuki M, Kawachi Y, Kurisu A *et al*. Localized small-bowel infarction caused by *Aspergillus* during chemotherapy for acute myeloid leukemia: report of a case. *Surg Today* 2008;**38**(5):449–452
7. Eggimann P, Chevrolet JC, Starobinski M, Majno P, Totsch M, Chapuis B *et al*. Primary invasive aspergillosis of the digestive tract: Report of two cases and review of the literature. *Infection* 2006;**34**(6):333–338
8. Mohite U, Kell J, Haj MA, O'Brien C, Kundu S, Rees J. Invasive aspergillosis localized to the colon presenting as toxic megacolon. *Eur J Haematol* 2007;**78**(3):270–273
9. Schwesinger G, Junghans D, Schoder, Bernhardt H, Knoke M. Candidosis and aspergillosis as autopsy findings from 1994 to 2003. *Mycoses* 2005;**48**(3):176–180
10. Shah SS, Birnbaum BA, Jacobs JE. Disseminated aspergillosis inciting intestinal ischaemia and obstruction. *Br J Radiol* 2001; **74**(888):1145–1147