



Usefulness of Gadolinium Ethoxybenzyl Diethylenetriamine Pentaacetic Acid–Enhanced Magnetic Resonance Imaging for the Evaluation of Hepatic Functional Reserve

Hiroya Iida¹, Tsukasa Aihara², Shinichi Ikuta², Naoki Yamanaka²

¹Department of Surgery, Shiga University of Medical Science, Japan

²Department of Surgery, Meiwa Hospital, Japan

Background: To determine the usefulness of the enhanced rate of gadolinium ethoxybenzyl diethylenetriamine pentaacetic acid–enhanced magnetic resonance imaging (EOB-MRI) during the hepatobiliary phase as a new parameter for hepatic functional reserve.

Aim: We retrospectively analyzed 153 patients who underwent EOB-MRI before radiofrequency ablation or hepatic resection between January 2008 and December 2012. The enhanced rate during the hepatobiliary phase was estimated using the ratio of regions of interest in the liver parenchyma to that in the paraspinal muscles. The enhanced rate was examined along with liver function tests and fibrosis levels for any correlations.

Results: A high correlation was found between the enhanced rate and indocyanine green retention rate at 15 minutes ($r = -0.66$, $P < 0.0001$). Additionally, a moderate correlation was discovered between the enhanced rate and serum albumin ($r = 0.57$, $P < 0.0001$), and fibrosis level ($r = -0.48$, $P < 0.0001$). The enhanced rate also weakly correlated with platelet count ($r = 0.28$, $P = 0.0005$), aspartate aminotransferase ($r = -0.37$, $P < 0.0001$), total bilirubin ($r = -0.26$, $P = 0.0014$), and prothrombin activity ($r = 0.27$, $P = 0.0014$).

Conclusions: The EOB-MRI–enhanced rate during the hepatobiliary phase strongly correlates with hepatic functional reserve.

Key words: EOB-MRI – Hepatic functional reserve – Hepatobiliary phase

Corresponding author: Hiroya Iida, Department of Surgery, Shiga University of Medical Science, Seta Tsukinowa-cho, Otsu, Shiga, 520-2192, Japan.

Tel.: +81 77 548 2238; Fax: +81 77 548 2240; E-mail: hiroya@belle.shiga-med.ac.jp

Gadolinium ethoxybenzyl diethylenetriamine pentaacetic acid-enhanced magnetic resonance imaging (EOB-MRI) allows the detection of small and hypovascular hepatocellular carcinomas (HCCs) during the hepatobiliary phase by identifying low-intensity areas, which conventional enhanced computed tomography (CT) cannot detect. While the usefulness of EOB-MRI as a new diagnostic modality for HCC has been reported,^{1,2} several reports have suggested that gadolinium ethoxybenzyl diethylenetriamine pentaacetic acid (Gd-EOB-DTPA) uptake by hepatocytes may decrease in patients with chronic liver dysfunction.³

EOB is a structure in which an ethoxybenzyl group, a fat-soluble side chain, is introduced into gadopentetic acid, a contrast agent distributed in the extracellular fluid. In the T1-weighted image, a signal-enhancement effect of gadolinium ion was observed. After intravenous administration, the EOB is shared in the intravascular and cell gaps and is taken into hepatocytes by ethoxybenzyl groups. EOB taken into hepatocytes was excreted into the bile and feces. If the EOB 0.1 mL/kg was intravenously administered to healthy adults, approximately 60% of the dose was excreted in the urine, approximately 40% was excreted in the feces. Meanwhile, if mild to moderate liver damage (Child–Pugh grades A and B) patients were administered EOB, its excretion in the feces was 21% and was lower than in healthy adults. In patients with severe liver damage (Child–Pugh grade C), excretion of EOB reduced to 6%. Furthermore, in patients with a serum bilirubin value of 3 mg/dL or more, it fell to less than 0.5%. In these patients with severe liver damage, significant loss of signal-enhancement effects of liver parenchyma was observed.

EOB, which is moved from the hepatic sinusoid to the space of Disse, is actively transported into hepatocytes through a transporter expressed in the hepatocellular membrane. As a transporter involved in EOB to be taken into the hepatocyte, OATP1B1, and OATP1B3, which are subfamilies of organic anion transporting polypeptide (OATP), and Na⁺-dependent taurocholate cotransporting peptide (NTCP) has been identified.^{4,5} Alternatively, OATP1B1 is mostly involved in the transport of bilirubin, which is widely used as an indicator of hepatic functional reserve; OATP1B3 and NTCP are primarily involved in the transport of indocyanine green, which is also widely used as an indicator of hepatic functional reserve.^{6,7}

From the above studies, EOB-MRI-enhanced rate during the hepatobiliary phase may be correlated with hepatic functional reserve.

This study aimed to determine the usefulness of EOB-MRI-enhanced rate during the hepatobiliary phase as a new parameter of hepatic functional reserve.

Materials and Methods

Patients

We retrospectively analyzed 153 patients who had undergone EOB-MRI before radiofrequency ablation (RFA) or hepatic resection between January 2008 and December 2012. The inclusion criteria include patients aged 20 years or older and patients who obtained informed consent. The exclusion criteria included patients with a history of liver treatment as the signal intensity of EOB-MRI may have been modified by the treatment.

MRI

All patients underwent MRI using a superconducting magnet operating at 1.5 T (Intera 1.5 T, Philips Medical Systems Nederland B.V., Best, The Netherlands) and a 32-channel phased-array coil. After precontrast, T1-weighted fast-spoiled gradient-echo imaging, T2-weighted fast spin-echo images, and diffusion-weighted single-shot spin-echo echo-planar images were obtained. Dynamic images using fat-suppressed T1-weighted gradient-echo images with a 3-dimensional acquisition sequence were obtained before contrast. At 20 seconds, 60 seconds, 3 minutes, and 20 minutes after intravenous injection of Gd-EOB-DTPA using a power injector (Sonic Shot GX, Nemoto Kyorindo Co, Ltd, Tokyo, Japan). Hepatobiliary phase imaging was obtained 20 minutes after injecting 0.1 mL/kg Gd-EOB-DTPA in the patients. The images acquired were in the transverse plane and had a section thickness of 3 mm and 1.5-mm overlap. The repetition time/echo time was 5.4/2.6 ms; flip angle, 12°; number of signals acquired, 1; field of view, 38 × 30 cm; matrix, 256 × 256; and acquisition time, 17 seconds.

Quantification of EOB-MRI-enhanced rate

The signal intensities of the liver were measured in the hepatobiliary phase. The EOB-MRI-enhanced rate was estimated as the ratio of the mean value of the regions of interest (ROIs) randomly selected from 8 individual subsegments in the liver parenchyma to the mean value of the ROIs in paraspinal

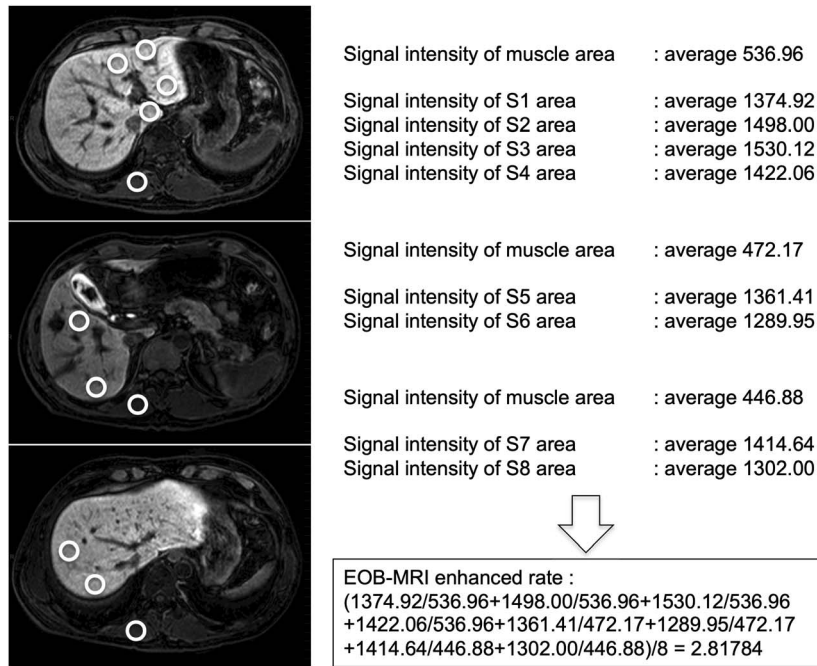


Fig. 1 Quantification of EOB-MRI-enhanced rate. The mean values of the ROIs of all 8 subsegments were divided using mean values of ROIs in paraspinal muscles in the same axial image. We defined the average value of the 8 subsegments as EOB-MRI-enhanced rate.

muscles. The equation used for this calculation is as follows (Fig. 1): EOB-MRI-enhanced rate = (signal intensity of the liver parenchyma [SILP] in segment 1 [S1]/signal intensity of the paraspinal muscle [SIPM] in the same axial image + SILP in S2/SIPM in the same axial image + SILP in S3/SIPM in the same axial image + SILP in S4/SIPM in the same axial image + SILP in S5/SIPM in the same axial image + SILP in S6/SIPM in the same axial image + SILP in S7/SIPM in the same axial image + SILP in S8/SIPM in the same axial image)/8. Each ROI with a diameter of 10 to 15 mm depending on the organ size was figured, but the Glisson's capsule and the hepatic vein were excluded in the ROI (Fig. 1).

Biochemical tests and pathologic results

The indocyanine green retention rate at 15 minutes (ICGR 15), platelet counts, prothrombin activity, alanine aminotransferase (ALT), aspartate aminotransferase (AST), total bilirubin, and serum albumin were investigated in less than a week before MRI.

Histologic findings of liver fibrosis levels were measured according to the METAVIR classification⁸ using resected specimens from patients who underwent hepatic resection or biopsy specimens from patients who underwent RFA (F0, no fibrosis; F1, fibrous portal expansion; F2, rare bridges or septae; F3, numerous bridges or septae; F4, cirrhosis).

Statistical analysis

Continuous variables were expressed as mean \pm SD. Spearman rank correlation coefficient test was used to determine the correlation between EOB-MRI-enhanced rate and ICGR 15, platelet count, prothrombin activity, ALT, AST, total bilirubin, and serum albumin, and fibrosis levels. A correlation coefficient value of up to 0.20 exhibited virtually no correlation; 0.21 to 0.40, weak correlation; 0.41 to 0.60, moderate correlation; 0.61 to 0.80, high correlation; and 0.81 or greater, very high correlation. All analyses were conducted using statistical software JMP 9.0.2 (SAS Institute, Tokyo, Japan).

Results

Patients' characteristics

Patients' characteristics are reported in Table 1. The mean age was 69 ± 8 years. There were 32 and 84 patients who had hepatitis B and C, respectively; 37 patients had neither hepatitis B nor C. The details of patients who had neither hepatitis B nor C included 24 cases of alcohol abuse, 9 cases of nonalcoholic steatohepatitis, 1 case of autoimmune hepatitis, and 3 cases of unknown etiology. RFA was conducted in 61 patients, and 92 patients underwent hepatic resections. The mean albumin level was 3.9 ± 0.4 g/dL; prothrombin activity, $82\% \pm 13\%$; total bilirubin level, 0.8 ± 0.3 mg/dL; AST level, 47 ± 29 IU/L; ALT level, 41 ± 28 IU/L; platelet count, 13

Table 1 Patients' characteristics^a

Variables	n = 153
Age (years)	69 ± 8
Sex (men:women)	107:46
Background liver disease (HCV:HBV:NBNC)	84:32:37
Treatment method (hepatic resection: RFA)	92:61
Albumin level (g/dL)	3.9 ± 0.4
Prothrombin activity (%)	82 ± 13
Total bilirubin level (m/dL)	0.8 ± 0.3
AST (IU/L)	47 ± 29
ALT (IU/L)	41 ± 28
Platelet count (×104/μL)	13 ± 8
ICGR 15 (%)	19 ± 12
Liver fibrosis level ^b (F1:F2:F3:F4)	20:32:28:73

HCV, positive for hepatitis C antibody; HBV, positive for hepatitis B antigen; NBNC, negative for hepatitis C antibody and hepatitis B antigen.

^aData are expressed as mean ± SD in continuous variables.

^bLiver fibrosis levels were categorized according to METAVIR classification.

± 8 × 104/μL; and ICGR 15, 19% ± 12%. The fibrosis levels were classified as F1, F2, F3, and F4 in 20, 32, 28, and 73 patients, respectively (Table 1).

Correlation with the parameters of hepatic functional reserve

The mean duration between EOB-MRI and RFA or hepatic resection was 26 days. No other medical intervention was conducted between EOB-MRI and RFA or hepatic resection.

A high correlation was found between EOB-MRI-enhanced rate and ICGR 15 ($r = -0.66$, $P < 0.0001$). Additionally, a moderate correlation was discovered between EOB-MRI-enhanced rate and serum albumin level ($r = 0.57$, $P < 0.0001$), and fibrosis level ($r = -0.48$, $P < 0.0001$). The EOB-MRI-enhanced rate also weakly correlated with platelet count ($r = 0.28$, $P = 0.0005$), AST level ($r = -0.37$, $P < 0.0001$), total bilirubin level ($r = -0.26$, $P = 0.0014$), and prothrombin activity ($r = 0.27$, $P = 0.0014$) (Table 2, Fig. 2).

Fig. 3 exhibits the receiver operating characteristic curve for predicting liver cirrhosis (F4). The cutoff value of EOB-MRI-enhanced rate was 2.270 with a sensitivity of 0.766 and specificity of 0.678 (Fig. 3).

Discussion

EOB-MRI is useful in detecting early and small HCCs that cannot be detected with enhanced CT or

Table 2 Correlation coefficients between liver function tests and the EOB-MRI-enhanced rate

Variables	Correlation coefficient (r)	P value
Albumin level (g/dL)	0.57	<0.0001
Prothrombin activity (%)	0.27	0.0014
Total bilirubin level (m/dL)	-0.26	0.0014
AST level (IU/L)	-0.37	<0.0001
ALT level (IU/L)	-0.18	0.03
Platelet count (×104/μL)	0.28	0.0005
ICGR 15 (%)	-0.66	<0.0001
Liver fibrosis level ^a	-0.48	<0.0001

^aLiver fibrosis levels were categorized according to METAVIR classification.

enhanced ultrasound.^{9,10} Additionally, one study reported that EOB-MRI could be used for tumor differentiation.¹¹ The hepatobiliary phase of EOB-MRI correlated with hepatic functional reserve, as reported in some studies. Most studies that showed a correlation between EOB-MRI and hepatic functional reserve reported that the ratio of precontrast signal intensity to hepatobiliary-phase signal intensity in the liver parenchyma correlated with the hepatic functional reserve.¹²⁻¹⁵ The degree of irregularity of the liver parenchyma in the hepatobiliary phase correlated with hepatic functional reserve as reported in other studies.^{16,17} In addition, many other studies have reported that the quantity of blood flow,¹⁸ the degree of hepatorenal contrast,¹⁹ the ratio of the spinal cord to the liver parenchyma signal intensity,²⁰ the ratio of the bile duct to liver parenchyma signal intensity,²¹ and the ratio of the spleen to liver parenchyma signal intensity^{22,23} correlated with hepatic functional reserve. This study showed that the ratio of paraspinal muscle to the liver parenchyma signal intensity correlated with hepatic functional reserve. One study reported that the ratio of the spleen to the liver parenchyma signal intensity correlated better with hepatic functional reserve than the ratio of the psoas muscle to the liver parenchyma signal intensity.²³ However, the value of the correlation coefficient between the EOB-MRI-enhanced rate and ICGR 15 found in our study ($r = -0.66$, $P < 0.0001$) was stronger than the correlation between the ratio of the spleen to the liver parenchyma signal intensity and the parameters of technetium-99m galactosyl serum albumin (99mTc-GSA) scintigraphy ($r = 0.593$, $P < 0.001$).²³

Of interest, some studies reported that the hepatobiliary phase of EOB-MRI could evaluate regional hepatic function reserve.^{24,25} We also evaluated regional hepatic function reserve by using

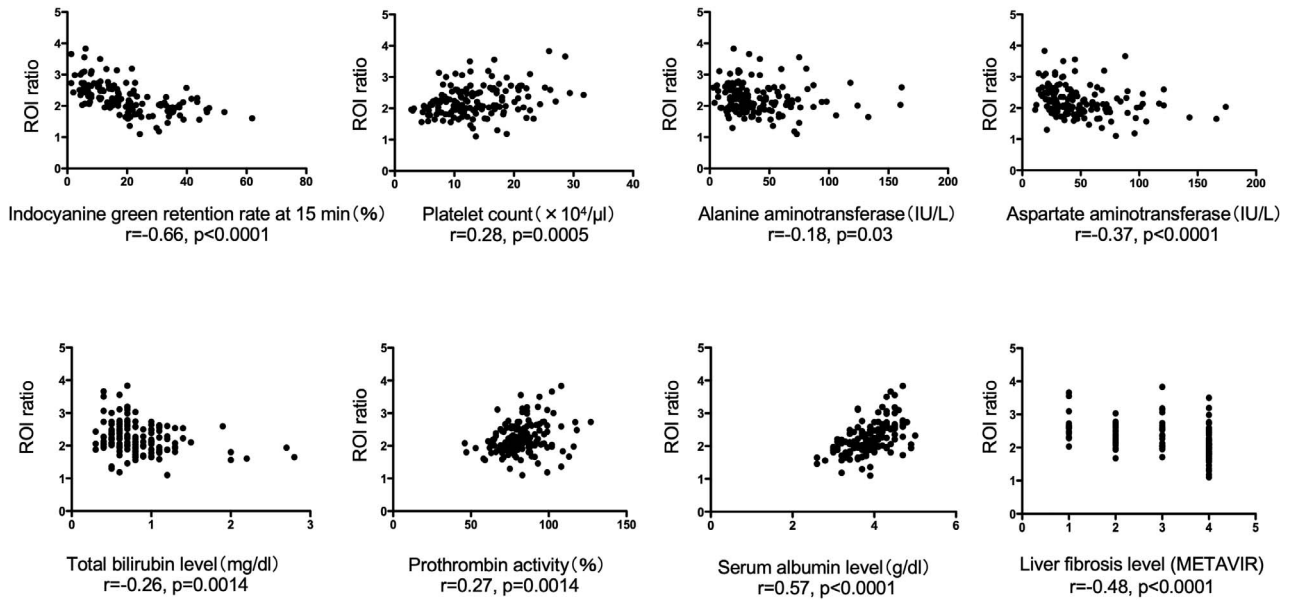


Fig. 2 Correlation between EOB-MRI-enhanced rate and parameters of hepatic functional reserve. A high correlation was found between EOB-MRI-enhanced rate and ICGR 15. A moderate correlation was discovered between EOB-MRI-enhanced rate and serum albumin level and fibrosis level. A weak correlation was found between EOB-MRI-enhanced rate and platelet count, AST level, total bilirubin level, and prothrombin activity.

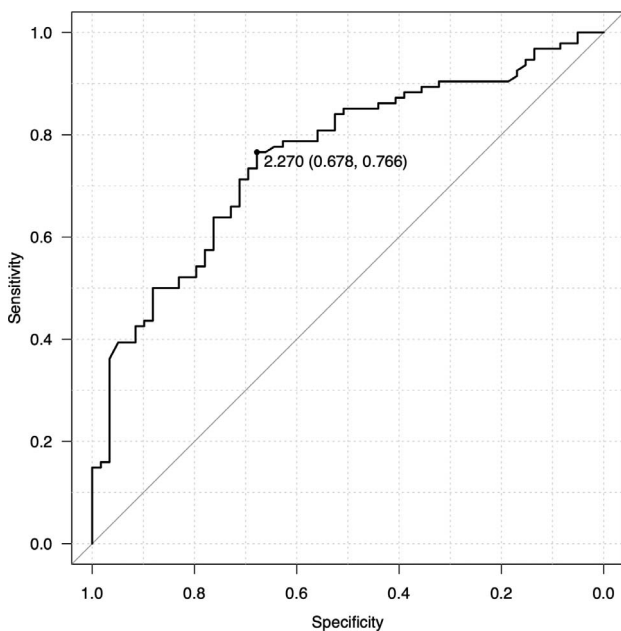


Fig. 3 Receiver operating characteristic curve for predicting liver cirrhosis (F4). The area under the curve was 0.758, and the 95% confidence interval was 0.682 to 0.835. Thus, the cutoff value of the EOB-MRI-enhanced rate was 2.270 with a sensitivity of 0.766 and specificity of 0.678.

percutaneous transhepatic portal vein embolization cases. The ratio of the signal intensity of the hepatobiliary phase of EOB-MRI in the right lobe to that of the left lobe was similar to the ratio of uptake of $^{99\text{m}}\text{Tc}$ -GSA scintigraphy in the right lobe to that of the left lobe (data not shown).

To date, $^{99\text{m}}\text{Tc}$ -GSA scintigraphy using X-ray images is the only modality that can evaluate hepatic functional reserve. However, this modality cannot detect tumors and determine tumor size, number, and location. This study showed that the hepatic functional reserve could be evaluated in the hepatobiliary phase of EOB-MRI. This finding suggests that tumor location, tumor number, and hepatic functional reserve can be analyzed using EOB-MRI. This is useful for decreasing the number of examinations in patients and medical expenses.

Other methods for analyzing hepatic functional reserve include liver biopsy and elastography.²⁶ However, a liver biopsy is invasive and usually requires hospitalization. Alternatively, percutaneous elastography is noninvasive, but its accuracy depends on the thickness of the subcutaneous fat and the amount of visceral fat. The evaluation of hepatic functional reserve using EOB-MRI is noninvasive and is not affected by subcutaneous

fat or visceral fat. Also, as there is no radiation exposure, future promotion of the research development is expected.

The limitation of this study is that it is a retrospective, single-center study. Therefore, these findings need to be confirmed using multicenter prospective studies. Among the various published studies on evaluating hepatic functional reserve using EOB-MRI, this paper is the first to use the ratio of the SIPM and the liver parenchyma. Subsequently, it will be necessary to compare the accuracy of our procedure with that of other procedures for evaluating hepatic functional reserve using EOB-MRI. In addition, it is crucial to assess the correlations between EOB-MRI and clinical significance, such as postoperative liver failure.

In conclusion, the EOB-MRI-enhanced rate during the hepatobiliary phase strongly correlates with hepatic functional reserve, suggesting its feasibility as a new supporting parameter for evaluating hepatic functional reserve.

Acknowledgments

All procedures followed were according to the ethical standards of the committee responsible for human experimentation (institutional and national) and with the Helsinki Declaration of 1975, as revised in 2008. Informed consent was obtained from all patients for being included in the study, and the institutional review board approved the study in our hospital (Receipt Number 27-15).

References

- Schuhmann-Giampieri G, Schmitt-Willich H, Press WR, Negishi C, Weinmann HJ, Speck U. Preclinical evaluation of Gd-EOB-DTPA as a contrast agent in MR imaging of the hepatobiliary system. *Radiology* 1992;**183**(1):59–64
- Earls JP, Bluemke DA. New MR imaging contrast agents. *Magn Reson Imaging Clin N Am* 1999;**7**(2):255–273
- Bae KE, Kim SY, Lee SS, Kim KW, Won HJ, Shin YM *et al*. Assessment of hepatic function with Gd-EOB-DTPA-enhanced hepatic MRI. *Dig Dis* 2012;**30**(6):617–622
- Leonhardt M, Keiser M, Oswald S, Kuhn J, Jia J, Grube M *et al*. Hepatic uptake of the magnetic resonance imaging contrast agent Gd-EOB-DTPA: role of human organic anion transporters. *Drug Metab Dispos* 2010;**38**(7):1024–1028
- Kitao A, Zen Y, Matsui O, Gabata T, Kobayashi S, Koda W *et al*. Hepatocellular carcinoma: signal intensity at gadoxetic acid-enhanced MR Imaging—correlation with molecular transporters and histopathologic features. *Radiology* 2010;**256**(3):817–826
- Cui Y, Konig J, Leier I, Buchholz U, Keppler D. Hepatic uptake of bilirubin and its conjugates by the human organic anion transporter SLC21A6. *J Biol Chem* 2001;**276**(13):9626–9630
- de Graaf W, Hausler S, Heger M, van Ginhoven TM, van Cappellen G, Bennink RJ *et al*. Transporters involved in the hepatic uptake of (99m)Tc-mebrofenin and indocyanine green. *J Hepatol* 2011;**54**(4):738–745
- Bedossa P, Poynard T. An algorithm for the grading of activity in chronic hepatitis C. The METAVIR Cooperative Study Group. *Hepatology* 1996;**24**(2):289–293
- Alaboudy A, Inoue T, Hatanaka K, Chung H, Hyodo T, Kumano S *et al*. Usefulness of combination of imaging modalities in the diagnosis of hepatocellular carcinoma using Sonazoid(R)-enhanced ultrasound, gadolinium diethylenetriamine-pentaacetic acid-enhanced magnetic resonance imaging, and contrast-enhanced computed tomography. *Oncology* 2011;**81** (suppl 1):66–72
- Van Beers BE, Pastor CM, Hussain HK. Primovist, Eovist: what to expect? *J Hepatol* 2012;**57**(2):421–429
- Kogita S, Imai Y, Okada M, Kim T, Onishi H, Takamura M *et al*. Gd-EOB-DTPA-enhanced magnetic resonance images of hepatocellular carcinoma: correlation with histological grading and portal blood flow. *Eur Radiol* 2010;**20**(10):2405–2413
- Katsube T, Okada M, Kumano S, Hori M, Imaoka I, Ishii K *et al*. Estimation of liver function using T1 mapping on Gd-EOB-DTPA-enhanced magnetic resonance imaging. *Invest Radiol* 2011;**46**(4):277–283
- Katsube T, Okada M, Kumano S, Imaoka I, Kagawa Y, Hori M *et al*. Estimation of liver function using T2* mapping on gadolinium ethoxybenzyl diethylenetriamine pentaacetic acid enhanced magnetic resonance imaging. *Eur J Radiol* 2012;**81**(7):1460–1464
- Kim HY, Choi JY, Park CH, Song MJ, Song DS, Kim CW *et al*. Clinical factors predictive of insufficient liver enhancement on the hepatocyte-phase of Gd-EOB-DTPA-enhanced magnetic resonance imaging in patients with liver cirrhosis. *J Gastroenterol* 2013;**48**(10):1180–1187
- Kubota K, Tamura T, Aoyama N, Nogami M, Hamada N, Nishioka A *et al*. Correlation of liver parenchymal gadolinium-ethoxybenzyl diethylenetriaminepentaacetic acid enhancement and liver function in humans with hepatocellular carcinoma. *Oncol Lett* 2012;**3**(5):990–994
- Nilsson H, Blomqvist L, Douglas L, Nordell A, Janczewska I, Naslund E *et al*. Gd-EOB-DTPA-enhanced MRI for the assessment of liver function and volume in liver cirrhosis. *Br J Radiol* 2013;**86**(1026):20120653
- Kim T, Murakami T, Hasuike Y, Gotoh M, Kato N, Takahashi M *et al*. Experimental hepatic dysfunction: evaluation by MRI with Gd-EOB-DTPA. *J Magn Reson Imaging* 1997;**7**(4):683–688
- Chen BB, Hsu CY, Yu CW, Wei SY, Kao JH, Lee HS *et al*. Dynamic contrast-enhanced magnetic resonance imaging with

- Gd-EOB-DTPA for the evaluation of liver fibrosis in chronic hepatitis patients. *Eur Radiol* 2012;**22**(1):171–180
19. Clement O, Muhler A, Vexler V, Berthezene Y, Brasch RC. Gadolinium-ethoxybenzyl-DTPA, a new liver-specific magnetic resonance contrast agent. Kinetic and enhancement patterns in normal and cholestatic rats. *Invest Radiol* 1992; **27**(8):612–619
 20. Kumazawa K, Edamoto Y, Yanase M, Nakayama T. Liver analysis using gadolinium-ethoxybenzyl-diethylenetriamine pentaacetic acid-enhanced magnetic resonance imaging: correlation with histological grading and quantitative liver evaluation prior to hepatectomy. *Hepatol Res* 2012;**42**(11): 1081–1088
 21. Okada M, Ishii K, Numata K, Hyodo T, Kumano S, Kitano M *et al.* Can the biliary enhancement of Gd-EOB-DTPA predict the degree of liver function? *Hepatobiliary Pancreat Dis Int* 2012; **11**(3):307–313
 22. Motosugi U, Ichikawa T, Sou H, Sano K, Tominaga L, Kitamura T *et al.* Liver parenchymal enhancement of hepatocyte-phase images in Gd-EOB-DTPA-enhanced MR imaging: which biological markers of the liver function affect the enhancement? *J Magn Reson Imaging* 2009;**30**(5):1042–1046
 23. Nishie A, Ushijima Y, Tajima T, Asayama Y, Ishigami K, Kakahara D *et al.* Quantitative analysis of liver function using superparamagnetic iron oxide- and Gd-EOB-DTPA-enhanced MRI: comparison with Technetium-99m galactosyl serum albumin scintigraphy. *Eur J Radiol* 2012;**81**(6):1100–1104
 24. Shimizu J, Dono K, Gotoh M, Hasuike Y, Kim T, Murakami T *et al.* Evaluation of regional liver function by gadolinium-EOB-DTPA-enhanced MR imaging. *Dig Dis Sci* 1999;**44**(7):1330–1337
 25. Utsunomiya T, Shimada M, Hanaoka J, Kanamoto M, Ikemoto T, Morine Y *et al.* Possible utility of MRI using Gd-EOB-DTPA for estimating liver functional reserve. *J Gastroenterol* 2012; **47**(4):470–476
 26. Sandrin L, Fourquet B, Hasquenoph JM, Yon S, Fournier C, Mal F *et al.* Transient elastography: a new noninvasive method for assessment of hepatic fibrosis. *Ultrasound Med Biol* 2003; **29**(12):1705–1713