



Case Report

Alveolar Echinococcosis of the Liver With Initially Suspected Intrahepatic Cholangiocarcinoma: Case Report—The Significance of Preoperative Serological Diagnostics

Miloš Milošević^{1,2}, Katarina Šarčev³, Mirjana Živojinov^{2,4}, Zoran Milošević^{2,3}, Dušan Lalošević², Slobodan Torbica^{2,5}, Maja Ružić^{2,6}

¹*Institute for Oncology of Vojvodina, Clinic for Surgical Oncology, Sremska Kamenica, Vojvodina, Serbia*

²*Medical University of Novi Sad, Vojvodina, Serbia*

³*University Clinical Centre of Vojvodina, Clinic for Abdominal and Endocrine Surgery, Novi Sad, Vojvodina, Serbia*

⁴*University Clinical Centre of Vojvodina, Centre for Pathology and Histology, Novi Sad, Vojvodina, Serbia*

⁵*University Clinical Centre of Vojvodina, Centre for Radiology, Novi Sad, Vojvodina, Serbia*

⁶*University Clinical Centre of Vojvodina, Clinic for Infectious Diseases, Novi Sad, Vojvodina, Serbia*

Introduction: Cysts of the liver pose a significant differential diagnostic problem, considering that the etiology of which can be various. Until recently, alveolar echinococcosis (AE) of the liver in a differential diagnostic analysis of cystic liver lesions with a solid component had little significance in the Vojvodina region. The Syrmia area of Vojvodina is an endemic zone of multilocular echinococcus among wildlife, and the first case of human AE was documented in April 2023. To denote the significance of preoperative serological AE diagnostics, we present a case of AE of the liver initially suspected to be cholangiocarcinoma.

Corresponding author: Miloš Milošević, MD, FICS, Institute for Oncology of Vojvodina, Clinic for Surgical Oncology, Sremska Kamenica, Vojvodina, Serbia.

Tel: +38 164 205 1748; E-mail: 1395d20@mf.uns.ac.rs or hepatobiliar95@gmail.com; <https://orcid.org/0009-0004-7554-7884>

Case report: A patient from the Syrmia area of Vojvodina reports in November 2023, after the appearance of icterus and epigastric pain. Laboratory results display slightly increased proinflammatory markers, and hepatogram results indicate cholestasis with reactive hepatitis. Magnetic resonance imaging (MRI) of the abdomen indicates a focal lesion in the S5/S8 segment of the liver of primarily infiltrative MRI characteristics, which may indicate cholangiocarcinoma. Total body computed tomography scan excludes other lesions. The patient has undergone extended right hepatectomy and the pathohistological results proved the presence of multilocular echinococcus.

Conclusion: Despite epidemiological risks, diagnosis of infiltrative cystic focal lesions of the liver does not include testing for echinococcus. The reported case indicates the necessity of testing all focal lesions of the liver for AE. The awareness of the epidemiological situation in the region where the patient resides must be raised in order to add serological testing of focal lesions of the liver for multilocular echinococcus to guidelines.

Key words: Hydatid disease – *Echinococcus multilocularis* – liver resection – cholangiocarcinoma

Cystic lesions of the liver are, etiologically speaking, a heterogeneous group of diseases with a wide range of clinical presentations and prognoses. The most common are the benign liver cysts, mostly located in the right lobe, and are mostly asymptomatic excluding complications in the form of spontaneous hemorrhage, infection, and rupture in the peritoneal cavity, blood vessels, or biliary ducts, as well as compression of biliary ducts.¹ They are most similar in terms of differential diagnosis as well as clinical progression to echinococcus cysts of the liver, caused by the larvae of *Echinococcus granulosus*.^{1,2} Depending of the avidity of the parasite, this form of cyst requires the application of albendazole in therapy, whereas the treatment of complications is nearly identical to that in the case of simple cysts.²

The greatest differential diagnostic problem is the cystic formations with a dominant or less-prominent solid component—starting with hemangioma, hepatocellular carcinoma, cholangiocellular carcinoma, non-invasive or invasive mucinous cystic neoplasm, metastasis of various primary tumor localizations, and sarcoma. Therapy options of the mentioned forms of focal lesions of the liver are diametrically different: from the application of radiological procedures, surgery, to the application of chemotherapeutic drugs. Taking into consideration the aggressive direction of malignant focal lesions, as well as the tendency toward complications (obstructive icterus, forming of abscess, Budd-Chiari syndrome) in the case of resectable changes, the general approach is surgical resection without prior etiological elaboration.³

Until recently, alveolar echinococcosis (AE) liver disease in a differential diagnostic analysis of cystic

liver lesions with a solid component had little significance in the Vojvodina region of Serbia. According to the research of Lalošević *et al*,⁴ the Syrmia area of Vojvodina is the endemic zone of multilocular echinococcus among jackals and foxes, and the first case of human AE was documented in April 2023.

Case Report

A man, aged 57 years, resident of the northwestern Syrmia region of Vojvodina, reports in for an examination in late November 2023 on the third day after the appearance of icterus followed by epigastric pain, which is spreading across the waist region. Laboratory analysis results display slightly increased proinflammatory markers (C-reactive protein 38/<5), and hepatogram results indicate cholestatic syndrome with reactive hepatitis. Abdominal ultrasound in the right lobe of the liver indicated a hyperechogenic lesion with dimensions of 5.8 × 5 cm, and the abdominal computed tomography (CT) scan in the S5/S8 liver segment indicated an unclearly demarked, irregularly shaped focal alteration, mostly hypodense, with segmentally dilated bile ducts, which, according to radiological characteristics, had the markings of an abscess (Figs. 1 and 2). Magnetic resonance imaging (MRI) of the abdomen indicated focal presence in the S5/S8 segment of the liver, dimensions of approximately 6.8 × 6 × 7.3 cm, with a heterogeneous appearance with necrosis zones and perilesional dilatation of intrahepatic bile ducts of primarily infiltrative MRI characteristics; differential diagnosis may indicate mass-forming cholangiocarcinoma (Fig. 3). In the region of the common bile duct there was suspected infiltration of the cystic duct, with the walls of the previously mentioned structures becoming thicker, which

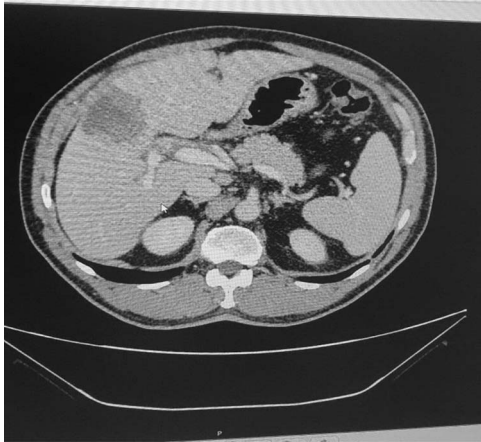

Fig. 1 Abdominal CT scan (venous phase) with tumorous alteration of S5/S8 liver segments and infiltration of the anterior branch of the right portal vein.

according to MRI characteristics could match cholangiocarcinoma. Furthermore, the anterior branch of the right portal vein and median hepatic vein appear to be infiltrated. Intrahepatic bile ducts for both lobes were initially enlarged, and in the hilus of the liver there were enlarged lymph nodes.

Tumor markers (carcinoembryonic antigen [CEA], Ca 19–9, alpha-fetoprotein [AFP], Ca 15–5, Ca 125) were within normal limits. Total body CT scan excluded the existence of other localizations of tumor infiltrate, apart from the noticed lesions of the liver.

Considering the presence of obstructive icterus, a percutaneous biliary drainage was performed on the patient by the interventional radiologist, followed by

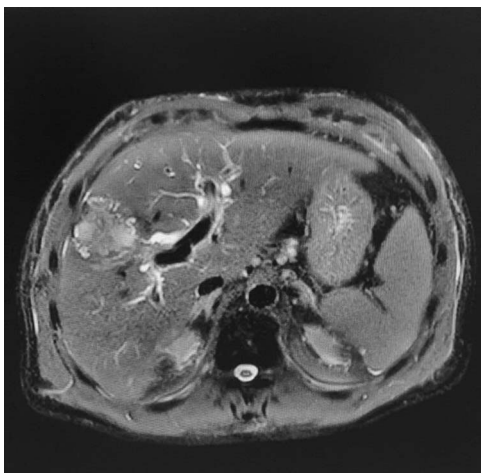


Fig. 2 MRI of the abdomen with tumorous alteration of S5/S8 liver segments and infiltration of the anterior branch of the right portal vein.

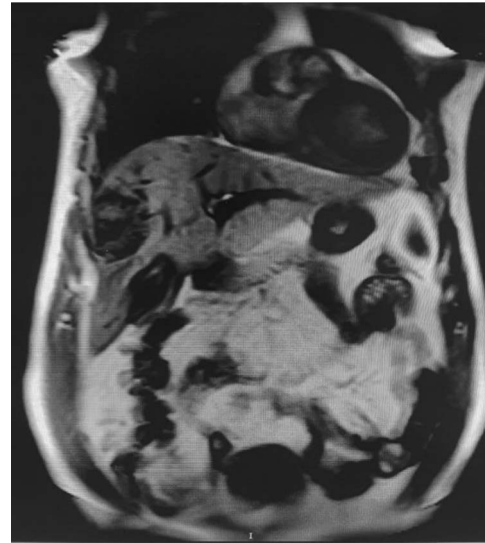


Fig. 3 MRI of the abdomen with tumorous alteration of S5/S8 liver segments and infiltration of the anterior branch of the right portal vein.

the control CT scan of the abdomen where the state of the previously described infiltrative lesions of the right liver lobe were noted to have remained unchanged.

The tumorous lesions are intraoperatively identified on the S5 and partially on the S8 segment of the liver, with macroscopic infiltratory characteristics compared with the surrounding liver parenchyma. After a generous mobilization of the right liver lobe, 2 biopsies of the tumorous lesions were taken and sent to “ex tempore” pathohistological (PH) analysis. The pathologist confirmed the benign status of both lesions. Next was the preparation of the hepatoduodenal (HD) ligament, followed by identification of the tumor that was the cause of the biliary obstruction. A biopsy was performed on the tumor in the aforementioned region and sent to “ex tempore” PH analysis. The pathologist confirmed the benign status of this lesion as well. Next, an inoperative cholangiography was performed, which confirmed a regular arborization of the intrahepatic ducts of the left liver lobe with insufficient arborization of the right lobe due to massive tumorous lesion compressing the intrahepatic ducts (Fig. 4).

Taking into consideration the intraoperative status, a transection was performed on the right hepatic artery, right portal vein, and right and middle hepatic vein, as well as the transection of the common bile duct with the tumorous infiltration. Part of the common bile duct encapsulated by the tumor was sent to an “ex tempore” PH analysis. The pathologist once

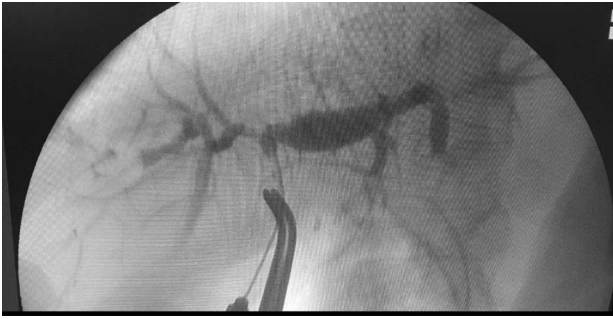

Fig. 4 Intraoperative cholangiography displays tumorous infiltration of biliary confluence.

again confirmed the benign status of the tumorous lesion. The surgical procedure was concluded by separating the right lobe of the liver from the inferior vena cava accompanied by detailed hemostasis control, followed by an extended right hepatectomy (SIV-SVIII) and a biliodigestive reconstruction (hepatic-jejunostomy). The liver with the tumor sample was cut and a macroscopic cross section was visualized (Fig. 5).

The postoperative period was relatively regular, with expected perioperative complications that were successfully treated. Clinical and laboratory analysis showed no indication of end-stage liver disease development, which was to be expected considering

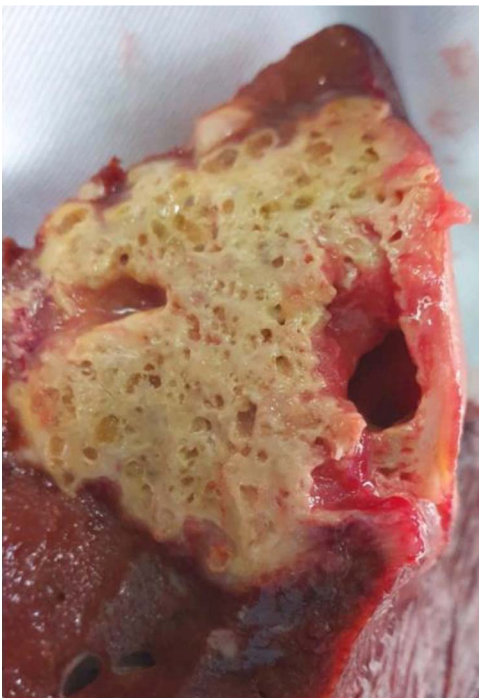

Fig. 5 Cross section of macroscopic liver sample showing the tumor.

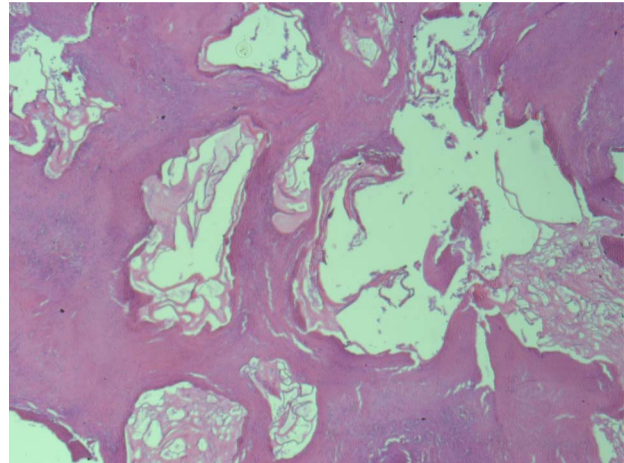


Fig. 6 Microscopic liver sample with chitin membranes.

the extensiveness of the surgical procedure. Twenty-one days after surgery, the patient was dismissed and sent to home treatment. The patient was afebrile, in a stable general state, with regular hepatogram laboratory results.

The definitive PH result of the operative material (2 liver samples, lymph node in the HD ligament region and part of the ductus choledochus) confirmed a multilocular echinococcus disease, with accompanying “metastasis” in the lymph node of the HD ligament, as well as signs of perineural expansion (Figs. 6 and 7).

Albendazole was included in therapy with a dose of 400 mg 2×1 ; however, in the second month of therapy there was an increase in aminotransferase activity over $5 \times$ compared with normal values, as well as a progressive development of sensory polyneuropathy on the lower extremities. This was verified via EMG

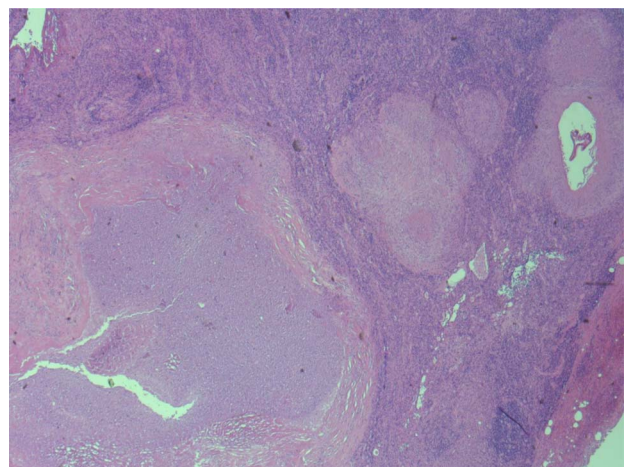


Fig. 7 Microscopic sample of a lymph node from the HD ligament with pseudometastasis.

(electromyography) examination, and it needed to be excluded due to unwanted side effects.

Discussion

Human AE is a zoonosis caused by the metacestode of the fox tapeworm (*Echinococcus multilocularis*). The human is an intermediary host, and the transmission occurs by accidentally ingesting the parasite's eggs after direct contact with the definitive host (animal – fox, jackal) or by indirectly contaminated food or water. AE is the most common pathogenic zoonosis of the northern hemisphere.⁵ Endemic regions such as Austria, Switzerland, France, and Germany have clear policies of epidemiological surveillance in definitive host populations, taking into consideration the acquired historical experience of its consequences in the human population. In 2016, the first cases of multilocular echinococcus were discovered among the foxes and jackals in the Vojvodina region, and afterward in Slovenia, Croatia, and Bosnia and Herzegovina.^{6,7} Shifting of the endemic zone southward, toward the Mediterranean, is one of the major areas of research regarding the effect of climate change on zoonosis. This begs the question why this disease from traditionally cold and humid areas of northern Europe has shifted into the warmer and dryer climate zones of the Mediterranean. There is also evidence that suggests that the expansion of AE in the fox population is the consequence of a successful campaign of rabies eradication and the colonization of urban environments as a paradigm of the increase in prevalence in the human population.⁴ However, the information on infected foxes and jackals in the “new” endemic zones remains “conclusive” among the professional public. Despite “One Health” activity, the awareness of the impending spread of this zoonosis to the human population has not reached clinical medicine.⁶ Traditionally, in the Vojvodina region, echinococcus was considered to be a cystic liver disease.⁴ The professional public has been sensitized and the diagnostic algorithm for cystic liver disease makes it mandatory to determine the titer of antibodies for *Echinococcus granulosus*. According to epidemiological data of the Institute for Public Health of Vojvodina, there have been 118 recorded cases in the past 42 years. However, the diagnosis of infiltrative cystic focal lesions of the liver with a solid component does not include testing for echinococcus disease, despite the listed epidemiological risks.

In the case of this patient, based on CT and MRI, there was almost a conclusive preoperative diagnosis of malignant liver disease, which was in accordance

with the slow progression of the disease. However, AE is a disease with a slow progression, and is completely asymptomatic in the first 5 to 15 years. In 33% of patients, the focal lesions of the liver are determined accidentally, via an ultrasound examination of the abdomen. Symptoms of AE appear in the disease's advance stage and are unspecific: fatigue, loss of body weight, and pain under the right costal margin. According to a study by Iranian authors,² the most common symptom is a pain in the epigastrium, present in 88% of patients. The laboratory results are highly unspecific, where, according to a study, it is possible to detect hypergammaglobulinemia in 50% of patients, dominantly based on increased immunoglobulin E antibodies, whereas eosinophilia is usually absent (Eckert World Health Organization [WHO]). Radiologists have an essential role in the early establishment of a diagnosis and follow-up monitoring after the extraction surgery or chemotherapy. However, the radiological analysis of focal liver lesions with irregular edges, a central necrosis, irregular intraluminal calcification, and calcification on the edge of the alteration is often variable and can lead to confusion and direct diagnostics and therapy in completely opposite directions. Guidelines of the World Health Organization Consensus list 4 diagnostic devices for diagnosing AE.⁸ However, the definitive diagnosis confirmation requires several criteria⁹: (1) presence of positive serology (detection of EM2 and EM2+), (2) localization of lesion and radiological characteristics, (3) accompanying histopathological characteristics, and (4) presence of nucleic acid of *E. multilocularis* discovered via polymerase of chain reaction (PCR) in the clinical sample. Therefore, according to the consensus protocol, the diagnostic biopsy of the lesion before surgery or in the case of inoperable alterations is not necessary (2 of 4 criteria required), but it is necessary to perform serological or PCR testing.

The patient's clinical status had a dominant sudden cholestasis syndrome. The ultrasound image and CT scan of the liver were inconsistent and indicated an abscess of the liver. As the patient was not febrile, with a slight increase of proinflammatory parameters, the clinical picture required additional diagnostics. The radiological MRI of the liver added to the confusion, which indubitably indicated mass-forming cholangiocarcinoma with the common bile duct encompassed (Klatskin-type tumor). The prevalence of the invasion of bile ducts in AE was reported to be approximately 11%¹⁰ and apart from cholestasis, can result in cholangitis and biliary sepsis. To supplement diagnostics as well as therapy in those situations it is necessary to perform endoscopic

retrograde cholangiopancreatography (ERCP and stent) or percutaneous transhepatic biliary drainage.¹¹ According to current guides for treating cholangiocellular carcinoma with Klatskin-type tumors, additional preoperative diagnostics to determine pathohistological conclusion of etiology is not necessary, and considering the estimated resectability of the lesion in patients, neither is biopsy necessary.

It should be noted that there is some controversy among the professional public regarding the safety of lesion biopsy.^{11–13} There is a theoretical risk of anaphylaxis and dissemination; however, retrospective studies have not come to that conclusion.^{14,15} The surgical approach on the reported patient, in the case that additional preoperative serological diagnosis that would indicate AE existed, would not significantly deviate from the surgical approach for malignant liver tumor. In the ideal case, AE therapy is surgical resection.¹⁴ Infected tissue needs to be removed in its entirety, with a minimal resection margin of 2 cm.⁸ The possibility of radical resection depends on the location of the lesion, presence of metastasis, comorbidity of the patient, and available surgical expertise. The patient has undergone a major and complex surgical procedure—extended right hepatectomy. The intraoperative, “ex tempore,” pathology results indicate a benign lesion, although without possibility of expanding on the nature of the lesion at the moment. The AE cyst grows by externally budding through the germinal membrane with progressive infiltration of the surrounding tissue, and this characteristic differentiates it from the self-limiting growth of EG. AE lesions have alveolar structures made of numerous irregularly shaped cysts with diameters ranging from 1 to 20 mm and are not harshly limited by surrounding tissue. Central cystic cavities may appear due to necrosis and are filled with fluid. In most cases, a thick and partially calcified wall is present. Histomorphological diagnosis of echinococcus is significantly easier if the chitin membranes are discovered. The presence of a protoscolex or at the very least chitin hooks support the theory of hydatid echinococcosis, considering that AE does not produce protoscolex in the human liver. Therefore, the absence of protoscolex in the PH sample could be considered a significant morphological diagnostic criterion in AE diagnosis.⁴

A pathohistological examination of the sample, which coincided with the previously mentioned alterations, could result in an AE diagnosis with a high likelihood. However, it is only possible to get a definitive confirmation of AE with an immunohistochemical

dye test for Em2G11 protein, or genetic testing of the sample using PCR method for the presence of *E multilocularis* DNA.^{16,17}

The mentioned method of immunohistochemical diagnostics was unavailable to us at the time. Apart from surgery, to reduce the likelihood or relapse, even in cases of complete surgical resection, a minimum 2-year treatment using anthelmintics is indicated and adjuvated (WHO [UTD 15]). Considering that mebendazole is a parasitostatic, the use of albendazole is preferred, in 10 to 15 mg/kg of body weight, separated into 2 doses [UTD 44]. The patient had his infected liver tissue fully removed, although considering the perineural expansion and encompassing of the regional lymph node, the guideline includes albendazole therapy. In the second month, there was a distinct hepatotoxic effect and progressive development of polyneuropathy in the lower extremities, verified using an EMG examination, which could be attributed to the toxic effect of albendazole. AE encompassing the lymph node is common; however, according to a study by German authors, it does not correlate with the degree and risk of disease dissemination.¹⁸ Positron emission tomography (PET) scan results could help in evaluating the presence of metabolically active focuses of AE and establishing indication for the application for some of the alternative regimen of antiparasitic medication (mebendazole, praziquantel, nitazoxanide, and amphotericin), even though their inferior efficacy compared with albendazole is known.⁴

The effect of neoadjuvant AE treatment regimen in the prevention of relapse or dissemination after the surgical procedure is insufficiently documented. Although WHO provides guidelines for introducing albendazole before surgical resection, there is no consensus on the period; however, most studies state a lower rate of relapse when it is applied.¹⁹ These data still apostrophize the necessity of establishing AE diagnosis before surgery. This is especially true in cases of expansive infiltration and risk of appearance of “small for size” syndrome. In that case, the only solution for the patient would be a liver transplant (LT).

The awareness of the epidemiological situation in the region where the patient resides must be raised among the professional public, to add serological testing of focal lesions of the liver for multilocular echinococcus to guidelines for good clinical practice.

According to SZO recommendation, LT could be considered in the case of AE in the following situations: (1) if there is severe liver insufficiency or recurrent life-threatening cholangitis, or

(2) if radical liver resection cannot be performed and there is absence of extrahepatic disease.⁸ Furthermore, it is necessary for the patient to be tolerant toward benzimidazole class drug therapy.

Taking into account the side effects of albendazole therapy, LT in the case of the reported patient would be debatable to say the least. LT should be reserved for special, select cases and should only be used as therapy to save the patient's life.¹⁹

The reported rates of relapse after curative resection were between 2% and 16% within 5 to 20 years. AE relapse usually appears at the point of resection, and it is exceptionally rare for new intrahepatic lesions or lesions in the hepatoduodenal ligament region to form.²⁰ The estimated parasite activity is key to the evaluation of potential treatment, as well as for the purposes of monitoring the efficacy of the antiparasitic treatment.²⁰

The reported patient had, at the moment of diagnosis, already been in an advanced stage of the disease. AE has a natural progression of malignant infiltrative lesion with the ability to perivascularly and perineurally disseminate into regional lymph nodes and form remote "metastatic" lesions, and WHO proposed the PMN classification of AE.²¹ Additional CT diagnostics (total body scan) excluded the existence of potential secondary AE foci. In the case of recessive intrahepatic focus, the patient could be monitored using MRI, where AE activity in the lesions would be estimated by visualizing microcysts (Kodama classification 1, 2, and 3), but there are no data regarding the connection between Kodama classification and prognosis.⁶ However, the most precise method for excluding secondary dissemination and the presence of extrahepatic loci is a PET scan examination, taking into consideration the accumulation of fludeoxyglucose F18 (FDG) in metabolically active AE zones. On the other hand, PET scan is an excellent tool for estimating the success of albendazole therapy, considering that the zone cured of AE displays a lower degree of FDG accumulation compared with normal tissue. This method of diagnostics is particularly significant in determining the duration of treatment of patients with resected AE.²²

Conclusion

Ever since 2016, when the first cases of AE were documented among foxes and jackals in the Vojvodina region, it became clear that the region had become a "new" endemic zone for AE. Despite "One Health" activity, the awareness of the impending spread of this zoonosis to the human population has not

reached clinical medicine. Despite the listed epidemiological risks, diagnosis of infiltrative cystic focal lesions of the liver with solid component does not include testing for echinococcus disease in everyday medical practice. The reported case confirms the current state and indicates the necessity of testing all focal lesions of the liver for AE. The awareness of the epidemiological situation in the region where the patient resides must be raised among the professional public, in order to add serological testing of focal lesions of the liver for multilocular echinococcus to guidelines for good clinical practice.

References

1. Djolai M, Torbica S, Stojanovic S, Rajkovic M, Moljevic N, Petrovic P *et al*. Mucinous cystadenoma of the liver with pathological-radiological correlation. *Ann Diagn Pathol* 2022;**59**: 151977
2. Chouhan MD, Wiley E, Chiodini PL, Amin Z. Hepatic alveolar hydatid disease (*Echinococcus multilocularis*), a mimic of liver malignancy: a review for the radiologist in non-endemic areas. *Clin Radiol* 2019;**74**(4):247–256
3. Zhou J, Sun H, Wang Z, Cong W, Zeng M, Zhou W. Guidelines for the diagnosis and treatment of primary liver cancer (2022 edition). *Liver Cancer* 2023;**12**(5):405–444
4. Lalošević D, Živojinov M, Isaković V, Ivanov D, Trifunović V, Ružić M. The first case of multilocular echinococcosis in Serbia. *Srp Arh Celok Lek* 2023 | Online First May 30, 2023 | DOI: <https://doi.org/10.2298/SARH230112060L>
5. Deplazes P, Rinaldi L, Alvarez Rojas CA, Torgerson PR, Harandi MF, Romig T *et al*. Global distribution of alveolar and cystic echinococcosis. *Adv Parasitol* 2017;**95**:315–493
6. Omeragić J, Goletić T, Softić A, Goletić Š, Kapo N, Soldo DK *et al*. First detection of *Echinococcus multilocularis* in Bosnia and Herzegovina. *Int J Parasitol Parasites Wildl* 2022;**19**:269–272
7. Balen Topić M, Papić N, Višković K, Sviben M, Filipec Kanižaj T, Jadrijević S *et al*. Emergence of *Echinococcus multilocularis* in central continental Croatia: a human case series and update on prevalence in foxes. *Life* 2023;**13**(6):1402
8. Brunetti E, Kern P, Vuitton DA; Writing Panel for the WHO-IWGE. Expert consensus for the diagnosis and treatment of cystic and alveolar echinococcosis in humans. *Acta Trop* 2010;**114**(1):1–16
9. Santoro A, Santolamazza F, Cacciò SM, La Rosa G, Antolová D, Auer H *et al*. Mitochondrial genetic diversity and phylogenetic relationships of *Echinococcus multilocularis* in Europe. *Int J Parasitol* (in press).
10. Kern P. Clinical features and treatment of alveolar echinococcosis. *Curr Opin Infect Dis* 2010;**23**(5):505–512
11. Ozturk G, Polat KY, Yildirgan MI, Aydinli B, Atamanalp SS, Aydin U. Endoscopic retrograde cholangiopancreatography in

- hepatic alveolar echinococcosis. *J Gastroenterol Hepatol* 2009;**24**(8):1365–1369
12. Kantarci M, Bayraktutan U, Karabulut N, Aydinli B, Ogul H, Yuce I *et al.* Alveolar echinococcosis: spectrum of findings at cross-sectional imaging. *Radiographics* 2012;**32**(7):2053–2070
 13. Jenkins D. WHO/OIE manual on Echinococcosis in humans and animals: a public health problem of global concern. *Int J Parasitol* 2001;**31**:1717–1718
 14. Thompson RC. Biology and systematics of echinococcus. *Adv Parasitol* 2017;**95**:65–109
 15. Bulakci M, Ilhan M, Bademler S, Yilmaz E, Gulluoglu M, Bayraktar A *et al.* Efficacy of ultrasound-guided core-needle biopsy in the diagnosis of hepatic alveolar echinococcosis: a retrospective analysis. *Parasite* 2016;**23**:19
 16. Mihmanli M, Idiz UO, Kaya C, Demir U, Bostanci O, Omeroglu S *et al.* Current status of diagnosis and treatment of hepatic echinococcosis. *World J Hepatol* 2016;**8**(28):1169–1181
 17. Reuss AM, Wulf MA, Oertel MF, Bozinov O, Henzi A, Kaelin MB *et al.* An immunocompetent farmer with isolated cerebral alveolar echinococcosis: illustrative case. *J Neurosurg Case Lessons* 2021;**1**(22):CASE2187
 18. Hillenbrand A, Gruener B, Kratzer W, Kern P, Graeter T, Barth TF *et al.* Impact of safe distance on long-term outcome after surgical therapy of alveolar echinococcosis. *World J Surg* 2017;**41**(4):1012–1018
 19. Salm LA, Lachenmayer A, Perrodin SF, Candinas D, Beldi G. Surgical treatment strategies for hepatic alveolar echinococcosis. *Food Waterborne Parasitol* 2019;**15**:e00050
 20. Calame P, Weck M, Busse-Cote A, Brumpt E, Richou C, Turco C *et al.* Role of the radiologist in the diagnosis and management of the two forms of hepatic echinococcosis. *Insights Imaging* 2022;**13**(1):68
 21. Mayo MJ. Extrahepatic manifestations of hepatitis C infection. *Am J Med Sci* 2003;**325**(3):135–148
 22. Husmann L, Muehlematter UJ, Grimm F, Ledergerber B, Messerli M, Kudura K *et al.* PET/CT helps to determine treatment duration in patients with resected as well as inoperable alveolar echinococcosis. *Parasitol Int* 2021;**83**:102356