

Case Report

# Images in Immunotherapy and Precision Oncology: Angiosarcoma of the Spleen and Liver

Anagha Deshpande,<sup>1</sup> Javier Munoz,<sup>2</sup> Katalin Kelemen,<sup>3</sup> Vrushali Dabak,<sup>4</sup> Amr Hanbali,<sup>5</sup> Razelle Kurzrock<sup>6,7,8</sup>

<sup>1</sup>Mayo Clinic Alix School of Medicine, Scottsdale, AZ, USA

<sup>2</sup>Department of Hematology, Mayo Clinic Arizona, Phoenix, AZ, USA

<sup>3</sup>Division of Hematopathology, Department of Laboratory Medicine and Pathology, Mayo Clinic Arizona, Phoenix, AZ, USA

<sup>4</sup>Department of Hematology and Oncology, Henry Ford Health System, Detroit, MI, USA

<sup>5</sup>King Faisal Specialist Hospital, Riyadh, Saudi Arabia

<sup>6</sup>Medical College of Wisconsin, Milwaukee, WI, USA

<sup>7</sup>Worldwide Innovative Networking in Personalized Cancer Medicine (WIN) Consortium, Paris, France

<sup>8</sup>University of Nebraska, Omaha, NE, USA

Address correspondence to Anagha Deshpande (deshpande.anagha@mayo.edu).

Anagha Deshpande and Javier Munoz are co-first authors.

Source of Support: None.

Conflict of Interest: Javier Munoz reports the following: consulting for Pharmacyclics/AbbVie, Bayer, Gilead/Kite Pharma, Pfizer, Janssen, Juno/Celgene, BMS, Kyowa, Alexion, Fosunkite, Innovent, Seattle Genetics, Debiopharm, Karyopharm, Genmab, ADC Therapeutics, Epizyme, Beigene, Servier, Novartis, Morphosys/Incyte, MEI Pharma, Zodiac; research funding from Bayer, Gilead/Kite Pharma, Celgene, Merck, Portola, Incyte, Genentech, Pharmacyclics, Seattle Genetics, Janssen, Millennium; honoraria from Targeted Oncology, OncView, Curio, Kyowa, Physicians' Education Resource, Dava, Global Clinical Insights, MJH, Shanghai Youyao, Seattle Genetics; and speaker's bureau at Gilead/Kite Pharma, Kyowa, Bayer, Pharmacyclics/Janssen, Seattle Genetics, Acrotech/Aurobindo, Beigene, Verastem, AstraZeneca, Celgene/BMS, Genentech/Roche. Razelle Kurzrock reports the following: research funding from Biological Dynamics, Boehringer Ingelheim, Debiopharm, Foundation Medicine, Genentech, Grifols, Guardant, Incyte, Konica Minolta, Medimmune, Merck Serono, Omniseg, Pfizer, Sequenom, Takeda, TopAlliance; consultant, speaker fees, and/or advisory board for Actuate Therapeutics, AstraZeneca, Bicara Therapeutics, Biological Dynamics, Daiichi Sankyo, Inc., Eisai, EOM Pharmaceuticals, Iylon, Merck, NeoGenomics, Neomed, Pfizer, Prosperdtx, Roche, TD2/Volastra, Turning Point Therapeutics, X-Biotech; equity interest in CureMatch Inc., CureMetrix, IDbyDNA; on boards of CureMatch, CureMetrix; and cofounder of CureMatch. The remaining authors have no disclosures.

Received: Aug 1, 2022; Revision Received: Oct 26, 2022; Accepted: Nov 2, 2022

Deshpande A, Munoz J, Kelemen K, et al. Images in immunotherapy and precision oncology: angiosarcoma of the spleen and liver. *J Immunother Precis Oncol.* 2023; 6:56–58. DOI: 10.36401/JIPO-22-22.

This work is published under a CC-BY-NC-ND 4.0 International License.

## ABSTRACT

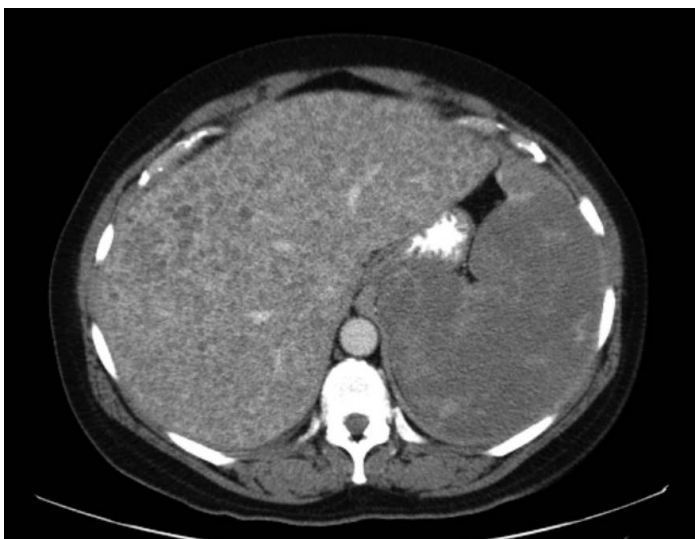Primary splenic or hepatic angiosarcomas are ultra-rare and aggressive malignancies associated with poor prognosis. The mainstay treatments are surgical resection and chemotherapy. We report a case of angiosarcoma in a 50-year-old woman who presented with bruising, fatigue, echymosis, and hepatosplenomegaly. She was treated with the multi-kinase inhibitor sunitinib for 4 weeks before developing a splenic hemorrhage and succumbing. Recent studies have demonstrated the clinical benefit of immunotherapies in angiosarcomas. Additionally, sequencing techniques have showcased the diverse molecular aberrations involved in angiosarcomas, which offer opportunities for precision-matched targeted therapies such as inhibitors of the VEGF/VEGFR axis and PI3K/Akt/mTOR pathway.

**Keywords:** splenic angiosarcoma, hepatic angiosarcoma, nivolumab, ipilimumab

## Case Summary

A 50-year-old woman presented with bruising, early satiety, fatigue, and dizziness. On physical examination, she had upper extremity echymosis and hepatosplenomegaly. She was hospitalized for severe hypochromic microcytic anemia (hemoglobin of 5.8 g/dL; normal  $\geq$  12 g/dL) and disseminated intravascular coagulation. Her initial laboratory profile consisted of a platelet count of 121,000/ $\mu$ L, partial thromboplastin time of 43 seconds,

prothrombin time of 21.1 seconds, international normalized ratio of 1.79, fibrinogen of 104 mg/dL, and D-dimer  $>$  20,000 ng/dL. Upper endoscopy and colonoscopy showed no significant bleeding source. A computed tomography (CT) scan revealed multiple small, low-attenuating lesions throughout the enlarged liver and spleen (Fig. 1). Abdominal laparoscopy showed multiple hemangioma-like lesions of the liver and spleen (Fig. 2). Liver biopsy demonstrated blood-filled cavities with infiltrative tumor cells; the tumor cells had abundant,



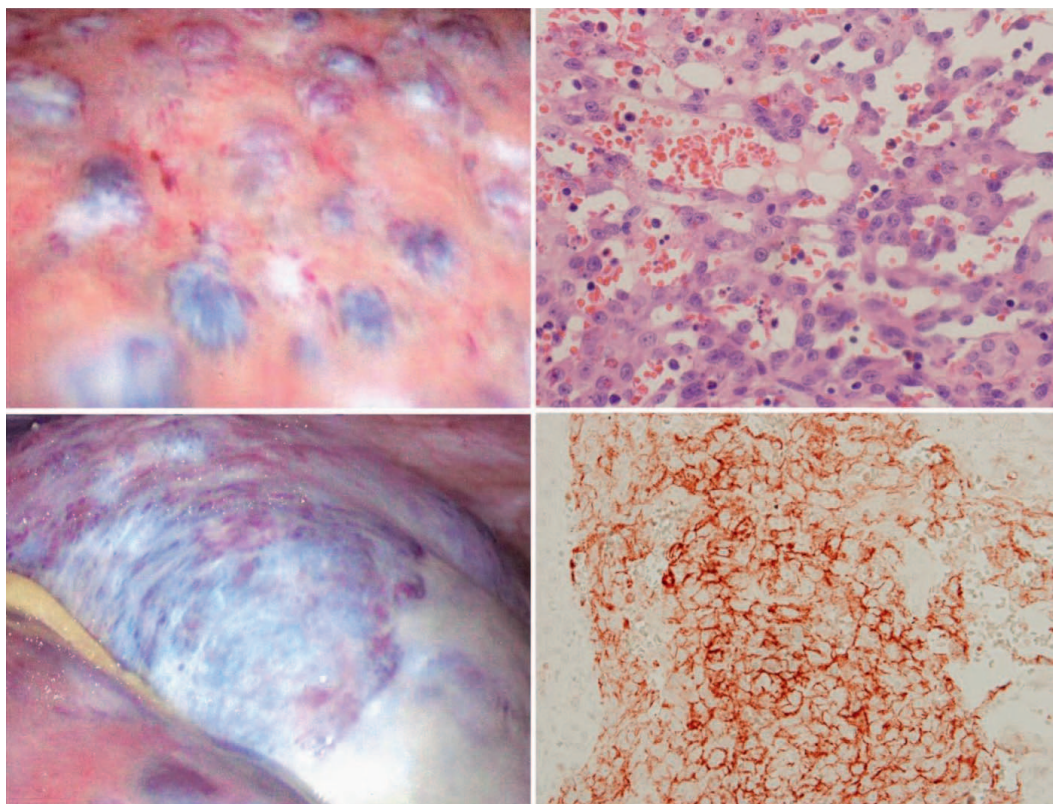
**Figure 1.** Computed tomography images revealed multiple small, low-attenuating lesions throughout the enlarged liver and spleen.

pale eosinophilic cytoplasm with poorly defined cell borders, pleomorphism, hyperchromatic nuclei, and increased mitotic activity. Immunohistochemical stains were positive for factor VIII-related antigen and cluster of differentiation 31 (CD31). The pathologic diagnosis

was angiosarcoma, but it was uncertain whether it was primary liver versus metastatic from the spleen. She was treated with the multikinase inhibitor sunitinib for 4 weeks, but she developed a splenic hemorrhage and succumbed. Informed consent was provided by the patient.

## DISCUSSION

Primary splenic or hepatic angiosarcomas are ultra-rare aggressive malignancies, associated with poor prognosis, especially after splenic rupture.<sup>[1,2]</sup> Clinically, primary splenic angiosarcoma presents with anemia and splenomegaly. Primary hepatic angiosarcoma, on the other hand, presents with right upper quadrant pain, weight loss, jaundice, and abdominal distension. Both can be diagnosed via ultrasound showing nodules or solitary masses with varying echogenicity secondary to the necrosis and hemorrhage within the lesions and later confirmed with a computed tomography scan and biopsy. For the minority of patients with localized disease, surgical resection, including splenectomy, is an option. Splenectomy can also be offered as a palliative measure for primary splenic angiosarcomas.<sup>[3]</sup> Chemotherapy (taxanes, doxorubicin, liposome doxorubicin, and ifosfamide) has been a mainstay treatment for



**Figure 2.** Angiosarcoma of the spleen and liver. The left panels represent a visualization of the liver (top) and the spleen (bottom). The right panels represent immunohistochemistry stains for CD31 (top) and hematoxylin and eosin (bottom). These stains revealed numerous blood-filled cavities with a diffusely infiltrative tumor composed of anastomosing epithelioid and spindled malignant-appearing cells protruding into the lumen of vascular channels. The tumor cells had abundant, pale, eosinophilic cytoplasm, poorly defined cell borders with increased pleomorphism, and hyperchromatic and variably prominent nucleoli with increased mitotic activity. CD31, cluster of differentiation 31.

advanced angiosarcoma. Paclitaxel is an active monotherapy.<sup>[4]</sup>

Recently, immune checkpoint blockade was reported to have activity in some angiosarcomas.<sup>[5,6]</sup> Florou et al<sup>[5]</sup> treated seven patients with immunotherapy (five had cutaneous angiosarcoma, one primary breast angiosarcoma, and one radiation-associated breast angiosarcoma); five (71%) attained partial responses. Similarly, in a phase 2 study (DART [Dual Anti-CTLA4 and Anti-PD1 in Rare Tumors]; ClinicalTrials.gov Identifier: NCT02834013 conducted by the National Cancer Institute–Southwest Oncology Group (NCI-SWOG),<sup>[6]</sup> the objective response rate to nivolumab combined with ipilimumab was 25%, with responses in breast angiosarcoma (postradiation type) and three of five patients (60%) with cutaneous scalp or face disease; some responses were ongoing at > 1 year. For treating primary hepatic angiosarcoma specifically, recent reports have shown the efficacy of pembrolizumab monotherapy, an immunotherapy targeting programmed cell death ligand 1 (PD-L1).<sup>[7,8]</sup> Immunotherapies targeting PD-L1 or the programmed cell death protein 1 PD-1 receptor have also demonstrated efficacy in treating primary splenic angiosarcomas, as recent case reports have shown significant clinical benefit with pembrolizumab monotherapy as well as with the anti-PD-1 toripalimab combined with the multikinase inhibitor anlotinib.<sup>[9,10]</sup> In addition to these novel therapies, other tyrosine kinase inhibitors that also inhibit the vascular endothelial growth factor (VEGF)/VEGF receptor (VEGFR) signaling pathway, such as sunitinib or sorafenib, have demonstrated clinical benefit in treating recurrent metastatic angiosarcomas.<sup>[11,12]</sup>

At the molecular level, angiosarcomas are heterogeneous. Those found on the scalp and face harbor high tumor mutation burden, hydrophobic (and therefore more immunogenic) amino acid variations, and ultraviolet mutational signature, all of which may predispose to immune checkpoint blockade response.<sup>[13,14]</sup> Whole-exome sequencing revealed a variety of pathogenic alterations, including *VEGFR2*, *TP53*, and *PIK3CA* alterations. *PIK3CA*-activating mutations were discerned mostly in primary breast angiosarcoma, which suggests a therapeutic rationale for phosphoinositide 3-kinase (PI3K) inhibitors. Breast angiosarcomas are also enriched for *MYC* amplification.<sup>[15]</sup> Next-generation sequencing has also revealed *FOS*-, *MCL1*-, and *PIK3CA*-activating mutations in primary splenic angiosarcomas, suggesting a rationale for using PI3K inhibitors as well as mammalian target of rapamycin (mTOR) inhibitors for therapeutic benefit.<sup>[16]</sup> In primary hepatic angiosarcomas, next-generation sequencing has shown high-level amplification of the 4q11-q13.1 region, which contains the *KIT*, *PDGFRA*, and *VEGFR2* genes.<sup>[17]</sup> Of note, whole-exome sequencing showed *PLCG1* mutations that allowed for VEGF-R independent signaling, providing a

plausible mechanism of resistance to VEGFR-directed therapies.<sup>[17]</sup>

In summary, angiosarcomas have diverse molecular abnormalities, and some of these genomic aberrations may be pharmacologically tractable. Furthermore, a subset of angiosarcomas, including but perhaps not limited to breast post-radiation and those of the face and scalp have high tumor mutational burden and are responsive to immune checkpoint blockade.

## References

1. Neuhauser TS, Derringer GA, Thompson LD, et al. Splenic angiosarcoma: a clinicopathologic and immunophenotypic study of 28 cases. *Mod Pathol*. 2000;13:978–987.
2. Averbukh LD, Mavilia MG, Einstein MM. Hepatic angiosarcoma: a challenging diagnosis. *Cureus*. 2018;10:e3283.
3. Liu Z, Du X, Li H, et al. Primary splenic angiosarcoma. *Vasa*. 2012;41:57–62.
4. Cao J, Wang J, He C, Fang M. Angiosarcoma: a review of diagnosis and current treatment. *Am J Cancer Res*. 2019;9:2303–2313.
5. Florou V, Rosenberg AE, Wieder E, et al. Angiosarcoma patients treated with immune checkpoint inhibitors: a case series of seven patients from a single institution. *J Immunother Cancer*. 2019;7:213.
6. Wagner MJ, Othus M, Patel SP, et al. Multicenter phase II trial (SWOG S1609, cohort 51) of ipilimumab and nivolumab in metastatic or unresectable angiosarcoma: a substudy of dual anti-CTLA-4 and anti-PD-1 blockade in rare tumors (DART). *J Immunother Cancer*. 2021;9:e002990.
7. Sindhu S, Gimber LH, Cranmer L, et al. Angiosarcoma treated successfully with anti-PD-1 therapy - a case report. *J Immunother Cancer*. 2017;5:58.
8. Qiao Y, Yang J, Liu L, et al. Successful treatment with pazopanib plus PD-1 inhibitor and RAK cells for advanced primary hepatic angiosarcoma: a case report. *BMC Cancer*. 2018;18:212.
9. Wheelwright M, Spartz EJ, Skubitiz K, et al. Primary angiosarcoma of the spleen, a rare indication for splenectomy: a case report. *Int J Surg Case Rep*. 2021;82:105929.
10. Xu W, Wang K, Gu W, et al. Case report: complete remission with anti-PD-1 and anti-VEGF combined therapy of a patient with metastatic primary splenic angiosarcoma. *Front Oncol*. 2022;12:809068.
11. Fujisawa Y, Yoshino K, Fujimura T, et al. Cutaneous angiosarcoma: the possibility of new treatment options especially for patients with large primary tumor. *Front Oncol*. 2018;8:46.
12. Lu HJ, Chen PCH, Yen CC, et al. Refractory cutaneous angiosarcoma successfully treated with sunitinib. *Br J Dermatol*. 2013;169:204–206.
13. Boichard A, Wagner MJ, Kurzrock R. Angiosarcoma heterogeneity and potential therapeutic vulnerability to immune checkpoint blockade: insights from genomic sequencing. *Genome Med*. 2020;12:61.
14. Painter CA, Jain E, Tomson BN, et al. The Angiosarcoma Project: enabling genomic and clinical discoveries in a rare cancer through patient-partnered research. *Nat Med*. 2020;26:181–187.
15. Espejo-Freire AP, Elliott A, Rosenberg A, et al. Genomic landscape of angiosarcoma: a targeted and immunotherapy biomarker analysis. *Cancers*. 2021;13:4816.
16. Cao L, Hong J, Wang Y, et al. A primary splenic angiosarcoma hepatic metastasis after splenectomy and its genomic alteration profile. *Medicine (Baltimore)*. 2019;98:e16245.
17. Prenen H, Smeets D, Mazzone M, et al. Phospholipase C gamma 1 (PLCG1) R707Q mutation is counterselected under targeted therapy in a patient with hepatic angiosarcoma. *Oncotarget*. 2015;6:36418–36425.