

## Case Report

# Sustained Clinical Response to Immunotherapy Followed by BET Inhibitor in a Patient with Unresectable Sinonasal NUT Carcinoma

Harriet Herbison,<sup>1</sup> Sidney Davis,<sup>2</sup> David Nickless,<sup>3</sup> Andrew Haydon,<sup>4</sup> Malaka Ameratunga<sup>4,5</sup>

<sup>1</sup>Department of Medical Oncology, Monash Health, Clayton, Victoria, Australia

<sup>2</sup>Department of Radiation Oncology, The Alfred Hospital, Melbourne, Victoria, Australia

<sup>3</sup>Department of Anatomical Pathology, Cabrini Pathology, Melbourne, Victoria, Australia

<sup>4</sup>Department of Medical Oncology, The Alfred Hospital, Melbourne, Victoria, Australia

<sup>5</sup>Central Clinical School, Monash University, Melbourne, Victoria, Australia

Address correspondence to Malaka Ameratunga (malaka.ameratunga@monash.edu).

Source of Support: None. Conflicts of Interest: None.

Submitted: Jul 4, 2023; First Revision Received: Aug 24, 2023; Accepted: Sep 13, 2023

Herbison H, Davis S, Nickless D, Haydon A, Ameratunga M. Sustained clinical response to immunotherapy followed by BET inhibitor in a patient with unresectable sinonasal NUT carcinoma. *J Immunother Precis Oncol.* 2024; 7:67–72. DOI: 10.36401/JIPO-23-19.

This work is published under a CC-BY-NC-ND 4.0 International License.

## ABSTRACT

NUT carcinomas (NCs) are a group of rare tumors that can occur anywhere in the body and are defined by the fusion of the nuclear protein in testis (*NUTM1*) resulting in increased transcription of proto-oncogenes. NCs have a poor prognosis that varies according to the site of origin with an urgent need to develop new treatment strategies. Case reports on immunotherapy in pulmonary NC have been published, and bromodomain and extraterminal (BET) inhibitors have shown activity in NC in phase I/II trials. We present the case of a 27-year-old woman with an unresectable sinonasal NC who had a sustained clinical response to both immunotherapy and BET inhibitor therapy. This is the first reported case of immunotherapy in sinonasal NC, and it highlights the different responses to a range of treatments including BET inhibitor therapy. This case supports the theory that NCs arising from different primary sites have differing prognoses.

**Keywords:** NUT carcinoma, BET inhibitor, radiation, immunotherapy

## INTRODUCTION

NUT carcinomas (NCs) are rare tumors defined by nuclear protein in testis (*NUTM1*) gene fusion, typically to a bromodomain and extraterminal (BET) gene, resulting in epigenetic dysregulation.<sup>[1]</sup> NC can occur at any age, including in children and young adults.<sup>[2]</sup> Treatment options include surgery, radiation, chemotherapy, immunotherapy, and targeted therapies, with limited evidence to guide treatment. BET inhibitors have demonstrated activity in NC in early-phase trials.<sup>[3–7]</sup> Although responses to immunotherapy in pulmonary NC have been observed,<sup>[8–10]</sup> to our knowledge, this is the first case report of a patient with sinonasal NC who benefited from immunotherapy. The patient gave written consent to publish her case per institutional guidelines.

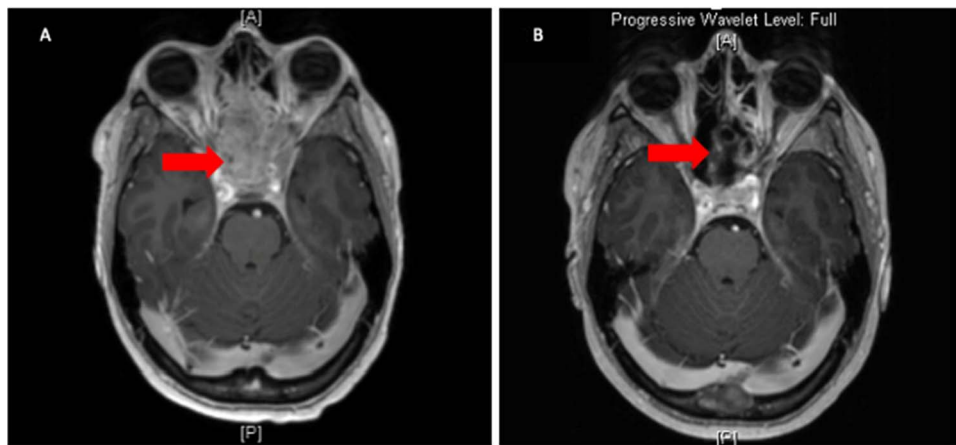
## CASE REPORT

A 27-year-old woman presented with headaches, left central visual field defect, and a smaller right visual field

defect in 2019. Magnetic resonance imaging (MRI) of the sinuses revealed a large heterogeneous enhancing tumor within the nasal cavity extending to the left cavernous sinus, encasing the left optic nerve as well as closely abutting the right optic apparatus (Fig. 1A). There were no distant metastases.

Biopsy showed a widely infiltrating tumor, with areas of spindle morphology and no squamous differentiation. The tumor cells were strongly and diffusely positive for p63, cytokeratin AE 1 and 3, cytokeratin 7, p40, CD34, and p16. There was strong positive speckled nuclear reactivity to NUT antibody, confirming the diagnosis of sinonasal NC. Tumor Proportion Score (TPS) showed <1% tumor cell membrane staining for programmed death ligand 1 (PD-L1) using the Ventana SP263 Clone (Fig. 2).

The tumor was deemed unresectable on review at a multidisciplinary meeting. The patient underwent induction chemotherapy with docetaxel 75 mg/m<sup>2</sup>, cisplatin 100 mg/m<sup>2</sup>, and fluorouracil 4000 mg/m<sup>2</sup> every 3 weeks for three cycles.<sup>[11]</sup> On completion of chemotherapy,



**Figure 1.** Magnetic resonance imaging (MRI) sinus (arrow). MRI shows sinus at diagnosis (A) and prolonged tumor response more than 2 years after diagnosis (B).

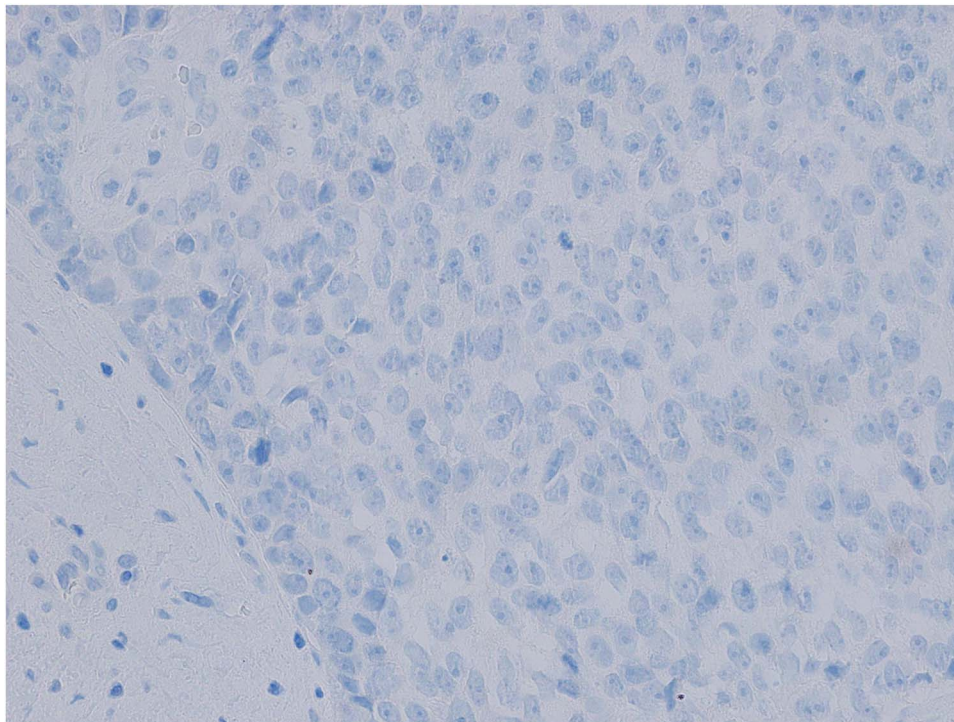
minor radiological disease progression was observed, and the patient proceeded to have 70-Gy volumetric modulated arc therapy (VMAT radiotherapy) encompassing all known tumor tissue. She had a radiological partial response (PR), with clinical improvement in her right eye visual acuity.

At the time of radiation, the patient also commenced second-line treatment with nivolumab 480 mg given intravenously every 4 weeks. She had further reduction in size of the primary tumor on serial imaging (Fig. 1B). In July 2020, a midline frontal calvarial metastasis was found on restaging MRI and was treated with stereotactic radiotherapy (30 Gy in five fractions). In February 2021, three additional calvarial metastases were seen on restaging

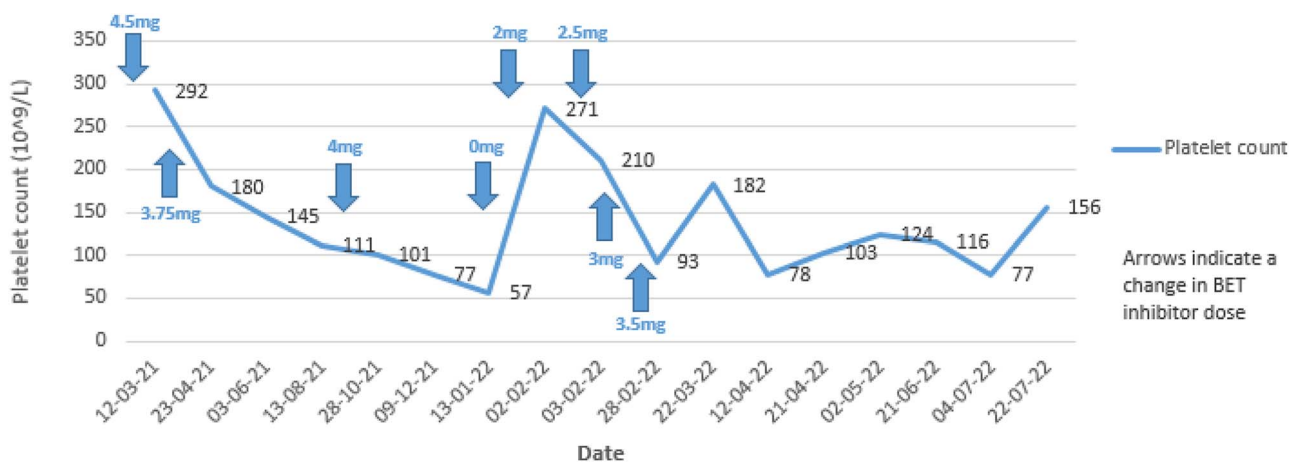
scans, and the decision was made to change systemic therapy. At this time, the patient had FoundationOne CDx testing that identified a *BRD3-NUTM1* fusion, confirming her NC diagnosis.

The patient was granted compassionate access to BET inhibitor BMS-986158, which has an intermittent oral daily dosing schedule (5 days on, 2 days off), initially commenced at 4.5 mg orally for 2 weeks, then reduced to 3.75 mg orally.<sup>3</sup> She required a 1-week dose interruption for grade 2 thrombocytopenia. On improvement of her thrombocytopenia to grade 1, BET inhibitor was recommenced at 2 mg and titrated up to 3.5 mg daily (Fig. 3).

After 3 months of BET inhibition, restaging MRI showed further reduction in the size of the primary tumor, stable



**Figure 2.** Histologic evaluation shows < 1% tumor cell membrane staining for PD-L1. PD-L1: programmed death ligand 1.



**Figure 3.** Platelet count over time with corresponding bromodomain and extraterminal (BET) inhibitor dosing.

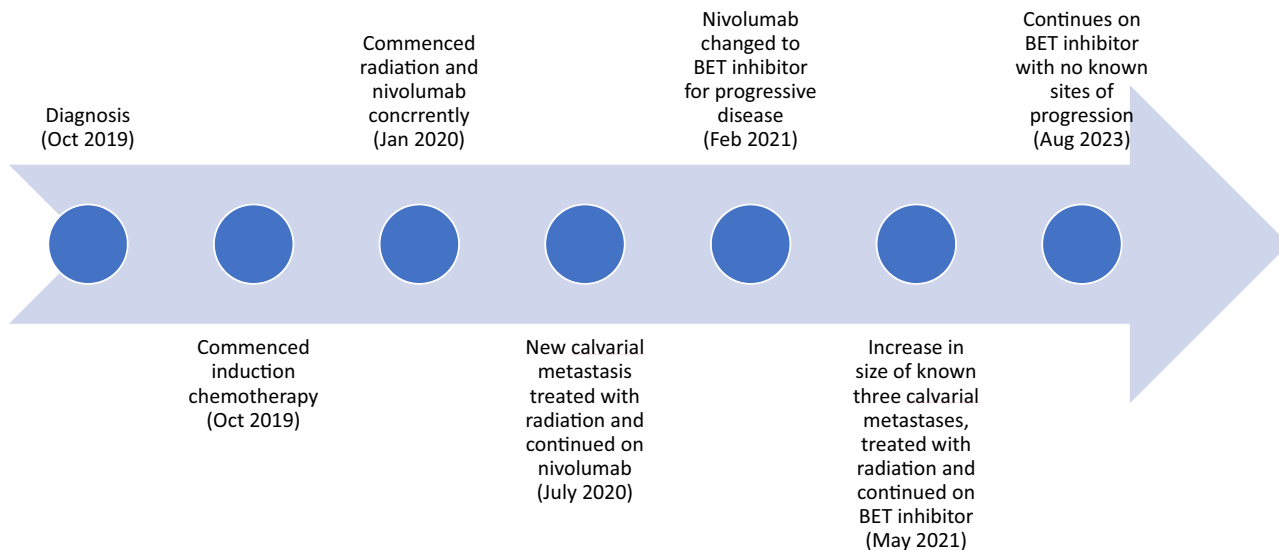
midline frontal calvarial metastasis, and increased size of the additional calvarial metastases, which was considered a treatment-related flare and was treated with stereotactic radiotherapy. Subsequently, the patient has had a sustained response to all known sites of disease, with no new lesions. Figure 4 shows the patient’s cancer journey from diagnosis.

**DISCUSSION**

Fewer than 100 cases of NC are diagnosed every year in the United States, with the true prevalence unknown, as NC is underrecognized and underdiagnosed.<sup>[12,13]</sup> NCs can occur anywhere, with pulmonary and head and neck NC being the most common sites (56% and 40%, respectively).<sup>[2,13]</sup> Pulmonary NC should be considered in all poorly differentiated pulmonary carcinomas that lack common lung molecular alterations.<sup>[13]</sup> Diagnosis can be made by performing NUT immunohistochemistry (100%

specificity, 87% sensitivity).<sup>[14]</sup> Alternatively, *NUTM1* fusions can be identified by fluorescence in situ hybridization, reverse transcriptase polymerase chain reaction, or next-generation sequencing.<sup>[15]</sup>

NC has a median overall survival (OS) of 6.7 months from time of diagnosis,<sup>[2]</sup> with 60% of patients presenting with de novo metastatic disease.<sup>[16]</sup> Although our patient exceeded the median OS, NC prognosis may differ by primary site and the specific molecular alteration.<sup>[12]</sup> The NUT Carcinoma Registry outlines three prognostic groups based on the outcomes of 141 patients.<sup>[12]</sup> Patients with thoracic tumors represent the worst prognostic group, with a median OS of 4.4 months. Patients with nonthoracic tumors with *BRD4-NUT* alterations have an intermediate prognosis, with a median OS of 10 months. The 12 patients with nonthoracic tumors with *BRD3* or *NSD3-NUT* alterations had the best prognosis, with a median OS of 36.5 months.<sup>[12]</sup> Our patient’s clinicopathological features are consistent with the best prognostic group.



**Figure 4.** Timeline of patient’s journey. BET, bromodomain and extraterminal.



**Table 1.** NUT carcinoma responses to BET inhibitors across multiple phase I/II trials

Study	Total Patients with NC (N)	Patients with PR, n (%)	mPFS	DOR
Hilton et al. <sup>[3]</sup>	7	1	-	-
Piha-Paul et al. <sup>[4]</sup>	19	4 (21)	2.5 mo	8–255 d
Ameratunga et al. <sup>[5]</sup>	4	0 (0)	2.2 mo	0.5–9.7 mo
Lewin et al. <sup>[6]</sup>	10	3 (14)	-	1.4–8.4 mo
Shapiro et al. <sup>[7]</sup>	8	2 (25)	94 d	15–783 d

Dash (-) indicates not available.

BET: bromodomain and extraterminal; DOR: duration of response; mPFS: mean progression-free survival; PR: partial response.

One of the most important prognostic factors is whether the tumor is resectable. Chau et al.<sup>[12]</sup> found that complete resection was a significant predictor of improved survival, which may explain the different outcomes for different primary sites, as head and neck cancers are more frequently resectable.

NCs are not chemotherapy-responsive, and the optimal chemotherapy regimen is undefined.<sup>[13]</sup> The best supportive data are for high-dose ifosfamide-based chemotherapy in the pediatric setting.<sup>[17–19]</sup>

The patient's excellent response to radiation is reflected in the literature on sinonasal NC.<sup>[2,12,16]</sup> A systematic review of 119 patients with NC showed that the 49 patients who received radiation had improved OS, especially in patients who received  $\geq 50$  Gy of radiation.<sup>[16]</sup> Head and neck NCs were the most likely to receive adjuvant or definitive radiation, and the positive impact of radiation was seen in head, neck, and lung but not mediastinal NCs. Two further studies also suggested that radiation improves OS.<sup>[2,12]</sup> It is unclear how much our patient benefited from radiation and immunotherapy individually or whether there was a synergistic effect because both commenced at the same time. In head and neck squamous cell carcinoma, this combination has not been proven effective compared with chemoradiation alone.<sup>[20,21]</sup>

Our patient's tumor sensitivity to radiation but not chemotherapy is consistent with the literature<sup>[16]</sup> for NC, but is not typically seen in other tumor types. The mechanism behind this difference remains unknown but warrants investigation, as this could inform our broader understanding of radiobiology.

Our patient had a durable response to immunotherapy for more than 12 months, signifying an important treatment option for unresectable sinonasal NCs. There are reported cases of pulmonary and two thyroid NCs treated with immunotherapy at different time points in the treatment trajectory.<sup>[8–10,22–25]</sup> Response to immunotherapy ranged from 1.5 months to not reached, with one patient with thyroid NC remaining disease-free more than 38 months after R1 resection followed by chemoradiation and immunotherapy.<sup>[23]</sup> Although tumor mutational burden and PD-L1 predict response to immunotherapy in some tumor types,<sup>[26]</sup> they do not always correlate with response to immunotherapy in NC.<sup>[8,10,25]</sup> Our patient's sustained response to immunotherapy with a PD-L1 score of <1% reflects what is reported in the literature. To our

knowledge, this is the first reported case of immunotherapy in sinonasal NC.

The molecular hallmark of NC is the fusion of *NUTM1* with a transcriptional and epigenetic regulator gene such as *BRD4*, *BRD3*, *NSD3*, or *ZNF*.<sup>[13]</sup> The result is increased activity of BET, which binds acetylated lysine residues at the amino-terminal tails of histones facilitating recruitment of P-TEFb, which phosphorylates RNA polymerase II resulting in chromatin elongation and transcription.<sup>[27–29]</sup> In NC, because of the fusion with *NUTM1*, this process is enhanced, resulting in increased expression of proto-oncogenes such as *MYC* and *SOX2*.<sup>[13]</sup>

BET inhibitors are acetyl-histone mimetic compounds that competitively inhibit BRD binding to chromatin, thereby limiting the activity of BRD.<sup>[30]</sup> Multiple BET inhibitors are in clinical development<sup>[31]</sup> with early-phase results demonstrating activity in NC (Table 1).<sup>[3–7]</sup> In a phase I/II study of molibresib, 4 of 19 patients with NC had a PR. The median progression-free survival (PFS) for the 19 patients was low at 2.5 months; however, four patients had a PFS of 6 months or more.<sup>[4]</sup> All had extrathoracic tumors, indicating possible underlying core biological differences according to primary site.

One of four patients with NC in a phase I study of pan-BET inhibitor ODM-207 had stable disease with a median PFS of 2.2 months.<sup>[5]</sup> Lewin et al.<sup>[6]</sup> tested BET inhibitor birabresib (MK-8628/OTX015) on 10 (of 46) patients with NC. Three had a PR with duration of response (DOR) ranging from 1.4 to 8.4 months. Shapiro et al.<sup>[7]</sup> examined pan-BET inhibitor RO6870810 in eight patients with NC, two of whom had a PR with DOR ranging from 15 to 783 days, with a median PFS of 94 days. Last, BMS-986158 is a selective BET inhibitor (used in our patient) that was examined in a phase I/II study, with one of seven patients with NC achieving a PR.<sup>[3]</sup>

Although the median PFS in these dose-escalation studies is poor, many patients with NC in these trials may have received sub-therapeutic doses. In addition, there is a wide variation in PFS, suggesting NCs are a heterogeneous group of tumors.

The lack of durable responses suggests single-agent BET inhibition may be insufficient for disease control. To mitigate this, novel strategies combining BET inhibitors with other targets, such as p300-CBP, CDK9, and CDK 4/6, are in preclinical development.<sup>[32–34]</sup> In addition, other novel approaches such as the use of histone deacetylase

inhibitors have been reported in both the preclinical and clinical setting.<sup>[35–37]</sup>

The side effect profile of BET inhibitors includes dysgeusia, nausea, vomiting, diarrhea, rash, and thrombocytopenia.<sup>[4,5]</sup> Our patient experienced all the aforementioned toxicities, which were mild and conservatively managed. Importantly, thrombocytopenia is an on-target toxicity of BET inhibition and may serve as a pharmacodynamic biomarker.<sup>[38]</sup> Consistent with the literature, the thrombocytopenia for our patient was easily reversible and manageable.

## CONCLUSION

This case gives insight into the use of various therapies in NC, including immunotherapy, chemotherapy, radiation, and BET inhibitors, and it serves as an example of prolonged response to both immunotherapy and BET inhibitor therapy. The biology behind the differences in response to treatment according to tumor location, as well as the difference in response to radiation compared with chemotherapy, warrants investigation.

## References

- Moreno V, Saluja K, Pina-Oviedo S. NUT carcinoma: clinicopathologic features, molecular genetics and epigenetics. *Front Oncol.* 2022;12:860830.
- Bauer DE, Mitchell CM, Strait KM, et al. Clinicopathologic features and long-term outcomes of NUT midline carcinoma. *Clin Cancer Res.* 2012;18:5773–5779.
- Hilton J, Cristea M, Postel-Vinay S, et al. BMS-986158, a small molecule inhibitor of the bromodomain and extraterminal domain proteins, in patients with selected advanced solid tumors: results from a phase 1/2a trial. *Cancers.* 2022;14:4079.
- Piha-Paul SA, Hann CL, French CA, et al. Phase 1 study of molibresib (GSK525762), a bromodomain and extraterminal domain protein inhibitor, in NUT carcinoma and other solid tumors. *JNCI Cancer Spectr.* 2019;4:pkz093.
- Ameratunga M, Braña I, Bono P, et al. First-in-human Phase I open label study of the BET inhibitor ODM-207 in patients with selected solid tumours. *Br J Cancer.* 2020;123:1730–1736.
- Lewin J, Soria JC, Stathis A, et al. Phase Ib trial with birabresib, a small-molecule inhibitor of bromodomain and extraterminal proteins, in patients with selected advanced solid tumors. *J Clin Oncol.* 2018;36:3007–3014.
- Shapiro GI, LoRusso P, Dowlati A, et al. A Phase 1 study of RO6870810, a novel bromodomain and extra-terminal protein inhibitor, in patients with NUT carcinoma, other solid tumours, or diffuse large B-cell lymphoma. *Br J Cancer.* 2021;124:744–753.
- Li X, Shi H, Zhang W, et al. Immunotherapy and targeting the tumor microenvironment: current place and new insights in primary pulmonary NUT carcinoma. *Front Oncol.* 2021;11:690115.
- Xie XH, Wang LQ, Qin YY, et al. Clinical features, treatment, and survival outcome of primary pulmonary NUT midline carcinoma. *Orphanet J Rare Dis.* 2020;15:183.
- Davis A, Mahar A, Wong K, et al. Prolonged disease control on nivolumab for primary pulmonary NUT carcinoma. *Clin Lung Cancer.* 2021;22:e665–e667.
- Ghi MG, Paccagnella A, Ferrari D, et al. Induction TPF followed by concomitant treatment versus concomitant treatment alone in locally advanced head and neck cancer. A phase II–III trial. *Ann Oncol.* 2017;28:2206–2212.
- Chau NG, Ma C, Danga K, et al. An anatomical site and genetic-based prognostic model for patients with nuclear protein in testis (NUT) midline carcinoma: analysis of 124 patients. *JNCI Cancer Spectr.* 2020;4:pkz094.
- French CA, Cheng ML, Hanna GJ, et al. Report of the first international symposium on NUT carcinoma. *Clin Cancer Res.* 2022;28:2493–2505.
- Haack H, Johnson LA, Fry CJ, et al. Diagnosis of NUT midline carcinoma using a NUT-specific monoclonal antibody. *Am J Surg Pathol.* 2009;33:984–991.
- Dickson BC, Sung YS, Rosenblum MK, et al. NUTM1 gene fusions characterize a subset of undifferentiated soft tissue and visceral tumors. *Am J Surg Pathol.* 2018;42:636–645.
- Giridhar P, Mallick S, Kashyap L, Rath GK. Patterns of care and impact of prognostic factors in the outcome of NUT midline carcinoma: a systematic review and individual patient data analysis of 119 cases. *Eur Arch Otorhinolaryngol.* 2018;275:815–821.
- Storck S, Kennedy AL, Marcus KJ, et al. Pediatric NUT-midline carcinoma: therapeutic success employing a sarcoma based multimodal approach. *Pediatr Hematol Oncol.* 2017;34:231–237.
- Leeman R, Pinkney K, Bradley JA, et al. NUT carcinoma without upfront surgical resection: a case report. *J Pediatr Hematol Oncol.* 2021;43:e707–e710.
- Mertens F, Wiebe T, Adlercreutz C, et al. Successful treatment of a child with t(15;19)-positive tumor. *Pediatr Blood Cancer.* 2007;49:1015–1017.
- Lee NY, Ferris RL, Psyrris A, et al. Avelumab plus standard-of-care chemoradiotherapy versus chemoradiotherapy alone in patients with locally advanced squamous cell carcinoma of the head and neck: a randomised, double-blind, placebo-controlled, multicentre, phase 3 trial. *Lancet Oncol.* 2021;22:450–462.
- Machiels JP, Tao Y, Burtress B, et al. LBA5 primary results of the phase III KEYNOTE-412 study: pembrolizumab (pembro) with chemoradiation therapy (CRT) vs placebo plus CRT for locally advanced (LA) head and neck squamous cell carcinoma (HNSCC). *Ann Oncol.* 2022;33:S1399.
- Chen M, Chen X, Zhang Y, et al. Clinical and molecular features of pulmonary NUT carcinoma characterizes diverse responses to immunotherapy, with a pathologic complete response case. *J Cancer Res Clin Oncol.* 2023;149:6361–6370.
- Kuo LE, Barletta J, Schoenfeld JD, et al. NUT carcinoma of the thyroid: an unusual case with a complete response to treatment. *Clin Thyroid.* 2021;33:38–47.
- Riess JW, Rahman S, Kian W, et al. Genomic profiling of solid tumors harboring BRD4-NUT and response to immune checkpoint inhibitors. *Transl Oncol.* 2021;14:101184.
- Zhou J, Duan M, Jiao Q, et al. Primary thyroid NUT carcinoma with high PD-L1 expression and novel massive IGKV gene fusions: a case report with treatment implications and literature review. *Front Oncol.* 2022;11:778296.

26. Fumet JD, Truntzer C, Yarchoan M, Ghiringhelli F. Tumour mutational burden as a biomarker for immunotherapy: current data and emerging concepts. *Eur J Cancer*. 2020;131:40–50.
27. LeRoy G, Rickards B, Flint SJ. The double bromodomain proteins Brd2 and Brd3 couple histone acetylation to transcription. *Mol Cell*. 2008;30:51–60.
28. Rahman S, Sowa ME, Ottinger M, et al. The Brd4 extraterminal domain confers transcription activation independent of pTEFb by recruiting multiple proteins, including NSD3. *Mol Cell Biol*. 2011;31:2641–2652.
29. Alekseyenko AA, Walsh EM, Wang X, et al. The oncogenic BRD4-NUT chromatin regulator drives aberrant transcription within large topological domains. *Genes Dev*. 2015;29:1507–1523.
30. Sun Y, Han J, Wang Z, et al. Safety and efficacy of bromodomain and extra-terminal inhibitors for the treatment of hematological malignancies and solid tumors: a systematic study of clinical trials. *Front Pharmacol*. 2020;11:621093.
31. Martin-Romano P, Baldini C, Postel-Vinay S. How much can we bet on activity of BET inhibitors beyond NUT-midline carcinoma? *JNCI Cancer Spectr*. 2019;4:pkz092.
32. Liao S, Maertens O, Cichowski K, Elledge SJ. Genetic modifiers of the BRD4-NUT dependency of NUT midline carcinoma uncovers a synergism between BETis and CDK4/6is. *Genes Dev*. 2018;32:1188–1200.
33. Morrison-Smith CD, Knox TM, Filic I, et al. Combined targeting of the BRD4–NUT–p300 axis in NUT midline carcinoma by dual selective bromodomain inhibitor, NEO2734. *Mol Cancer Ther*. 2020;19:1406–1414.
34. Tontsch-Grunt U, Traexler PE, Baum A, et al. Therapeutic impact of BET inhibitor BI 894999 treatment: backtranslation from the clinic. *Br J Cancer*. 2022;127:577–586.
35. Schwartz BE, Hofer MD, Lemieux ME, et al. Differentiation of NUT midline carcinoma by epigenomic reprogramming. *Cancer Res*. 2011;71:2686–2696.
36. Maher OM, Christensen AM, Yedururi S, et al. Histone deacetylase inhibitor for NUT midline carcinoma. *Pediatr Blood Cancer*. 2015;62:715–717.
37. Shiota H, Alekseyenko AA, Wang ZA, et al. Chemical screen identifies diverse and novel histone deacetylase inhibitors as repressors of NUT function: implications for NUT carcinoma pathogenesis and treatment. *Mol Cancer Res*. 2021;19:1818–1830.
38. Gamsjaeger R, Webb SR, Lamonica JM, et al. Structural basis and specificity of acetylated transcription factor GATA1 recognition by BET family bromodomain protein Brd3. *Mol Cell Biol*. 2011;31:2632–2640.