

# Laparoscopic-Assisted Endoscopic Retrograde Cholangiopancreatography in Patients With Prior Gastric Bypass Surgery: A Case Series of Technical Challenges

Abdulrahman Aloun,<sup>1</sup> Fahad Al Abeidi,<sup>2</sup> Ali Alzahrani,<sup>2</sup> Abdul Monem Swied<sup>3</sup>

<sup>1</sup>Department of Medicine, Gastroenterology Division, King Khalid University Hospital, King Saud University, Riyadh, Saudi Arabia

<sup>2</sup>Department of Surgery, National Guard Hospital, Kind Saud Bin Abdulaziz University for Health and Science, Riyadh, Kingdom of Saudi Arabia

<sup>3</sup>Department of Medicine, Gastroenterology Division, Southern Illinois University School of Medicine, Springfield, IL, USA

Address correspondence to Abdulrahman A. Aloun (DrAloun@hotmail.com).

Source of Support: None. Conflict of Interest: None.

Received: Sep 28, 2020; Revision Received: Jan 2, 2021; Accepted: Jan 14, 2021

Aloun A, Al Abeidi F, Alzahrani A, Swied AM. Laparoscopic-assisted endoscopic retrograde cholangiopancreatography in patients with prior gastric bypass surgery: a case series of technical challenges. *Innov Surg Interv Med*. 2021; 1:20–22. DOI: 10.36401/ISIM-20-04.

© Innovative Healthcare Institute

## ABSTRACT

Accessing the biliary ducts for performing endoscopic retrograde cholangiopancreatography (ERCP) and relevant interventional procedures after gastric bypass surgery is technically difficult and frequently unsuccessful due to anatomical alterations. To overcome such technical challenges, laparoscopic-assisted ERCP (LA-ERCP) is used to approach the biliary ducts via nonperoral reliable access for performing different endoscopic biliary interventions. In this case series, we report a total of three patients with different anatomical alterations who underwent LA-ERCP.

**Keywords:** bariatric surgery, case series, CBD stone, LA-ERCP

## INTRODUCTION

In the era of epidemic obesity, there has been an increase in the number of bariatric surgical procedures and nonsurgical procedures performed; however, these procedures are associated with increased risk of gallbladder and common bile duct (CBD) stones formation.<sup>[1,2]</sup> Due to alteration of anatomy after these procedures, which include Roux-en-Y gastric bypass (RYGB) surgery and other forms of bariatric procedures that involve rerouting of the gastrointestinal (GI) tract, standard peroral access to the biliary tree is technically challenging and frequently unsuccessful.<sup>[3,4]</sup> Creation of a temporary laparoscopic gastrostomy or jejunostomy tract and the use of a side-viewing duodenoscope with reliable access to the duodenal papilla is an alternative approach (Fig. 1). Laparoscopic-assisted endoscopic retrograde cholangiopancreatography (LA-ERCP) was first described in 2002 for benign biliary stricture in a patient with a history of RYGB surgery.<sup>[5]</sup> Thereafter, LA-ERCP has been proposed as an

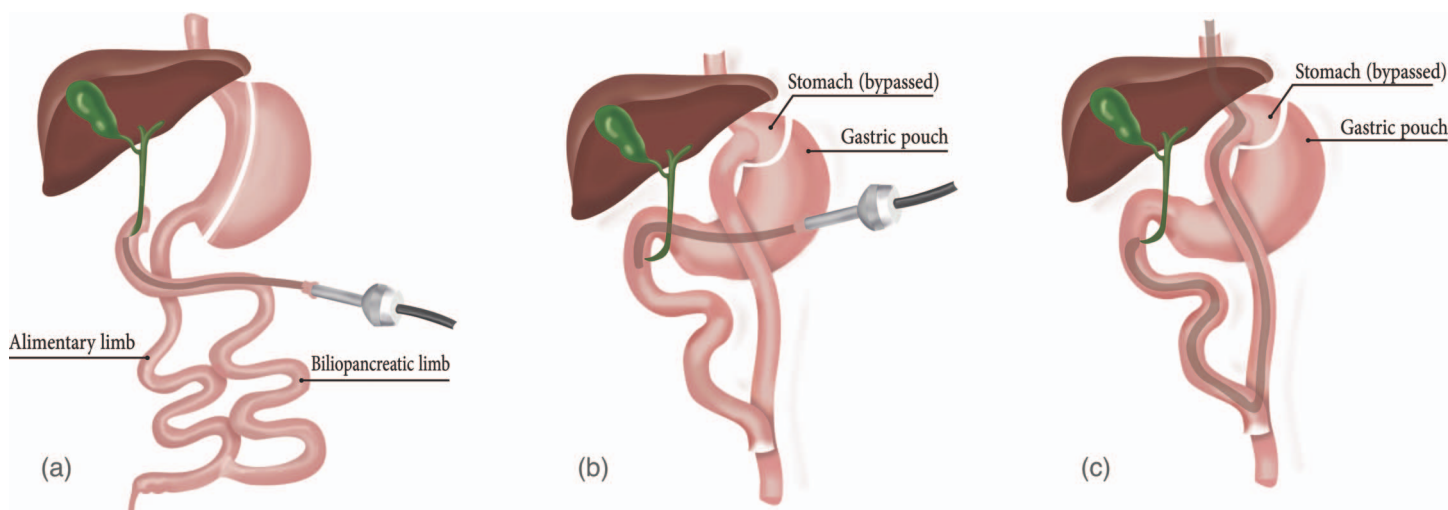
option, and multiple studies followed. However, most of the supporting data are derived from case reports and single-center small case series.<sup>[6–9]</sup>

## METHODS

The present study was conducted at King Abdelaziz Medical City, Riyadh, Saudi Arabia. The objective was to assess the feasibility and performance of LA-ERCP. After institutional review board approval at National Guard Hospital, we performed a retrospective chart review of patients with a prior history of bariatric surgeries that entailed rerouting of the GI tract who underwent LA-ERCP in a tertiary hospital from 2015 to 2019. Data were retrieved from electronic records.

## CASE SERIES

We identified three patients with different anatomical alterations: one with classic RYGB (patient 1), one with



**Figure 1.**—The figure illustrates different anatomic alterations, including laparoscopy-assisted endoscopic retrograde cholangiopancreatography (LA-ERCP) through the remnant isolated stomach (b), LA-ERCP through a created jejunostomy in a patient who underwent biliopancreatic diversion (a), in addition to ERCP using a conventional approach (c).

mini bypass after sleeve gastrectomy (patient 2), and one with RYGBP after biliopancreatic diversion (BPD; patient 3). All patients presented with abdominal pain and deranged liver enzymes, and imaging (magnetic resonance cholangiopancreatography or ultrasound of abdomen) confirmed presence of CBD stones in all three patients. One patient (patient 2) had concomitant cholecystitis, and one had biliary pancreatitis (patient 2). The mean age was 35 years, with male-to-female ratio of 2:1. Intraoperatively, two patients underwent LA-ERCP through isolated stomach through a 15-mm

laparoscopic trocar. Because of the previous BPD in one patient, it was not possible to use the remnant stomach for access. A laparoscopically created jejunostomy was used for retrograde access to the second part of the duodenum. A combined laparoscopic cholecystectomy was performed for the patients with cholecystitis. Sphincterotomy was performed in all three patients. Biliary cannulation was successful in all three patients. There were no endoscopic-related complications. Specifically, there were no cases of gastrointestinal bleeding, acute pancreatitis, or perforation, and no surgical complications. The mean hospital stay was approximately 2 days (Table 1).

**Table 1.**—Patient information

| Parameter                           | Value      |
|-------------------------------------|------------|
| Patients (N = 3)                    |            |
| Median age (range), years           | 35 (26–45) |
| Male:female ratio                   | 2:1        |
| Indications                         |            |
| Cholelithiasis                      | 3          |
| Cholelithiasis/biliary pancreatitis | 1          |
| Cholelithiasis/cholelithiasis       | 2          |
| Cholelithiasis/cholecystitis        | 0          |
| Timing of CCE                       |            |
| Concomitant CCE                     | 1          |
| Prior CCE                           | 1          |
| ERCP findings                       |            |
| Cholelithiasis                      | 2          |
| Sludge                              | 1          |
| Dilated CBD                         | 3          |
| Procedural course                   |            |
| Sphincterotomy                      | 3          |
| Biliary cannulation                 | 3          |
| Postprocedural course               |            |
| Gastrointestinal bleeding           | 0          |
| Pancreatitis                        | 0          |
| Perforation                         | 0          |
| Mean hospital stay, days            | 2          |

CBD: common bile duct; CCE: cholecystectomy; ERCP: endoscopic retrograde cholangiopancreatography.

## DISCUSSION

Obesity is a worldwide pandemic that affects children, adolescents, and adults. In the context, Saudi Arabia is among countries with the highest prevalence of obesity.<sup>[10]</sup> Surgery is currently the most effective way for durable weight loss in morbidly obese patients. Over the past decade, there has been an increase in the number of bariatric surgeries performed; however, it has been associated with possible early and late adverse outcomes, including biliary lithiasis.

Cholelithiasis can occur in as many as 40% of patients up to 6 months after surgery.<sup>[11]</sup> Cholelithiasis also can occur, which can be difficult to treat in patients with different forms of gastric bypass surgeries. Anatomic alterations after gastric bypass surgeries make standard duodenoscopic access to papilla technically infeasible. As a result, these patients are expected to have lower success rates of cannulation and higher rates of complications compared with ERCP in patients with unaltered anatomy.<sup>[12]</sup>

To overcome such technical difficulties, many approaches have been proposed. Some are endoscopic, like

the use of pediatric colonoscopes, or enteroscopes, some surgical, through a gastrostomy or jejunostomy tract, and some are percutaneous approaches. No single approach proved to be the best option; however, each modality has its advantages and disadvantages. Hence, each case merits its individualized approach, keeping in consideration factors like patient anatomy, the length of Roux limb, the patient's surgical risk, and the experience of the institute. ERCP using a pediatric colonoscope or enteroscope has an advantage of deep length compared with a duodenoscope; also it is less invasive compared with surgical approaches, but is frequently unsuccessful in long Roux limbs. Also, it is performed only with a forward view and lacks an elevator instrument.<sup>[13]</sup>

LA-ERCP is a surgical approach to access the biliary system. It allows using a side-viewing duodenoscope with all standard accessories by performing a temporary laparoscopic gastrostomy or jejunostomy tract; however, it is a more invasive procedure and requires careful coordination between endoscopic and surgical teams. A less invasive option is using a percutaneous approach via interventional radiology, which is a good option in poor surgical candidates. Unfortunately, this option has limitations, such as the inability to access to the pancreas and the need to maintain external drains for prolonged periods.

Evidence for LA-ERCP is largely derived from multiple case reports and case series; only a few large and comparative studies have been conducted. Abbas et al<sup>[14]</sup> reported a retrospective cohort study of adult patients with RYGB who underwent LA-ERCP in 34 centers. A total of 579 patients were included. Procedure success was achieved in 98%. The median total procedure time was 152 minutes with a median ERCP time of 40 minutes. The median hospital stay was 2 days. Adverse events were 18% (laparoscopy related, 10%; ERCP related, 7%; both, 1%).<sup>[14]</sup> One comparative retrospective cohort study was reported on balloon enteroscopy-assisted ERCP (BEA-ERCP) versus LA-ERCP in post-RYGB. It included 56 patients. LA-ERCP was superior to BEA-ERCP with regard to papilla identification (100 versus 72%), cannulation rate (100 versus 59%), and therapeutic success (100 versus 59%).<sup>[4]</sup> Considering the higher rate of procedure failure of the conventional approach, the fact that cholecystectomy is sometimes required, and that LA-ERCP does not add much to operating room time or to hospital stay compared with the laparoscopic approach alone, all of which should be considered from a cost-effectiveness point of view.

In Saudi Arabia, a few case reports have been published; however, no data were collected from case series and no comparative study was done.<sup>[15]</sup> In our case series, we report a series of three patients who underwent LA-ERCP with different anatomic alterations, but none of them had previous surgery that created adhesions. Anatomic variation gives an advantage to this study; however, the study is limited by the sample size.

Our institution's experience illustrates that LA-ERCP is a feasible procedure. There was a high success rate compared with conventional ERCP. This series also adds to the already robust data supporting LA-ERCP as a safe and highly effective therapy for patients with RYGB with a relatively shorter period of hospital stay, taking into account the limited sample size where more data are needed.

## References

1. Nguyen NT, Root J, Zainabadi K, et al. Accelerated growth of bariatric surgery with the introduction of minimally invasive surgery. *Arch Surg.* 2005;140:1198–1202; discussion 1203.
2. Shiffman ML, Sugerman HJ, Kellum JH, et al. Gallstones in patients with morbid obesity. Relationship to body weight, weight loss and gallbladder bile cholesterol solubility. *Int J Obes Relat Metab Disord.* 1993;17:153–158.
3. Shah RJ, Smolkin M, Yen R, et al. A multicenter, U.S. experience of single-balloon, double-balloon, and rotational overtube-assisted enteroscopy ERCP in patients with surgically altered pancreaticobiliary anatomy (with video). *Gastrointest Endosc.* 2013;77:593–600.
4. Schreiner MA, Chang L, Gluck M, et al. Laparoscopy-assisted versus balloon enteroscopy-assisted ERCP in bariatric post-Roux-en-Y gastric bypass patients. *Gastrointest Endosc.* 2012;75:748–756.
5. Peters M, Papasavas PK, Caushaj PF, et al. Laparoscopic transgastric endoscopic retrograde cholangiopancreatography for benign common bile duct stricture after Roux-en-Y gastric bypass. *Surg Endosc.* 2002;16:1106.
6. Mita MT, Dalmonte G, Gnocchi A, Marchesi F. Transjejunal laparoscopic-assisted ERCP in Roux-en-Y patient: the new right path. *Ann R Coll Surg Engl.* 2019;101:e45–e47.
7. Snauwaert C, Laukens P, Dillemans B, et al. Laparoscopy-assisted transgastric endoscopic retrograde cholangiopancreatography in bariatric Roux-en-Y gastric bypass patients. *Endosc Int Open.* 2015;3:E458–E463.
8. Dickinson KJ, Beckett CG, May JC, Halstead JC. A laparoscopic transgastric approach to the treatment of sphincter of Oddi dysfunction postgastric bypass. *BMJ Case Rep.* 2013;2013:bcr2012007811.
9. Bertin PM, Singh K, Arregui ME. Laparoscopic transgastric endoscopic retrograde cholangiopancreatography (ERCP) after gastric bypass: case series and a description of technique. *Surg Endosc.* 2011;25:2592–2596.
10. Al-Ghamdi S, Shubair MM, Aldiab A, et al. Prevalence of overweight and obesity based on the body mass index; a cross-sectional study in Alkharj, Saudi Arabia. *Lipids Health Dis.* 2018;17:134.
11. Shiffman ML, Sugerman HJ, Kellum JM, et al. Gallstone formation after rapid weight loss: a prospective study in patients undergoing gastric bypass surgery for treatment of morbid obesity. *Am J Gastroenterol.* 1991;86:1000–1005.
12. Hintze RE, Adler A, Veltzke W, Abou-Rebyeh H. Endoscopic access to the papilla of Vater for endoscopic retrograde cholangiopancreatography in patients with billroth II or Roux-en-Y gastrojejunostomy. *Endoscopy.* 1997;29:69–73.
13. Wright BE, Cass OW, Freeman ML. ERCP in patients with long-limb Roux-en-Y gastrojejunostomy and intact papilla. *Gastrointest Endosc.* 2002;56:225–232.
14. Abbas AM, Strong AT, Diehl DL, et al. Multicenter evaluation of the clinical utility of laparoscopy-assisted ERCP in patients with Roux-en-Y gastric bypass. *Gastrointest Endosc.* 2018;87:1031–1039.
15. Mansor SM, Abdalla SI, Bendardaf RS. Laparoscopy assisted transjejunal endoscopic retrograde cholangiography for treatment of intrahepatic duct stones in a post Roux-en-Y patient. *Saudi Med J.* 2015;36:104–107.