



# Scalp Metastasis as the First Sign of Small-Cell Lung Cancer: Management and Literature Review

Nikolaos S. Salemis<sup>1</sup>, Georgios Veloudis<sup>1</sup>, Kyriakos Spiliopoulos<sup>2</sup>, Georgios Nakos<sup>3</sup>, Nikolaos Vrizidis<sup>4</sup>, Stavros Gourgiotis<sup>1</sup>

<sup>1</sup>2nd Department of Surgery, Army General Hospital, Athens, Greece

<sup>2</sup>Department of Thoracic and Cardiovascular Surgery, University of Thessaly, Larisa, Greece

<sup>3</sup>Department of Pathology, Army General Hospital, Athens, Greece

<sup>4</sup>Department of Internal Medicine, Army General Hospital, Athens, Greece

Cutaneous metastasis from primary visceral malignancy is a relatively uncommon clinical entity, with a reported incidence ranging from 0.22% to 10% among various series. However, the presence of cutaneous metastasis as the first sign of a clinically silent visceral cancer is exceedingly rare. We describe here a case of an asymptomatic male patient who presented with a solitary scalp metastasis as the initial manifestation of an underlying small-cell lung cancer. Diagnostic evaluation revealed advanced disease. We conclude that the possibility of metastatic skin disease should always be considered in the differential diagnosis in patients with a history of smoking or lung cancer presenting with cutaneous nodules. Physicians should be aware of this rare clinical entity, and appropriate investigation should be arranged for early diagnosis and initiation of the appropriate treatment. The prognosis for most patients remains poor.

*Key words:* Small cell lung carcinoma – Scalp – Metastasis

Cutaneous metastasis from a primary visceral malignancy is a relatively uncommon clinical entity, with a reported incidence ranging from 0.22% to 10% among various series.<sup>1–10</sup> In a meta-analysis of 7 studies comprising a total of 20,380 patients, Krathen *et al*<sup>5</sup> found that the overall incidence of

Reprint requests: Nikolaos S. Salemis, MD, PhD, Consultant Surgical Oncologist, Head of Breast Cancer Surgery Unit, 19 Taxiarchon Str, 19014 Kapandriti, Athens, Greece.

Tel.: +30 22950 23559; E-mail: nikos\_salemis@hotmail.com

cutaneous metastasis was 5.3% and that the most common tumor to metastasize to the skin was breast cancer.<sup>5</sup> Cutaneous involvement may occur due to direct extension of the tumor as a local metastasis or as a distant metastasis,<sup>9</sup> and it has been associated with advanced disease and poor prognosis.<sup>3,4,11–13</sup> Half of the patients with cutaneous metastases die within the first 6 months after the diagnosis, whereas lung cancer has been associated with the poorest prognosis.<sup>14</sup> Cutaneous metastasis as the first sign of an internal malignancy is an exceedingly rare occurrence. It has been reported to occur in only 0.8% of the cases and has been associated with advanced disease.<sup>15</sup> Skin metastasis from lung cancer is a rare clinical entity that has been reported to occur in 0.22% to 12% of patients with lung cancer.<sup>1–4,6,10,15–17</sup> In most cases, metastases occur after the initial diagnosis and treatment of the primary lung tumor.<sup>17</sup> Skin metastasis as the initial manifestation of an underlying lung cancer is a very rare occurrence.<sup>4,6,16,17</sup> We describe herein an exceedingly rare case of an asymptomatic male patient who presented with a solitary scalp metastasis as the initial manifestation of an underlying small-cell lung cancer. Diagnostic evaluation and management are discussed along with a review of the literature.

### Case Presentation

A 74-year-old man presented with a 2-month history of a slowly growing, painless nodule in his right temporal region. His past medical history was significant for arterial hypertension. He was a heavy smoker but had no history of lung disease. He denied any respiratory symptoms, fever, or weight loss, and his general condition was good.

Clinical examination revealed a painless, movable, nonulcerated nodule in the right temporal region measuring approximately 2 cm in diameter. There were no signs of infection and the overlying skin was normal. A chest X-ray showed a large mass occupying the upper lobe of the left lung. Subsequent computed tomography (CT) showed a large mass involving the left upper lobe associated with extensive mediastinal lymphadenopathy. In addition, a head CT revealed 3 metastatic brain lesions.

The scalp lesion was easily resected down to the epicranial aponeurosis. Histopathologic examination and detailed immunohistochemical analysis revealed extensive infiltration from small-cell lung carcinoma (Fig. 1). Immunohistochemically, the tumor cells were strongly positive for TTF-1 and cytokeratin 8.18 and focally positive for CD56 and

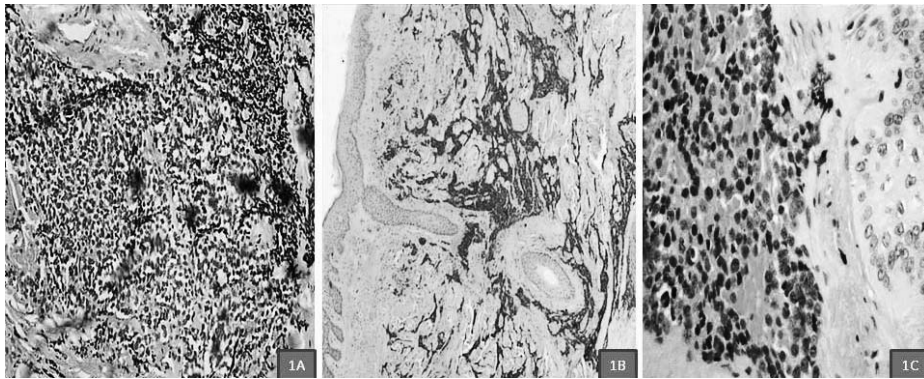
synaptophysin (Fig. 2). A CT-guided biopsy of the lung tumor confirmed the presence of a small-cell lung carcinoma, and the patient was advised to start chemotherapy and radiotherapy. Unfortunately, although he completed the first cycle of chemotherapy, he refused to continue and was subsequently lost to follow-up.

### Discussion

Scalp tumors are rare neoplasms accounting for 2% of all skin tumors. They may arise from the pilosebaceous unit, from the interfollicular epidermis, or dermis, and they may represent metastases from other tumors.<sup>10</sup> The scalp accounts for 4% to 6.9% of all cutaneous metastases and is a relatively frequent metastatic site possibly because of the abundant blood supply, immobility, and warmth of the region.<sup>5,10</sup> Chiu *et al*<sup>18</sup> reviewed the data of 398 patients with malignant scalp tumors and found that the basal and squamous cell carcinomas were the most common histologic subtypes. Metastatic tumors were found in 12.8% of the cases, and lung cancer was the most common primary tumor. Scalp metastasis as the initial manifestation of an underlying lung cancer is an exceedingly rare clinical entity.<sup>19–22</sup>

Small-cell lung cancer accounts for 10% to 15% of all lung cancers.<sup>23</sup> It is characterized by an aggressive clinical course, early systemic dissemination, and increased sensitivity to chemotherapy and radiation. Approximately two thirds of the patients have advanced-stage disease at presentation, and only 1% of these patients are alive 5 years later.<sup>23</sup> Although small-cell lung cancer is an aggressive tumor, its tendency to metastasize to the skin is very low compared to the other subtypes of lung cancer.<sup>1,3,12</sup> Hidaka *et al*<sup>16</sup> found an incidence of 2.8% of skin metastases among 579 patients with lung cancer and reported that large-cell carcinoma showed the greatest tendency for spread to the skin. In another study, Terashima and Kanazawa<sup>17</sup> reviewed the findings of 34 patients and 25 autopsies of lung cancer with skin metastases and found that the most common histologic type of cutaneous metastasis was adenocarcinoma.

Skin metastases from lung cancer most commonly occur in the chest wall, abdomen, back, and upper extremities<sup>3,6,12,16,17</sup> and do not have a pathognomonic gross appearance.<sup>13,17</sup> The lesions may have a nodular, inflammatory, or sclerodermoid morphology usually measuring 1 to 5 cm in diameter. They can be painless, movable, solitary, multiple, exuda-

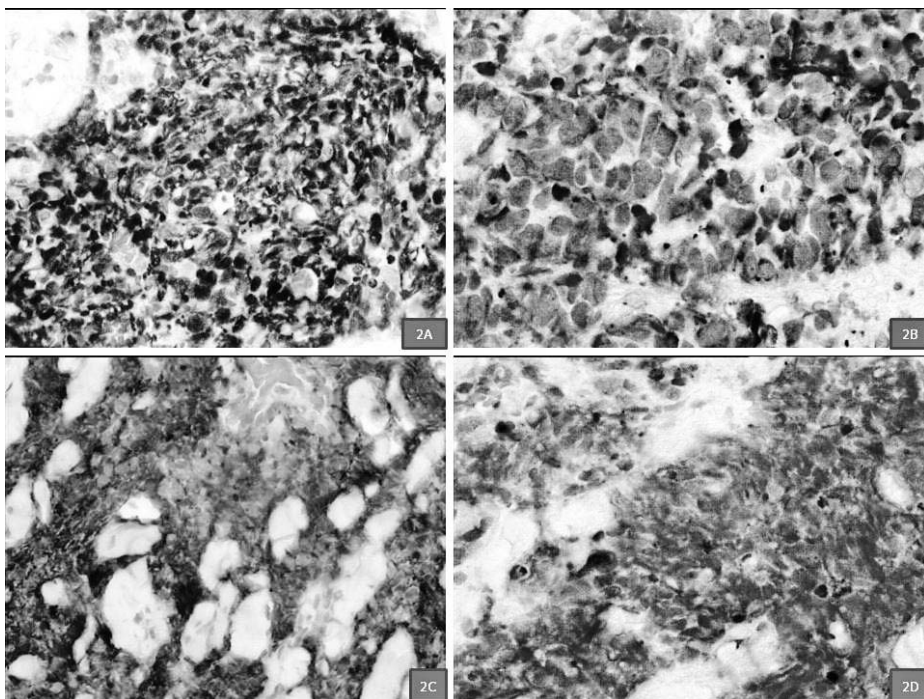


**Fig. 1** Histopathologic findings. (1A) Typical appearance of small-cell carcinoma. Small hyperchromatic nuclei and squeezing artifact [hematoxylin and eosin (H&E)  $\times 100$ ]. (1B) Whole-mount section showing large metastatic infiltration of dermis leaving surprisingly unaffected the epidermis (H&E  $\times 25$ ). (1C) Note the border between neoplastic cells (left) and the basal layer of epidermis (right; H&E  $\times 200$ ).

tive, or ulcerated with deep extension into the subcutaneous tissue.<sup>17</sup> In most cases the lesions are multiple.<sup>2,3,16</sup> In our patient, clinical presentation was very uncommon, since the solitary nodule was movable and the overlying skin was intact. Increased awareness is needed, as a similar clinical presentation can be attributed to an epidermoid or a trichilemmal cyst, especially when the patient is

completely asymptomatic. Epidermoid and trichilemmal cysts are the most common causes of solitary scalp nodules in adults.<sup>24</sup>

Metastatic skin tumors cannot be differentiated from primary skin malignancies solely on the basis of clinical findings, especially in cases presenting with ulcerated lesions. Primary skin cancer can be polymorphous in clinical presentation regarding



**Fig. 2** Immunohistochemical analysis. (2A) Strong nuclear positivity for TTF-1 (original magnification  $\times 400$ ). (2B) Diffuse cytoplasmic reactivity for cytokeratin 8/18 (original magnification  $\times 400$ ). (2C) Many of the neoplastic cells show membranous-pattern positivity for CD56 (original magnification  $\times 200$ ). (2D) Focal cytoplasmic positivity for synaptophysin (original magnification  $\times 400$ ).

tumor size, number and color of lesions, and consistency.<sup>25</sup> Hence, the differentiation of a metastatic skin lesion from a primary malignancy is made by histologic examination.<sup>25</sup>

Skin metastases from internal malignancies tend to occur at a site near the primary tumor<sup>7,13</sup> through different pathways such as lymphatic spread, hematogenous spread, and direct contiguous tissue infiltration. In this case of advanced lung cancer, hematogenous and lymphatic spread likely resulted in the development of brain and scalp lesions.

Histopathologically, skin metastases from lung cancer are often moderately to poorly differentiated. Immunohistochemical markers that may be useful in establishing the diagnosis of the primary tumor are TTF1 and CK 7/20.<sup>13</sup> However, the histologic diagnosis of the primary tumor may be challenging, especially in patients with no previous history.<sup>26</sup>

The prognosis of patients with skin metastasis from lung cancer is poor, with a reported median survival of 3 to 5 months after diagnosis.<sup>3,4,6,13,16,17</sup> In the vast majority of the cases, the patients have associated widespread metastatic disease mainly affecting bones, liver, brain, and the lungs, and the response to chemotherapy and radiotherapy is limited.<sup>3,16</sup> A slightly better prognosis has been reported in a few cases where the patients with skin metastases had no other distant lesions.<sup>17</sup> In these patients skin metastasectomy may be justified.<sup>27</sup> Apart from establishing the histologic diagnosis, surgical resection should also be considered for local palliation.<sup>11</sup> Miyazaki *et al*<sup>28</sup> reported a case of spontaneous regression of scalp metastases from lung cancer. In general, regardless of the type of primary malignancy or site of metastasis, the dissemination of an internal malignancy to the skin is associated with a poor prognosis.<sup>25</sup>

In conclusion, solitary scalp metastasis as the first sign of an occult small-cell lung cancer is an extremely rare occurrence. Despite its rarity, metastatic skin disease should always be considered in the differential diagnosis in patients with a history of smoking or lung cancer presenting with cutaneous nodules. Increased awareness of this rare clinical entity is needed for early recognition and initiation of the appropriate treatment. However, the prognosis for most patients remains poor.

## References

- Lee JH, Ahn SJ, Kim HJ, Jang SE, Noh GY, Kim HR *et al*. Cutaneous metastasis from lung cancer: a single-institution retrospective analysis. *Tuberc Respir Dis* 2011;**70**(2):139–142
- Gül U, Kiliç A, Gönül M, Külcü Cakmak S, Erinçkan C. Spectrum of cutaneous metastases in 1287 cases of internal malignancies: a study from Turkey. *Acta Derm Venereol* 2007;**87**(2):160–162
- Triller Vadnal K, Triller N, Pozek I, Kecelj P, Kosnik M. Skin metastases of lung cancer. *Acta Dermatovenereol Alp Panonica Adriat* 2008;**17**(3):125–128
- Song Z, Lin B, Shao L, Zhang Y. Cutaneous metastasis as a initial presentation in advanced non-small cell lung cancer and its poor survival prognosis. *J Cancer Res Clin Oncol* 2012;**138**(10):1613–1617
- Krathen RA, Orengo IF, Rosen T. Cutaneous metastasis: a meta-analysis of data. *South Med J* 2003;**96**(2):164–167
- Perng DW, Chen CH, Lee YC, Perng RP. Cutaneous metastasis of lung cancer: an ominous prognostic sign. *Zhonghua Yi Xue Za Zhi (Taipei)* 1996;**57**(5):343–347
- Lookingbill DP, Spangler N, Helm KF. Cutaneous metastases in patients with metastatic carcinoma: a retrospective study of 4020 patients. *J Am Acad Dermatol* 1993;**29**(2 pt 1):228–236
- Chopra R, Chhabra S, Samra SG, Thami GP, Punia RP, Mohan H. Cutaneous metastases of internal malignancies: a clinicopathologic study. *Indian J Dermatol Venereol Leprol* 2010;**76**(2): 125–131
- Lookingbill DP, Spangler N, Sexton FM. Skin involvement as the presenting sign of internal carcinoma. A retrospective study of 7316 cancer patients. *J Am Acad Dermatol* 1990;**22**(1):19–26
- Tosti A, Pazzaglia M, Piraccini BM. Scalp tumors. In: Bume-Peytani U, Tosti A, Whitting DA, Trueb R, eds. *Hair Growth and Disorders*. Berlin: Springer-Verlag, 2008:379–388
- Saeed S, Keehn CA, Morgan MB. Cutaneous metastasis: a clinical, pathological, and immunohistochemical appraisal. *J Cutan Pathol* 2004;**31**(6):419–430
- Dhambri S, Zendah I, Ayadi-Kaddour A, Adouni O, El Mezni F. Cutaneous metastasis of lung carcinoma: a retrospective study of 12 cases. *J Eur Acad Dermatol Venereol* 2011;**25**(6):722–726
- Mollet TW, Garcia CA, Koester G. Skin metastases from lung cancer. *Dermatol Online J* 2009;**15**(5):1
- Schoenlaub P, Sarraux A, Grosshans E, Heid E, Cribier B. Survival after cutaneous metastasis: a study of 200 cases. *Ann Dermatol Venereol* 2001;**128**(12):1310–1315
- Molina Garrido MJ, Guillén Ponce C, Soto Martínez JL, Martínez Y Sevilla C, Carrato Mena A. Cutaneous metastases of lung cancer. *Clin Transl Oncol* 2006;**8**(5):330–333
- Hidaka T, Ishii Y, Kitamura S. Clinical features of skin metastasis from lung cancer. *Intern Med* 1996;**35**:459–462
- Terashima T, Kanazawa M. Lung cancer with skin metastasis. *Chest* 1994;**106**:1448–1450
- Chiu CS, Lin CY, Kuo TT, Kuan YZ, Chen MJ, Ho HC *et al*. Malignant cutaneous tumors of the scalp: a study of demographic characteristics and histologic distributions of 398 Taiwanese patients. *J Am Acad Dermatol* 2007;**56**(3):448–452
- Kodama T, Satoh H, Sekizawa K. Scalp metastasis from lung cancer. *Arch Oncol* 2003;**11**(2):116

20. Loh LC, Raman S, Yusoff SM, Yaacob WAW, Kumar S. Scalp metastasis from squamous cell carcinoma of lung. *Grand Rounds* 2005;5:19–21
21. Ampil FL, Gonzalez-Toledo E, Krishnamsetty RM. Calvarial and scalp metastases: an unusual presentation of non-small-cell lung cancer. *J La State Med Soc* 2006;158(3):133–134
22. Gupta PP, Gupta KB, Gulia J, Agarwal D, Mehta D. Scalp lesion: a presenting feature of squamous cell carcinoma of lung. *J Cancer Res Ther* 2010;6(3):370–373
23. Rodriguez E, Lilenbaum RC. Small cell lung cancer: past, present, and future. *Curr Oncol Rep* 2010;12(5):327–334
24. Farley R, Manolidis S, Ratner D. Adenocarcinoma of the lung metastatic to the skull presenting as a scalp cyst. *J Am Acad Dermatol* 2006;54:916–917
25. Ortel B, Bolotin D. Cancer of the skin. In: Bope ET, Kellerman RD, eds. *Conn's Current Therapy*. Philadelphia, PA: Elsevier Saunders, 2012:201–205
26. Azoulay S, Adem C, Pelletier FL, Barete S, Francès C, Capron F. Skin metastases from unknown origin: role of immunohistochemistry in the evaluation of cutaneous metastases of carcinoma of unknown origin. *J Cutan Pathol* 2005;32(8):561–566
27. Ambrogi V, Nofroni I, Tonini G, Mineo TC. Skin metastases in lung cancer: analysis of a 10-year experience. *Oncol Rep* 2001;8(1):57–61
28. Miyazaki K, Masuko H, Satoh H, Ohtsuka M. Lung cancer with spontaneous regression of scalp metastasis. *Respiratory Medicine Extra* 2007;3(2):83–85