



Effect of Topical Tetracycline on Seroma Formation in the Lichtenstein Technique: A Prospective Randomized Study

Emin Turk¹, Erdal Karagulle¹, Gokcen Coban², Erkan Yildirim², Gokhan Moray¹

¹Department of General Surgery and ²Department of Radiology, Baskent University Faculty of Medicine, Ankara, Turkey

We sought to investigate whether application of topical tetracycline has a limiting effect on seroma formation in patients undergoing hernia repair using a polypropylene mesh. This study was conducted in 96 patients undergoing an elective groin hernia repair. Patients were randomized and divided into 2 groups. After the graft was placed, and before external oblique muscle aponeurosis was closed, 5 mL tetracycline was administered on the graft in the tetracycline group (tetra group, n = 50), and 5 mL isotonic saline was administered in the control group (n = 46) without putting in a drain. Seroma checks via surface ultrasonography were done. Seroma amounts measured on the first day were significantly higher in the tetra group ($P = 0.04$). There were no significant differences regarding seroma measurements on the seventh day or in the first and second months. Topical tetracycline application has no limiting effect on seroma formation after a groin hernia operation.

Key words: Lichtenstein technique – Polypropylene mesh – Topical tetracycline – Seroma – Ultrasonography

Hernia operations are among the most frequently performed surgical operations. Graft use to repair the defect is commonplace because graft use decreases recurrence rate, and defect closure in large abdominal hernias is easier with a mesh.¹ The most commonly used and least expensive mesh is the

polypropylene mesh. This mesh causes a foreign-body reaction where it is placed, which leads to seroma formation.² Repeat aspirations of seromas cause infection, and recurrence is seen on follow-up, especially in large hernias.² While drain use is not recommended in groin hernias, drain use in other

Corresponding author: Erdal Karagulle, MD, Baskent Universitesi Konya Hastanesi Hocacihan mah. Saray caddesi No. 1 Selcuklu, Konya 42080 Turkey.

Tel.: +900332 257 0606; Fax: +900332 257 0637; E-mail: erenka2000@hotmail.com or erdalk@mail.baskent-ank.edu.tr

Reprints will not be available from the authors.

abdominal-wall hernias is left to the physician's discretion. The biggest problem with drain use is transport of the infection by an ascending route.³

Tetracycline is an antibiotic, the solution form of which is topically used for pleurodesis in chest surgery.⁴ Some researchers also report successful topical use of its solution in seroma treatment, taking advantage of its sclerosing effect in cases with breast carcinoma.^{5,6} Tetracycline has demonstrated increased growth factor-like activity in mesothelial cells exposed to tetracycline leading to fibroblast proliferation.⁷ This study sought to investigate whether tetracycline has a reducing effect on seroma development in cases undergoing elective groin hernia repair using a polypropylene mesh.

Patients and Methods

The study was conducted according to the recommendations of the Declaration of Helsinki on Biomedical Research Involving Human Subjects. This prospective, randomized, single-blind clinical study was performed at the Baskent University, Department of General Surgery, after obtaining University Ethical Committee approval. All patients gave written, informed consent before the operation.

This study was planned in patients undergoing elective groin hernia repair between January 2011 and July 2012. The inclusion criteria were (1) being in American Society of Anesthesiologists (ASA) 1 and 2 categories upon anesthesiologic examination and (2) having a unilateral hernia. Exclusion criteria were (1) a recurrent hernia; (2) incarceration or strangulation of hernia; (3) known hypersensitivity to antibiotics and other drugs; (4) known ascites, connective tissue disease, heart/kidney failure, and hypoalbuminemia; and (5) use of aspirin or other blood thinners or anticoagulants.

A total of 147 patients were enrolled in the study. The reasons for exclusion and the number of excluded patients were as follows: 7 had an incarcerated-strangulated hernia; 14 had a recurrent hernia; 2 had known allergies to antibiotics; 6 had bilateral hernias; and 16 had known heart/kidney failure, were on aspirin or an anticoagulant, were in an ASA 3 or higher anesthesia category, or had a combination of these factors. Patients were divided into tetracycline group and control group using a computer-generated randomized sequence. This randomization procedure was completed for 102 patients. Six patients did not continue as their

own controls or did not come for their ultrasonography (USG) examinations on a regular basis. The patients were blind to which group they were assigned. As a result, 96 patients (tetra group, 50 subjects; control group, 46 subjects) came for USG examinations on a regular basis and completed the study (Fig. 1).

One hundred two patients underwent a Lichtenstein-type grafted hernia repair using a polypropylene mesh (Prolene; Ethicon GmbH, Hamburg, Germany). Before this study, we added isotonic saline of varying amounts to the graft. During the procedure, we observed that isotonic saline over 5 mL escaped via the external ring when the external oblique aponeurosis was closed. Therefore, we decided to add 5 mL fluid. After the graft was placed and before the external oblique muscle aponeurosis was closed, 5 mL tetracycline (100 mg) (tetracycline-oxytetracycline hydrochloride; BIYOKAN, Ankara, Turkey) was administered onto the graft in the tetracycline group and 5 mL isotonic saline was administered onto the graft in the control group. We applied the fluid by spraying it onto the graft area with the help of an injector. Procedures of routine operations of grafted hernia repair were used, and no drain was placed. In all operations, an inguinal incision was made parallel to the skin crease, and a dissection was performed until the external oblique muscle aponeurosis was accessed. The external oblique muscle aponeurosis was opened and dissected as far as the inguinal ligament laterally and the anterior rectus sheath anteriorly. The cord was suspended. In indirect hernias, the hernia sac was dissected until the level of neck, and a high ligation was done. In direct hernias, the hernia sac was imbricated with continuous sutures. A polypropylene mesh of adequate size for the posterior wall (approximately 7 × 15 cm) was prepared and placed in a way that its long axis would be parallel to the cord. Attention was paid so that the placed sheath would cover the whole area between the anterior rectus sheath and inguinal ligament, it would not impair cord circulation, and one-third of its entire surface area would lie at the side of the inguinal ligament and two-thirds at the side of the anterior rectus sheath. For anchoring the mesh, 2-0 polypropylene suture (Ethicon) was used. The mesh was anchored to the inguinal ligament laterally with continuous sutures, and to the anterior rectus sheath medially with individual sutures. Individual anchoring sutures were placed at the line dissected for the cord's passage. Then, the external oblique muscle aponeurosis was closed

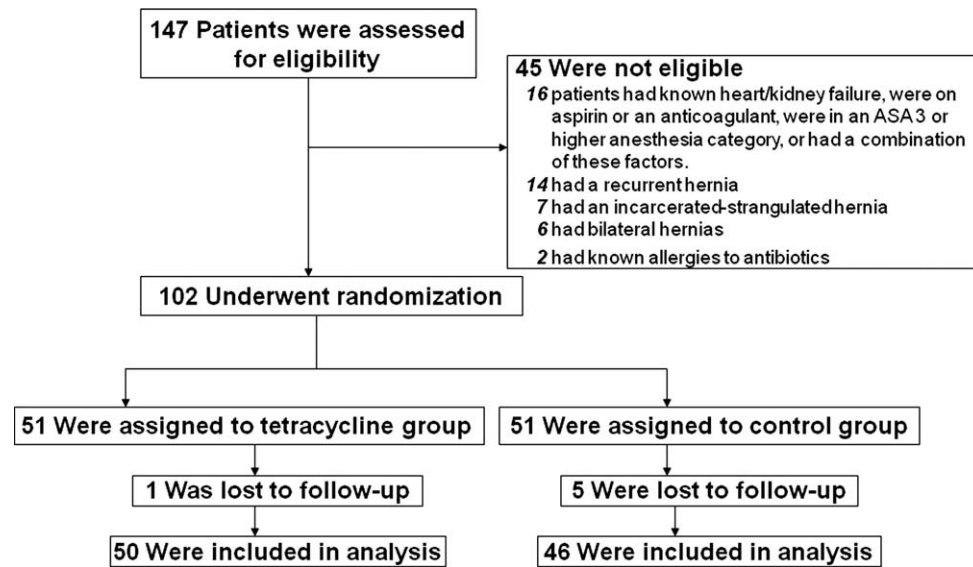


Fig. 1 Randomization of the groups.

with continuous 2-0 polyglactin 910 sutures (Vicryl; Ethicon). All of these operations were performed by the same surgeon (EK). Age, sex, body mass index, type of anesthesia used, type of hernia, operative time, and postsurgical complications were recorded in all patients. During the postsurgical period, radiologists (GC and EY), blinded to the patient groups, searched for the presence and amount of seroma with USG (13 MHz linear probe; Acuson Antares Premium Edition Ultrasound System, Siemens, Munich, Germany) on the first and seventh days, and again in the first month as well as the second and third months if a seroma was spotted at first checks. Seroma measurement was done by obtaining the length, width, and depth of the fluid and multiplying the values, giving the volume of the fluid in cubic millimeters. The units of these results were converted to milliliters. Interobserver agreements for continuous seroma measurements were calculated by random marginal agreement coefficient.⁸ All agreement coefficients in control group were higher than 0.60, and agreement coefficients for tetra group were generally over 0.60, except for the second month agreement coefficient, which was lower because of the small sample size ($n = 2$; random marginal agreement coefficient = 0.217). A surgeon completed the processes of randomization and recording of patient data on paper forms (ET). Radiologists measuring seroma were blind to the procedure, and only the operation group had the information regarding whether the patient was

given tetracycline or isotonic saline during the operation.

Statistical Analyses

The hypothesis was that using tetracycline on the groin hernia repair with polypropylene mesh would result in less seroma development during the follow-up periods. For the calculation of sample sizes, the mean difference and standard deviation of seroma after repair using a polypropylene mesh with tetracycline were accepted as 10 mL and 12 mL, respectively. A 2-sided 5% significance level and 95% power were considered. Thirty-nine participants in each group were calculated to be required. Sample-size calculations were calculated using Minitab Statistical Package Program (Release 14; Minitab, State College, PA). Statistical analyses were performed with Statistical Package for the Social Sciences software (Version 9.0; SPSS, Inc., Chicago, IL). The independent sample t test and Mann-Whitney U test were used to compare the 2 groups in pairs for all possible combinations. Numeric values were expressed as mean \pm SD. Values for $P < 0.05$ were considered statistically significant.

Results

All patients were operated on after receiving spinal anesthesia, and no postsurgical early complications

Table 1 Comparison of demographic, operational, and postsurgical ultrasonographic data of the patients^a

	Group tetra (n = 50)	Group control (n = 46)	P value
Male/female	46/4	43/3	0.43
Age, y*	55.8 ± 15.4 (25–74)	51.5 ± 13.1 (22–74)	0.33
Body mass index, kg/m ² *	33.8 ± 4.7 (22.3–44.6)	35.1 ± 4.1 (29.4–41.4)	0.32
Duration of operation, min*	56.2 ± 12.4	53.5 ± 15.4	0.43
Duration of hernia, mo*	21.9 ± 22.1 (2–62)	18.8 ± 19.2 (3–60)	0.68
Type of hernia			
Direct	16	15	0.76
Indirect	24	23	0.69
Combined	10	8	0.42
USG on the first day			
Seroma + number of patients, %	27 (54%)	15 (32%)	0.02
Amount of seroma, mL*	15.6 ± 4.4	10 ± 3.8	0.04
USG on the seventh day			
Seroma + number of patients, %	30 (60%)	24 (52%)	0.21
Amount of seroma, mL*	82.5 ± 19	109.6 ± 26.7	0.68
USG at the first month			
Seroma + number of patients, %	10 (20%)	9 (19%)	0.91
Amount of seroma, mL*	20.8 ± 6	12.4 ± 4.1	0.64
USG at the second month			
Seroma + number of patients, %	2 (4%)	3 (6%)	0.27
Amount of seroma, mL*	0.07 ± 0.02	0.05 ± 0.02	0.74

^aValues are mean ± standard deviation.

developed in any patient. There were no statistically significant differences between the 2 groups regarding patient characteristics and general operative outcomes (Table 1). Comparison of the number of patients diagnosed with seroma in each group revealed that the number of patients diagnosed with seroma was significantly higher in the tetra group on the first day ($P = 0.02$), whereas the groups were similar on the seventh day and in the first and second months (Table 1).

During the second month, seroma formation was seen in 3 patients in the control group and 2 patients in the tetra group. No seroma was seen in these patients during the third month. The amount of seroma on the first day in the tetra group was significantly greater ($P = 0.04$). There were no significant differences regarding seroma measurements at the seventh day or in the first and second months ($P = 0.68$, $P = 0.64$, and $P = 0.74$).

Discussion

The description of the Lichtenstein tension-free mesh repair, about 23 years ago, opened a new era in groin hernia repair.⁹ The method is simple, effective, and is associated with low recurrence rates (ranging from 0% to 0.7%).¹ Owing to these advantages, it is the preferred method for reconstructing groin hernias for most surgeons worldwide.

Several prosthetic meshes are available to the surgeon. The ideal mesh properties include inertness, resistance to infection, molecular permeability, pliability, transparency, mechanical integrity, and biocompatibility. Absorbable meshes do not remain in the wound long enough for adequate collagen to be deposited, while multifilament meshes can harbor bacteria. Monofilament mesh is the most popular today, with various types of polypropylene having different advantages.¹⁰ Use of porous mesh (polypropylene) allows a large surface area for in growth of connective tissue, leading to permanent fixation of the prosthesis in the abdominal wall. Intraparietal placement of the prosthesis allows well-vascularized tissue coverage of all aspects of the prosthesis. Fears of complications related to mesh implantation have proved unjustified. Prosthetic materials implanted in these spaces create exaggerated seromas as a result of irritation and following serum leakage.¹¹ Especially in incisional hernias, seroma and prolonged drainage are frequently reported.¹² When the mesh is used to repair large and more complex incisional hernias, the risk of seroma formation increases. Using the mesh onlay technique, which requires more-extensive dissection, is associated with an even greater incidence of seroma formation.¹³ Previously reported rates of seroma occurrence with different types of mesh range from 4% to 8% with polypropylene grafts (Prolene, Marlex) and 5% to 15% with

expanded polytetrafluoroethylene grafts (Gore-Tex).¹⁴ In most instances, these seromas resolve either spontaneously or with the insertion of drains or serial percutaneous aspirations. However, indication for suction drainage differs among investigators.³

Topical sclerotherapy with tetracycline has long been used successfully to treat malignant pleural effusions to cause obliteration of the pleural space.⁴ Two reports suggest the effectiveness of tetracycline, a topical sclerosing agent, in treating postoperative wound seromas in mastectomy patients.^{5,6} Topical tetracycline has been used to treat hydrocele testis,¹⁵ endometrial cysts,¹⁶ hepatic cysts,¹⁷ pericardial effusions,¹⁸ and the gallbladder lumen.¹⁹

We determined groin hernias as a prototype during the planning phase. Our main aim was to use tetracycline to decrease/prevent seroma from developing in large abdominal wall hernias repaired with polypropylene mesh. In abdominal hernia repair, a potential tissue space naturally occurs behind the dissected area created by the hernia mass. Fluid collection in this pouch gives a surgeon pause as to whether it is a complication or a natural process of healing.^{11,12,20} The character of this postoperative mass in the previous hernia region cannot be discriminated with physical examination alone. In our prospective study, USG was used to detect and follow the nature of this fluid collection in the hernia site. Resorption time was reported. Post and associates²¹ performed Lichtenstein repair, and presence of the seroma was checked by USG and accepted as a fluid collection greater than 10 mL; these authors reported a seroma rate of 35% on the second postoperative day, and 1.7% during the sixth month. Another study reported the rate of seroma as 5.8% on the seventh day and 7.8% during the first month.²² In laparoscopic inguinal hernia repairs, the duration of the seromas generally was reported as 2 months, and 80% of them disappeared by the end of the third month.^{11,23} One study by Susmallian and associates¹² demonstrated the presence of seroma in 100% of patients evaluated with USG. The peak of seroma formation occurred 7 days after the laparoscopic ventral hernia repair and resolved almost completely by 90 days. Consistent with the literature, the number of the patients with seroma on the first and seventh days after surgery was high in both groups. Beginning from the first month, however, seroma was completely cleared away by the third month. The reason more patients were diagnosed with seroma in this study compared

with the literature was thought to be that we detected the seroma not only on physical examination but also on USG, which is a more sensitive radiologic technique. We also thought that the high amount of seroma on the first day after the surgery may be because both tetracycline and isotonic saline were placed on the graft during the operation. Since tetracycline absorption is slower than isotonic saline, on the postoperative first day we found statistically significant differences between the groups.

In conclusion, we found no beneficial effect of using topical tetracycline on seroma development in grafted hernia repair. In addition, seroma development should be expected, especially in the first week after grafted hernia surgery, and it disappears by the third month.

Acknowledgments

This study was approved by Baskent University Institutional Review Board and supported by Baskent University Research Fund. Baskent University Ethical Committee approval number is KA09/405.

References

1. Sakorafas GH, Halikias I, Nissotakis C, Kotsifopoulos N, Stavrou A, Antonopoulos C *et al*. Open tension free repair of inguinal hernias; the Lichtenstein technique. *BMC Surg* 2001;1:3. <http://www.biomedcentral.com/1471-2482/1/3>. Accessed October 15, 2001.
2. Fitzgibbons RJ, Filipi CJ, Quinn TH. Groin hernias. In: Brunicki FC, Andersen DK, Billiar TR, Dunn DL, Hunter JG, Pollock RE, eds. *Schwartz's Principles of Surgery*. 8th ed. New York, NY: McGraw-Hill, 2005:1387-1388
3. Gurusamy KS, Allen VB, Samraj K. Wound drains after incisional hernia repair. *Cochrane Database Syst Rev* 2012 Feb 15;2:CD005570. <http://onlinelibrary.wiley.com/o/cochrane/clabout/articles/WOUNDS/frame.html>. Accessed Feb 15, 2012.
4. Kilic D, Akay H, Kavukcu S, Kutlay H, Cangir AK, Enön S *et al*. Management of recurrent malignant pleural effusion with chemical pleurodesis. *Surg Today* 2005;35(8):634-638
5. Sitzmann JV, Dufresne C, Zuidema GD. The use of sclerotherapy for treatment of postmastectomy wound seromas. *Surgery* 1983;93(2):345-347
6. Nichter LS, Morgan RF, Dufresne CR, Lambruschi P, Edgerton MT. Rapid management of persistent seromas by sclerotherapy. *Ann Plast Surg* 1983;11(3):233-236

7. Antunes G, Neville E, Duffy J, Ali N; Pleural Diseases Group, Standards of Care Committee, British Thoracic Society. BTS guidelines for the management of malignant pleural effusions. *Thorax* 2003;**58**(suppl 2):ii29–38.
8. Fay MP, Lee JH. Measuring agreement between two statistics with applications to age standardization. *J R Stat Soc Ser A Stat Soc* 2006;**169**(1):81–96
9. Lichtenstein IL, Shulman AG, Amid PK, Montllor MM. The tension-free hernioplasty. *Am J Surg* 1989;**157**(2):188–193
10. Goldstein HS. Selecting the right mesh. *Hernia* 1999;**3**(1):23–26
11. Cihan A, Ozdemir H, Uçan BH, Acun Z, Comert M, Tascilar O *et al*. Fade or fate: seroma in laparoscopic inguinal hernia repair. *Surg Endosc* 2006;**20**(2):325–328
12. Susmallian S, Gewurtz G, Ezri T, Charuzi I. Seroma after laparoscopic repair of hernia with PTFE patch: is it really a complication? *Hernia* 2001;**5**(3):139–141
13. White TJ, Santos MC, Thompson JS. Factors affecting wound complications in repair of ventral hernias. *Am Surg* 1998;**64**(3):276–280
14. Lehr SC, Schuricht AL. A minimally invasive approach for treating postoperative seromas after incisional hernia repair. *J SLS* 2001;**5**(3):267–271
15. Breda G, Giunta A, Gherardi L, Xausa D, Silvestre P, Tamai A. Treatment of hydrocele: randomised prospective study of simple aspiration and sclerotherapy with tetracycline. *Br J Urol* 1992;**70**(1):76–77
16. Chang CC, Lee HF, Tsai HD, Lo HY. Sclerotherapy—an adjuvant therapy to endometriosis. *Int J Gynaecol Obstet* 1997;**59**(1):31–34
17. Davies CW, McIntyre AS. Treatment of a symptomatic hepatic cyst by tetracycline hydrochloride instillation sclerosis. *Eur J Gastroenterol Hepatol* 1996;**8**(2):173–175
18. Celermajer DS, Boyer MJ, Bailey BP, Tattersall MH. Pericardiocentesis for symptomatic malignant pericardial effusion: a study of 36 patients. *Med J Aust* 1991;**154**(1):19–22
19. el-Mufti M. Sclerotherapy of the human gallbladder using ethanol and tetracycline hydrochloride. *Br J Surg* 1993;**80**(7):916
20. Kapiris SA, Brough WA, Royston CM, O'Boyle C, Sedman PC. Laparoscopic transabdominal preperitoneal (TAPP) hernia repair: a 7-year two-center experience in 3017 patients. *Surg Endosc* 2001;**15**(9):972–975
21. Post S, Weiss B, Willer M, Neufang T, Lorenz D. Randomized clinical trial of lightweight composite mesh for Lichtenstein groin hernia repair. *Br J Surg* 2004;**91**(1):44–48
22. Szopinski J, Dabrowiecki S, Pierscinski S, Jackowski M, Jaworski M, Szuflet Z. Desarda versus Lichtenstein technique for primary inguinal hernia treatment: 3-year results of a randomized clinical trial. *World J Surg* 2012;**36**(5):984–992
23. Lau H, Lee F. Seroma following endoscopic extraperitoneal inguinal hernioplasty. *Surg Endosc* 2003;**17**(11):1773–1777