

International Surgery

Traumatic Pulmonary Herniation: A Conservative Approach

--Manuscript Draft--

Manuscript Number:	INTSURG-D-23-00001R1
Full Title:	Traumatic Pulmonary Herniation: A Conservative Approach
Article Type:	Case Report
Keywords:	Traumatic Pulmonary Herniation; Hernia; Chest Wall Trauma; Case Report; Conservative Management
Corresponding Author:	Alexandra Tara Close University of Maryland College Park, UNITED STATES
Corresponding Author Secondary Information:	
Corresponding Author's Institution:	University of Maryland
Corresponding Author's Secondary Institution:	
First Author:	Alexandra Tara Close
First Author Secondary Information:	
Order of Authors:	Alexandra Tara Close Tyler Kingma, DO Maaria Chaudhry, BS Bilal Chaudhry, MD Alekseyev Kirill, MD, M.B.A.
Order of Authors Secondary Information:	
Abstract:	Pulmonary herniation is an uncommon but potentially dangerous complication of chest wall trauma. We present a 60-year-old female who presented to the hospital after blunt chest wall trauma resulting in thoracic pulmonary herniation. A majority of cases have historically been treated surgically, though this patient achieved spontaneous reduction of lung tissue after chest tube placement without recurrence. This report evaluates the elements of pulmonary herniation and highlights the need for defined guidelines in treatment of this condition.

TRAUMATIC PULMONARY HERNIATION

Traumatic Pulmonary Herniation: A Conservative Approach

By

Alexandra Close, BS², and Tyler Kingma, DO,
Maaria Chaudhry, MS³, and Bilal Chaudhry, MD,
Kirill Alekseyev, MD

Pulmonary Herniation: A Conservative Approach

Abstract:

Pulmonary herniation is an uncommon but potentially dangerous complication of chest wall trauma. We present a 60-year-old female who presented to the hospital after blunt chest wall trauma resulting in thoracic pulmonary herniation. A majority of cases have historically been treated surgically, though this patient achieved spontaneous reduction of lung tissue after chest tube placement without recurrence. This report evaluates the elements of pulmonary herniation and highlights the need for defined guidelines in treatment of this condition.

INTRODUCTION

We report here a case of a right traumatic pulmonary herniation with associated hemopneumothorax that was successfully managed conservatively. Chest wall injury is a common outcome in blunt thoracic trauma. Most commonly, it results in soft tissue trauma, rib fractures, and internal organ injury depending on the severity. Rib fractures at multiple locations can be associated with several conditions, including herniation of the lung parenchyma. Intercostal pulmonary herniation is a rare condition first accurately described as a protrusion of the lung through an abnormal opening in the chest wall by Roland in 1499 and was further classified by Morel-Lavallee in 1847 by differentiating by both etiology and location as reported by literature. According to etiology, about 18% of cases are congenital in nature, while about 82% of cases are acquired from traumatic (50-57%), spontaneous (20-32%), or pathologic (0-3%) etiologies [1,2]. Classification by location is divided into cervical, thoracic, and diaphragmatic. Thoracic herniation is the most common (70-80%) while diaphragmatic herniations are exceedingly rare [1,2]. Within the thoracic region, herniation is often anteriorly in the lower intercostal spaces. This is due to the anatomically decreased muscular support in this region along with greater spacing of the lower costal cartilages in comparison to the superior, posterior, and lateral chest wall [3].

CASE REPORT

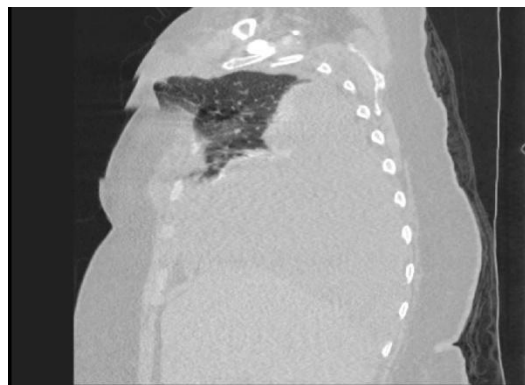


Fig. 1. CT Scan of Thoracic Pulmonary Herniation

A 60-year-old female with a history of obesity and hyperlipidemia presented to the emergency department after a head-on motor vehicle accident, where the patient was the restrained driver. On arrival, the patient's oxygen saturation was 91% on a 6 L nasal cannula. She was afebrile and normotensive with an elevated respiratory rate. On exam, there were obvious fractures of the femur and ribs with chest wall deformity appreciable on inspiration as well as associated tachypnea. CT imaging revealed an intercostal pulmonary herniation between right ribs one through three with a large hemopneumothorax. While a wide pore approach could have been taken, it was surgical preference to do a CT guided catheter insertion between the 4th and 5th intercostal space along the midaxillary line. She underwent a CT guided catheter insertion with 4.4 liters of blood drained with subsequent improvement in pulmonary herniation and O₂ saturation stabilizing at >93%. As per thoracentesis protocol, the patient was volume resuscitated with 2 liters of lactated ringers and two units of packed red blood cells. The patient demonstrated hemodynamic stability without recurrence of the hernia over the next seven days before the chest tube was removed. Pulmonary toileting measures with incentive spirometry were conducted in order to prevent development of atelectasis. No surgical intervention was taken for the rib fractures. The patient was subsequently discharged to an acute rehabilitation center where they resided for 14 days before returning home. The patient made a full recovery.

DISCUSSION

Traumatic herniations as shown in the case above are most often caused by blunt trauma to the thorax through a combination of increased intrathoracic pressure and anatomical weakness of the chest wall (rib fractures or intercostal muscle damage). A smaller percentage of these cases develop postoperatively or from penetrating trauma. Although a majority of cases present immediately after the inciting event, traumatic herniations can develop years after the original blunt trauma occurred. This was shown in the case study by Detorakis et al. in which a lung hernia only presented after vigorous coughing eight years after thoracic motor vehicle trauma [4]. Spontaneous herniations form in a similar fashion to traumatic herniation with an abrupt increase in intrathoracic pressure resulting in some form of damage to the chest wall. This is most commonly seen in coughing, sneezing, playing musical instruments, or strenuous lifting. Patients with chronic obstructive pulmonary disease (COPD) and obesity are at the highest risk given chronically elevated intrathoracic pressures [5].

Pulmonary herniation can be asymptomatic in uncomplicated cases, but classically presents with dyspnea and chest pain. Pain is typically worse with inhalation, cough, or sneeze likely as a result of parietal pleura irritation. On exam a soft, fluctuant, subcutaneous mass is often palpable on the chest wall with paradoxical motion. These masses will increase in size with coughing and Valsalva maneuver [6]. In traumatic cases, there is commonly evidence of rib fractures, chest wall ecchymosis, and even flail chest in severe cases [7].

Given the variation in symptomatology and differential diagnosis, imaging is often used to clarify the etiology. Initial evaluation with chest radiograph may show a non-specific radiolucent area in the chest wall especially if doing Valsalva maneuver. However, this modality is imperfect

and may not show an abnormality if the x-ray beam is at a poor angle in relation to the hernia [4,8]. Computed tomography effectively demonstrates the lung parenchyma protruding through a defect in the chest wall making it the most accurate modality of imaging for diagnosis of pulmonary hernia. As imaging techniques have advanced, multiplanar reconstruction imaging, maximum/minimum intensity projection images, and volume rendered three-dimensional reconstructions have become an important tool in defining severity, determining management, and surgical planning [4]. When CT is unavailable or avoidance of radiation is preferred, chest ultrasound can be used. Hernias will show as hyperechoic lesions with absence of the hyperechogenic pleural line within the intercostal space [4,9].

There is no standard management for pulmonary herniation though the consensus across the literature is that large/symptomatic herniations at risk for strangulation/incarceration should be managed surgically within the first few days. Conservative management in these cases via thoracic strapping has been abandoned secondary to the increased risk of atelectasis and infection due to restricted pulmonary compliance [6]. Historically, most surgical repairs were performed via thoracotomy though there is growing evidence that a total versus hybrid approach with thoracoscopic assist could result in improved post-operative outcomes, though further research needs to be performed in this area [10,11]. Large defects often require reconstruction of the chest wall while smaller defects can be repaired with pericostal sutures [10]. Clinical judgment and experience are required to determine which approach is appropriate as there is no defined treatment algorithm or hernia size cutoff.

For minor or asymptomatic cases, a conservative or nonsurgical approach has been argued to be clinically indicated. In the context of a hemothorax in our patient, a chest tube was placed resulting in decreased intrathoracic pressure and spontaneous reduction of the lung parenchyma. After correction of the malformation, the chest wall approximated and was allowed to heal with supportive measures, monitoring of oxygen saturation, and repeat imaging. This treatment approach was felt to be indicated given clinical stability of the patient, lack of evidence of strangulation, improvement after intervention, and no evidence of recurrence. In a case discussed by Bikhchandani et al. a similar approach to management was taken, again demonstrating the value in conservative management with chest tube in a patient with evidence of hemothorax/pneumothorax and no clear indications for immediate operation [12].

Summary

In this case, the patient presented with a traumatic lung hernia as demonstrated on physical exam and CT imaging. The patient was successfully treated with a chest tube and frequent monitoring. This case demonstrates the success that can be achieved in certain patient populations with conservative management techniques. The indications for surgical versus conservative management of this condition needs to be further evaluated. We suggest that with defined treatment criteria, fewer patients would require surgical intervention for the treatment of lung herniation.

References

1. Hiscoe DB, Digman GJ. Types and incidence of lung hernias. *Journal of Thoracic Surgery*. 1955;30(3):335-342. doi:10.1016/s0096-5588(20)30630-9
2. Morel-Lavallée A. Hernies Du poumon. *Bull Soc Chir Paris 1845–1847*;1:75–195.
3. Wightman CF. Report of a Case of Hernia of the Lung, with Remarks. *Br Med J*. 1898;1(1936):365-366. doi:10.1136/bmj.1.1936.365
4. Detorakis EE, Androulidakis E. Intercostal lung herniation--the role of imaging. *J Radiol Case Rep*. 2014;8(4):16-24. Published 2014 Apr 1.10.3941/jrcr.v8i4.1606
5. Goverde P, Van Schil P, Van den Brande F, Vanmaele R. Chronic herniation of the lung in a patient with chronic obstructive pulmonary disease. Case report and review of the literature. *Thorac Cardiovasc Surg*. 1998;46(3):164-166. doi:10.1055/s-2007-1010219
6. Wani AS, Kalamkar P, Alhassan S, Farrell MJ. Spontaneous intercostal lung herniation complicated by rib fractures: A therapeutic dilemma. *Oxford Medical Case Reports*. 2015;2015(12):378-381. doi:10.1093/omcr/omv069
7. Scelfo C, Longo C, Aiello M, Bertorelli G, Crisafulli E, Chetta A. Pulmonary hernia: Case report and review of the literature. *Respirology Case Reports*. 2018;6(8). doi:10.1002/rcr2.354
8. Bhalla M, Leitman BS, Forcade C, Stern E, Naidich DP, McCauley DI. Lung hernia: Radiographic features. *American Journal of Roentgenology*. 1990;154(1):51-53. doi:10.2214/ajr.154.1.2104725
9. Gordon R, Karfunkle B, Smith H, Larimore K, Turgiss K, Najeemuddin S. B- lines beyond the thoracic cavity - ultrasound identification of intercostal pulmonary hernia. *Journal of Clinical Ultrasound*. 2021;50(1):101-105. doi:10.1002/jcu.23035
10. Chiang T-Y, Yin M-F, Yang S-M, Chen K-C. Thoracoscopic management of incarcerated lung herniation after Blunt Chest Trauma: A case report and literature review. *Journal of Thoracic Disease*. 2017;9(3). doi:10.21037/jtd.2017.03.41
11. Khalil MW, Masala N, Waller DA, Cardillo G. Surgical repair of post-traumatic lung hernia using a video-assisted Open technique. *Interactive CardioVascular and Thoracic Surgery*. 2008;7(3):506-507. doi:10.1510/icvts.2007.168658
12. Bikhchandani J, Balters MW, Sugimoto JT. Conservative management of traumatic lung hernia. *The Annals of Thoracic Surgery*. 2012;93(3):992-994. doi:10.1016/j.athoracsur.2011.08.023