

# Is myocutaneous flap alone sufficient for reconstruction of chest wall osteoradionecrosis?

Mohamed Makboul<sup>a,\*</sup> and Mohamed A.K. Salama Ayyad<sup>b</sup>

<sup>a</sup> Department of Plastic and Reconstruction Surgery, Faculty of Medicine, Assiut University, Assiut, Egypt

<sup>b</sup> Department of Cardio-Thoracic Surgery, Faculty of Medicine, Assiut University, Assiut, Egypt

\* Corresponding author. Department of Plastic Surgery, Assiut University Hospital, Assiut 71526, Egypt. Tel: +2-0100-1862263; fax: +2-088-2333327; e-mail: plasticconsult@gmail.com (M. Makboul).

Received 24 December 2011; received in revised form 28 February 2012; accepted 13 March 2012

## Abstract

**OBJECTIVES:** This study was carried out to determine whether the myocutaneous flap, alone, is sufficient to reconstruct a chest wall defect after osteoradionecrosis and provide satisfactory stability to the chest wall.

**METHODS:** This study involved five patients who were subjected to post-mastectomy radiotherapy as a treatment for breast cancer. Excision of the ulcer and all the necrotic ribs, with preservation of the parietal pleura and reconstruction with the latissimus dorsi flap, was done without the use of either an artificial prosthesis or autologous rib to reconstruct the chest wall defect.

**RESULTS:** Clinical and radiological follow-up showed no complications regarding respiratory impairment or pleural complications.

**CONCLUSIONS:** The use of myocutaneous flap in patients with chest wall defect following osteoradionecrosis is satisfactory to cover the chest wall defect and provide satisfactory stability to the chest wall.

**Keywords:** Osteoradionecrosis • Chest wall reconstruction • Latissimus dorsi flap

## INTRODUCTION

In the treatment of primary, recurrent, and unresectable chest wall malignancies (e.g. breast, lung and chest wall tumours deeply infiltrating skin tumours), chest wall irradiation is useful and essential [1]. Osteoradionecrosis (ORN) is a severe complication of radiation therapy in patients with breast and lung cancers. ORN was more frequent in the era when radiotherapy was carried out using conventional techniques and ortho-voltage devices, but is now less commonly witnessed, due to the use of modern devices in radiation therapy and better-planned treatment regimens [2, 3].

The main consideration in the planning of reconstructive surgery is the potential to reconstruct and close the defect in the chest wall after resection. The basic question to be answered, in preoperative planning of the extent of resection and reconstruction, is the normality of breathing after surgery and appropriate protection of the intrathoracic organs [4].

Restoration of the radiation-injured chest wall often requires significant dismantling of the manubrioclavicular/sternocostal framework, leaving the patient with a substantial flail. Reconstruction of support structures may well be a surgical imperative for survival. A surface-only mentality in chest wall repair could spell disaster for the patient. In the past decade, reconstruction of the chest wall and the breast has advanced remarkably because of muscle and musculocutaneous transposition flaps [5].

Numerous parameters should be taken into account when planning the chest wall reconstruction, such as the site, size, type and extent of the lesion, wall invasion (superficial or to full

depth), local tissue status (postirradiation changes, necrosis, infection, residual tumour, scar), general patient's status, chronic diseases, prior treatment (corticosteroids and/or chemotherapy) and prognosis [6–8].

The aim of this work was to learn if the myocutaneous flap on its own is sufficient to reconstruct the chest wall defect after ORN and to provide satisfactory stability to the chest wall.

## MATERIALS AND METHODS

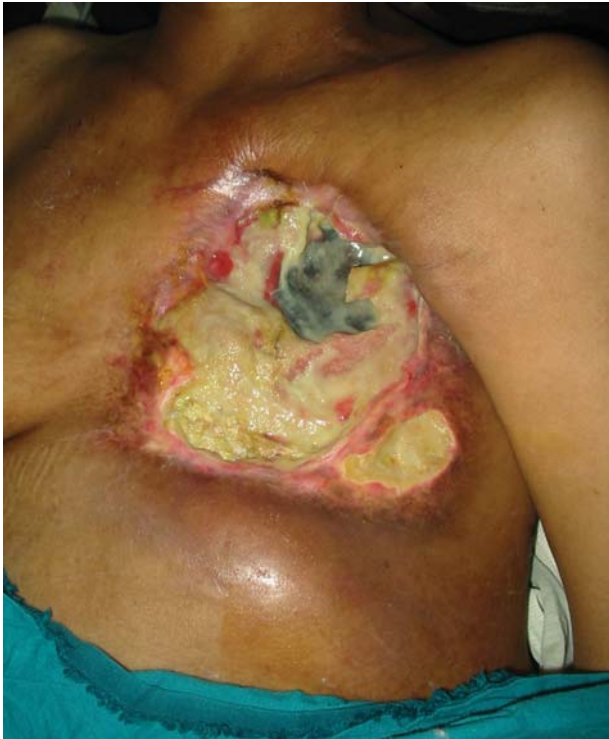This study involved five patients who were subjected to post-mastectomy radiotherapy as a treatment for breast cancer. These patients were presented to our facility in Assiut University Hospital, Assiut, Egypt, as a result of unhealed ulceration of the chest wall (Fig. 1).

Despite regular, daily dressing, none of the patients showed any improvement in terms of infection and signs of healing.

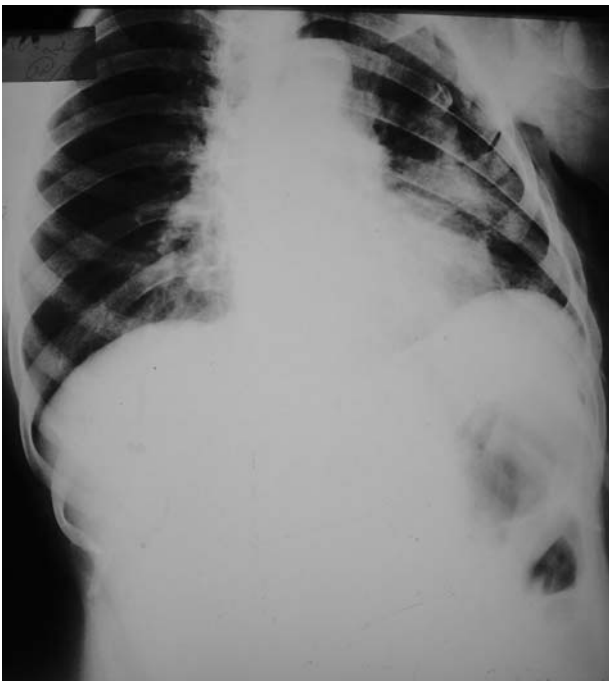
Histopathological examination showed chronic inflammatory cells without evidence of malignancy. Chest X-ray showed rib necrosis, while CT scan of the chest confirmed the absence of any intrathoracic lesions and showed necrosis of the ribs with normal sternum density (Fig. 2). CT scan showed also thickening of the pleura, which is mostly attributed to the radiotherapy and the chronicity of the ulcer (Fig. 3).

Daily dressing was carried out with antibiotic irrigation, according to the culture and sensitivity test taken from the ulcer, for two weeks until infection had subsided.

Preoperative laboratory investigations were done and patients were scheduled for operative management.



**Figure 1:** Post-radiation chronic ulcer of the left side of the chest (15 × 15 cm in dimensions) with rib necrosis and intact pleura. (Notice that the lung is expanded.)



**Figure 2:** Chest X-ray shows absence of any intrathoracic lesions, necrosis of the ribs with normal sternum density and expanded lungs.

### Operative techniques

With the patient in a supine position and under general anaesthesia, the ulcer was excised until a healthy margin was reached and all the necrotic ribs were excised with special precautions to leave the thickened parietal pleura intact (Fig. 4).

The patient was moved into lateral decubitus position and a pad was placed between the shoulder and the neck on the contralateral side, to harvest the latissimus dorsi flap to cover the defect.

A skin monitor was left over the latissimus dorsi flap to assess the flap vascularity postoperatively. The donor site was closed using subcutaneous 2/0 Vicryl sutures, a suction drain was inserted and skin closure effected with simple 4/0 Vicryl sutures.

The patient was returned to the original supine position and the flap was rotated to cover the chest wall defect and covered with split-thickness skin graft (Fig. 5). Tie-over dressing was applied to the skin graft, which was removed one week postoperatively.

All the patients were admitted to intermediate care unit with special attention to the pulse oxymetry to detect any respiratory impairment and hypoxia, and to monitor flap viability.

Follow-up chest X-rays were taken in the first postoperative day and 48 h later, to assess lung expansion.

### RESULTS

All five patients recovered smoothly, with extubation of the endotracheal tube in the operating theatre and no need for postoperative mechanical ventilation as indicated by pulse oxymetry and clinical examination of the patient. The patients were transported to intermediate care and all were closely observed 48 h postoperatively for respiratory movement, signs of respiratory distress, restlessness, signs of air hunger, irritability and pulse oxymetry: all the latter criteria proved satisfactory with no need for further action.

Immediate postoperative chest X-ray of the patients showed no evidence of pneumo- or haemothorax, as we did not introduce a chest tube from the start and kept the pleura intact (Fig. 6).

Follow-up chest X-ray after 48 h showed the same results (Fig. 7).

Complete flap viability was achieved, with 100% graft take (Fig. 8) except in one case, in which there was partial skin graft loss: this was managed by conservative manoeuvres through daily dressing, which was enough for wound healing with secondary intention.

Chest wall movement showed a slight movement of the flap. The flap movement disappeared completely two months postoperatively. This slight movement of the flap did not affect respiration at all and the patient did not need any further treatment. Six-month late follow-up of the patients showed the same results and no effect on respiration.

### DISCUSSION

Radiation therapy is an important treatment, providing local control in the multidisciplinary treatment of breast cancer [9–11].

Unless radiotherapy is performed with modern systems and techniques, thorax wall necrosis, ulceration on skin, brachial plexopathy, cardiac morbidity/mortality, secondary cancer, pneumonitis, oedema of the arms and costal fracture may be encountered [12–14]. Despite many developments in radiotherapy, ORN—although now rare—may still also be seen [15].

In our cases we used neither a prosthesis nor autologous rib to reconstruct the chest wall defect after excision of the infected,

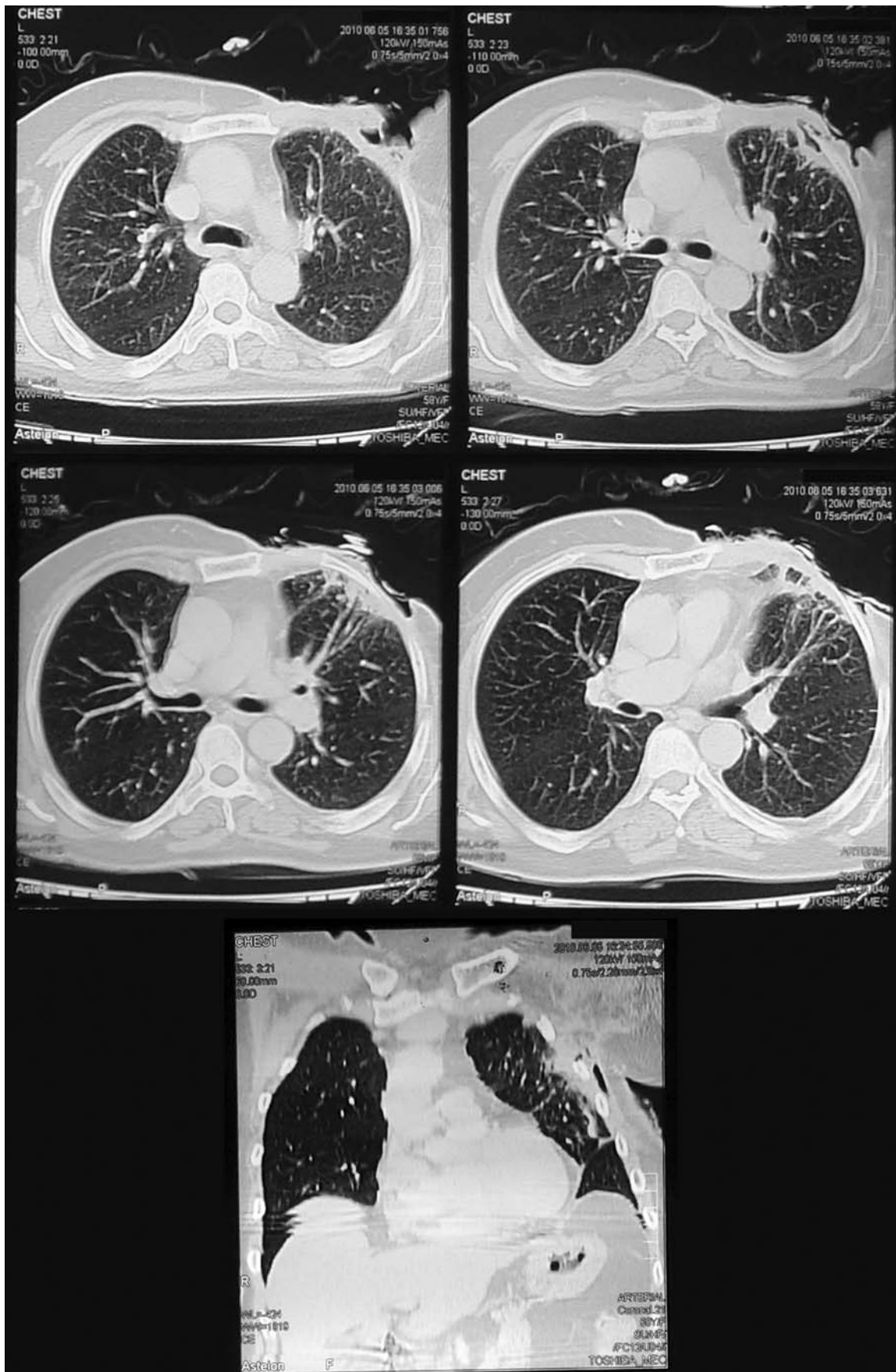
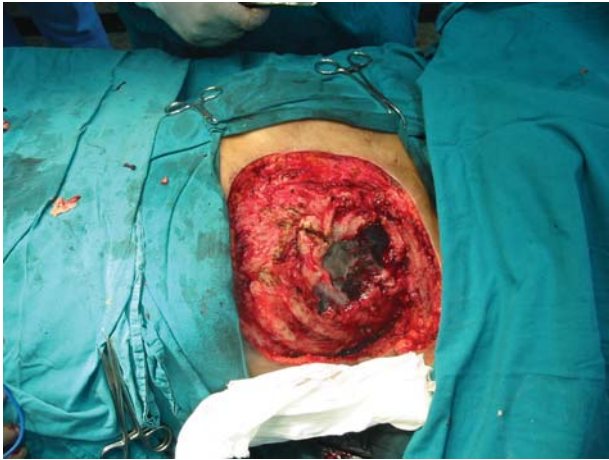
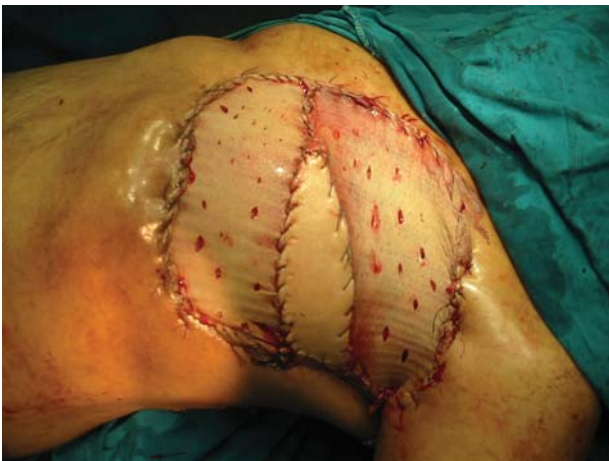
Figure 3: CT scan of chest shows absence of any intrathoracic lesions, necrosis of the ribs with normal sternum density, expanded lungs and thickened pleura.



**Figure 4:** Intraoperative photo shows excision of the ulcer and all the necrotic ribs and intact thickened parietal pleura.

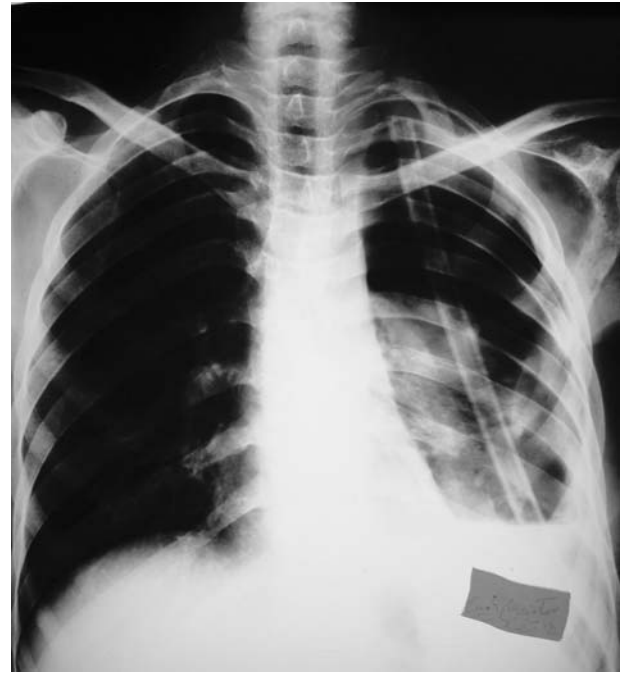

**Figure 5:** Intraoperative photo shows covering the latissimus dorsi muscle flap with skin monitor and split-thickness skin graft.

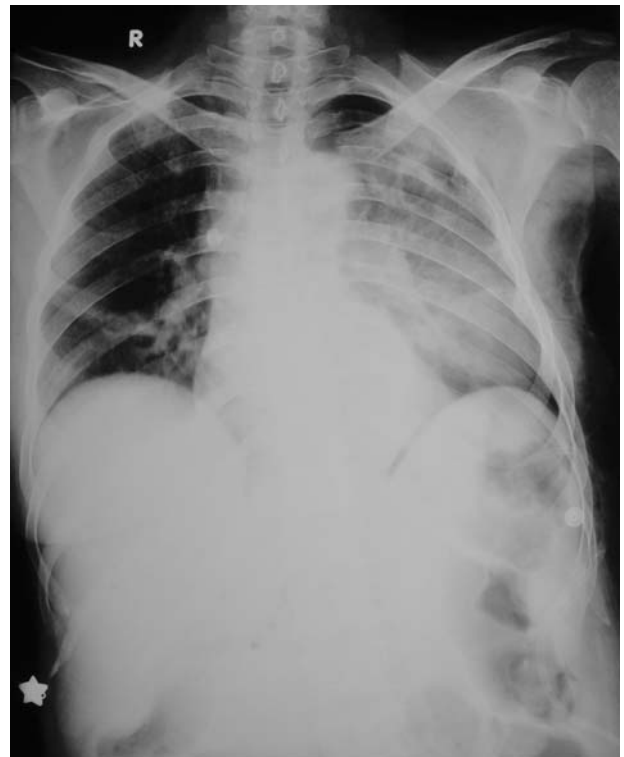
necrotic area, since we suspect that, after radiotherapy treatment, the mediastinum of the patient will be fixed in place without fear of mediastinal flutter or paradoxical movement.

Although Tanasini, in 1996, originally described the latissimus dorsi musculocutaneous flap for coverage of an anterior chest wall defect after radical mastectomy, it was not until the latter half of the century that this flap became a workhorse for chest wall coverage. It can be transferred as a muscle or myocutaneous flap on the dominant thoracodorsal pedicle and is ideally suited for anterior and anterolateral defects.

The latissimus dorsi muscle is a versatile and reliable muscle for chest wall reconstruction. It has a sturdy vascular pedicle and can be elevated and rotated through a generous arc and can reach the entire ipsilateral chest, as well as the midline and contralateral anterior axillary fold. However, the previous thoracotomy or axillary incisions need to be taken into account for possible interruption of this dominant pedicle. The reconstructive surgeon should have sufficient experience and should be well versed in the anatomy of the thoracodorsal system. In the present study, soft tissue coverage was provided with pedicled latissimus dorsi muscle only because of personal preference.

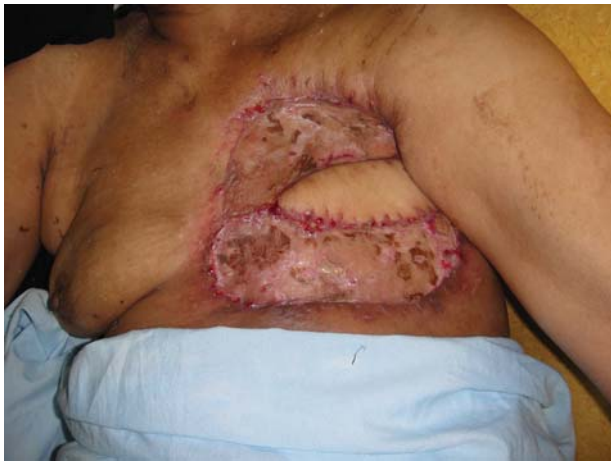

**Figure 6:** Immediate postoperative chest X-ray shows no evidence of pneumo- or haemothorax. (Notice the suction drain for the latissimus dorsi donor site.)



**Figure 7:** Forty-eight hours postoperative chest X-ray shows no evidence of pneumo- or haemothorax.

Follow-up of our cases, clinically and by radiographic study, shows that the flap is fixed in place and no complication occurred regarding respiratory impairment or pleural complications.



**Figure 8:** Six weeks postoperative photo shows complete flap viability and 100% graft take.

The use of a prosthesis allows rigid chest wall reconstruction to avoid the floating respiratory mechanism. The primary objective is to obtain parietal stability and therefore minimize the functional limitations. However, we found that development of fairly rigid scar and soft tissue fibrosis could explain the progressive flap stability, avoiding paradoxical movements.

## CONCLUSION

We concur that the use of prosthetic material carries a high risk of complications, mostly infection. So the use of only the myocutaneous flap, post-radiotherapy treatment, is sufficiently satisfactory to obtain coverage of the wound and stability of the chest wall, which is almost fixed due to soft tissue fibrosis.

## REFERENCES

- [1] Arnold PG, Pairolero PC. Chest wall reconstruction: an account of 500 consecutive patients. *Plast Reconstr Surg* 1996;98:804e10.
- [2] Studer G, Gratz KW, Glanzmann C. Osteoradionecrosis of the mandibula in patients treated with different fractionations. *Strahlenther Onkol* 2004; 180:233–40.
- [3] Daly M, Junor EJ, Harnett AN. Late effects after radiotherapy for breast cancer. *BMJ* 1995;310:669.
- [4] Vojkan S, Marjan N, Tatjana V, Vlado C, Aleksandar R, Bojan G. Reconstruction of large chest wall defects after radical resection for malignant tumours. *ACTA FAC MED NAISS* 2006;23:107–11.
- [5] Sando W, Jurkiewicz MJ. An approach to repair of radiation necrosis of chest wall and mammary gland. *World J Surg* 1986;10:206–19.
- [6] Pairolero P. Chestwall tumours. In: Shields T. (ed). *General Thoracic Surgery*, 4 edn. Williams and Wilkins, 1994, 579–88.
- [7] Hood RM. *Surgical Anatomy of the Thoracic Wall and Pleura*. In: Saunders WB (ed). *Surgical Diseases of the Pleura and Chest Wall*, Philadelphia, 1986, 1.
- [8] Allen MS, Mathisen DJ, Grillo HC, Wain JC, Moncure AC, Hilgenberg AD. Bronchogenic carcinoma with chest wall invasion. *Ann Thorac Surg* 1991;51:948.
- [9] Fisher B, Anderson S, Bryant J, Margolese RG, Deutsch M, Fisher ER *et al*. Twenty-year follow-up of a randomized trial comparing total mastectomy, lumpectomy and lumpectomy plus irradiation for treatment of invasive breast cancer. *N Engl J Med* 2002;347:1233–41.
- [10] Veronesi U, Cascinelli N, Mariani L, Greco M, Saccozzi R, Luini A *et al*. Twenty-year follow-up of a randomized study comparing breast-conserving surgery with radical mastectomy for early breast cancer. *N Engl J Med* 2002;347:1227–32.
- [11] Veronesi U, Marubini E, Mariani L, Galimberti V, Luini A, Veronesi P *et al*. Radiotherapy after breast-conserving surgery in small breast carcinoma: long-term results of a randomized trial. *Ann Oncol* 2001;12:997–1003.
- [12] Lingos TI, Recht A, Vicini F, Abner A, Silver B, Harris JR. Radiation pneumonitis in breast cancer patients treated with conservative surgery and radiation therapy. *Int J Radiat Oncol Biol Phys* 1991;21:355–60.
- [13] Powell S, Cooke J, Parsons C. Radiation induced brachial plexus injury: follow-up of two different fractionation schedules. *Radiother Oncol* 1990;18:312–20.
- [14] Swedborg I, Wallgren A. The effect of pre- and post-mastectomy radiotherapy on the degree of oedema, shoulder joint mobility, and gripping force. *Cancer* 1981;47:877–81.
- [15] Syed MI, Clark LJ, Adams C. Life threatening haemorrhage from osteoradionecrosis of the ribs and clavicle. *Laryngoscope* 2007;117:1594–5.