

Cite this article as: Toale C, Fitzmaurice GJ, Eaton D, Lyne J, Redmond KC. Outcomes of left atrial appendage occlusion using the AtriClip device: a systematic review. *Interact CardioVasc Thorac Surg* 2019;29:655–62.

Outcomes of left atrial appendage occlusion using the AtriClip device: a systematic review

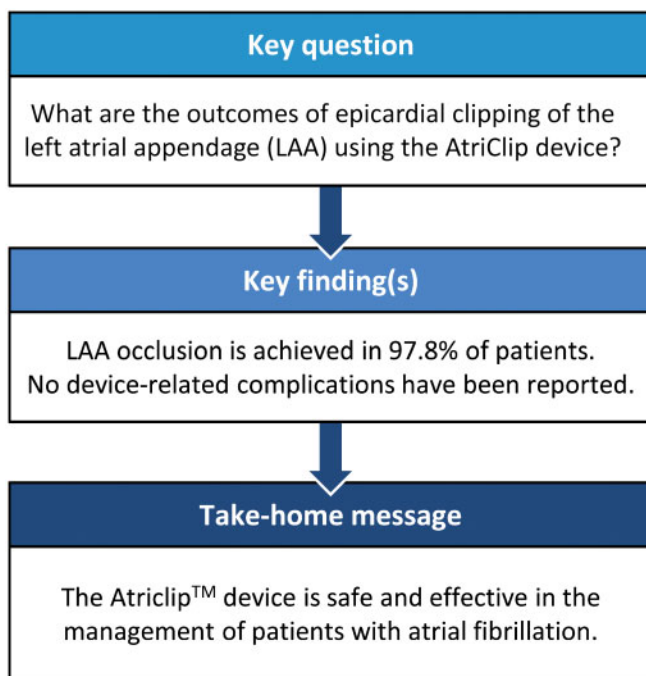
Conor Toale ^a, Gerard J. Fitzmaurice ^a, Donna Eaton^a, Jonathan Lyne^b and Karen C. Redmond^{a,*}

^a Department of Thoracic Surgery, The Mater Misericordiae University Hospital, Dublin, Ireland

^b Department of Cardiology, Blackrock Clinic, Dublin, Ireland

* Corresponding author. Department of Thoracic Surgery, Mater Misericordiae University Hospital, Eccles Street, Dublin, Ireland. Tel: +353-1803-2162; fax: +353-1803-4048; e-mail: karedmond@mater.ie (K.C. Redmond).

Received 14 January 2019; received in revised form 7 May 2019; accepted 19 May 2019



Summary

Atrial fibrillation increases lifetime stroke risk. The left atrial appendage (LAA) is thought to be the source of embolic strokes in up to 90% of cases, and occlusion of the LAA may be safer than the alternative of oral anticoagulation. Occlusion devices, such as the AtriClip™ (AtriCure, Mason, OH, USA) enable safe and reproducible epicardial clipping of the LAA. A systematic review was performed in May 2018, based on the Preferred Reporting Items for Systematic Reviews and Meta-analyses guidelines, using the keyword 'AtriClip'. A total of 68 papers were identified and reviewed; 11 studies were included. Data including demographics, medical history intervention(s) performed, periprocedural outcomes and follow-up were assessed and analysed. A total of 922 patients were identified. LAA occlusion was achieved in 902 out of 922 patients (97.8%). No device-related adverse events were reported across the studies. The reported incidence of stroke or transient ischaemic attack post-clip placement ranged from 0.2 to 1.5/100 patient-years. Four hundred and seventy-seven of 798 patients (59.7%) had ceased anticoagulation on follow-up. The AtriClip device is safe and effective in the management of patients with atrial fibrillation, either as an adjunct in patients undergoing cardiac surgery or as a stand-alone thoracoscopic procedure.

Keywords: Left atrial appendage clipping • AtriClip • Atrial fibrillation

INTRODUCTION

Rationale

Stroke risk reduction in patients with atrial fibrillation (AF) is largely based on anticoagulation with warfarin or direct oral anticoagulants. Contraindications may prohibit the use of these agents, such as poor patient compliance, the need for continuous monitoring and bleeding risk [1]. In acknowledgement of these limitations, interventional methods of reducing stroke risk targeting the left atrial appendage (LAA) have been explored. The LAA is a tubular structure separated from the left atrium by an oval orifice [2], containing muscular trabeculae, which allow for the formation of thrombus in AF [3]. Up to 90% of ischaemic strokes are thought to arise from the LAA in patients with AF [4].

Occlusion of the LAA is equally as efficient and may be safer than warfarin in stroke prevention [5]. Percutaneous methods of LAA occlusion have shown promise as a viable alternative to oral anticoagulation (OAC) [6]. Devices include the percutaneous left atrial appendage transcatheter occlusion (PLAATO) device, the Watchman device and the Amplatzer ACP device [7]. In particular, the Watchman device (Boston Scientific, Maple Grove, MN, USA) has been shown to be non-inferior or superior to oral anticoagulation by the PROTECT-AF and PREVAIL trials [5, 8, 9]. However, percutaneous LAA closure is associated with high procedural failure rates [10, 11]. They also carry the risks of bleeding, cardiac perforation, air embolism, pericardial effusions, sepsis and device-related complications, e.g. migration [7]. Device-related thrombus has also been demonstrated on follow-up, giving rise to concern over the cessation of anticoagulant therapy. The anatomical variability of the LAA, and in particular the variable size of the LAA neck, may also preclude consistent closure with internal occlusion devices [12].

Surgical options include amputation/exclusion with stapling devices and excision with suture closure. Kanderian *et al.* [6] state that surgical resection, suture closure and stapling lead to successful occlusion rates of 73%, 23% and 0%, respectively [13–15]. Epicardial LAA clipping has been approved by the United States Food and Drug Administration (US-FDA) and is increasingly being used to exclude the LAA in patients with AF undergoing cardiac surgery. The AtriClip™ device (AtriClip Pro, AtriCure, Inc., Cincinnati, OH, USA) is used during both open and thoracoscopic surgery, either as a stand-alone procedure or as part of a combined approach with other procedures, thoracoscopic ablation or staged catheter ablation.

Objectives

The AtriClip device is a single-patient-use medical implant available in 4 sizes ranging from 35 to 50 mm and has shown substantial promise in providing a safe, effective and durable closure of the LAA. It carries theoretical benefits of minimal bleeding risk, immediate electrical isolation of the LAA and does not mandate for post-placement OAC or antiplatelet use [16]. In this study, literature concerning the placement of the AtriClip device in patients with AF was assessed, to establish the safety and efficacy of this emerging device.

METHODS

Information sources and protocol

A systematic review of PubMed, EMBASE and Cochrane library databases was performed in May 2018 based on the Preferred

Reporting Items for Systematic Reviews and Meta-analyses (PRISMA) guidelines [17].

Search, eligibility criteria and study selection

Titles, abstracts and keywords were searched using the term 'AtriClip'. Articles were then screened based on the exclusion and inclusion criteria in Table 1. Articles were included if they recorded perioperative outcomes of patients undergoing placement of the AtriClip device for AF, with specific regard to clip-placement success and device-associated adverse events.

Data collection process and data items

Information was extracted from selected articles on the following variables; patient demographics, operative characteristics (procedure type, method for determining clip placement, surgical approach, i.e. open or thoracoscopic), and outcomes including the rate of complete occlusion, revision for bleeding, device-related serious adverse events, postoperative stroke/transient ischaemic attack (TIA) and rates of long-term clip placement success.

Risk of bias in individual studies

The quality of included studies was assessed according to the National Institute of Health/National Heart, Lung and Blood Institute (NIH/NHLBI) Quality Assessment Tool for Observational Cohort and Cross-Sectional Studies (available at <https://www.nhlbi.nih.gov/health-topics/study-quality-assessment-tools>).

Summary measures

Continuous variables were reported as weighted mean and range, whereas categorical variables were reported as frequencies with percentages. A *P*-value <0.05 was considered to be statistically significant. A statistical analysis was performed using the SPSS Software (IBM Corp. Released 2017. IBM SPSS Statistics for Macintosh, Version 25.0. Armonk, NY, USA: IBM Corp.).

RESULTS

Study selection and quality assessment

A total of 68 results were obtained from the initial literature search. Of the returned results, 22 were duplicates. Thirty-five of the 46 remaining articles were subsequently excluded for reasons outlined

Table 1: Inclusion and exclusion criteria

Inclusion criteria	Exclusion criteria
Clinical studies reporting outcomes following left atrial appendage clipping using the AtriClip™ device	Review articles
Treatment was for atrial fibrillation or stroke prevention in otherwise at-risk patients	Case reports
Full text available in English	Cadaveric studies
	Animal studies
	Technique articles

in Fig. 1. One further study was identified from a manual review of references. In total, 11 studies were included in the subsequent analysis. Risk of bias and quality assessment were carried out using the NIH/NHLBI Quality Assessment Tool for Observational Cohort and Cross-Sectional Studies and rated as 'Good', 'Fair' or 'Poor'. Nine studies were rated as 'Good', whereas 2 studies received a 'Fair' rating (Table 2). Included cohort studies were likely subject to the usual biases of such designs, namely selection bias.

Results of individual studies

Patient demographics. Eleven studies including 922 patients were identified. One of the 11 studies did not report the primary indication for surgery. Of the remaining patients, 879 (96.5%) patients had a history of AF. Patient demographics are outlined in Table 3. The method of clip placement varied across studies. In 4 studies, the AtriClip devices were placed thoracoscopically. Four studies comprised of patients undergoing cardiac surgery via median sternotomy, and in 2 studies clips were placed via minithoracotomy (46 patients). One study included patients undergoing a wide variety of open surgical procedures without distinction, as to the method of clip placement.

Rates of left atrial appendage occlusion. Perioperative and short-term outcomes are outlined in Table 4. Long-term outcomes are outlined in Table 5. Complete LAA occlusion was achieved in 902 out of 922 patients (97.8%, range 93.9–100%). The method of determining adequate placement differed between studies. Two studies defined success as the absence of a residual stump ≥ 10 mm [22, 27]. Four studies used the more stringent criteria of a residual stump < 10 mm combined with an absence of flow to the LAA on Doppler echocardiography [2, 19, 20, 26]. Three studies defined a successful placement as

one resulting in the clip at the base of the LAA with no residual LAA flow [24, 25, 27]. One study defined success as the placement of the AtriClip to the satisfaction of the cardiology service [22], whereas in 1 study the criteria for adequate placement were not specified [21]. van Laar *et al.* [18] reported a success rate of 95% in 222 patients in whom clips were thoracoscopically placed. One patient required the placement of a second clip due to malplacement where repositioning of the first clip was not possible [18]. Kurfirst *et al.* [20] report residual stumps of 18, 15 and 14 mm in 3 of 155 patients. Ailawadi *et al.* [21] report that 1 patient's LAA was too small to allow clip placement. Three further patients in whom clips were placed had residual LAA stumps on transoesophageal echocardiogram (TOE) it is not reported whether these stumps were > 10 mm [21]. In 2 of Ellis *et al.*'s [22] cases, the clip was placed too distally leaving a stump with exposed trabeculations, whereas in 2 further cases the clip failed to address a secondary or posteriorly rotated LAA lobe. One out of 40 patients included in a study by Osmancik *et al.* [23] had clip malplacement confirmed on TOE and later on cardiac CT. Ad *et al.* [24] reported a success rate of 95%. The procedure was aborted in 1 patient due to the presence of severe adhesions, which prevented safe dissection [24]. One patient in a small study by Akca *et al.* [27] required clip repositioning to correct a residual LAA ostium. No incidences of residual LAA flow or leak were reported in these studies. In total, 410 patients had clips thoracoscopically placed across 11 studies.

Safety and durability. No device-related adverse events were reported across any of the studies. Ellis *et al.* [22] reported no device-related complications in patients undergoing standalone thoracoscopic AtriClip placement. In no study was there any incidence of bleeding in which the source was found to be the AtriClip itself. Caliskan *et al.* [18] identified 32 survivors with a follow-up time of 5 years or more. CT imaging, at least 5 years

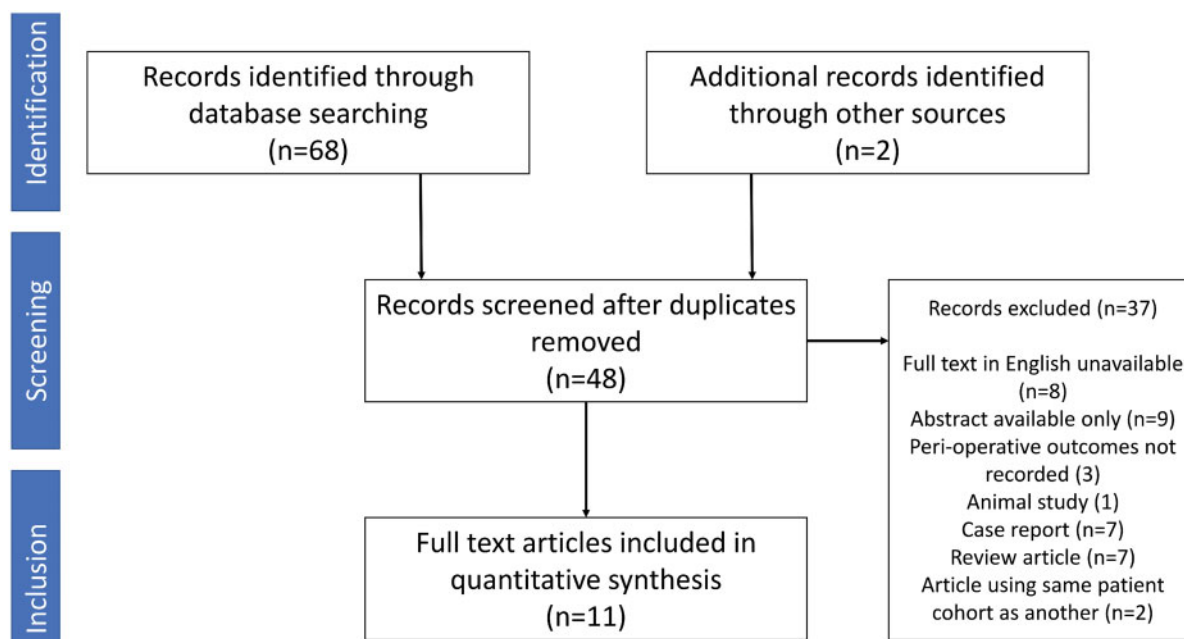


Figure 1: PRISMA flow diagram.

Table 2: NIH/NHLBI quality assessment tool for observational cohort and cross-sectional studies

NIH/NHLBI quality assessment tool for observational cohort and cross-sectional studies	Caliskan <i>et al.</i>	van Laar <i>et al.</i>	Kurfirst <i>et al.</i>	Ailawadi <i>et al.</i>	Ellis <i>et al.</i>	Osmancik <i>et al.</i>	Ad <i>et al.</i>	Alqaqa <i>et al.</i>	Page <i>et al.</i>	Suwalski <i>et al.</i>	Akca <i>et al.</i>
1. Was the research question or objective in this paper clearly stated?	Yes	Yes	Yes	Yes	Yes	Yes	Yes	Yes	Yes	Yes	Yes
2. Was the study population clearly specified and defined?	Yes	Yes	Yes	Yes	Yes	Yes	Yes	Yes	Yes	Yes	Yes
3. Was the participation rate of eligible persons at least 50%?	NR	NR	NR	NR	Yes	NR	NR	NR	NR	NR	NR
4. Were all the subjects selected or recruited from the same or similar populations? Were inclusion and exclusion criteria for being in the study prespecified and applied uniformly to all participants?	Yes	Yes	No	Yes	Yes	Yes	Yes	Yes	Yes	Yes	Yes
5. Was a sample size justification, power description, or variance and effect estimates provided?	No	No	No	No	No	No	No	No	No	No	No
6. Were the exposure(s) of interest measured prior to the outcome(s) being measured?	Yes	Yes	Yes	Yes	Yes	Yes	Yes	Yes	Yes	Yes	Yes
7. Was the timeframe sufficient so that one could reasonably expect to see an association between exposure and outcome if it existed?	Yes	Yes	Yes	Yes	Yes	Yes	Yes	Yes	Yes	Yes	No
8. Did the study examine different levels of the exposure as related to the outcome?	NA	NA	NA	NA	NA	NA	NA	NA	NA	NA	NA
9. Were the exposure measures clearly defined, valid, reliable and implemented consistently across all study participants?	Yes	Yes	Yes	Yes	Yes	Yes	Yes	Yes	Yes	Yes	Yes
10. Was the exposure(s) assessed more than once over time?	NA	NA	NA	NA	NA	NA	NA	NA	NA	NA	NA
11. Were the outcome measures clearly defined, valid, reliable and implemented consistently across all study participants?	Yes	Yes	Yes	Yes	Yes	Yes	Yes	Yes	Yes	Yes	Yes
12. Were the outcome assessors blinded to the exposure status of participants?	No	No	No	No	No	No	No	No	No	No	No
13. Was loss to follow-up after baseline 20% or less?	Yes	Yes	Yes	Yes	Yes	Yes	Yes	NA	Yes	NA	Yes
14. Were key potential confounding variables measured and adjusted statistically for their impact on the relationship between exposure(s) and outcome(s)?	Yes	No	No	No	No	Yes	Yes	Yes	No	Yes	No
Overall quality rating	Good	Good	Good	Good	Good	Good	Good	Good	Good	Fair	Fair

NA: not applicable; NHLBI: National Heart, Lung and Blood Institute; NIH: National Institute of Health; NR: not recorded.

Table 3: Patient demographic

Studies, <i>n</i>	11
Patients, <i>n</i>	922
Age (years), weighted mean (range)	68.2 (62.6–74)
Diabetes, % (<i>n/n</i> status recorded)	18.8 (113/602)
Hypertension, % (<i>n/n</i> status recorded)	73.7 (442/602)
Prior stroke/TIA % (<i>n/n</i> status recorded)	13.3 (116/871)
History of atrial fibrillation, atrial flutter % (<i>n/n</i> status recorded)	93.9 (845/900)
LVEF (%), weighted mean (range)	56.4 (50–59.6)
CHA ₂ DS ₂ -VASc score, weighted mean (range)	2.77 (2.2–5)
Left atrial size, weighted mean (range)	4.88 (4.49–5.6)
CABG, <i>n</i> (%)	236 (25.6)
Valve procedure, <i>n</i> (%)	325 (35.2)
Thoracoscopic ablation, <i>n</i> (%)	404 (43.8)
AtriClip™ placement alone, <i>n</i> (%)	21 (2.3)
Surgical maze (open), <i>n</i> (%)	126 (13.7)
Surgical PVI (open), <i>n</i> (%)	104 (11.3)
Other, <i>n</i> (%)	54 (5.8)

CABG: coronary artery bypass grafting; LVEF: left ventricular ejection fraction; PVI: pulmonary vein isolation; TIA: transient ischaemic attack.

post-clip placement, was available in 23 of these survivors. These images confirmed long-term stability of clip position, with complete LAA occlusion and no sign of reperfusion. van Laar *et al.* [19] report a 96.7% complete closure rate in patients who underwent a follow-up TOE approximately 6 months after surgery. Fifty-six patients enrolled in a study by Ailawadi *et al.* underwent CT angiography (CTA) 3 months postprocedure, whereas a further 5 underwent TOE. All but one of these patients had complete exclusion of the LAA (98.3%). Ellis *et al.* sought to assess the long-term efficacy of the AtriClip post-thoracoscopic placement. CT angiography was performed >90 days postimplantation; 93.9% of patients had complete LAA closure. Osmancik *et al.* [23] performed CT at 2–5 months postplacement in 27 of 40 patients. Malposition was confirmed in 1 patient with known unsuccessful occlusion on TOE. No further complications or evidence of thrombus formation was seen in the remaining 26 patients.

Postoperative stroke/transient ischaemic attack. Caliskan *et al.* [18] recorded 5 perioperative strokes, of which 3 were ischaemic in nature [18]. One of these was secondary to a large

Table 4: Short-term outcomes

Study	n	Method of clip placement	Complete LAA occlusion	LAA leak	Success criteria	Revision for bleeding	Revision for bleeding due to clip	Device-related serious adverse events	Postoperative TIA	Postoperative ischaemic stroke	30-Day mortality
Caliskan et al. [18]	291	Median sternotomy, other cardiac surgery	291	0	Residual stump <10 mm	0	0	0	0	3	16
van Laar et al. [19]	222	Thoracoscopic	211	0	No flow to LAA, residual stump <10 mm	0	0	0	0	0	0
Kurfurst et al. [20]	155	Multiple methods included	152	0	No flow to LAA, residual stump <10 mm	10	0	0	0	1	13
Ailawadi et al. [21]	71	Median sternotomy, other cardiac surgery	67	0	Unspecified, 'residual stump' in 3 patients	4	0	0	0	0	0
Ellis et al. [22]	65	Thoracoscopic	65	0	Clip at base of LAA 'to satisfaction of cardiology'	0	0	0	0	0	0
Osmancik et al. [23]	40	Thoracoscopic	39	0	Residual stump <10 mm	2	0	0	0	0	0
Ad et al. [24]	24	Right minithoracotomy and transverse sinus	23	0	No flow to LAA + Clip at base of LAA	0	0	0	0	0	0
Alqaqa et al. [25]	22	Minithoracotomy (minimally invasive mitral)	22	0	No flow to LAA + Clip at base of LAA	2	0	0	0	0	0
Page et al. [2]	20	Median sternotomy, other cardiac surgery	20	0	No flow to LAA, residual stump <10 mm	0	0	0	0	0	0
Suwalski et al. [26]	7	Median sternotomy, other cardiac surgery	7	0	No flow to LAA, residual stump <10 mm	0	0	0	0	0	0
Akca et al. [27]	5	Thoracoscopic	5	0	No flow to LAA + clip at base of LAA	0	0	0	0	0	0

LAA: left atrial appendage; TIA: transient ischaemic attack.

left atrial thrombus. Another was due to intraoperative hypoxia, whereas the third was secondary to an intraoperative air embolism. Two further ischaemic strokes occurred during the follow-up period—one due to thromboembolism of cardiac origin and another in a patient with recurrent AF off oral anticoagulation [18]. The predicted ischaemic stroke rate was 2.9/100 patient-years in this cohort undergoing open cardiac surgery. A stroke rate of 0.2/100 patient-years was recorded postclip placement, representing a 14.5-fold relative risk reduction [18]. A further subgroup analysis of 166 patients off oral anticoagulation revealed a relative risk reduction in the stroke rate of 87.5% attributable to the AtriClip. van Laar et al. [19] recorded 1 ischaemic stroke and 1 TIA in the follow-up of their cohort undergoing totally thoracoscopic maze with atrial appendage clipping. The overall cerebrovascular event rate was, therefore, low at 0.5 per 100 patient-years [19]. One patient undergoing coronary artery bypass grafting with closure of a patent foramen and concomitant AtriClip placement suffered a postoperative stroke in a study by Kurfurst et al. [20]. A transthoracic echocardiogram did not reveal any intra-atrial thrombus on the endocardial side of the closed LAA [20]. One further cerebrovascular accident (CVA) and 4 further TIAs occurred during long-term follow-up; again, on review of the patients' imaging, there was no evidence of AtriClip-associated thrombus [20]. This equates a cerebrovascular event rate of 1.5/100 patient-years in a cohort undergoing a wide range of thoracoscopic and open procedures with concomitant epicardial clipping [20]. In Ailawadi et al.'s cohort of 64 patients available for follow-up postepicardial clipping, 1 patient had suffered a TIA secondary to a hypertensive crisis, whereas another had suffered an anterior circulation stroke cerebrovascular event (CVE) rate of 1.5/100 patient-years. Ellis et al. [22] recorded 1 hypertensive CVA in 183 patient-years post-thoracoscopic epicardial clipping with or without concomitant ablation. In another cohort undergoing thoracoscopic ablation and AtriClip placement, Osmancik et al. report no stroke/TIA in 40 patients over a mean follow-up of 363.2 days [23]. Nor were there any strokes/TIAs in Ad et al.'s [23] study post-clipping and ablation via minithoracotomy over 12.3 months of follow-up. Furthermore, Page et al. [2] noted no incidence of stroke or TIA in 375 days of patient follow-up in 20 patients undergoing open cardiac surgery with AtriClip placement. Finally, none of the 5 patients enrolled in Akca et al.'s [27] study suffered a CVE over a mean follow-up of 7.2 months after stand-alone AtriClip placement.

Approach to postoperative anticoagulation. One hundred and sixty-six of 291 patients in a large study by Caliskan et al. [18] discontinued oral anticoagulation after clip placement. Fifty-seven percent of patients in van Laar's [19] study were not on OAC at latest follow-up. Of 142 patients followed in Kurfurst et al.'s [20] paper, 38.7% of patients remained on warfarin, 14.1% of patients continued direct oral anticoagulant (DOAC) therapy and 3.5% of patients remained on LMWH. Forty-five of 64 patients available for postprocedural follow-up had ceased anticoagulation therapy in Ailawadi's study [21], whereas only 12 of 65 patients in Ellis et al.'s [22] study remained on OAC. Three of these 12 patients had malpositioned AtriClip devices, whereas 8 patients had ongoing indications for AC use and 1 patient continued out of patient preference [22]. Seventy percent of Osmancik et al.'s [23] cohort of patients ceased the AC therapy.

Table 5: Long-term outcomes

Study	<i>n</i>	Mean follow-up (months)	Late TIA	Late ischaemic stroke	Discontinued anticoagulation (n/n recorded)	Late deaths	Late deaths attributable to clip
Caliskan <i>et al.</i> [18]	291	36	0	2	166/273	36	0
van Laar <i>et al.</i> [19]	222	20	1	1	127/222	3	0
Kurfirist <i>et al.</i> [20]	155	25.2	4	1	62/142		
Ailawadi <i>et al.</i> [21]	71	12	1	1	45/64		
Ellis <i>et al.</i> [22]	65	34.3	0	0	53/65	0	0
Osmancik <i>et al.</i> [23]	40	12.1	0	0	19/27	0	0
Ad <i>et al.</i> [24]	24	12.3	0	0		0	0
Alqaqa <i>et al.</i> [25]	22						
Page <i>et al.</i> [2]	20	44.8	0	0		3	0
Suwalski <i>et al.</i> [26]	7						
Akca <i>et al.</i> [27]	5	7.2	0	0	5/5	0	0

TIA: transient ischaemic attack.

DISCUSSION

Summary of evidence

Complete LAA occlusion was achieved in 902 out of 922 patients (97.8%). This highlights the efficacy of epicardial appendage occlusion and adds to the growing body of evidence supporting the use of the AtriClip device in the surgical management of AF. On pooled analysis, thoracoscopic placement success rates were 95.3% compared to 99.2% for patients in whom clips were placed via an open technique. This difference is statistically significant (X^2 analysis, $P=0.0002$). Lower rates of success with the thoracoscopic placement were attributed by the authors of 1 study to the learning curve of the procedure [20]. Nevertheless, both thoracoscopic and open techniques had high procedural success. This supports the use of thoracoscopic clipping as part of a totally thoracoscopic ablation procedure, as a stand-alone procedure or potentially as an adjunct to non-cardiac thoracic surgery in patients with AF.

Criteria for successful placement varied across studies. Most commonly, no residual flow to the LAA or a residual LAA stump <10 mm is used as an indicator of success, imported from studies assessing surgical LAA closure [6]. The cut-off point of <10 mm is arbitrary, and a number of studies fail to give descriptions of how these measurements were obtained [28–30]. A residual stump has never been reported to be associated with a higher risk of stroke [23]. Persistent flow to the LAA has, however, been shown to confer increased stroke risk in patients who have undergone surgical LAA closure [31]. No so-called ‘narrow-channel’ failures were reported in the studies included in this review. These data suggest that epicardial closure would compare favourably to surgical methods. Standardized criteria for clip placement success are required to guide surgeons going forward. Intraoperative visualization with TOE is essential to confirm the absence of flow to the LAA after clip placement and to rule out intra-appendiceal thrombus prior to placement, which can be dislodged into the systemic circulation by clipping.

Placement of the AtriClip is safe; no device-related complications have been reported in these studies. Furthermore, in none of the studies was there any increased risk of bleeding attributable to the device. The AtriClip would, therefore, likely compare favourably to surgical methods of closure. However, in the absence of randomized clinical trials, it is impossible to reliably

comment on the merits of epicardial clipping versus surgical methods or indeed percutaneous LAA closure. Percutaneous devices are associated with high rates of complete closure, from 91% to 98.5% [32]. However, the definition for complete LAA closure used in these studies allows for peridevice leakage of <3–5 mm in diameter. This leakage is seen in 8–13% of patients [33–35]. Although it is unclear whether this peridevice leakage impacts future stroke risk, it is plausible that this ‘narrow-channel failure’ may predispose to LAA thrombus formation postclosure. The incidence of device-related thrombus ranges is as high as 7.2% with endocardial closure devices [36]. Given the lack of an endovascular foreign body with epicardial clipping, the risk of device-related thrombus formation is theoretically lower. Four studies included in this review recorded a device-related thrombus rate of 1 in 252 patients on follow-up, in a patient in whom LAA exclusion was incomplete at the time of clip placement [23]. Moreover, AtriClip is durable. Although long-term assessment of clip placement was not performed routinely in all of the studies in this review, several studies have demonstrated the long-term stability of epicardial clips. This would suggest that long-term imaging follow-up is not essential after clip placement.

Anticoagulation protocols postdevice placement varied across studies. Caliskan *et al.* [18] initially favoured stopping warfarin/DOAC therapy at 3 months postprocedure [33]. However, after initial safety results emerged from their first-in-human prospective trial, they opted to cease anticoagulation immediately postprocedure in the absence of other indications. Kurfirist *et al.* [37] again favoured continuing anticoagulation for 3 months postprocedure, stopping at this point if the patient was in sinus rhythm and switching to antiplatelet therapy. In a number of patients in the included studies, anticoagulation was not stopped after clip placement because of reasons including ongoing indication for OAC and inadequate clip placement. Furthermore, Caliskan *et al.* [18] highlight a reluctance by referring physicians to stop OAC due to lack of available supporting data and guidelines. They report that cessation rates improved after the publication of the Watchman trials showing favourable outcomes after LAA occlusion [18]. Again, the durability of the devices as suggested by a number of studies in this review may allow for the cessation of OAC immediately after clip placement, once positioning has been confirmed by the intraoperative TOE.

The effect of the AtriClip device on the subsequent stroke rate, cannot be reliably determined from the data in this review because of the heterogeneous nature of the interventions

performed and the lack of standardization in the approach to medical therapy. Importantly, the studies in this review failed to demonstrate a total elimination of stroke/TIA in patients treated with the AtriClip, highlighting that the LAA is not the only source of stroke. Without screening for conditions such as carotid stenosis, the potential implications of stopping medical therapy, i.e. antiplatelets in patients postprocedurally are unknown. Furthermore, the studies in this review failed to discuss potentially detrimental effects of LAA clipping. Evidence from animal studies suggests that LAA obliteration can lead to adverse haemodynamic effects [38]. Studies in primates have shown that bilateral excision of the atrial appendages leads to an attenuated natriuretic response to volume expansion [39]. Similar effects have been observed in humans [40]. Furthermore, atrial appendectomy leads to a reduced stroke volume and a subsequent reduction in 'atrial kick', and may contribute to a lower cardiac output [38]. There are also concerns regarding leaving a necrotic mass of appendiceal tissue inside the thorax; significantly elevated levels of C-reactive protein have been seen postepicardial clipping when compared to stapled excision [41]. Whether this inflammatory response affects the outcome of arrhythmia surgery has yet to be established.

Limitations

This review assesses data from a number of heterogeneous studies of differing design and methodology. Epicardial clipping was performed via a number of different approaches including open placement via sternotomy/minithoracotomy and thoracoscopic techniques. Furthermore, the approach to combined ablative procedures varied both within and across studies. Though some patients underwent epicardial clipping as part of a stand-alone procedure, others underwent ablation, epicardial maze or other operations for the management of AF. Postoperatively, the approach to anticoagulation was inconsistent across studies. Data regarding postprocedural stroke rates should be interpreted with caution, particularly as other potential embolic factors such as carotid stenosis were not recorded or adjusted for many included patients. Publication bias was not formally assessed.

CONCLUSION

This review highlights the safety, efficacy and durability of the AtriClip device in the management of patients with AF. Rates of total LAA occlusion compare favourably to conventional surgical closure methods and percutaneous closure techniques. Success with thoracoscopic placement may lead to the increased utility of the AtriClip devices in patients undergoing non-cardiac thoracic surgery or as a stand-alone therapy. Future trials should aim to compare the safety and efficacy of epicardial clipping with established surgical and percutaneous methods of LAA closure. Clear guidelines are required regarding the need for postoperative anticoagulation in patients postepicardial clipping. Whether the elimination of the LAA by this method has long-term implications for patients, in light of its role in fluid dynamics, it should be assessed by long-term follow-up of the cohorts included in the above studies.

Conflict of interest: The authors of this review declare no conflict of interest. Studies included for review have declared the

following: Sacha P. Salzberg and Maximilian Y. Emmert have received speaker fees from AtriCure [18]. Charlotte van Laar is funded by an unrestricted research grant from AtriCure; Niels J. Verberkmoes is a speaker and a proctor for AtriCure; Bart P. van Putte is a proctor for AtriCure; Gan Dunnington is a proctor and consultant for AtriCure; Carolyn M. Pierce is a consultant for AtriCure. Dipak Kotecha has received speaker fees from AtriCure [19, 27]. Ellis *et al.* [22] received funding from AtriCure; Christopher R. Ellis, Steven J. Hoff and S. Patrick Whalen have received consulting fees from AtriCure. Niv Ad is a consultant for AtriCure [24]. Michael Yii is a consultant for AtriCure [2].

REFERENCES

- [1] Gladstone DJ, Bui E, Fang J, Laupacis A, Lindsay MP, Tu JV *et al.* Potentially preventable strokes in high-risk patients with atrial fibrillation who are not adequately anticoagulated. *Stroke* 2009;40:235–40.
- [2] Blackshear JL, Odell JA. Appendage obliteration to reduce stroke in cardiac surgical patients with atrial fibrillation. *Ann Thorac Surg* 1996;61:755–9.
- [3] Ho SY, Cabrera JA, Sanchez-Quintana D. Left atrial anatomy revisited. *Circ Arrhythm Electrophysiol* 2012;5:220–8.
- [4] Page S, Hallam J, Pradhan N, Cowie B, Phan T, McGlade D *et al.* Left atrial appendage exclusion using the AtriClip device: a case series. *Heart Lung Circ* 2019;28:430–5.
- [5] Holmes DR, Reddy VY, Turi ZG, Doshi SK, Sievert H, Buchbinder M *et al.* Percutaneous closure of the left atrial appendage versus warfarin therapy for prevention of stroke in patients with atrial fibrillation: a randomised non-inferiority trial. *Lancet* 2009;374:534–42.
- [6] Kanderian AS, Gillinov AM, Pettersson GB, Blackstone E, Klein AL. Success of surgical left atrial appendage closure: assessment by transesophageal echocardiography. *J Am Coll Cardiol* 2008;52:924–9.
- [7] Sakellariadis T, Argiriou M, Charitos C, Tsakiridis K, Zarogoulidis P, Katsikogiannis N *et al.* Left atrial appendage exclusion—where do we stand? *J Thorac Dis* 2014;6(Suppl 1):S70–7.
- [8] Holmes DR Jr, Kar S, Price MJ, Whisenant B, Sievert H, Doshi SK *et al.* Prospective randomized evaluation of the watchman left atrial appendage closure device in patients with atrial fibrillation versus long-term warfarin therapy: the PREVAIL trial. *J Am Coll Cardiol* 2014;64:1–12.
- [9] Reddy VY, Sievert H, Halperin J, Doshi SK, Buchbinder M, Neuzil P *et al.* Percutaneous left atrial appendage closure vs warfarin for atrial fibrillation: a randomized clinical trial. *JAMA* 2014;312:1988–98.
- [10] Pillarisetti J, Reddy YM, Gunda S, Swarup V, Lee R, Rasekh A *et al.* Endocardial (Watchman) vs epicardial (Lariat) left atrial appendage exclusion devices: understanding the differences in the location and type of leaks and their clinical implications. *Heart Rhythm* 2015;12:1501.
- [11] Viles-Gonzalez JF, Kar S, Douglas P, Dukkipati S, Feldman T, Horton R *et al.* The clinical impact of incomplete left atrial appendage closure with the watchman device in patients with atrial fibrillation: a PROTECT AF (Percutaneous closure of the left atrial appendage versus warfarin therapy for prevention of stroke in patients with atrial fibrillation) substudy. *J Am Coll Cardiol* 2012;59:923–9.
- [12] Salzberg SP, Grunenfelder J, Emmert MY. Left atrial appendage closure to prevent stroke in patients with atrial fibrillation: a call for the heart team approach. *Europace* 2015;17:1880–1.
- [13] Gillinov AM. Advances in surgical treatment of atrial fibrillation. *Stroke* 2007;38:618–23.
- [14] Fuster V, Ryden LE, Cannom DS, Crijns HJ, Curtis AB, Ellenbogen KA *et al.* ACCF/AHA/HRS focused updates incorporated into the ACC/AHA/ESC 2006 guidelines for the management of patients with atrial fibrillation: a report of the American College of Cardiology Foundation/American Heart Association Task Force on Practice Guidelines developed in partnership with the European Society of Cardiology and in collaboration with the European Heart Rhythm Association and the Heart Rhythm Society. *J Am Coll Cardiol* 2011;57:e101–98.
- [15] Fumoto H, Gillinov AM, Ootaki Y, Akiyama M, Saeed D, Horai T *et al.* A novel device for left atrial appendage exclusion: the third-generation atrial exclusion device. *J Thorac Cardiovasc Surg* 2008;136:1019–27.
- [16] Turagam MK, Velagapudi P, Kar S, Holmes D, Reddy VY, Refaat MM *et al.* Cardiovascular therapies targeting left atrial appendage. *J Am Coll Cardiol* 2018;72:448–63.

- [17] Liberati A, Altman DG, Tetzlaff J, Mulrow C, Gotzsche PC, Ioannidis JP *et al.* The PRISMA statement for reporting systematic reviews and meta-analyses of studies that evaluate health care interventions: explanation and elaboration. *Ann Intern Med* 2009;151:W65-94.
- [18] Caliskan E, Sahin A, Yilmaz M, Seifert B, Hinzpeter R, Alkadhi H *et al.* Epicardial left atrial appendage AtriClip occlusion reduces the incidence of stroke in patients with atrial fibrillation undergoing cardiac surgery. *Europace* 2018;20:e105-14.
- [19] van Laar C, Verberkmoes NJ, van Es HW, Lewalter T, Dunnington G, Stark S *et al.* Thoracoscopic left atrial appendage clipping: a multicenter cohort analysis. *JACC Clin Electrophysiol* 2018;4:893-901.
- [20] Kurfirst V, Mokráček A, Čanádýová J, Bulava A, Pešl L. Effectivity of left atrial appendage occlusion with AtriClip in 155 consecutive patients—single center study. *Cor Vasa* 2017;59:e376-80.
- [21] Ailawadi G, Gerdisch MW, Harvey RL, Hooker RL, Damiano RJ Jr, Salamon T *et al.* Exclusion of the left atrial appendage with a novel device: early results of a multicenter trial. *J Thorac Cardiovasc Surg* 2011;142:1002-9, 1009.e1.
- [22] Ellis CR, Aznaurov SG, Patel NJ, Williams JR, Sandler KL, Hoff SJ *et al.* Angiographic efficacy of the Atriclip left atrial appendage exclusion device placed by minimally invasive thoracoscopic approach. *JACC Clin Electrophysiol* 2017;3:1356-65.
- [23] Osmancik P, Budera P, Zdarska J, Herman D, Petr R, Fojt R *et al.* Residual echocardiographic and computed tomography findings after thoracoscopic occlusion of the left atrial appendage using the AtriClip PRO device. *Interact CardioVasc Thorac Surg* 2018;26:919-25.
- [24] Ad N, Massimiano PS, Shuman DJ, Pritchard G, Holmes SD. New approach to exclude the left atrial appendage during minimally invasive cryothermic surgical ablation. *Innovations* 2015;10:323-7.
- [25] Akca F, Verberkmoes NJ, Verstraeten SE, van Laar C, van Putte BP, van Straten A. Is there an alternative treatment for patients intolerant to antiplatelet therapy if percutaneous left atrial appendage closure is considered? *Neth Heart J* 2017;25:510-5.
- [26] Suwalski G, Emery R, Gryszyk L, Kaczejko K, Żegadło A, Frankowska E *et al.* Early operative comparison of two epicardial left atrial appendage occluding systems applied during off-pump coronary revascularisation in patients with persistent atrial fibrillation. *Kardiologich Torakochirurgia Pol* 2016;13:10-4.
- [27] Alqaqa A, Martin S, Hamdan A, Shamoon F, Asgarian KT. Concomitant left atrial appendage clipping during minimally invasive mitral valve surgery: technically feasible and safe. *J Atr Fibrillation* 2016;9:1407.
- [28] Salzberg SP, Plass A, Emmert MY, Desbiolles L, Alkadhi H, Grünenfelder J *et al.* Left atrial appendage clip occlusion: early clinical results. *J Thorac Cardiovasc Surg* 2010;139:1269-74.
- [29] Mokracek A, Kurfirst V, Bulava A, Hanis J, Tesarik R, Pešl L. Thoracoscopic occlusion of the left atrial appendage. *Innovations* 2015;10:179-82.
- [30] Emmert MY, Puiippe G, Baumuller S, Alkadhi H, Landmesser U, Plass A *et al.* Safe, effective and durable epicardial left atrial appendage clip occlusion in patients with atrial fibrillation undergoing cardiac surgery: first long-term results from a prospective device trial. *Eur J Cardiothorac Surg* 2014;45:126-31.
- [31] Gillinov AM, Pettersson G, Cosgrove DM. Stapled excision of the left atrial appendage. *J Thorac Cardiovasc Surg* 2005;129:679-80.
- [32] Sharma SP, Park P, Lakkireddy D. Left atrial appendages occlusion: current status and prospective. *Korean Circ J* 2018;48:692-704.
- [33] Tzikas A, Shakir S, Gafoor S, Omran H, Berti S, Santoro G *et al.* Left atrial appendage occlusion for stroke prevention in atrial fibrillation: multi-centre experience with the AMPLATZER cardiac plug. *EuroIntervention* 2016;11:1170-9.
- [34] Urena M, Rodes-Cabau J, Freixa X, Saw J, Webb JG, Freeman M *et al.* Percutaneous left atrial appendage closure with the AMPLATZER cardiac plug device in patients with nonvalvular atrial fibrillation and contraindications to anticoagulation therapy. *J Am Coll Cardiol* 2013;62:96-102.
- [35] Boersma LV, Schmidt B, Betts TR, Sievert H, Tamburino C, Teiger E *et al.* EWOLUTION: design of a registry to evaluate real-world clinical outcomes in patients with AF and high stroke risk-treated with the WATCHMAN left atrial appendage closure technology. *Catheter Cardiovasc Interv* 2016;88:460-5.
- [36] Fauchier L, Cinaud A, Brigadeau F, Lepillier A, Pierre B, Abbey S *et al.* Device-related thrombosis after percutaneous left atrial appendage occlusion for atrial fibrillation. *J Am Coll Cardiol* 2018;71:1528-36.
- [37] Kurfirst V, Mokráček A, Čanádýová J, Frána R, Zeman P. Epicardial clip occlusion of the left atrial appendage during cardiac surgery provides optimal surgical results and long-term stability. *Interact CardioVasc Thorac Surg* 2017;25:37-40.
- [38] Al-Saady NM, Obel OA, Camm AJ. Left atrial appendage: structure, function, and role in thromboembolism. *Heart* 1999;82:547-54.
- [39] Benjamin BA, Metzler CH, Peterson TV. Chronic atrial appendectomy alters sodium excretion in conscious monkeys. *Am J Physiol* 1988;254:R699-705.
- [40] Omari BO, Nelson RJ, Robertson JM. Effect of right atrial appendectomy on the release of atrial natriuretic hormone. *J Thorac Cardiovasc Surg* 1991;102:272-9.
- [41] Verberkmoes NJ, Akca F, Vandevenne AS, Jacobs L, Soliman Hamad MA, van Straten A. Significantly elevated C-reactive protein levels after epicardial clipping of the left atrial appendage. *Innovations* 2018;13:125-31.