
ORIGINAL ARTICLE

Differences in learning retention when teaching a manual motor skill with a visual vs written instructional aide

Alice Cade, MHSc, BSc (Chiro), Matthew Sherson, BSc, BSc (Chiro), Kelly Holt, BSc (Chiro), PhD, Graham Dobson, DC, Katie Pritchard, BSc, BSc (Chiro), and Heidi Haavik, BSc (Chiro), PhD

Objective: This study aimed to determine if a written or visual teaching aid influenced learning retention when teaching a manual motor skill.

Methods: Seventy chiropractic students who had completed an upper cervical specific chiropractic technique course were evaluated for technique-specific recall before and after a review using either a visual teaching aid or a written guide. Two randomized groups reviewed original course-written guides ($n = 33$) or new visual teaching aids ($n = 37$). Repeated-measures analysis of variance and post hoc t tests compared group differences in reevaluation scores.

Results: Performance of both groups improved postintervention ($F[1, 68] = 182.56, p < .001$). However, the visual teaching aid group improved more than the written guide group ($F[1, 68] = 4.66, p = .03$). The visual teaching aid group percentage score improved by 24.4% ($SD \pm 12.3\%$, $p < .01$); the written guide group improved by 17.7% ($SD \pm 13.7\%$; $p < .01$).

Conclusion: The mean learning retention improved in both the visual and the written teaching guide groups, but there was greater improvement in the visual aid group. This study suggests that visual teaching aids may be more useful than written guides when students attempt to recall information related to learning a manual motor skill.

Key Indexing Terms: Chiropractic; Learning; Mental Recall; Motor Skills; Students

J Chiropr Educ 2018;32(2):107–114 DOI 10.7899/JCE-17-19

INTRODUCTION

Much of a student's academic life involves the memorization of various facts and figures; because of this, students often seek an array of strategies to facilitate their memory and recall.¹ Repetition of information is one way of remembering it, but other strategies include learning mnemonics, visual imagery, and multimodal association links.² Visual imagery techniques have been used since the time of Greek and Roman orators³ and are associated with successful encoding of information to long-term memory and its retrieval.⁴ However common memory strategies may be, there is only a small amount of research available investigating their effectiveness,^{5,6} with most emphasis on memory recovery in individuals with brain damage.^{7,8}

Memory is divided into implicit (nondeclarative) or explicit (declarative) memory.⁹ Explicit memory is consciously available and includes the semantic (facts and general knowledge) and the episodic (events from the past).¹⁰ Implicit memory is that of performing a task without consciously "thinking" about it.¹⁰ For example, regarding making a cup of tea, describing how to make a

cup of tea relies on utilizing declarative-semantic memory,¹¹ getting the words, facts, and information into a cohesive pattern that makes sense to the listener. However, making a cup of tea relies on procedural memory: common motor patterns that people perform almost automatically.¹²

This study was performed to determine whether direct incorporation of visual imagery in the presentation of upper cervical vertebral subluxation indicators would improve student recall. In addition to improving student recall, we believed that students would learn valuable study techniques that may be able to transfer to different learning environments. This is of particular importance as, similar to that of clinical best-practice guidelines, clinical educators continually question the effectiveness of their teaching strategies. This study gives direct insight into how effective a visual teaching tool can be and is part of an ongoing New Zealand College of Chiropractic (NZCC) quality assurance program. This study aimed to determine if a written or a visual teaching aid influences learning retention when teaching a manual motor skill.

METHODS

Trial Design

A parallel group randomized controlled trial design was utilized for this study to test the effectiveness of 2 study aids for upper cervical specific technique subluxation indicator recall. A visual guide was designed to help chiropractic students learn about upper cervical subluxation indicators. To enhance memory and recall, the guide used a combination of visual and spatial association combined with the written word (Fig. 1). This visual guide was tested against the current written guide used in the upper cervical specific course (UCSC).

This paper seeks to describe the findings of a study investigating a visual teaching tool for the UCSC taught at the NZCC. This course draws on elements of Palmer, Blair, Wernsing, Grostic, the National Upper Cervical Chiropractic Association, and atlas orthogonal techniques.¹³ This paper will not attempt to describe the rationale for vertebral subluxation findings or the addition or omission of particular facets of differing techniques but will focus on the teaching tool itself.

Students were asked to complete a free recall questionnaire (Appendix A) for 3 upper cervical subluxation listings (see “Outcomes”) over 10 minutes. They were then given 5 minutes to review either a written guide or a visual guide, after which there were asked to complete a new free-recall upper cervical subluxation listings questionnaire with the same listings (also over 10 minutes).

Participants

Undergraduate chiropractic students who had previously completed (and passed) the UCSC were invited to participate in this study. This course is taught during the 1st year of the college curriculum. Students were from all year groups at the college. All students spoke English as an entry requirement to the college.

Informed consent had been previously gained. All students had previously agreed to participate in research projects at the NZCC. However, the Heath and Disabilities Ethics Committee of New Zealand was contacted to gauge whether further ethical approval should be sought. After consideration, the committee recommended that no further ethical approval was needed, as this data collection was performed as part of course review processes.

Sample Size

To detect a medium effect size of 0.3 with an α of .05 and a β of .8, a minimum sample size of 24 was required.

Interventions

The students were given 5 minutes to study either the original written teaching notes (Appendix B) regarding upper cervical vertebral subluxation indicators or the visual guides created for this study. The free-recall test was repeated after the 5 minutes of upper cervical specific indicators study with the visual teaching guide or the written guide. The 5-minute study period was used, as it mirrors the length of reading time given for reviewing class notes before engaging in learning new motor skills.

Outcomes

Each student was asked to complete a free-recall questionnaire to test their knowledge of upper cervical specific vertebral subluxation indicators (Appendix A) and were allowed 10 minutes to complete the chart. Specifically, they were asked to fill out a chart of 12 rows for 3 selected upper cervical vertebral subluxation listings: C1 anterior, superior and right; C1 atlas right posterior; and C2 center pivot body posterior. The chart included responses for cervical syndrome, Prill test, muscles involved, motion restricted, muscle touch test, muscle head position test, doctor stance, patient position, doctor contact, tissue pull, line of drive, and torque required.¹³ Tests were marked on a scale of 0 to 24 for each listing, with an overall marking scale of 0 to 72. To be scored correct, more than one-half of each indicator had to be accurate; 0 marks were given for an incorrect indicator answer, 1 mark was given for a partially correct indicator answer, and 2 marks were given for a fully correct indicator answer. The free-recall questionnaire was based on previously used examination sheets for the UCSC.

Data Analysis

Data collected from the participants were evaluated pre- and postvisual teaching aid or written guide review. Two randomized groups reviewed original course-written guides or new visual teaching aids. Descriptive statistics (unadjusted means, standard deviations, and counts) were used to describe the characteristics of the study sample using SPSS (IBM SPSS Statistics, version 21, IBM, Armonk, NY).¹⁴ Shapiro-Wilk tests¹⁵ revealed that the outcome data collected for all tasks were normally distributed. A repeated-measures analysis of variance and post hoc *t* tests compared group differences in reevaluation scores.¹⁵

Randomization

Participants were randomly divided into 2 groups via a single application of the Rock-Paper-Scissors game. The Rock-Paper-Scissors game has been shown to be a useful tool for randomization of decision making when only a single round is played.^{16,17}

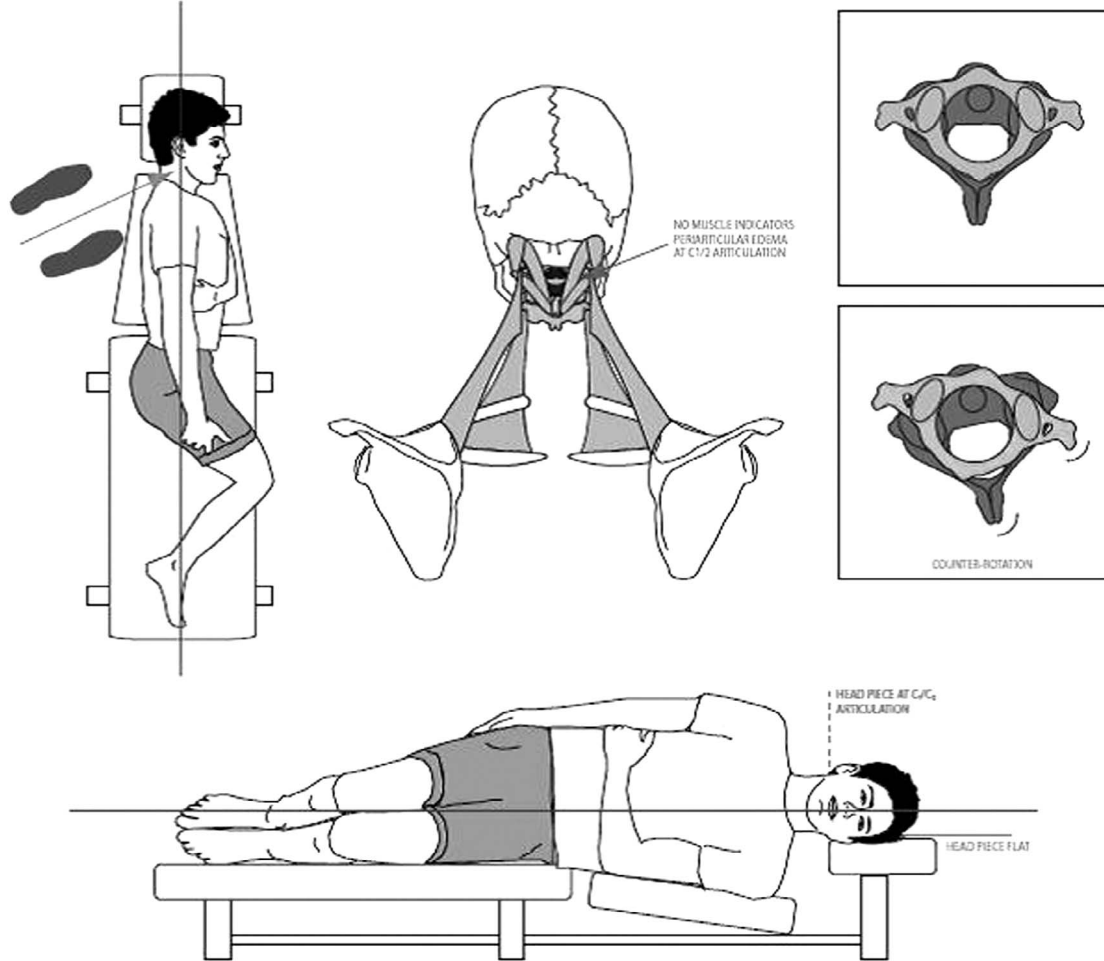
RESULTS

Four classes of students ($n = 208$) were invited to participate in this study, with all invitees being eligible. Seventy students agreed to participate. The participants were randomized to review either a written guide ($n = 33$) or the visual teaching aid ($n = 37$). All participants completed the study. Baseline demographic information is summarized in Table 1. There were some differences in baseline groups with age, sex, and year group. However, most of these differences were minor.

Table 2 shows that the performance of both groups improved postintervention. There was a significant effect of time outcome ($F[1, 68] = 182.56, p < .001$). There was also a significant interaction for the type of guide used, with the visual teaching aid group improving more than the written guide group ($F[1, 68] = 4.66, p = 0.03$). The

C1/C2 ARP (TVP contact)

(C1 TVP rotated posteriorly with counter rotation of C2 spinous right)



Cervical Syndrome	Short Leg goes shorter	Stance	Posterior & slightly inferior to C1 TVP, pivoted facing slightly superior
Prill	Prone: Raise Feet	Patient Position	Lateral Recumbent R. side up - C1/C2 articulation at edge of headpiece
Muscle Palpation	Tension: No distinct muscle findings. Periarticular edema at R. C1/2 facet.	Contact	R. posterior aspect of TVP, with Superior hand contact (L)
Motion	Reduced Motion: C1/2: R Rotation + Extension	Tissue Pull	P-A + I-S
Muscle Test (Push)	BL thumb mid C2 Lamina; one brush A-P to spinous, other P-A to C1 TVP	LOD	Strongly P-A, Slightly I-S & L-M
Muscle Test (Head Position)	Full R. head rotation & slight flexion	Torque	Clockwise

Figure 1 - An example of the visual teaching aid for upper cervical specific technique.

Table 1 - Sample Characteristics

Sample Characteristics	Total, N = 70	Visual Teaching Aid, n = 37	Written Guide, n = 33
Mean (SD) age (y) at assessment	25.7 (7.2)	26.3 (8.0)	25.0 (6.1)
Year group, n (%)			
Year 1	8 (11.4)	4 (10.9)	4 (12.1)
Year 2	26 (37.2)	13 (35.1)	13 (39.4)
Year 3	29 (41.4)	14 (37.8)	15 (45.5)
Year 4	7 (10.0)	6 (16.2)	1 (3.0)
Gender, n (%)			
Female	32 (45.7)	18 (48.6)	14 (42.4)
Male	38 (54.3)	19 (51.4)	19 (57.6)

Data are presented as n (%) unless stated otherwise.

visual teaching aid group percentage score improved by 24.4% (SD ± 12.3%; *p* < .01), and the written guide improved by 17.7% (SD ± 13.7%; *p* < .01).

DISCUSSION

This study aimed to determine if a written or a visual teaching aid influences learning retention when teaching a manual motor skill. Students using a teaching aid utilizing visual imagery showed greater recall of its contents when compared to the written guide.

Teaching the subluxation indicators (muscle tension, Prill test, cervical syndrome, motion palpation, and muscle tests) and adjustment setups for upper cervical vertebral subluxations as part of the college's upper cervical specific technique is often didactic and relies on a brute-force memorization approach.¹⁸ During previous years, it had been noticed that many chiropractic students seemed to lack the mental-rotation ability experienced chiropractors have that allows them to hold a 3-dimensional picture of the spine in their minds eye to which to apply upper cervical specific technique subluxation indicators. This lack of mental 3-D ability leaves many students reporting anecdotally that they try to rote learn upper cervical indicators in the hope that it might fall into place one day. While rote learning is a useful learning strategy, anxious people perform poorly when using only such learning,¹⁹ and words that are difficult to picture are harder to remember.²⁰ Key word mnemonics and mnemonic pictures seem to perform well in comparison,²¹ and visual imagery or words aids recall.²² Previous studies have shown that pictures and words are most effectively retained when they are presented together²³ and that the superiority of pictures in memory and learning tasks is well established.²⁴

Based on the studies mentioned above, it seems also likely that a pictorial guide (such as the 1 used in this study) to complex recall task would be more helpful in aiding student's recollection of complex course material than standard written notes. These findings should also be tempered with the fact that both learning aids showed improvements in recall after their use, so future studies would be recommended to investigate this line of research further.

This study has some limitations. While this study shows improvement in free recall of upper cervical subluxation indicators, only 3 subluxation listings were tested; thus, it is unknown if these visual guides improve recall about all upper cervical subluxation listings or listings elsewhere in the spine. What is also unknown is whether these guides improve understanding of the upper cervical subluxation indicators in a practical, patient-focused sense. Furthermore, the free recall questionnaire used has not been tested for validity; it was used as it was in a format familiar to the students. Future studies should use validated questionnaires where possible. Finally, both teaching guides showed improvements in recall after their use, so the findings in this study may not be generalizable to all courses teaching a motor skill. It would be wise to perform similar studies for other chiropractic technique courses, with prevalidated questionnaires to investigate the effects of visual guides on learning and recall.

Based on the outcome of this study, the NZCC has included the visual teaching guide in its upper cervical specific technique class notes. Additional future research could include testing future UCSC cohorts with the study questionnaire and comparing them to this study's original results to see how or if class testing improves over time.

Table 2 - Questionnaire Scores Pre- and Post-Visual Teaching Aid or Written Guide Review

Outcome	Intervention										Significance	
	Visual Teaching Aid					Written Guide					Group Effect, <i>p</i> Value	Group by Time Interaction, <i>p</i> Value
	N	Pre	N	Post	% Improved	N	Pre	N	Post	% Improved		
Total score N (SD)	37	42.18 (14.14)	37	59.76 (10.28)	24.4% (12.3)	33	44.61 (13.63)	33	57.33 (10.56)	17.7% (13.7)	.03	<.01

CONCLUSIONS

The use of a visual teaching guide showed improvements in learning retention when teaching a manual motor skill when compared to a written guide. This study suggests that visual teaching aids may be more useful than solely written material given that the understanding of many chiropractic techniques relies on skilled 3-dimensional mental modeling of a functional spinal unit. Chiropractic educators may find that visual teaching aids assist students' recollection of complex, multiplane spinal movements. However, further research is recommended to fully investigate this relationship.

ACKNOWLEDGMENT

The authors wish to acknowledge Mr Brad Johns, a final-year NZCC intern, for assisting in the creation of the visual guides used in this study.

FUNDING AND CONFLICTS OF INTEREST

This work was funded internally. The authors have no conflicts of interest to declare relevant to this work.

About the Authors

Alice Cade is a lecturer and intern mentor. Matthew Sherson is the head of the technique department. Kelly Holt is the dean of research. Graham Dobson is a lecturer and intern mentor. Katie Pritchard is the dean of chiropractic. Heidi Haavik is the director of research. All are with the New Zealand College of Chiropractic (6 Harrison Road, Mount Wellington, Auckland, New Zealand; Alice.cade@nzchiro.co.nz). Address correspondence to Alice Cade, 6 Harrison Road, Mount Wellington, Auckland, New Zealand; Alice.cade@nzchiro.co.nz. This article was received August 23, 2017, revised October 25, 2017, October 31, 2017, and accepted October 31, 2017.

Author Contributions

Concept development: AC. Design: AC, KH, GD, MH, KP. Supervision: AC, KH. Data collection/processing: AC. Analysis/interpretation: AC, KH. Literature search: AC. Writing: AC, KH. Critical review: AC, KH, GD, MH, KP, HH.

© 2018 Association of Chiropractic Colleges

REFERENCES

1. Schmeck RR. *Learning Strategies and Learning Styles*. New York, NY: Springer Science & Business Media; 2013.
2. Bellezza FS. Mnemonic methods to enhance storage and retrieval. *Memory*. 1996;1:345–380.

3. Bellezza FS. Mnemonic-device instruction with adults. In: Rensley M, Levin JR, eds. *Cognitive Strategy Research Part 1: Psychological Foundations*. New York, NY: Springer; 1983:51–73
4. Wilson BA, Diller L. *Rehabilitation of Memory*. New York, NY: Guilford Press; 1987.
5. Milne R, Bull R. Back to basics: a componential analysis of the original cognitive interview mnemonics with 3 age groups. *Appl Cogn Psychol*. 2002;16(7):743–753.
6. Patton GW. Testing the efficacy of name mnemonics used during conversation. *Psychol Rep*. 1994;75(1): 131–142.
7. Richardson JT. The efficacy of imagery mnemonics in memory remediation. *Neuropsychologia*. 1995;33(11): 1345–1357.
8. Richardson JT, Cermak LS, Blackford SP, O'Connor M. The efficacy of imagery mnemonics following brain damage. In: McDaniel MA, Pressley M, eds. *Imagery and Related Mnemonic Processes: Theories, Individual Differences, and Applications*. New York, NY: Springer-Verlag; 1987:303–328.
9. Tulving E. Introduction to part VI: memory. In: Gazzaniga MS, ed. *The New Cognitive Neurosciences*. Cambridge, MA: MIT Press; 2000:727–732.
10. Schacter DL, Graf P. Effects of elaborative processing on implicit and explicit memory for new associations. *J Exp Psychol Learn Mem Cogn*. 1986;12(3):432.
11. Alberini CM, LeDoux JE. Memory reconsolidation. *Curr Biol*. 2013;23(17):R746–R750.
12. Yoo Y-H, Kim J-H. Procedural memory learning from demonstration for task performance. Paper presented at: 2015 IEEE International Conference on Systems, Man, and Cybernetics (SMC); XXXX XX, 2015; XXXX, XX.
13. Woodfield HC III, York C, Rochester RP, et al. Craniocervical chiropractic procedures—a précis of upper cervical chiropractic. *J Can Chiropr Assoc*. 2015; 59(2):173.
14. International Business Machines Corp. *SPSS I. IBM SPSS Statistics Version 21*. Boston, MA: International Business Machines Corp. 2012:126.
15. Pallant J. *SPSS Survival Manual*. London: McGraw-Hill Education; 2013.
16. McCannon BC. Rock paper scissors. *J Econ*. 2007; 92(1):67–88.17.
17. Baek K, Kim Y-T, Kim M, et al. Response randomization of one- and two-person Rock–Paper–Scissors games in individuals with schizophrenia. *Psychiatry Res*. 2013;207(3):158–163.
18. Chougule M, Patil P. Role of small group discussion in comparison to didactic lecture in improving self directed learning among first year medical students. *Indian J Basic Appl Med Res*. 2015;1(5):501–505.
19. Montague EK. The role of anxiety in serial rote learning. *J Exp Psychol*. 1953;45(2):91.
20. Paivio A. Mental imagery in associative learning and memory. *Psychol Rev*. 1969;76(3):241.

21. Thomas MH, Wang AY. Learning by the keyword mnemonic: looking for long-term benefits. *J Exp Psychol.* 1996;2(4):330.
22. Paivio A, Yuille JC. Mediation instructions and word attributes in paired-associate learning. *Psychonomic Sci.* 1967;8(2):65–66.
23. Mayer RE, Anderson RB. The instructive animation: helping students build connections between words and pictures in multimedia learning. *J Educ Psychol.* 1992; 84(4):444.
24. Standing L. Learning 10000 pictures. *Q J Exp Psychol.* 1973;25(2):207–222.

Appendix A: Upper Cervical Questionnaire

Name:

Age:

Year:

Sex:

Grading rubric: 0 = incorrect, 1 = partially correct/complete, 2 = fully correct/complete

Listing	C1 Anterior, Superior, Right	C1 Atlas Right, Posterior	C2 Center Pivot, Body Right
Cervical Syndrome:			
Prill Test:			
Muscles involved:			
Motion restricted:			
Muscle Test (Touch):			
Muscle Test (Head position):			
Stance:			
Patient Position:			
Contact:			
Tissue Pull:			
LOD:			
Torque:			
	/24	/24	/24

**SUMMARY TABLES: CERVICAL SPECIFIC TECHNIQUE
UPPER CERVICAL ANALYSIS AND TOGGLE-RECOIL ADJUSTING
ATLAS C1/0 AND ATLAS C1/2
ALWAYS USE SUPERIOR HAND CONTACT FOR ATLAS TOGGLE ADJUSTMENTS**

Atlas Listing	C Syndrome Leg Checks, Prill Tests	Muscle Palpation (Tension)	Dobson Muscle Challenges— Positives	Motion Palpation (↓ Motion)	Toggle Recoil Adjustment
Ant/sup, R C1/0 (Blair). Combined ant/ sup and R TVP contact.	Fast balancing Prill C1+ on resistance to raising feet.	↑R levator scapula ↑L superior oblique.	TT: R styloid fossa. HP: head flx in slight R rotation and R lat flx.	Finger ant to C1 TVP. Motion: ↓C1/0 R cervical fl x combined with slight R rotation and R lat flx).	SCP: ant/sup C1 TVP. STANCE: ant/sup to contact pivoted to inf. LOC: S-I, A-P, L-M. TORQUE: clockwise, drop head piece angled up 5° under mastoid.
Ant/sup, R C1/0 (Blair). Ant/sup and R post arch contact.	As above.	As above.	As above.	As above.	SCP: inf aspect of R post arch. STANCE: <i>ant/inf</i> to contact pivoted to sup. LOC: I-S, A-P, L-M. TORQUE: clockwise, drop head piece level.
Post, R inferior C1/ 0 (Blair). Combined post inf to R post arch contact.	Fast balancing Prill C1+ on resistance to raising feet.	↑R levator scapula. ↑L sup oblique.	TT: R post of C1/0 artic. HP: head extension in slight R rotation and R lat flx.	Finger: post/sup of C1 lateral mass. Motion: ↓C1/0 R cervical extension combined with slight R rotation and R lat flx).	SCP: post/sup aspect of the atlas posterior arch in line with the right lateral mass. STANCE: Post/sup to contact pivoted to inf. LOC: S-I, P-A, L-M. TORQUE: N/A, drop head piece angled up 5° under mastoid.
Atlas right post C1/2 (Dobson). Contact R TVP of atlas. Counterrotations of C1 and C2 (C1 R TVP is rotated post with C2 Sp R).	Short leg becomes shorter Prill C1+ on resistance to raising feet.	Periarticular edema at R post C1/2 artic.	HP: full R head rotation and slight flx. PT: contact mid- C2 lamina with thumbs. Brush skin A-P to C2 Sp and P-A to C1 R TVP at same time.	Finger on post of C1/2 articulation. Motion: ↓C1/2 R cervical rotation and extension.	TVP contact: SCP: post to R TVP. STANCE: Post and slightly inf to contact slightly pivoted to superior. LOC: strongly P-A and slightly I-S, lateral to medial. TORQUE: clockwise, drop head piece level.

R = right; L = left; TVP = transverse process; lat flx = lateral flexion; SCP = segmental contact point; lat = lateral; med = medial; ant = anterior; sup = superior; inf = inferior; LOC = line of correction; Sp = spinous process.