

## Early detection of dens evaginatus appearing on the premolars and clinical management: histological study

T. Kawata\* / K. Tanne\*\*

*A review of the methods for the prevention of central cusp fracture is presented, with a case of central cusp protection of a premolar by self-curing acrylic resin by early detection. The anomalous tooth was extracted for histological observation. Closure of the pulpal horn, could be accomplished by early detection and adequate treatment for the central cusp fracture of premolars. In this case, if the gradual attrition of a central cusp were not possible, a protecting the cusp using a self-curing acrylic resin would be an effective form of treatment.*

J Clin Pediatr Dent 26(2): 199-201, 2002

### INTRODUCTION

Central cusp is present on the occlusal surface of premolars. An invasion of dental pulp is often observed in the central cusp. This anomaly has no known hereditary origin, but has been described as occurring together with other dental abnormalities such as odontomas and impacted canines. Radiographically, central cusps have a structure similar to normal tooth tissue, since they consist of enamel, dentine and usually contain a horn of pulp.<sup>1,2</sup>

Central cusps may present a number of problems both to the patient and orthodontist. If there is a potentially normal premolar relationship, then they are likely to interfere with the occlusion by forming a premature contact, and in many cases, a reduction of the bulk of the central cusp may be necessary. The cusp or the opposing tooth may also undergo attrition. This report shows a radiographical and histological studies of a case of central cusp, which was protected by a self-curing acrylic resin.

### MATERIALS AND METHODS

#### The prevention of central cusp fracture

The occlusal surface of the tooth was cleaned with polishing paste. A 37% phosphoric-acid gel was applied to the occlusal surface of tooth for 60 seconds. The teeth were rinsed with a water spray for 30 seconds and dried with an oil-free air source for 15 seconds. The occlusal surface looked like a chalky white in color. Superbond (Sun Medical Co, Shiga, Japan) orthodontic bonding self-curing acrylic resin was applied and an orthodontic brush was used for superbond molding.

#### Tooth extraction

The patient gave her informed consent before extraction. The human subject protocols were approved by the Committee on Investigations Involving Human Subjects, Hiroshima University Faculty of Dentistry.

#### Histological observation

The tooth was fixed with 4% formaldehyde for 12 hrs at 4°C, decalcified in 5% ethylenediamine tetra acetic acid (EDTA, pH 7.4) for two weeks, embedded in paraffin, and cut into longitudinal sections of 7m thickness. These sections were stained with hematoxylin and eosin (HE).

### RESULTS

On examination, the tooth had a large central cusp to the upper second premolar (Figure 1). A Radiograph of the central cusp showed a pulpal horn (Figure 2). The central cusp was protected by the application of a self-curing acrylic resin at early detection. Acrylic resin was attached on the occlusal surface for about one year (Figure 3). At one year acrylic resin was observed to the bottom surface and showed good

\* T. Kawata, Hiroshima University Faculty of Dentistry, Department of Orthodontics, 1-2-3 Kasumi, Minami-ku Hiroshima 734-8553, Japan.

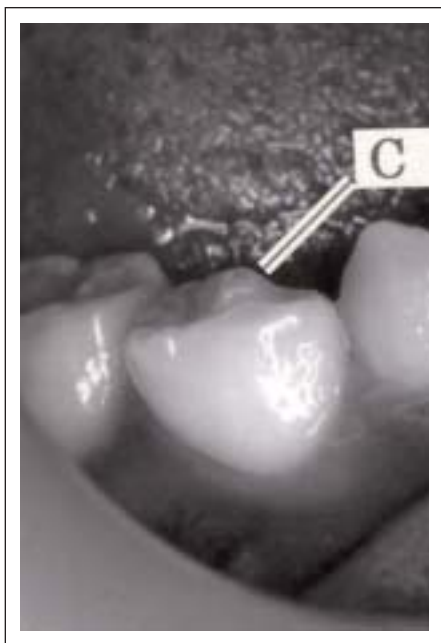\*\* T. Kawata, Hiroshima University Faculty of Dentistry, Department of Orthodontics, 1-2-3 Kasumi, Minami-ku Hiroshima 734-8553, Japan.

Send all correspondence to Dr. T. Kawata, Hiroshima University Faculty of Dentistry, Department of Orthodontics, 1-2-3 Kasumi, Minami-ku Hiroshima 734-8553, Japan.

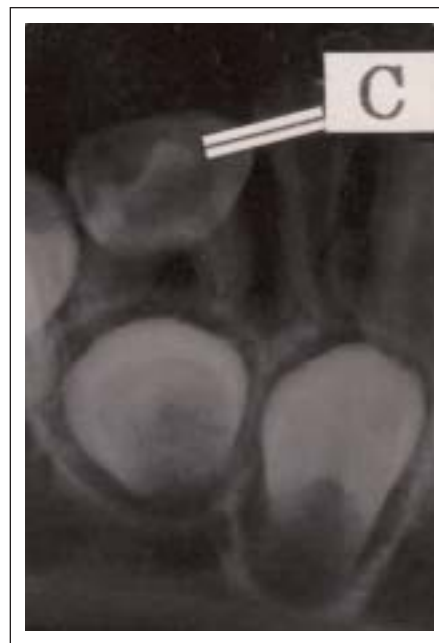Tel: (81)-82-257-5686;

Fax: (81)-82-257-5687

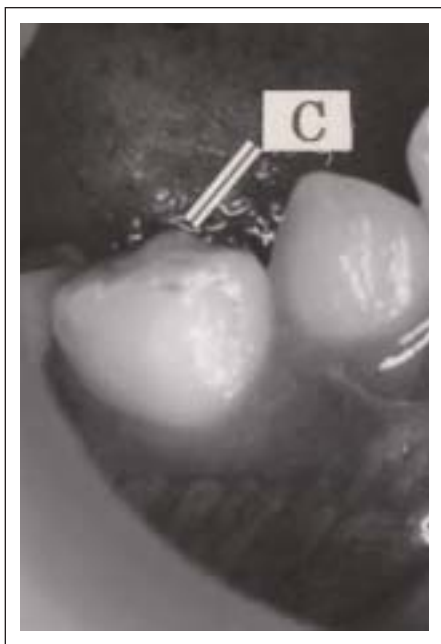
E-mail: tenzan@hiroshima-u.ac.jp



**Figure 1.** The appearance of the central cusp on initial presentation. C: central cusp.



**Figure 2.** Radiographic appearance on presentation. C: central cusp.



**Figure 3.** The appearance of the cusp when protected by self-curing acrylic resin at early detection. C: central cusp.

adhesive properties (Figure 4). Histological examination showed a large pulpal cavity and a wide radicular canal extending from the pulp horns through the root apex (Figure 5).

#### DISCUSSION

If it is necessary to reduce a central cusp, then it may be possible to carry out the gradual removal of the central cusp on several consecutive visits, after protecting the

cusp with a self-curing acrylic resin. Otani<sup>3</sup> reported using this method to remove a central cusp without pulpal exposure.

However, Saito<sup>4</sup> and Yaezawa et al.<sup>5</sup> both reported that the cusp tooth underwent attrition after the resin was applied. It is likely that if the central cusp is reduced at a rate, which allows enough reparative dentine to be laid down to avoid pulpal exposure, then many of the problems associated with the presence of a central cusp may be avoided. In this study the central cusp was protected by acrylic resin for about one year.

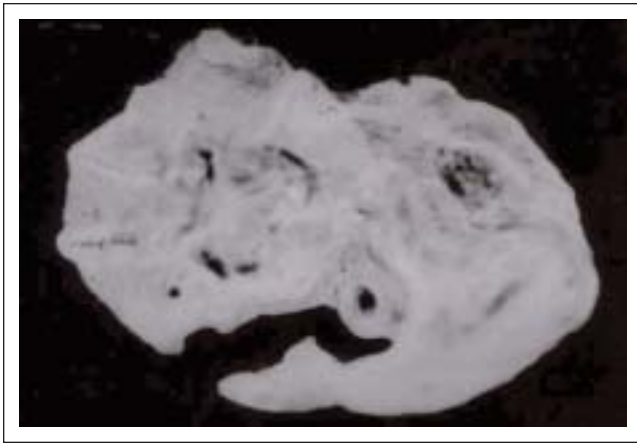Histological examination showed that, the pulp did not penetrate deeply into the central cusp. We suggest that closure of the horn of pulp can be accomplished by early detection and a useful treatment for central cusp fractures of premolars.

#### CONCLUSION

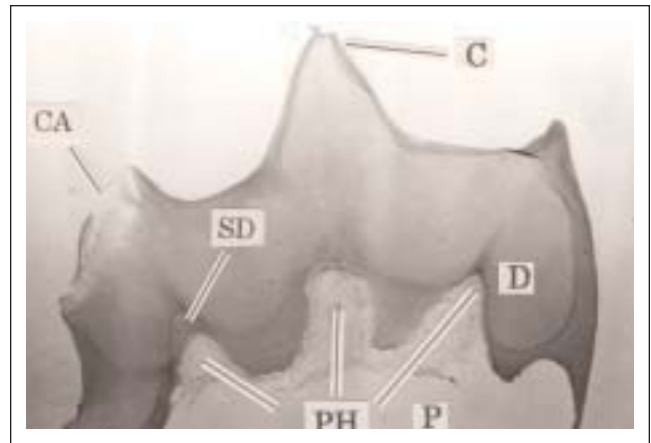
In conclusion, if gradual attrition of a central cusp is not possible, protecting the cusp using a self-curing acrylic resin is an effective form of treatment.

#### REFERENCES

1. Noikura T, Ooya K, Kikuchi M. Double dens in dente with a central cusp and multituberculism in bilateral maxillary supernumerary central incisors: report of a case. *Oral Surg Oral Med Oral Pathol* 82: 466–469, 1996.
2. Pledger DM, Roberts GJ. Talon cusp: report of a case. *Br Dent J* 167: 171–173, 1989.
3. Otani H, Nonaka K, Matsumoto T, et al. Early detection of dens evaginatus appearing on the 1st and 2st premolars and clinical management. *Jpn J Pediat Dent* 31: 536–541, 1993.



**Figure 4.** The bottom surface of the cusp after the application of the self-curing acrylic resin.



**Figure 5.** A photomicrograph of the upper second premolar. P: pulp. C: central cusp. CA: caries. D: dentin. PH: pulp horn. SD: secondary dentin.

4. Saito T. Abnormality of dental tubercle. *Dental Diamond* 11: 208–213, 1986.

5. Yaezawa T, Haishima K, Tomizawa M et al. A clinical study on 7 premolars treated with endodontic therapy due to central cusp fracture. *Jpn J Pediat Dent* 33: 833–841, 1995.

