

Amelogenesis imperfecta and nephrocalcinosis: a new case of this rare syndrome

Isabelle Normand de la Tranchade* / Hervé Bonarek** / Jean-Marie Marteau*** / Marie-José Boileau**** / Javotte Nancy*****

This article describes a new case of a rare syndrome including enamel agenesis of the primary and permanent dentition, delayed or absent eruption of the permanent dentition, coronal intra-alveolar resorption and gingival enlargement. Renal symptoms include medullary nephrocalcinosis without any apparent cause, and evolution to a renal failure. The early diagnosis provided by the oral symptoms leads to a better renal prognosis. As a consequence, pediatric dentists should be aware of this pathology.

J Clin Pediatr Dent 27(2): 171-176, 2002

INTRODUCTION

The syndrome of Amelogenesis Imperfecta and Nephrocalcinosis is relatively rare. Only four sibling pairs have been described until now.

Amelogenesis Imperfecta is a group of hereditary developmental defects of the tooth enamel. It can belong to several syndromes, but it is pathognomonic of a few.

Inheritance is mainly autosomal dominant, but autosomal recessive, X-linked and sporadic cases can also occur.

Nephrocalcinosis is a common disease characterized by the precipitation of calcium salts in the renal tissue. Hypercalcemia and/or hypercalciuria is usually found except in a few rare syndromes including Amelogenesis Imperfecta.

In the previously described families, there was no family history of Amelogenesis Imperfecta or renal problems, and in one case, parents had blood relations; so autosomal recessive inheritance is strongly suggested in this syndrome.

Presented in this report is an isolated case, none of the parents, brothers or sisters were affected.¹

CASE REPORT

The patient, a girl aged 15 years, presented at the Department of Dentistry for a severe delay of eruption affecting the premolars, permanent canines and molars.

She consulted much more for esthetic reasons than for functional reasons whereas, the discomfort was real. The patient had no significant medical history, notably no hypertension or uro-nephrologic or dental pathology. Her general health was also good. She was a well-proportioned child with no cranio-facial, dermal or skeletal dysmorphologies, nor abnormality of the skin, hair or nails. She was of normal intelligence.

The extraoral examination did not reveal any abnormality, but there was a TMJ dysfunction. The intraoral examination revealed the presence of all the primary teeth, except the maxillary and mandibular incisors, which had been replaced by the permanent ones. There was also a mandibular premolar, which had erupted partially. The primary teeth were discolored light-yellow and were very abraded (Figure 1).

The permanent incisors which were erupted by only two millimeters into the mouth, were also discolored light-yellow. The incisors were small and widely spaced. There was also a slight gingival enlargement. The orthopantomogram showed a number of non-erupted

* Dr. Isabelle Normand de la Tranchade, 7 rue Roquelaine, 31000 Toulouse, France. Send all correspondence to Dr. Isabelle Normand de la Tranchade.
Voice: 05 61 62 58 65

or

Université d'Odontologie de Bordeaux II, Service d'Odontologie pédiatrique, 16 cours de la Marne, 33000 Bordeaux, France.
E-mail: i.normand@wanadoo.fr

** Dr. Hervé Bonarek, Hopital Saint André, Service de Néphrologie, Cours d'Albret, 33000 Bordeaux, France.

*** Dr. Jean-Marie Marteau, Université d'Odontologie de Bordeaux II, Service de Chirurgie Buccale, 16 cours de la Marne, 33000 Bordeaux, France.

**** Pr. Marie-José Boileau, Université d'Odontologie de Bordeaux II, Service d'Orthodontie, 16 cours de la Marne, 33000 Bordeaux, France.

***** Dr. Javotte Nancy, Université d'Odontologie de Bordeaux II, Service d'Odontologie Pédiatrique, 16 cours de la Marne, 33000 Bordeaux, France.

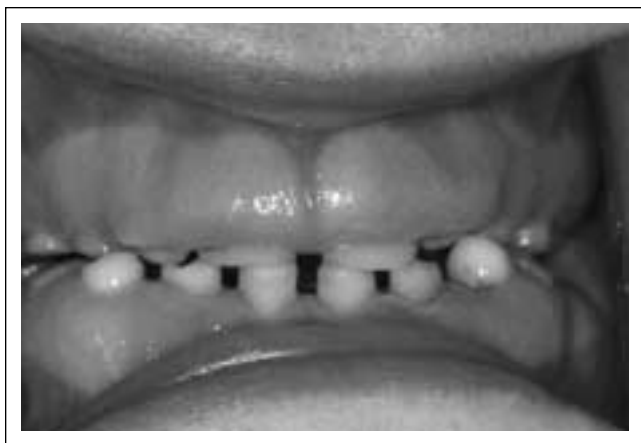

Figure 1.

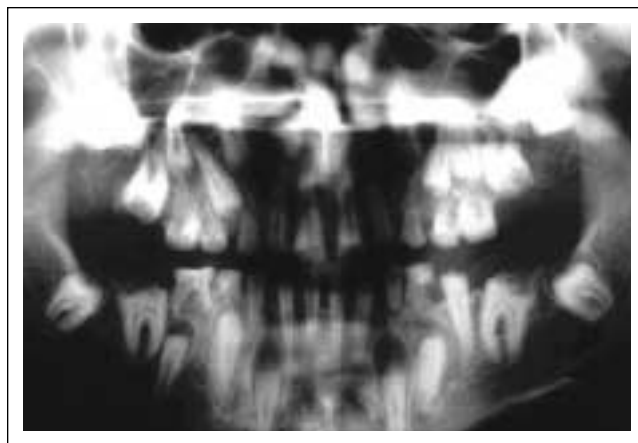


Figure 2.

permanent teeth, with well-developed roots and sometimes intracoronal resorptions. There was no agenesis, nor any supernumerary teeth (Figure 2). Intraoral radiographs confirmed the previous information and showed the rarity of enamel on both primary and permanent dentition.

The scan analysis showed both numerous and voluminous follicular cysts.

A structure abnormality and a delayed eruption were diagnosed, but it was impossible to specify the pathology.

In our opinion, the pathology was systemic, but there were no clinically evident symptoms associated with a known pathology. Therefore, we did an extensive evaluation, looking for rare syndromes associated with Amelogenesis Imperfecta.

Pictures were submitted to various specialists, including Pr. Hall, who suggested the association of Amelogenesis Imperfecta and Nephrocalcinosis.

We performed a plain abdominal film showing a few small bilateral calcification foci in renal areas. The diagnosis of medullary Nephrocalcinosis was confirmed by renal ultrasound scan, with the presence of numerous medullary hyperechoic foci on both kidneys. The size of the kidneys was normal, and there were no urinary tract abnormalities. The patient had no history of urinary tract infection, macroscopic hematuria, renal calculus, childhood enuresis or polyuria.

Subsequent investigation revealed a slightly impaired renal function with glomerular filtration rate 80 ml/mn/1.73m² assessed by an isotopic method.

Creatinemia was slightly elevated at 107(mol/L). There was no proteinuria, no macroscopic hematuria, no blood electrolytic abnormalities nor acidosis.

The main urinary abnormalities were a low excretion of calcium at 1.34 mmol/24H (N: 2-6mmol/24H) and citrate at 0.3mmol/24H (N: 2.2-4.4mmol/24H). Urinary phosphate was also slightly reduced at 16.20mmol/24H.

Urinary oxalate, amino-acids and pH were normal. Concerning the other parameters of calcium metabolism, no other abnormalities were found. Plasma Ca and P were normal at 2.33mmol/L and 1.20mmol/L respectively. PTH, 25-OH vitamin D3, 1,25-OH vitamin D were in the normal range. Bone densitometry was also normal and bone age corresponded to chronological age.

Therapy began before the diagnosis of Amelogenesis Imperfecta and Nephrocalcinosis. The therapy aimed at restoring a functional and esthetic denture. First the esthetic appearance was restored by surgery and the addition of composite material on the incisors, to ensure motivation by the patient and to protect the pulp. A gingivectomy and an osteotomy were done for esthetic reasons and with the intention of uncovering the crown of the incisors. Amelogenesis Imperfecta was then evident because of the roughness of the enamel (Figure 4).

Then, to compensate for the TMJ dysfunction and ensure the maintenance of the incisor restorations, an appropriate vertical occlusal dimension had to be found. With this end in view, the first mandibular molars were treated with steel stainless crowns and a lingual arch wire was welded to the crowns.

During the surgery, we noted an inclusion of hard tissue in the crown of a permanent molar, which was not enamel. The pathological examination revealed that the sample was an Haversian bone inclusion. The dental crown seemed to be progressively resorbed and replaced by bone. A sample of the dental follicle of a permanent molar was also extracted and examined. It seemed to present some pathological calcifications (Figure 5). One of the primary molars and incisors were examined in our laboratory. Light microscopy confirmed the absence of enamel in both of them.

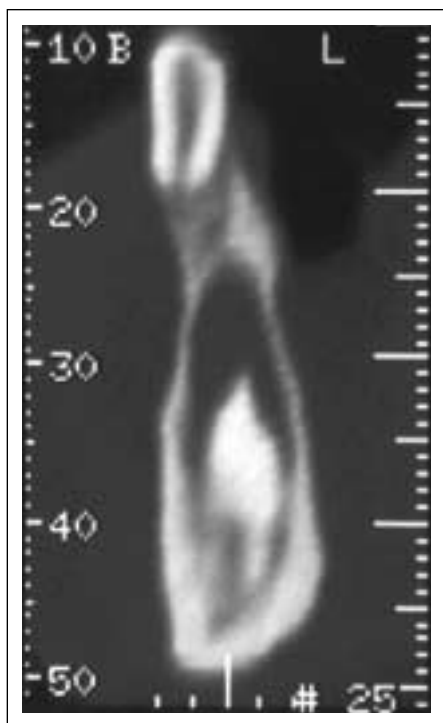


Figure 3.

DISCUSSION

The first sibling pair was described by Mac Gibbon in 1972.² The sister was diagnosed by screening after her older brother developed renal failure and hypertension. Both had the same enamel defect. The brother died at the age of 26, with a severe renal failure as a complication arising from his Nephrocalcinosis.

The sister also developed multiple urinary infections, hypertension and renal failure. The subsequently reported cases,^{3,4} had in common a failure of the teeth to erupt, unexplained Nephrocalcinosis, enamel agenesis and normal plasma calcium, 25-OH vitamin D₃, alkaline phosphatase and parathyroid functions.

Renal failure and urinary infections have also often been described (Table 1). The rarity of this syndrome makes diagnosis difficult. The relationship between the enamel defect and the Nephrocalcinosis is still unknown. The hypothesis has been made of an underlying abnormality in the interstitial matrix leading to dystrophic calcifications in the kidneys, and abnormal enamel production in the teeth.⁴

Two separate, but closely linked genes, could also be involved. Finally, some authors have suggested that albumin and osteopontin could be involved in the renal and dental defect, since they both occur in the renal and dental calcium metabolism.³ Most of all, the genes responsible for the synthesis of these two proteins are carried on the same chromosome.

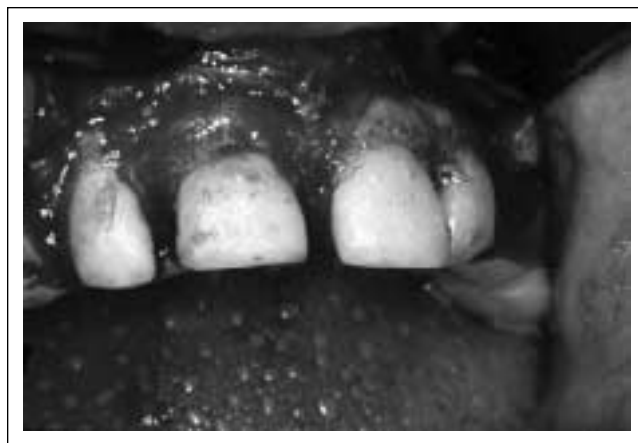

Figure 4.

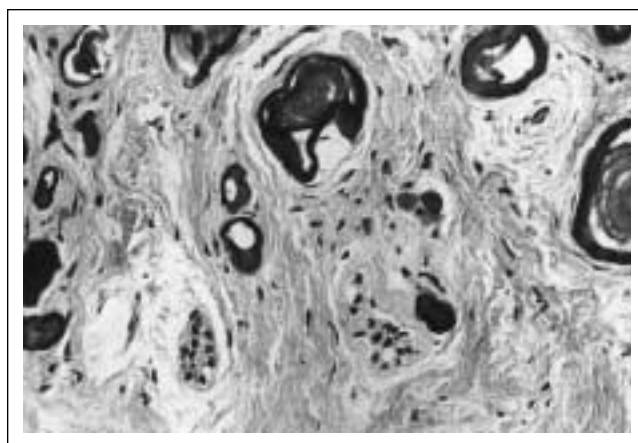


Figure 5.

Concerning the dental pathology, four aspects seem to be particularly interesting:

1. The delay of eruption could be explained by the pathology of the dental follicle, as has already been demonstrated.^{5,6} The dental follicle might be unable to synthesize the factors that initiate eruption. It could also obstruct the eruption by a mechanical retention due to cystic or fibrous transformation. Our recent experiments have shown some calcifications in the dental follicle that could indirectly explain the delay of eruption.
2. Amelogenesis Imperfecta, in both dentures, was studied by Phakey⁷ and Hall.⁸

They found that hypoplasia of enamel matrix and the hypocalcification and hypomaturation of the enamel crystals were present on the same tooth. They describe the enamel ultrastructure and clinical features in two siblings with the little known syndrome of Amelogenesis Imperfecta and Nephrocalcinosis. Nephrocalcinosis was diagnosed by radiographic examination of the abdomen, intravenous pyelography,

Table 1. Cases in the literature and our patient

	Mac Gibbon Male Female		Lubinsky Male Female		Phakey - Hall Male Female		Dellow Male Female		Maryse R. (our patient) Female
Symptomatic uronephrological pathology	yes	yes	yes	no	no	yes	yes	no	no
Calcemia	normal		normal		normal		normal		normale
Calciuria	normal		↘		normal		↘		↘
Sanguine alkaline phosphatases	normal		normal		*		normal		normal
urinary phosphate	*		↘		normal		normal		normal (↘)
PTH	*		normal		normal		normal ↗		normal (↗)
25(OH) vitamin D3	*		normal		normal		normal		normal
Proteinuria	*		*		normal		↗		normal
Urinary citrates	*		↘		normal		normal		↘
Urinary oxalates	*		↘		normal		normal		normal (())
Plasmatic creatinine	*		normal		normal normal ↗		↗		↗
Urinary aminoacids	*		normal		normal		normal		normal
Plasmatic inorganic phosphate	normal		normal		normal		normal ↘		normal
Urinary pH	*		normal		normal		normal		normal
δ-carboxyglutamic acid	*		↘		*		*		*
Osteocalcin	*		↗		normal		*		normal (↗)

* results not reported

ultrasonography, and computed tomography scan. Amelogenesis imperfecta was diagnosed from clinical and histological examinations.

The affected enamel was hypoplastic (approximately 0.2 mm thick), positively birefringent, generally aprismatic, porous, and consisted of loosely packed, randomly orientated, thin (approximately 10 nm wide), ribbonlike crystals. The enamel surface was rough, extensively cracked, and covered with ovoid or globular protrusions. Observations showed that in this case hypoplasia, hypocalcification, or hypomaturational defects were present in the same tooth, indicating that both secretory and maturation phases may have been affected.

The study suggested the possibility of an abnormality in interstitial matrix, which could lead to dystrophic calcification in the kidney and abnormal

tooth enamel formation. It also suggested the possibility of involvement of two separate, but closely linked genes.⁸

Therefore, the Amelogenesis Imperfecta and Nephrocalcinosis syndrome is difficult to classify. The gingival enlargement is not associated with a local bacterial cause, nor with a general disease or treatment. Nor could we entirely explain the intra-alveolar resorptions of some crowns.

Concerning the renal pathology, the Nephrocalcinosis remains unexplained. Nephrocalcinosis is a common disease, with a variable prognosis depending on the underlying disease. In the Amelogenesis Imperfecta and Nephrocalcinosis syndrome, no predisposing factors such as hypercalcemia or hypercalciuria have been found. On the contrary, our patient presented a very low urinary calcium and citrate

excretion. The same abnormalities were found by others.⁴ It remains unclear whether these are the cause or consequence of this syndrome and whether it may be involved in the Nephrocalcinosis. Through the different reported cases, it seems that there is no abnormality of bone metabolism. In any respect, the patient was not symptomatic and the renal involvement could have remained unknown until a nephrological examination was done. Because of hypocitraturia, we proposed a citrate supplementation which is a crystallization inhibitor, in order, may be, to prevent the aggravation of calcium salts precipitation in the renal tissue.

This syndrome is extremely rare and the prognosis is unknown. Dental development disorder requires a team approach with the pediatric dentist as coordinator, an oral surgeon, a periodontist, an orthodontist, and finally a prosthodontist to undertake the difficult final crown construction. While renal function seems stable in our patient, who is now 17, worsening of renal function or other complications can ensue, as reported by Mac Gibbon. Ignoring the renal involvement can lead to serious consequences. In any case, since the pathogenesis remains unknown until now, therapy consists above all in surveillance and palliative treatment of these renal complications.

All children with autosomic recessive hypoplastic Amelogenesis imperfecta should be referred for renal examination to detect Nephrocalcinosis.

ACKNOWLEDGMENTS

The authors are extremely grateful to Dr. Roger Hall for his helpful assistance in the pathological diagnosis of the patient. They also thank Dr. Chris Laing for the genetic analysis.

REFERENCES

1. Normand de la Tranchade I. Syndrome d'Amélogénèse imparfaite et néphrocalcinose. A propos d'un cas. Thèse de Chirurgie Dentaire n° 16. Université de Bordeaux II. 14 juin 2000.
2. MacGibbon D. Generalized enamel hypoplasia and renal dysfunction. *Aust Dent J* 17: 61-63, 1972.
3. Dellow EL, Harley KE, Unwin RJ, Wrong O, Winter GB, Parkins BJ. Amelogenesis imperfecta, nephrocalcinosis and hypocalciuria syndrome in two siblings from a large family with consanguineous parents. *Nephrol Dial Transplant* 13: 3193-3196, 1998.
4. Lubinsky M, Angle C, Marsh PW, Witkop CJ. Syndrome of amelogenesis imperfecta, nephrocalcinosis, impaired renal concentration and possible abnormality of calcium metabolism. *Am J Med Genet* 20: 233-243, 1985.
5. Marks SC. The basic and applied biology of tooth eruption. *Connect Tissue Res* 32: 149-157, 1995.
6. Wise GE. Cells and molecular bio of tooth eruption. In: *The biological mechanisms of tooth eruption, resorption and replacement by implants*. Davidovitch Z, editor, Birmingham, AL, EBSCO Media, 1998.
7. Phakey P, Palamara J, Hall RK, Mc Credie DA. Ultrastructural study of tooth enamel with amelogenesis imperfecta in AI-nephrocalcinosis syndrome. *Connect Tissue Res* 32: 253-259, 1995.
8. Hall RK, Phakey P, Palamara J, Mc Credie DA. Amelogenesis imperfecta and nephrocalcinosis syndrome. Case studies of clinical features and ultrastructure of tooth enamel in two siblings. *Oral Surg Oral Med Oral Pathol Oral Radiol End* 79: 583-592, 1995.

