

Endodontic management of an impacted premolar

Virginia Karapanou*

This report demonstrates a simple endodontic solution to an interdisciplinary case of a patient with multiple gene deficiencies. An adolescent patient presented with an impacted premolar that could not be extracted due to high-risk conditions. A suspicious degree of radiolucency around the crown was clinically diagnosed as dentigerous cyst. The treatment dilemma and implementation are discussed. This case report offers a different treatment option for impacted teeth when significant differential diagnosis of a pericoronal lesion dictates treatment.

J Clin Pediatric Dent 29(4): 293-298, 2005

INTRODUCTION

Impacted teeth are often treated with surgical extraction or orthodontic manipulation and eruption. Oral and maxillofacial surgeons devote a large portion of the practice to the removal of impacted teeth.

In addition to the wisdom teeth, the most commonly impacted teeth are maxillary canines, maxillary central incisors, mandibular second premolars and mandibular second molars.¹ The reason for non-eruption is, most likely, diversion or deviant angulations during development of the root end. Once the root formation is completed, teeth decrease their potential to erupt.² Conversely, impacted teeth display an increased potential in causing significant problems.³ An ankylosed tooth or a tooth with a failed eruption mechanism may be mistaken for an impacted tooth.⁴

In a retrospective study⁵ of 2646 pericoronal lesions during a time period of six years, it has been shown that 67.1% of all submissions contained no pathological follicular tissue. However, significant lesions were diagnosed in 32% of cases. Among these lesions were 673 dentigerous cysts (28.4%); 79 dentigerous cysts with mucous cell protoplasia, 71 odontogenic keratocysts (2.68%); 19 odontomas 0.7%, 13 ameloblastomas (0.5%); 6 carcinomas (0.23%); 6 calcifying odontogenic cysts (0.23%); 4 calcifying epithelial odontogenic tumors and one odontogenic myxoma (0.04%).

Hyperplastic follicular tissue and a dentigerous cyst are the two most common entities associated with the crown of an impacted tooth. Still, ameloblastoma is

well documented as pericoronal radiolucency associated with an impacted tooth. Furthermore, research stresses the importance of histological evaluation of all pericoronal radiolucencies.

The potential for the development of significant, even life-threatening, disease associated from impacted teeth is well-documented.

The objective of this report is to present a clinical case of an impacted tooth treated with endodontic therapy. The medical history, the justification of the treatment and the outcome are discussed.

Endodontic therapy of this impacted tooth offered a simple solution. Additional complications for the patient were avoided and his chief complaint was addressed.

CASE REPORT

A 17-year-old male patient sought consultation and possible treatment for a mandibular impacted premolar without obvious clinical symptoms. The mother reported "My son has an impacted tooth that can not be extracted."

Patient offered a complex medical history, as well as, a contributory dental history, but he had no known allergies and he was not taking any medications. He has Usher's Syndrome and Amelogenesis Imperfecta (AI).

Usher's Syndrome is a genetic disorder that causes congenital sensorineural hearing impairment, vestibular malfunction and progressive visual loss due to progressive pigmentary retinopathy. The etiology is a genetic mutation in a gene that encodes a protein with domains related to many types of extra cellular matrix and cell surface receptor proteins. This protein, called Usherin, is found in all of the capillary and structural basement membranes of the human retina and ear. Usherin's role appears to be critical for normal development and tissue homeostasis in the inner ear and retina. It has been also observed in high levels in other

* Virginia Karapanou, DMD, Assistant Professor, Department of Endodontics, Tufts University School of Dental Medicine, One Kneeland Street, Boston, MA 02111

Voice # 617-636 6796

Fax # 617- 636 6885

E-mail: Virginia.karapanou@tufts.edu

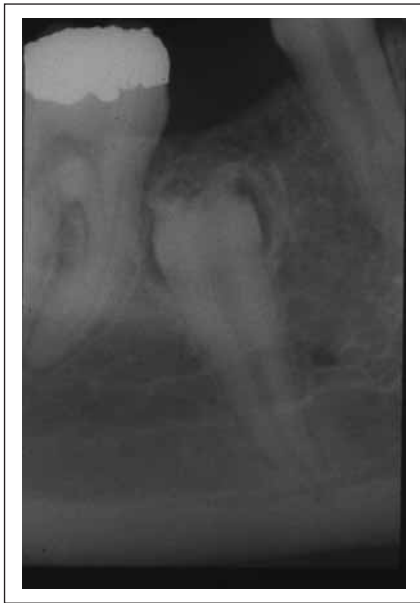

Figure 1. Pre-operative radiograph.



Figure 2. Surgical endodontic access.

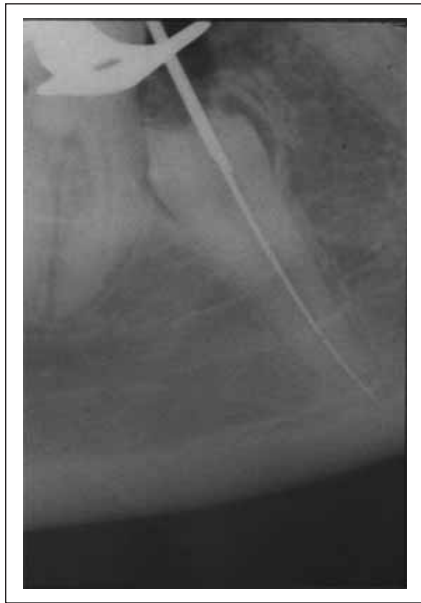

Figure 3. Guide file radiograph.

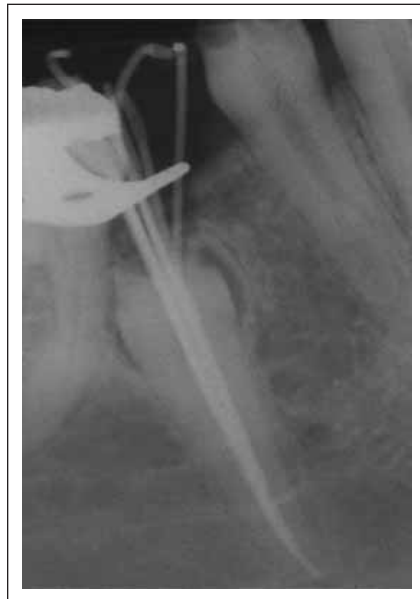

Figure 4. Partial fill radiograph.

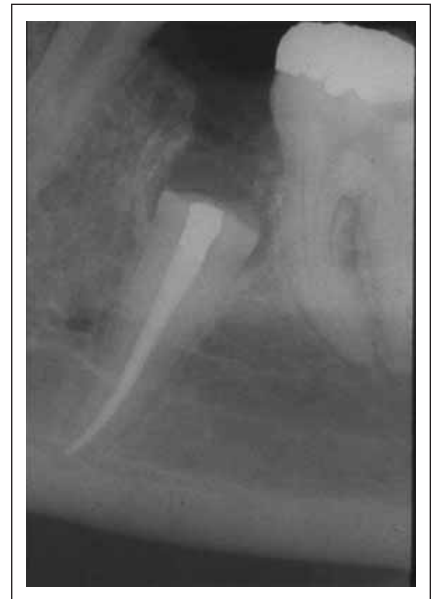

Figure 5. Post-operative radiograph.

tissues not affected by Usher's Syndrome like the sub maxillary gland, spleen, testis, oviduct, epididymis, large and small intestines.⁶

At least three clinical types are known relating to the degree of severity and combination of clinical symptoms like deafness, vestibular dysfunction, and progressive retinitis pigmentosa. Several subtypes have been described in relationship with other abnormalities.^{7,8}

Usher's Syndrome is a fine paradigm of the genetic concepts of pleiotropy and significant heterogeneity.⁹

Approximately 70 genes have found to be related to craniofacial anomalies, 30 genes are related to dental

tissue disorder, 20 genes found related to facial clefting defects and 3 genes related to craniosynostosis.¹⁰ The current case may suggest a possible link for Usher's Syndrome with Amelogenesis Imperfecta (AI), the most common hereditary disease of enamel. However, it is not our intention to illustrate this.

AI is a collective term for a hereditary disfiguring oral condition with hypoplastic, hypomineralized, abnormal enamel. Two enamel proteins amelogenin and tuftelin/enamelin are associated with enamel formation and appear to play significant role in the etiology of AI.¹¹ The mechanisms involved in biosynthesis and secretion of these extracellular matrix proteins

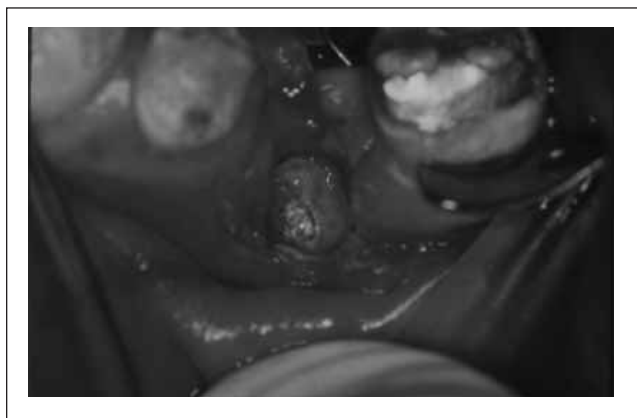


Figure 2. Surgical endodontic access.

have been investigated. The amelogenin gene is located on the chromosome X. Mutations within the amelogenin gene cause X-linked AI.¹² The tuftelin/enamelin gene has been localized to the long arm of the autosomal chromosome. An autosomal dominant or recessive trait linked to the tuftelin/enamelin gene results in autosomally linked AI.¹³ Defects in genes encoding other enamel proteins are also candidates for autosomal forms. Both types of AI present interesting genotype-phenotype correlations depending on severity of molecular defects on the genes involved.

It is remarkable that both Usher's syndrome and AI have variable clinical phenotypes. One month earlier, the patient was presented at Department of Pediatric Dentistry, Tufts University School of Dental Medicine. His chief complaint was "I want better looking teeth." His pediatric dentist proposed a complete oral rehabilitation treatment plan with extensive crown and bridge restorative work.

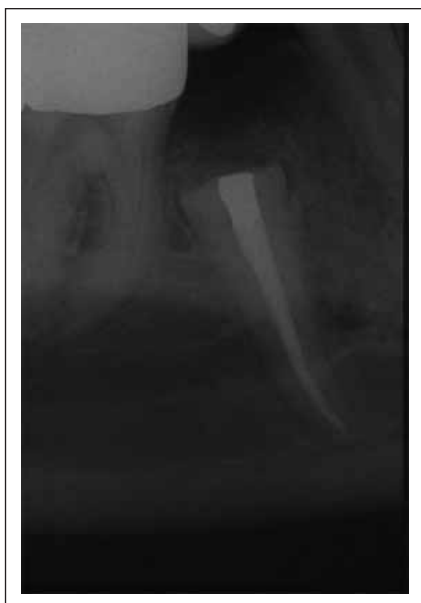

Figure 8. Final recall four years later.

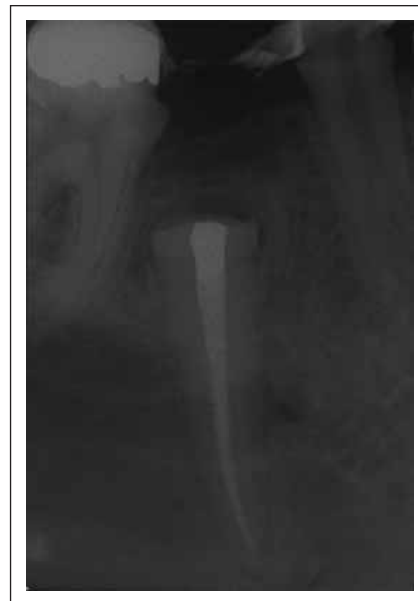

Figure 7. First recall six months later.

Clinically missing tooth #20 was detected on panoramic radiograph located inside the mandible. The patient was referred to the Oral and Maxillofacial Surgery department for evaluation and treatment of the impacted tooth with a tentative diagnosis of small follicular cyst/dentigerous cyst. The oral surgeon did not extract #20 due to increased risk of fracturing the jaw and traumatizing the mandibular nerve.

A significant generalized loss of enamel was obvious throughout dentition. All teeth appeared stained with erosion, attrition, abrasion, hypoplastic and hypocalcification defects. The periodontal condition was generalized moderate gingival inflammation. There was space between teeth #21 and #19. Soft tissues appeared normal with slight expansion on the buccal side. Periodontal probing for teeth #21 and #19 was found within normal limits.

Periapical and occlusal radiographs were taken.

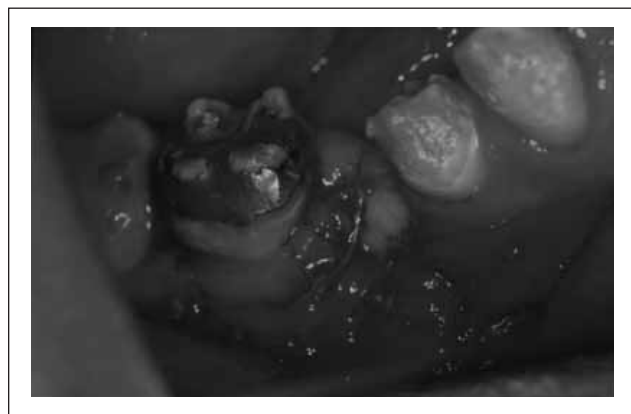

Figure 9. Sutures after procedure.

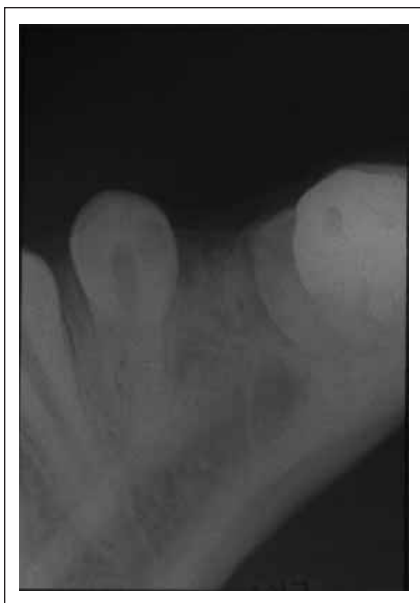

Figure 10. Occlusal radiograph.

Vitality thermal tests with ice were responsive for both teeth #21 and #19.

Tooth #20 was impacted, fully developed with closed apex and well-formed root. The crown appeared to be surrounded by a pericoronal, symmetric and well-circumscribed radiolucency. The crown suffered enamel loss and sponge appearance dentin.

The location of the tooth was buccally at the interproximal space between #21 and #19 at close proximity with the mesial aspect of #19.

The pediatric dentist had a treatment plan which included the fabrication of a bridge between teeth #21 and #19. The access for surgical removal of the crown and follicle of that tooth was easier at time.

With a diagnosis of normal pulpal tissue and normal periapical status, conventional root canal therapy with surgical access was recommended. The suspicious pericoronal lesion would be removed by curettage and sent for biopsy.

Patient was very cooperative during exam and his mother gave informed consent for treatment.

Anesthesia of 1.8ml Xylocaine 2%, 1:100000 Epi for IANB and 1.8ml Xylocaine 2%, 1:50000 for infiltration was administered, an horizontal incision parallel to the alveolar crest on the buccal was performed between #21 and #19 with two releasing parallel vertical incisions towards the lingual, one distal of #21 and one mesial of #19.

The flap was reflected and 0.9ml Xylocaine 2%, 1:50000 Epi was infiltrated to control bleeding. Osteotomy was performed with copious irrigation of sodium chloride 0.9%. The crown was removed and the tissue around the crown was curetted by surgical scraping of the soft tissue and surrounding bone, to allow

removal of the contents for biopsy and sufficient access to the root canal system.

Rubber dam placed on tooth #19 to the mesial side of #22. The canal was instrumented with serial filing at working length determined with a guide file radiograph and irrigated with sodium chloride 0.9%. Tooth was filled with lateral condensation and Roth's sealer.

Gutta-percha cones were sheared off at CEJ and the access entrance was sealed with amalgam filling. The flap was closed with absorbable 0.4 chromic gut sutures. The patient was comfortable and tolerated the procedure well. He was given post-op instructions and an analgesics prescription.

One week later, the soft tissues were healing without any complications and the patient was asymptomatic. According to the biopsy report, the histopathological features of the tissue surrounding the crown were similar to those of normal dental follicular tissue around a developing tooth.

Six months later the patient was asymptomatic. Soft tissues appear within normal limits. There was a temporary bridge on the adjacent teeth. Radiographically, the surgical access appeared to be filling in with bone.

Four years later, the patient appeared with PFM Bridge from #21 to #19. Soft tissues were normal. Radiographically, complete healing had occurred.

DISCUSSION

Pericoronal radiolucencies are common findings surrounding impacted teeth. They may present no pathological conditions such as a normal dental follicle. They may also present hyperplastic dental follicles with various degrees of radiolucency around the impacted crown, but require no intervention. However, if a follicular space, detected in an intraoral radiograph, is greater than 2.5mm, then it is clinically suspicious because such radiolucencies associated with unerupted teeth may develop pathological change.¹⁴

Dentigerous cysts are asymptomatic, well-circumscribed, symmetrical, radiolucent lesions and arise almost twice as often in male as in female patients in the second or third decade of life. A greater proportion of dentigerous cysts, removed from older patients, suggest that retained follicles may become clinically cystic in time.¹⁵ Al - Talabani and Smith¹⁶ explained the pathogenesis of human dentigerous cysts and imply a possible role for enamel hypoplastic defects in cyst initiation.

Treatment options for the management of impacted teeth are falling into four categories: extraction, observation, autotransplantation (relocation) and orthodontic intervention.¹⁷ Treatment modalities for pericoronal lesions almost always include extraction of the involved impacted tooth to prevent recurrence of the cyst. Another advisable treatment is cyst marsupialization in order to preserve the related tooth and promote its eruption.¹⁸

Surgical conservative endodontic treatment with crown excision followed by curettage seemed to be the most appropriate therapeutic option for our patient. The completed developmental status of the root apex and the relationship of the impacted tooth to the surrounding structures affected the procedure options.

Intraoral radiography is necessary to provide accurate assessment about the location and position of an impacted tooth. The orthodontic practice of maxillary impacted canine extrusion and alignment has driven research to identify various radiographic techniques so that the position of a clinically missing canine would be accurately reported. Conventional dentoalveolar radiographic examinations continue to be instrumental in the majority of cases. Clark¹⁹ introduced the "buccal object rule" in 1909. By taking two periapical radiographs at different angles, the object closest to the lingual surface will appear on the film to move in the same direction that the cone moved. Almost 50 years ago, Hitchin²⁰ suggested the use of occlusal radiographs as another way to identify the buccolingual relationship of impacted teeth. Recently, Computed Tomography with advanced three-dimensional image has been proposed as an important aid, but the applicable high radiation dose to young patients is not desirable and the cost offsets the qualified advantages.²¹

The occlusal radiograph in our case confirmed the Clark's rule and provided evidence for the clinical appearance of the alveolar ridge.

The patient and his parents did not choose the option of orthodontic extrusion for tooth #20. If the treatment plan included orthodontic reposition of #20, endodontic therapy would have been the treatment of choice since the hypoplastic defective crown of the impacted premolar would not allow use of the direct bonding system to apply traction. Endodontic therapy allows the cementation of a post. The shallow position and angulation of tooth #20 in the alveolar bone was favorable. The prognosis for orthodontically moving an impacted tooth into occlusion depends on the position and angulation, the length of treatment time, the age and cooperation of the patient, the available space and keratinized gingival tissue.^{22,23}

This case was evaluated and treated before the broad use of advanced technology. In modern dentistry, the use of a microscope would be further helpful to accomplish microscopic examination of the follicular tissue for identification of cystic cavity between the soft tissue and the enamel of the tooth. Such an observation will enhance the diagnosis of a dentigerous cyst and it is included in the recommended guidelines for diagnosis of a dentigerous cyst.¹⁵ A normal follicle is attached to the enamel by a basement membrane and hemidesmosomes, while a true cyst exhibits a fluid-filled cavity that allows the operator to easily separate at least portion of the dentigerous cyst from the impacted tooth. This observation was not possible in

this case as tooth #20 was fully impacted and microscopic vision was not used.

The amalgam, used to seal the access cavity in this case, has been the most widely used root-end-filling material, but it has come under mounting condemnation for reasons such as leakage, biocompatibility, corrosion, staining and mercury hazard.²⁴ Mineral Trioxide Aggregate (MTA) is the present most promising compound that has shown consistently superior quality and good biocompatibility.²⁵ In this case the amalgam provided a well tolerated fibrous encapsulated surface and the soft tissues presented with no staining, as it was shown by the four years follow-up radiograph. However, the use of MTA would have provided, most likely, a surface for cell attachment and better adaptation at the dentin-filling interface.²⁶

The introduction of highly flexible rotary Ni-Ti file systems and evolved obturation techniques has also facilitated root canal preparation. Teeth with complicated internal root canal system may be treated in a predictable and timely manner.

CONCLUSION

Unfavorable root canal anatomy was extremely difficult to be treated predictably before the broad use of advanced endodontic technology. The impacted teeth may present a complex anatomy or invisible location. However, in selected cases and based upon this case report, the clinician may have a new multidisciplinary revelation in treatment planning for impacted teeth. The present case report has demonstrated that conservative endodontic treatment can expand the therapeutic options and it may be considered one of the treatment modalities for impacted teeth that require intervention.

REFERENCES

1. Kramer RM, Williams AD. The incidence of impacted teeth. *Oral Surg Oral Med Oral Pathol* 29: 237-41, 1970.
2. Kokich VG, Mathews DP. Surgical and orthodontic management of impacted teeth. *Dent Clin North Am* 37: 181-204, 1993.
3. Lytle JJ. Indications and contraindications for removal of the impacted tooth. *Dent Clin North Am* 23: 333-46, 1979.
4. Frank AL, Glick DH, Patterson SS, Weine FS. Long-term evaluation of surgically placed amalgam fillings. *J Endodont* 16: 528-33, 1990.
5. Curran AE, Damm DD, Drummond JF. Pathologically significant pericoronal lesions in adults: Histopathologic evaluation. *J Oral Maxil Surg* 60: 613-17, 2002.
6. Pearsall N, Bhattacharya G, Wisecarver J, Adams J, Cosgrove D, Kimberling WJ. Usherin expression is highly conserved in mouse and human tissues. *Hear Res* 174: 55-63, 2002.
7. Otterstedde CR, Spandau U, Blankenagel A, Kimberling WJ, Reisser C. A new clinical classification for Usher's syndrome based on a new subtype of Usher's syndrome type I. *Laryngoscope* 111: 84-6, 2001.
8. Marietta J, Walters KS, Burgess R, Ni L, Fukushima K, Moore KC, Hejtmancik JF, Smith RJ. Usher's syndrome type IC: clinical studies and fine-mapping the disease locus. *Ann Otol Rhinol Laryngol* 106: 123-8, 1997.

9. Samuelson S, Zahn J. Usher's Syndrome. *Ophthalmic Paediatr Genet* 11: 71-6, 1990.
10. Slavkin HC. Molecular biology experimental strategies for craniofacial-oral-dental dysmorphology. *Connect Tissue Res* 32: 233-9, 1995.
11. Simmer JP, Hu JC. Dental enamel formation and its impact on clinical dentistry. *J Dent Educ* 65: 896-905, 2001.
12. Aldred MJ, Crawford PJ. Molecular biology of hereditary enamel defects. *Ciba Found Symp* 205: 200-5, 1997.
13. Deutsch D, Palmon A, Dafni L, Mao Z, Leytin V, Young M, Fisher LW. Tuftelin-aspects of protein and gene structure. *Eur J Oral Sci* 106: 315-23, 1998.
14. Farah CS, Savage NW. Pericoronary radiolucencies and the significance of early detection. *Aust Dent J* 47: 262-5, 2002.
15. Daley TD, Wysocki GP. The small dentigerous cyst: A diagnostic dilemma. *Oral Surg Oral Med Oral Pathol* 79: 77-81, 1995.
16. Al-Talabani NG, Smith CJ. Experimental dentigerous cysts and enamel hypoplasia: their possible significance in explaining the pathogenesis of human dentigerous cysts. *J Oral Pathol Med* 9: 82-91, 1980.
17. Frank CA. Treatment options for impacted teeth. *JADA* 131: 623-32, 2000.
18. Miyawaki S, Hyumoto M, Tsubouchi J, Kirita T, Sugimura M. Eruption speed and rate of angulation change of a cyst-associated mandibular second premolar after marsupialization of a dentigerous cyst. *Am J Orthod Dentofacial Orthop* 116: 578-84, 1999.
19. Clark CA. A method of ascertaining the position of unerupted teeth by means of film radiographs. *Proceedings of the Royal Society of Medicine (Odontological section)* 3: 87-90, 1909.
20. Hitchin AD. The impacted maxillary canine. *Dental Practitioner*. 2: 100-3, 1951.
21. Lecomber AR, Yoneyama Y, Lovelock DJ, Hosoi T, Adams AM. Comparison of patient dose from imaging protocols for dental implant using conventional radiography and computed tomography. *Dentomaxillofac Radiol* 30: 255-9, 2001.
22. Fournier A, Turcotte J, Bernard C. Orthodontic consideration in the treatment of maxillary impacted canines. *Am J Orthod* 81: 236-9, 1982.
23. Vanarsdall RL, Corn H. Soft-tissue management of labially positioned unerupted teeth. *Am J Orthod* 72: 53-64, 1977.
24. Frank AL, Glick DH, Patterson SS, Weine FS. Long-term evaluation of surgically placed amalgam fillings. *J Endodont* 16: 528-33, 1990.
25. Hauman CHJ, Love RM. Biocompatibility of dental materials used in contemporary endodontic therapy: a review. Part 2. Root-canal-filling materials. *Inter Endo J* 36: 147-160, 2003.
26. Torabinejad M, Smith PW, Kettering J, Pitt Ford TR. Comparative investigation of marginal adaptation of Mineral Trioxide Aggregate and other commonly used root-end filling materials. *J Endo* 21: 295-99, 1995.