

Oral manifestations of juvenile hyaline fibromatosis: a case report

Manal I. Al-Malik* / Ziad A. Rehmini** / Ali A. Eltayeb***

Hyaline fibromatosis is a rare autosomal recessive disease of connective tissue, characterised by an accumulation of hyaline in the skin as well as various organs. The clinical features include: multiple cutaneous nodules, joint contractures, osteolytic lesions and gingival hypertrophy. This paper reports the case of an 11-year-old boy, who was referred to our dental clinic complaining of pain in his mouth. On examination, the patient had gross maxillary and mandibular gingival hyperplasia, which caused severe feeding difficulties. He also had severe dental decay, mal-positioned teeth and limited mouth opening. Treatment was done under general anesthesia to remove excess gingival tissue and extract the severely decayed teeth. Histological examination confirmed the diagnosis of juvenile hyaline fibromatosis. It was concluded that patients with this condition have special dental needs. Early diagnosis of the affected children is important in order to start early preventive dental therapy.

J Clin Pediatr Dent 29(4): 347-352, 2005

INTRODUCTION

Hyaline fibromatosis is an extremely rare inherited autosomal recessive disease of connective tissue, characterized by an accumulation of hyaline in the skin as well as various organs.¹⁻³ This condition was first described by Murray in 1873¹ and only a few cases were reported in the literature. It is believed that the condition results from an inborn error of metabolism, but this disease is still not well understood.⁴

Two clinical conditions are recognized in the literature: infantile systemic hyalinosis (ISH) and juvenile hyaline fibromatosis (JHF). These two conditions are usually difficult to separate because they show significant overlap with similar clinical and histopathological findings, therefore it was suggested that the conditions should be known as systemic hyalinosis.⁵

The clinical features include: multiple cutaneous nodules, particularly of the scalp and neck, small pearly facial papules around the nostrils, chin and ears, painful progressive joint contractures, osteolytic bone lesions and gingival hypertrophy.

The onset of ISH is at birth or during early infancy and death usually occurs in early childhood,^{3,5,6} while in

JHF the onset is within the first few years of life and most of those affected may survive into adulthood.^{5,7}

Additionally, some symptoms, like recurrent severe infections, chronic diarrhea and diffuse thickened skin seen in ISH are not common features in JHF. So whether JHF represents a mild form of ISH remains unclear.^{2,8}

This report presents the oral findings of a juvenile hyaline fibromatosis patient, who was referred to our dental clinic due to pain in his mouth and poor dental condition. Evidence of clinical and histopathological findings aided in establishing the diagnosis.

CASE REPORT

The patient was an 11-year-old Saudi boy born to consanguineous parents, who has 2 older and 1 younger sibling all in good health. The child had multiple cutaneous nodules located on the scalp, both ears (Figures 1, 2) and upper and lower limbs, as well as hyperpigmented papules over the proximal interphalangeal joint of the hand (Figure 3). He also had multiple contractures and short stature.

Radiographic examination revealed multiple osteolytic defects. The boy was severely handicapped by the joint contractures with no spontaneous movement and was completely dependent on his parents. The flexion contractures developed at the age of 6 months, when he became increasingly stiff and began to lose motor skills. The hyaline fibrous nodules appeared during the first few years of life and slowly enlarged. No other medical abnormalities were detected. There was no history of gastrointestinal or urinary symptoms and no history of bleeding disorder or skin rash. CT scan of the brain did

* Manal I. Al-Malik, BDS, MS, PhD, Consultant Pedodontist, Dental Department, Armed Forces Hospital, Jeddah, Saudi Arabia.

** Ziad A. Rehmini, BDS, MS, Consultant Oral Surgeon, Dental Department, Armed Forces Hospital- Jeddah, Saudi Arabia.

*** Ali A. Eltayeb, MBBS, DCP, FRC path Consultant Pathologist, Pathology Department, Armed Forces Hospital- Jeddah, Saudi Arabia.

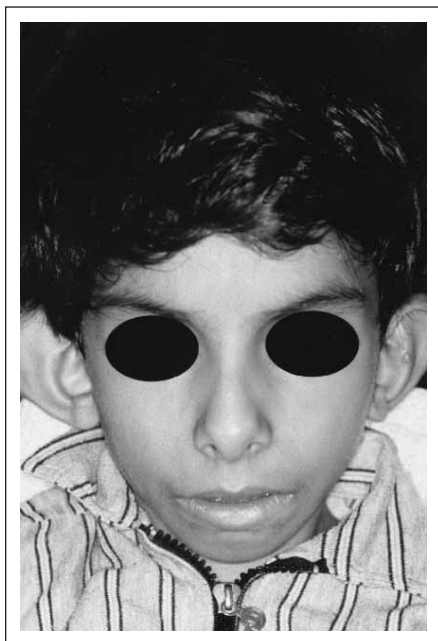

Figure 1. The facial appearance of the child with Juvenile Hyaline Fibromatosis.

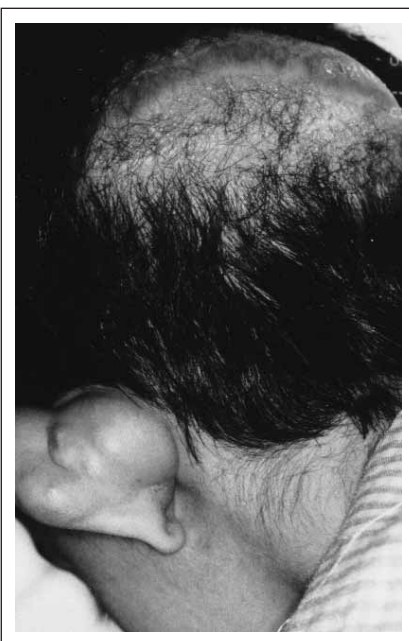


Figure 2. The present of cutaneous nodule behind the left ear and a scar of the surgically removed nodule on the back of the scalp.

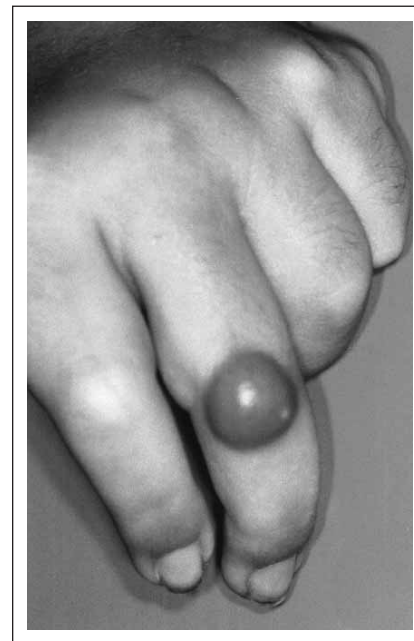


Figure 3. Hyperpigmented papule over the proximal interphalangeal joint of the finger.

not show any signs of intra cranial pathology. Mental development was normal.

Laboratory investigations of complete blood count, metabolic screening including mucopolysaccharide, as well as renal, liver and thyroid tests were all within normal limits. The boy was admitted on a number of occasions to various hospitals for examination and diagnosis. He was first seen in our hospital at the age of 5 years when his parents sought counseling for his condition.

The patient was under the care of a pediatric rheumatologist, who prescribed penicillin and methotrexate as therapeutic trial, however his symptoms progressed and did not improve.

Oral findings

The child was referred to our dental clinic complaining of pain in his mouth and was unable to eat. Oral examination revealed gross maxillary and mandible gingival hypertrophy, which was soft and inflamed and covering most of his teeth (Figure 4). This caused pain and severe feeding difficulties. He also had severe dental decay, mal-positioned teeth and limited mouth opening. A thick band of muscular fibers was felt at the corner of the mouth (in the *orbicularis oris* and buccinators muscles areas), which was lacking normal muscular elasticity and formed a ring of stiff fibers around the ostium. The movement of the temporomandibular joint was rotational and there was great limitation of transitional sliding of the condyles to maintain normal mouth opening. There was no deviation of the mandible during mouth opening and no joint sounds were heard during the condylar movement.

Treatment was done under general anesthesia to extract the badly decayed teeth and to remove the hyperplastic gingival tissue (Figure 5). Biopsies were taken from the hyperplastic tissue and the cheek muscles to confirm the diagnosis. CT scan of the temporomandibular joint (TMJ) was performed to check for the limited mouth opening. Dietary advice, as well as, oral hygiene instructions were given and the use of Corsodyl gel and mouth rinse were recommended.

Histopathological findings (Figures 6, 7)

The light microscopic examination of hypertrophic gingival tissue removed from the mandibular jaw revealed normal lining non keratinizing stratified squamous epithelium with focal areas of hyperplasia. The central part of the hypertrophic tissue is hypocellular, revealing deposition of hyaline amorphous, eosinophilic collagen-like material surrounding, in some areas, columns of fibroblastic cells.

The Congo Red and Elastic Van Gieson failed to demonstrate amyloid material and collagen fibers respectively. Irregular ectatic thin walled blood vessels are seen lined with flat endothelial cells. At the periphery of the amorphous tissue more cellular areas are seen surrounded with dense chronic inflammatory infiltrate (mainly lymphocytes and plasma cells) which indicates chronic gingivitis. The overlying mucosa opposite the inflamed areas showed ulceration.

The biopsy from the cheek muscles consisted mainly of striated muscle fibers with degeneration collagen material, but there were no hyaline deposition in the biopsy. Other biopsies taken previously from nodules of scapula, occiput, sacrum, ear, neck and scalp showed

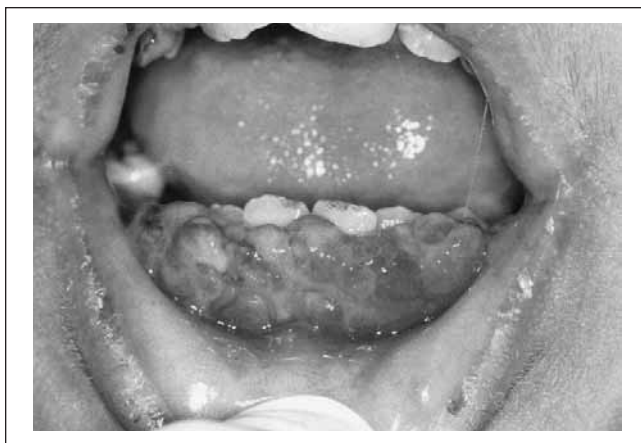

Figure 4. Pre-operative view: The gingival hyperplasia in the mandibular anterior region causing pain and feeding difficulty.

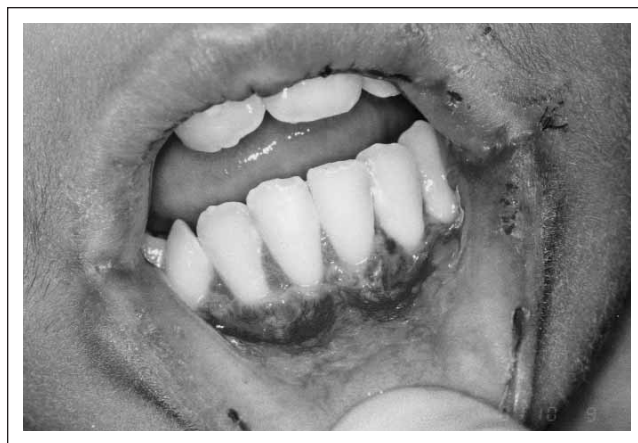

Figure 5. Post-operative view: The hyperplastic gingival tissue was removed.

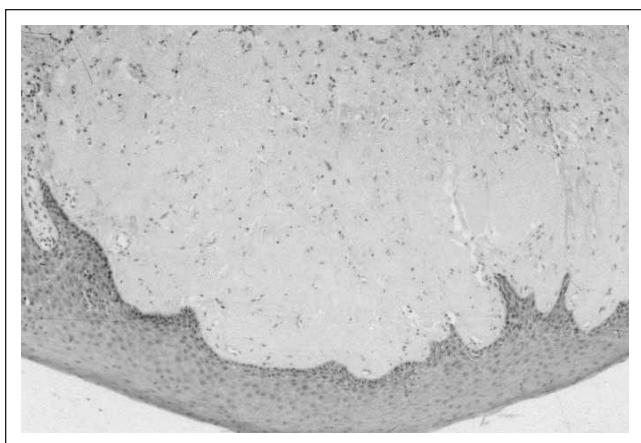


Figure 6. Microscopic appearance of the gingival tissue showing submucosal deposition of hyaline material (magnification X100).

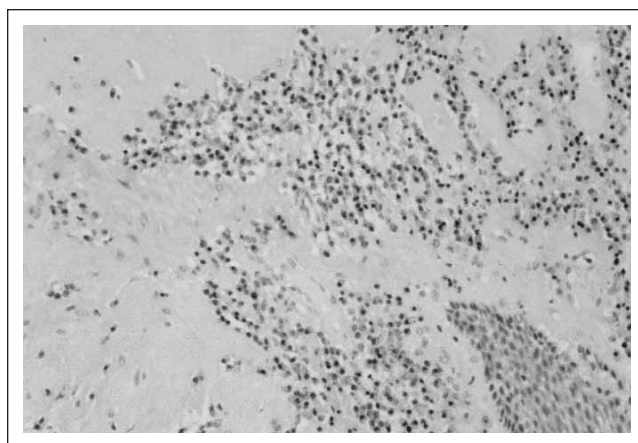


Figure 7. Microscopic appearance of the tissue showing the periphery of gingival nodule with lymphocyte and plasma cell (magnification X200).

similar histological appearances. The histological examination confirmed the diagnosis of JHF, which represents the same underlying pathological condition as ISH.

DISCUSSION

Juvenile hyaline fibromatosis is an extremely rare condition, with only 40 cases reported, and is usually diagnosed in the first few years of life.^{2,5,9} Both ISH and JHF are conditions affecting the connective tissue and are characterized by joint contracture, cutaneous nodules and gingival hypertrophy, however the symptoms in ISH are more severe with death occurring in early childhood. The differences between these two conditions are summarized in Table 1.

The cutaneous lesions are typically slow growing and painless, commonly located on the head, face, back and limbs.^{2,3,8} All these features (nodules, gingival hypertrophy and joint contractions) are present in our patient. The hyaline fibrous nodules appeared during the first few years of life and slowly enlarged. Although most of the lesions are formed during childhood, new lesions may continue to appear into adult life. Over the

Table 1. The differences between Infantile Systemic Hyalinosis (ISH) and Juvenile Hyaline Fibromatosis (JHF)

	Infantile Systemic Hyalinosis	Juvenile Hyaline Fibromatosis
Onset	Within the 1st few week of life with death occurring by 20 months	Within the 1st few years of life and most of those affected may survive into adulthood.
Recurrent severe infection	Yes	No
Chronic diarrhea	Yes	No
Diffuse thickened skin	Yes	No
Large cutaneous nodules and tumors	No	Yes
Joint contracture	Yes	Yes
Gingival hypertrophy	Yes	Yes
Osteolytic lesions	Yes	Yes
Hyperpigmentation over the bony prominences	Yes	No
Histological finding	Same	Same
Visceral involvement (intestinal, cardiac, hepatic, spleen, thyroidal)	Yes	No
Failure to thrive	Yes	No

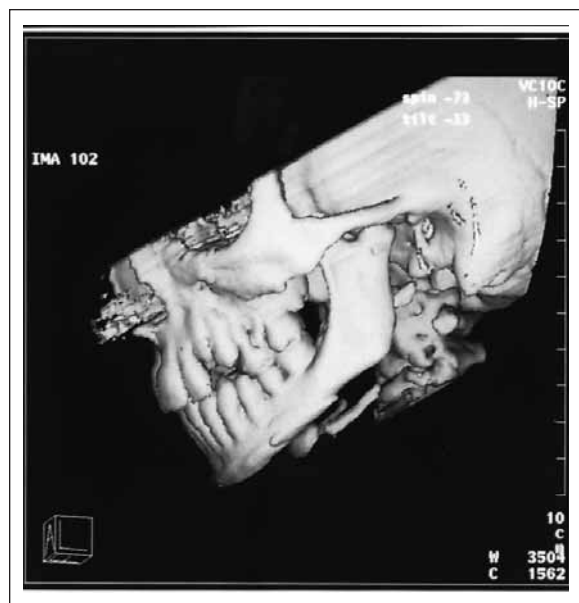

Figure 8. CT scan of the TMJ showing abnormal size of TMJ and fosse, flattening of the condylar heads, shortening of the necks of the condyles and elongation of coronoid process.

years they show small changes in size, shape and microscopic appearance, and persist.

The child had severely decayed teeth and poor dental condition. It would be expected that oral hygiene procedures may not be done properly and thereby dental plaque will accumulate due to limited mouth opening, the inability of the patient to perform oral hygiene due to his disability, and his dependence on others to perform oral hygiene. In addition, a soft diet was necessary for the patient. All these factors may lead to extensive dental caries, impaired oral health and poor dental condition.

Histological diagnosis remains the main means of diagnosis. JHF can be confused with a number of other conditions, also involving oral and skin lesions including neurofibromatosis, infantile myofibromatosis, infantile digital fibromatosis, Winchester syndrome and hyalinosis cutis mucosae. The clinicopathological correlation would help in differentiating these entities. Striking histological similarities have been noticed between JHF and ISH.

Electron microscopic appearances and histochemistry also confirm the similarity in both lesions. The basic defect appears to be a localized metabolic disturbance in the formation of collagen (Collagen type VI) in both lesions. The difficulty in staining with Elastic Van Gieson may be related to defective collagen formation. Considering the systemic deposition of hyaline material in skin, mucosa and other organs, systemic hyalinosis was suggested to embrace both diseases (the infantile and juvenile forms). The infantile form represents the severe form with involvement of more than

one type of tissue and with a bad prognosis. The juvenile form is a milder form of the disease appearing in childhood.

Although the pathogenesis of this condition is still unknown, collagen of poor quality (typical of type VI collagen) is associated with this condition² and this was confirmed in our histological study. The function of this type of collagen is to form a filamentous network that binds structures like blood vessels and nerves into a functional unit, while maintaining flexibility and strength.⁹ Previous reports suggested that an increase in the amount of this type of collagen would be expected to result in stiff joints, limitation of joint movement and thick skin.² Also it has been suggested that the capsules of the joints could be infiltrated by hyaline material¹⁰ and this would expect to cause joint contracture.

The patient had limited mouth opening. The CT scan for the TMJ showed abnormal TMJ region; flattening of the condylar heads, shortening of the necks of the condyles, elongation of both coronoid processes, flat and reversed glenoid fossa, flat sigmoid notch and decrease in the vertical height of the mandibular body distal to first molar (Figure 8). The degenerative changes in the muscles around the mouth, the shape of the TMJ and the elongated coronoid processes may be responsible of the limitation of mouth opening. Other muscles of mastication may exhibit the same muscular degenerative changes and maybe MRI scan of the joints may show capsular and discs abnormality.

No effective treatment to date has been found for these patients. Even when these lesions are excised for function and esthetic reasons they keep recurring, however, the surgical reductions of these lesions have benefited the patients.^{2,5,11}

CONCLUSION

Patients with this condition have special dental needs, therefore early dental consultation is important in order to start early standard caries preventive measures and dental therapy.

Unfortunately, no known therapy exists for hyaline fibromatosis. The prognosis is poor and the only treatment is to control pain and infection. The excised lesions keep recurring, which necessitates further surgical reduction. However, for function and aesthetic improvement and to relieve pain the surgical removal of excessive hypertrophic tissue is recommended.

ACKNOWLEDGEMENT

I would like to thank Dr M. Majeed, 'Paediatric Rheumatologist' in Armed Forces Hospital in Jeddah, Saudi Arabia for revising this manuscript.

REFERENCES

1. Witkop CJ Jr. Fibromatosis, juvenile hyaline. In: Buyse ML. ed. Birth defects encyclopedia. New York, Blackwell Scientific, pp. 736-738, 1990.
2. Glover MT, Lake BD, Atherton DJ. Infantile systemic hyalinosis: newly recognized disorder of collagen. *Pediatrics* 87: 228-234, 1991.
3. Devlin H, Sloan P, Thakkar NS. Oral manifestations of infantile systemic hyalinosis. *J Oral Pathol Med* 24: 140-143, 1995.
4. Piattelli A, Scarano A, Di Bellucci A, Matarasso S. Juvenile hyaline fibromatosis of the gingiva: a case report. *J Periodontol* 67: 451-453, 1996.
5. Glover MT, Lake BD, Atherton DJ. Clinical, histologic, and ultrastructural findings in two cases of infantile systemic hyalinosis. *Pediatr Dermatol* 9: 255-258, 1992.
6. Landing BH, Nadorra R. Infantile systemic hyalinosis: report of four cases of a disease, fatal in infancy apparently different from Juvenile systemic hyalinosis. *Pediatr Pathol* 6: 55-79, 1986.
7. Finlay AY, Ferguson S, Holt PJA. Juvenile hyaline fibromatosis. *Br J Dermatol* 108: 609-616, 1983.
8. O'Neil DB, Kasser JR. Juvenile hyaline fibromatosis. A case report and review of musculoskeletal manifestations. *J Bone Joint Surg* 71: 941-944, 1989.
9. Keene DR, Engvall E, Glanville RW. Ultrastructure of type VI collagen in human skin and cartilage suggests an anchoring function for this filamentous network. *J Cell Biol* 107: 1995-2006, 1988.
10. Suzuki S, Kasahara Y, Seto Y, Futami T, Ochi J. Juvenile hyaline fibromatosis. A case report. *J Bone Joint Surg* 74: 290-293, 1992.
11. Hutchinson I. Juvenile systemic hyalinosis - a rare cause of gingival hypertrophy. a case report. *Int J Paediatr Dent* 6: 39-43, 1996.